

World Journal of *Clinical Cases*

World J Clin Cases 2022 October 26; 10(30): 10823-11213



REVIEW

- 10823** New insights into the interplay between intestinal flora and bile acids in inflammatory bowel disease
Zheng L
- 10840** Role of visfatin in obesity-induced insulin resistance
Abdalla MMI

MINIREVIEWS

- 10852** Hyperthermic intraperitoneal chemotherapy and colorectal cancer: From physiology to surgery
Ammerata G, Filippo R, Laface C, Memeo R, Solaini L, Cavaliere D, Navarra G, Ranieri G, Currò G, Ammendola M
- 10862** New-onset diabetes secondary to acute pancreatitis: An update
Yu XQ, Zhu Q
- 10867** Ketosis-prone diabetes mellitus: A phenotype that hospitalists need to understand
Boike S, Mir M, Rauf I, Jama AB, Sunesara S, Mushtaq H, Khedr A, Nitesh J, Surani S, Khan SA
- 10873** 2022 Monkeypox outbreak: Why is it a public health emergency of international concern? What can we do to control it?
Ren SY, Li J, Gao RD

ORIGINAL ARTICLE**Retrospective Cohort Study**

- 10882** Clinical characteristics and prognosis of non-small cell lung cancer patients with liver metastasis: A population-based study
Wang JF, Lu HD, Wang Y, Zhang R, Li X, Wang S

Retrospective Study

- 10896** Prevalence and risk factors for *Candida* esophagitis among human immunodeficiency virus-negative individuals
Chen YH, Jao TM, Shiue YL, Feng IJ, Hsu PI

- 10906** Prognostic impact of number of examined lymph nodes on survival of patients with appendiceal neuroendocrine tumors
Du R, Xiao JW

Observational Study

- 10921** Clinical and epidemiological features of ulcerative colitis patients in Sardinia, Italy: Results from a multicenter study
Magri S, Demurtas M, Onidi MF, Picchio M, Elisei W, Marzo M, Miculan F, Manca R, Dore MP, Quarta Colosso BM, Cicu A, Cugia L, Carta M, Binaghi L, Usai P, Lai M, Chicco F, Fantini MC, Armuzzi A, Mocci G

- 10931** Clinical observation of laparoscopic cholecystectomy combined with endoscopic retrograde cholangiopancreatography or common bile duct lithotripsy

Niu H, Liu F, Tian YB

Prospective Study

- 10939** Patient reported outcome measures in anterior cruciate ligament rupture and reconstruction: The significance of outcome score prediction

Al-Dadah O, Shepstone L, Donnell ST

SYSTEMATIC REVIEWS

- 10956** Body mass index and outcomes of patients with cardiogenic shock: A systematic review and meta-analysis

Tao WX, Qian GY, Li HD, Su F, Wang Z

META-ANALYSIS

- 10967** Impact of being underweight on peri-operative and post-operative outcomes of total knee or hip arthroplasty: A meta-analysis

Ma YP, Shen Q

- 10984** Branched-chain amino acids supplementation has beneficial effects on the progression of liver cirrhosis: A meta-analysis

Du JY, Shu L, Zhou YT, Zhang L

CASE REPORT

- 10997** Wells' syndrome possibly caused by hematologic malignancy, influenza vaccination or ibrutinib: A case report

Šajin M, Luzar B, Zver S

- 11004** Giant cutaneous squamous cell carcinoma of the popliteal fossa skin: A case report

Wang K, Li Z, Chao SW, Wu XW

- 11010** Right time to detect urine iodine during papillary thyroid carcinoma diagnosis and treatment: A case report

Zhang SC, Yan CJ, Li YF, Cui T, Shen MP, Zhang JX

- 11016** Two novel mutations in the *VPS33B* gene in a Chinese patient with arthrogryposis, renal dysfunction and cholestasis syndrome 1: A case report

Yang H, Lin SZ, Guan SH, Wang WQ, Li JY, Yang GD, Zhang SL

- 11023** Effect of electroacupuncture for Pisa syndrome in Parkinson's disease: A case report

Lu WJ, Fan JQ, Yan MY, Mukaeda K, Zhuang LX, Wang LL

- 11031** Neonatal Cri du chat syndrome with atypical facial appearance: A case report

Bai MM, Li W, Meng L, Sang YF, Cui YJ, Feng HY, Zong ZT, Zhang HB

- 11037** Complete colonic duplication presenting as hip fistula in an adult with pelvic malformation: A case report

Cai X, Bi JT, Zheng ZX, Liu YQ

- 11044** Autoimmune encephalitis with posterior reversible encephalopathy syndrome: A case report
Dai SJ, Yu QJ, Zhu XY, Shang QZ, Qu JB, Ai QL
- 11049** Hypophysitis induced by anti-programmed cell death protein 1 immunotherapy in non-small cell lung cancer: Three case reports
Zheng Y, Zhu CY, Lin J, Chen WS, Wang YJ, Fu HY, Zhao Q
- 11059** Different intraoperative decisions for undiagnosed paraganglioma: Two case reports
Kang D, Kim BE, Hong M, Kim J, Jeong S, Lee S
- 11066** Hepatic steatosis with mass effect: A case report
Hu N, Su SJ, Li JY, Zhao H, Liu SF, Wang LS, Gong RZ, Li CT
- 11074** Bone marrow metastatic neuroendocrine carcinoma with unknown primary site: A case report and review of the literature
Shi XB, Deng WX, Jin FX
- 11082** Child with adenylosuccinate lyase deficiency caused by a novel complex heterozygous mutation in the *ADSL* gene: A case report
Wang XC, Wang T, Liu RH, Jiang Y, Chen DD, Wang XY, Kong QX
- 11090** Recovery of brachial plexus injury after bronchopleural fistula closure surgery based on electrodiagnostic study: A case report and review of literature
Go YI, Kim DS, Kim GW, Won YH, Park SH, Ko MH, Seo JH
- 11101** Severe *Klebsiella pneumoniae* pneumonia complicated by acute intra-abdominal multiple arterial thrombosis and bacterial embolism: A case report
Bao XL, Tang N, Wang YZ
- 11111** Spontaneous bilateral femur neck fracture secondary to grand mal seizure: A case report
Senocak E
- 11116** Favorable response after radiation therapy for intraductal papillary mucinous neoplasms manifesting as acute recurrent pancreatitis: A case report
Harigai A, Kume K, Takahashi N, Omata S, Umezawa R, Jingu K, Masamune A
- 11122** Acute respiratory distress syndrome following multiple wasp stings treated with extracorporeal membrane oxygenation: A case report
Cai ZY, Xu BP, Zhang WH, Peng HW, Xu Q, Yu HB, Chu QG, Zhou SS
- 11128** Morphological and electrophysiological changes of retina after different light damage in three patients: Three case reports
Zhang X, Luo T, Mou YR, Jiang W, Wu Y, Liu H, Ren YM, Long P, Han F
- 11139** Perirectal epidermoid cyst in a patient with sacrococcygeal scoliosis and anal sinus: A case report
Ji ZX, Yan S, Gao XC, Lin LF, Li Q, Yao Q, Wang D

- 11146** Synchronous gastric cancer complicated with chronic myeloid leukemia (multiple primary cancers): A case report
Zhao YX, Yang Z, Ma LB, Dang JY, Wang HY
- 11155** Giant struma ovarii with pseudo-Meigs' syndrome and raised cancer antigen-125 levels: A case report
Liu Y, Tang GY, Liu L, Sun HM, Zhu HY
- 11162** Longest survival with primary intracranial malignant melanoma: A case report and literature review
Wong TF, Chen YS, Zhang XH, Hu WM, Zhang XS, Lv YC, Huang DC, Deng ML, Chen ZP
- 11172** Spontaneous remission of hepatic myelopathy in a patient with alcoholic cirrhosis: A case report
Chang CY, Liu C, Duan FF, Zhai H, Song SS, Yang S
- 11178** Cauda equina syndrome caused by the application of DuraSeal™ in a microlaminectomy surgery: A case report
Yeh KL, Wu SH, Fuh CS, Huang YH, Chen CS, Wu SS
- 11185** Bioceramics utilization for the repair of internal resorption of the root: A case report
Riyahi AM
- 11190** Fibrous hamartoma of infancy with bone destruction of the tibia: A case report
Qiao YJ, Yang WB, Chang YF, Zhang HQ, Yu XY, Zhou SH, Yang YY, Zhang LD
- 11198** Accidental esophageal intubation *via* a large type C congenital tracheoesophageal fistula: A case report
Hwang SM, Kim MJ, Kim S, Kim S
- 11204** Ventral hernia after high-intensity focused ultrasound ablation for uterine fibroids treatment: A case report
Park JW, Choi HY

LETTER TO THE EDITOR

- 11210** C-Reactive protein role in assessing COVID-19 deceased geriatrics and survivors of severe and critical illness
Nori W

ABOUT COVER

Editorial Board Member of *World Journal of Clinical Cases*, Rajeev Gurunath Redkar, FRCS, FRCS (Ed), FRCS (Gen Surg), MBBS, MCh, MS, Dean, Professor, Surgeon, Department of Pediatric Surgery, Lilavati Hospital and Research Centre, Mumbai 400050, Maharashtra, India. rajeev.redkar@gmail.com

AIMS AND SCOPE

The primary aim of *World Journal of Clinical Cases (WJCC, World J Clin Cases)* is to provide scholars and readers from various fields of clinical medicine with a platform to publish high-quality clinical research articles and communicate their research findings online.

WJCC mainly publishes articles reporting research results and findings obtained in the field of clinical medicine and covering a wide range of topics, including case control studies, retrospective cohort studies, retrospective studies, clinical trials studies, observational studies, prospective studies, randomized controlled trials, randomized clinical trials, systematic reviews, meta-analysis, and case reports.

INDEXING/ABSTRACTING

The *WJCC* is now abstracted and indexed in Science Citation Index Expanded (SCIE, also known as SciSearch®), Journal Citation Reports/Science Edition, Current Contents®/Clinical Medicine, PubMed, PubMed Central, Scopus, Reference Citation Analysis, China National Knowledge Infrastructure, China Science and Technology Journal Database, and Superstar Journals Database. The 2022 Edition of Journal Citation Reports® cites the 2021 impact factor (IF) for *WJCC* as 1.534; IF without journal self cites: 1.491; 5-year IF: 1.599; Journal Citation Indicator: 0.28; Ranking: 135 among 172 journals in medicine, general and internal; and Quartile category: Q4. The *WJCC*'s CiteScore for 2021 is 1.2 and Scopus CiteScore rank 2021: General Medicine is 443/826.

RESPONSIBLE EDITORS FOR THIS ISSUE

Production Editor: *Ying-Yi Yuan*; Production Department Director: *Xu Guo*; Editorial Office Director: *Jin-Lei Wang*.

NAME OF JOURNAL

World Journal of Clinical Cases

ISSN

ISSN 2307-8960 (online)

LAUNCH DATE

April 16, 2013

FREQUENCY

Thrice Monthly

EDITORS-IN-CHIEF

Bao-Gan Peng, Jerzy Tadeusz Chudek, George Kontogeorgos, Maurizio Serati, Ja Hyeon Ku

EDITORIAL BOARD MEMBERS

<https://www.wjgnet.com/2307-8960/editorialboard.htm>

PUBLICATION DATE

October 26, 2022

COPYRIGHT

© 2022 Baishideng Publishing Group Inc

INSTRUCTIONS TO AUTHORS

<https://www.wjgnet.com/bpg/gerinfo/204>

GUIDELINES FOR ETHICS DOCUMENTS

<https://www.wjgnet.com/bpg/GerInfo/287>

GUIDELINES FOR NON-NATIVE SPEAKERS OF ENGLISH

<https://www.wjgnet.com/bpg/gerinfo/240>

PUBLICATION ETHICS

<https://www.wjgnet.com/bpg/GerInfo/288>

PUBLICATION MISCONDUCT

<https://www.wjgnet.com/bpg/gerinfo/208>

ARTICLE PROCESSING CHARGE

<https://www.wjgnet.com/bpg/gerinfo/242>

STEPS FOR SUBMITTING MANUSCRIPTS

<https://www.wjgnet.com/bpg/GerInfo/239>

ONLINE SUBMISSION

<https://www.f6publishing.com>

Hyperthermic intraperitoneal chemotherapy and colorectal cancer: From physiology to surgery

Giorgio Ammerata, Rosalinda Filippo, Carmelo Laface, Riccardo Memeo, Leonardo Solaini, Davide Cavaliere, Giuseppe Navarra, Girolamo Ranieri, Giuseppe Currò, Michele Ammendola

Specialty type: Surgery

Provenance and peer review:

Unsolicited article; Externally peer reviewed.

Peer-review model: Single blind

Peer-review report's scientific quality classification

Grade A (Excellent): 0
Grade B (Very good): B
Grade C (Good): C
Grade D (Fair): D
Grade E (Poor): 0

P-Reviewer: Ding L, China; Farouk S, Egypt; Serban ED, Romania

Received: January 13, 2022

Peer-review started: January 13, 2022

First decision: June 15, 2022

Revised: June 23, 2022

Accepted: August 13, 2022

Article in press: August 13, 2022

Published online: October 26, 2022



Giorgio Ammerata, Rosalinda Filippo, Giuseppe Currò, Michele Ammendola, Science of Health Department, Digestive Surgery Unit, University “Magna Graecia” Medical School, Catanzaro 88100, Italy

Carmelo Laface, Girolamo Ranieri, Interventional Oncology Unit with Integrated Section of Translational Medical Oncology, National Cancer Research Centre “Giovanni Paolo II”, Bari 70124, Italy

Riccardo Memeo, Hepato-Biliary and Pancreatic Surgical Unit, “F. Miulli” Hospital, Acquaviva delle Fonti, Bari 70124, Italy

Leonardo Solaini, Department of Medical and Surgical Sciences, University of Bologna, Forlì 40126, Italy

Davide Cavaliere, Department of General and Oncologic Surgery, Morgagni-Pierantoni Hospital, Forlì 47121, Italy

Giuseppe Navarra, Department of Human Pathology of Adult and Evolutive Age, Surgical Oncology Division, “G. Martino” Hospital, University of Messina, Messina 98122, Italy

Corresponding author: Michele Ammendola, MD, PhD, Professor, Science of Health Department, Digestive Surgery Unit, University “Magna Graecia” Medical School, Viale Europa, Germaneto, Catanzaro 88100, Italy. michele.ammendola@unicz.it

Abstract

The pursuit of this paper is to collect principal reviews and systematic reviews about hyperthermic intraperitoneal chemotherapy (HIPEC) and cytoreductive surgery (CRS) used in colorectal cancer (CRC). We focus on principal biological aspects of CRC, hyperthermia effects, and surgical procedures. We searched PubMed/MEDLINE for the principal reviews and systematic reviews published from 2010 to 2021 regarding the bimodal treatment (CRS + HIPEC) against local and advanced CRC. In the literature, from several studies, it seems that the efficacy of bimodal treatment with an accurate CRS can extend overall survival. Despite these studies, there are not still any straight guidelines more detailed and scheduled about the use of combined treatment in patients with CRC. Even if the concept is still not very clear and shared, after a careful evaluation of the published data, and after some technical and pathophysiological descriptions, we concluded that it is possible to improve the overall survival and quality of life and

to reduce the tumor relapse in patients affected by locally advanced (pT4) CRC with peritoneal metastases.

Key Words: Hyperthermic intraperitoneal chemotherapy; Colorectal cancer; Peritoneum; Cytoreductive surgery

©The Author(s) 2022. Published by Baishideng Publishing Group Inc. All rights reserved.

Core Tip: The purpose of this review is to summarize the most relevant evidence on the use of hyperthermic intraperitoneal chemotherapy (HIPEC) in colorectal cancer and to specify the main properties of HIPEC and its application.

Citation: Ammerata G, Filippo R, Laface C, Memeo R, Solaini L, Cavaliere D, Navarra G, Ranieri G, Currò G, Ammendola M. Hyperthermic intraperitoneal chemotherapy and colorectal cancer: From physiology to surgery. *World J Clin Cases* 2022; 10(30): 10852-10861

URL: <https://www.wjgnet.com/2307-8960/full/v10/i30/10852.htm>

DOI: <https://dx.doi.org/10.12998/wjcc.v10.i30.10852>

INTRODUCTION

The synergistic anti-tumor effects of heat and intraperitoneal chemotherapy, have been known to be effective since decades and is now well known as hyperthermic intraperitoneal chemotherapy (HIPEC); this strategy is based on both hyperthermia and high intraperitoneal concentration of chemotherapy (IP).

Originally, hyperthermia was introduced by Spratt *et al*[1] who demonstrated the benefit of heated IP perfusion in canine models; furthermore, the first prototype IP therapy filtration system was designed and tested by Palta *et al*[2].

HIPEC is based on the physiological effect of the "peritoneal-plasma barrier": While peritoneal surface malignancies (PSM) cannot be effectively reached by intravenous chemotherapy[3], these tumors can benefit from intraperitoneal administration of high-dose cytotoxic drugs in direct contact with tumor cells, combining the effect of hyperthermia and minimizing the systemic toxic effects of drug reabsorption.

The first use of HIPEC was described in 1979 for the treatment of recurrent peritoneal pseudomyxoma (PMP) after previous cytoreductive surgery (CRS)[4]; subsequently, Sugarbaker *et al*[5,6] compared the use of 5-fluorouracil IP with systemic therapy for colorectal cancer (CRC) and appendiceal cancer to show the benefits of IP therapy[7-10]. During the years, HIPEC became a new option of care for different tumors with peritoneal metastases (PMs): CRC, appendiceal cancer, ovarian cancer (OC), gastric cancer (GC), and peritoneal mesothelioma[11,12].

Later, HIPEC was also applied in the treatment of PSM from GC and OC: In 1988, Fujimoto *et al*[9] reported the effects of HIPEC in patients with PMs from GC and in 1996, Yonemura *et al*[13] showed a 5-year survival of 11% in a cohort of 83 patients who underwent CRS and HIPEC for GC; moreover, in 1989, HIPEC was used for peritoneal lesions from OC[14].

Since the 1990s, CRS combined with HIPEC has been a treatment option for PSM; today, CRS and HIPEC represent the standard of care for PMP and peritoneal mesothelioma[15]. In particular, regarding the combination of CRS plus HIPEC in CRC, there were several clinical trials about this specific combined treatment; nevertheless, this option of treatment remains a debated topic. Ceelen[16] first described the efficacy of CRS + HIPEC in peritoneal carcinomatosis arising from CRC. Later, numerous studies have been conducted until nowadays, reaching a better use of the bimodal treatment. For instance, Birgisson *et al*[17] studied the use of the peritoneal cancer index (PCI) as a prognostic factor in patients affected by PMs from CRC and treated with CRS + HIPEC.

Rosa *et al*[18] showed the clinical outcomes in 67 patients affected by CRC, focusing on the complete cytoreduction of PMs and calculating the median overall and disease-free survival.

Moreover, Elias *et al*[19] showed the results of HIPEC plus second look surgery in selected patients, increasing their 5-year overall survival to 90%.

However, despite several studies on this topic, there is still no consensus on the indication of CRS combined with HIPEC in CRC.

The purpose of this review is to summarize the most relevant evidence on the use of HIPEC in CRC and to specify the main properties of HIPEC and its application.

MATERIAL AND METHODS

In this narrative review, we searched PubMed, a free online biomedical database developed by the National Center for Biotechnology Information at the National Library of Medicine, using the following keywords: “Colorectal Tumor” and “HIPEC”, “Colorectal Cancer” and “HIPEC”, “HIPEC”, “Hyperthermic Intraperitoneal Chemotherapy”, “Hyperthermia and HSPs”, “Hyperthermia and Tumor”, and “Hyperthermia and Cancer” (Figure 1). We collected the reviews and systematic reviews published from 2010 to 2021 and analyzed the principal clinical studies about the management of PMs arising from CRC (Table 1; Figure 2). This current work focuses the attention on HIPEC, from its first uses to now, looking at principal uses in different tumors like gastric, ovarian, and colorectal. Moreover, the review explains in detail the biologic effects of HIPEC on tumoral cells and the latest clinical trials regarding locally advanced colorectal cancer by describing CRS technique step by step.

HIPEC AND CRC

CRC is a big killer, representing the third most commonly diagnosed malignancy worldwide; it represents the third most common cancer in men (746000 cases; 10 % of the total) and the second in women (614000 cases; 9.2 % of the total)[20]. Surgery represents the elective therapy for resectable CRC (to gain R0 resection); instead, chemotherapy, radiotherapy, and the combination of both have indications for neoadjuvant and adjuvant purposes[21].

CRC most frequently metastasizes to the liver and peritoneum. PMs from CRC are tumoral deposits on the peritoneal surface, originating from the primitive cancer. PMs originated from CRC can cause several and severe complications like bowel and ureteral obstruction, and malignant ascites[22-24].

There are a variety of chemohyperthermia protocols in the literature, but in general they consist of intraperitoneal infusion of different drugs at a particular range of temperature and pressure for a definite time at the end of surgery to eradicate the residual microscopic tumor tissue[25,26].

Today, HIPEC after CRS is still considered an investigational treatment for CRC-originated PMs, but its role is not yet defined.

HIPEC AND PHYSIOLOGICAL MECHANISM

HIPEC for PMs from CRC has some technical specific parameters like temperature, drugs, and pressure.

Mitomycin-C (MMC) is administered as monotherapy in a large majority of protocols[11,27-29] or in combination with cisplatin[30-34]. The second most commonly used drug in monotherapy is oxaliplatin or also in combination with irinotecan. MMC gives higher efficacy as a single agent administered at a dose of 35 mg/m²[35-40], although the dose of MMC can be modified from 10 to 40 mg/m²[41].

Establishing the drug dose is the cornerstone for even distribution of chemotherapy; some institutions use an approach called body surface area-based and others use a concentration-based approach. These approaches have some limitations such as gender and the presence of malignant ascites, but both attempt to find a conventional dose[42].

High temperature is a key issue; there are three temperature ranges that classify the type of hyperthermia: Fever hyperthermia (39-40 °C), mild hyperthermia (heat shock temperature 41-43 °C), and thermal ablation (cytotoxic temperature, > 43 °C).

Focusing attention on biological aspects, it is necessary to discuss about hyperthermia effects on tumor tissue. Hyperthermia has an important role in different paths like apoptosis regulation, neoangiogenesis, and immune status of the tumor. For example, hyperthermia induces DNA damage response by activating single strand break, double strand break, histone H₂AX with phosphorylated C-terminal serine (γ-H₂AX) site formation, and ataxia-telangiectasia mutated protein phosphorylation, and by decreasing DNA replication and repair.

Indirectly, hyperthermia activates DNA damage response and induces tumor suppressor alternative reading frame by starting reactive oxygen species (ROS) production, cell cycle arrest, cell cycle checkpoint arrest, and cell death; in addition, hyperthermia decelerates DNA replication.

Hyperthermia can also damage cancer stem cells exceeding conventional therapeutic regimens, so it is used in combination with chemotherapy or radiation to result in non-reversible damage to tumor cellular DNA[43].

Specifically, fever range hyperthermia can alter cell membrane fluidity and stability, changing cell shape and affecting intracellular sodium-calcium levels[44]; moreover, it recruits heat shock proteins (HSPs) and endoplasmic reticulum (ER) stress (type II) at the same time[45].

ER stress and ROS (type I) activate immunogenic cell death (ICD) and promote, through specific signals “eat me” and “enabler”, the recruitment of immune cells. Definitively, hyperthermia can be considered an inducer of ICD and a powerful change of tumor microenvironment (TME)[46-48].

Table 1 List of clinical studies with phases, correlated institutions and principal investigators (Clinicaltrials.gov or clinicaltrialsregister.eu; the list below describes the brief titles of the ended clinical trials)

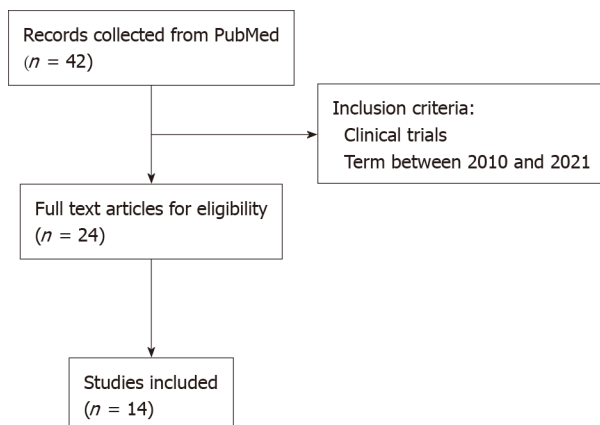
Phase	Institution/Group	Country	Author/ClinicalTrials.gov ID	Year beginning
II	Fudan University	China	Guoxiang Cai/NCT02965248	November 2016
III	Zhejiang University	China	Ding Ke-Feng/NCT02179489	October 2014
II	Wuhan University	China	Bin Xiong/NCT02830139 ¹	July 2016
II/III	Catharina, Ziekenhuis, Eindhoven	Netherlands	Koen Rovers/NCT02758951	June 2017
III	Academisch Medisch Centrum-Universiteit van Amsterdam	Netherlands	P.J. Tanis/NCT02231086	March 2015
III	Universitair Medisch Centrum Groningen	Netherlands	NACHO trial /2010-020787-37	January 2013
II	University Hospital, Ghent	Belgium	Wim P Ceelen/NCT02399410	December 2015
II	University Hospital, Ghent	Belgium	Trial Bureau/2012-000701-77 ²	May 2012
II	University Hospital, Ghent	Belgium	Bimetra Clinics/2014-000882-34 ³	June 2014
III	Gustav Roussy, Cancer Campus, Grand Paris	France	Diane GOERE/NCT01226394	April 2010
I/II	Hospices Civils de Lyon	France	Benoit You/NCT02866903 ⁴	May 2017
III	UNICANCER	France/Spain	BEATA JUZYNA/2006-006175-20	December 2012
III	University of Roma La Sapienza	Italy	P.Sammartino/NCT02974556	March 2019
III	Maimonides Biomedical Research Institute of Cordoba	Spain	Alvaro Arjona Sanchez /NCT02614534	November 2015

¹Radical colorectal resection and hyperthermic intraperitoneal chemotherapy in locally advanced colorectal cancer.

²Cytoreduction followed by normothermic *vs* hyperthermic intraperitoneal intraoperative chemoperfusion: A phase II study in peritoneal carcinomatosis.

³Catheter based adjuvant intraperitoneal chemotherapy for carcinomatosis.

⁴IPOXA, phase I/II dose escalation trial aiming to evaluate the safety of intraperitoneal oxaliplatin in association with systemic FOLFIRI bevacizumab chemotherapy in patients with peritoneal carcinosis of colorectal origin and uncertain resectability.



DOI: 10.12998/wjcc.v10.i30.10852 Copyright ©The Author(s) 2022.

Figure 1 Flowchart of all studies found in PubMed search.

A range of heat shock temperature recruits different molecules like L-selectin, P-selectin, and intracellular cell adhesion molecule-1 in the vessel wall, and causes the production of pro-inflammatory cytokines and chemokines [interleukin (IL)-1 β , IL-6, IL-8, IL-10, and C-C class chemokines 22][49-52]. These cytokines “storm” facilitates the infiltration of lymphocytes in the TME and triggers an immune cascade against solid tumor.

Many HSPs are expressed on the surface of different types of solid and haematological tumors, a high concentration of mHSPs is associated with tumor progression and resistance to anti-tumor therapies, but under stress (for example anoxia and hyperthermia), HSPs can modify their relationship with tumor. Hyperthermia, in this sense, becomes an inducer of HSPs; it rapidly regulates different heat shock factors in tumor cells and activates HSPs, and in particular leads the translocation of HSPs to the

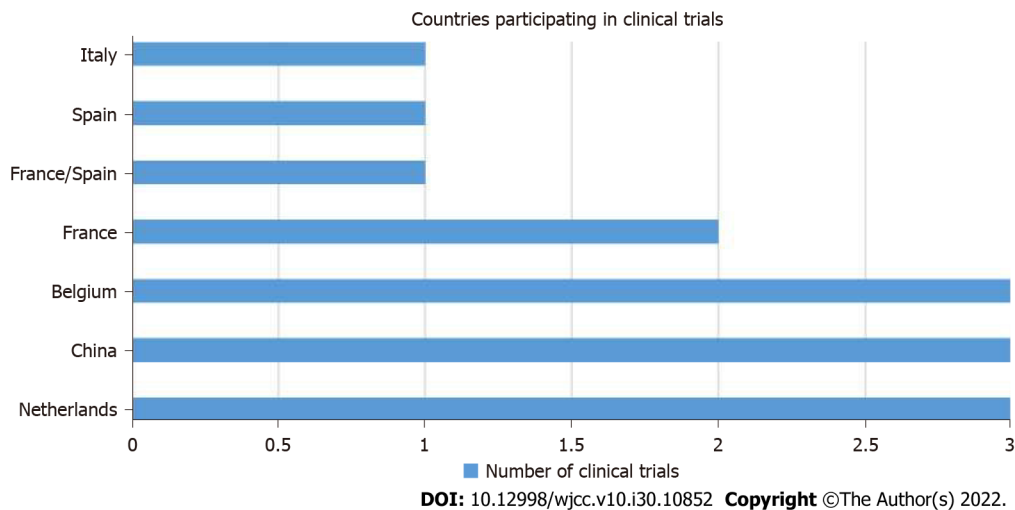


Figure 2 Countries participating in clinical trials.

nucleus and their synthesis by an autocrine loop[53].

HSPs constitute a large family of proteins, acting as molecular chaperones; they reside in three intracellular compartments such as the cytosol, nucleus, and plasma membrane or in the extracellular space. For example, HSP70, localized on the plasma membrane of tumor cells in CRC[54], facilitates cross-presentation of antigenic peptides *via* major histocompatibility complex class I molecules and determines the consecutive induction of a CD8⁺T cell-mediated immune response. CD8⁺T cell differentiation and their cytotoxicity against pathogens are both temperature sensitive, in fact hyperthermia can promote antigen-specific naïve CD8⁺T cell differentiation and increase cytotoxic potential of T cells and memory stem T cell generation. Moreover, chaperones of HSP70 family can activate the proliferation of natural killer cells even without immunogenic peptides[55].

There is no univocal standard on the temperature to be used during HIPEC: A range from 38.5 °C to 44 °C is reported in the abdomen with an average value that is usually considered close to 42 °C. However, it is essential that the temperature does not exceed thermal ablation to avoid systemic toxic effects.

CRS: STEP BY STEP

CRS has a curative intent and consists of a complex series of steps, aiming to achieve a radical visceral and parietal peritonectomy to eliminate the macroscopic visible tumor nodules, leaving a most microscopic residual tumor tissue. It is important to consider cancer histopathology, radiological imaging, and PCI to plan the best surgery[56-58].

The patient is placed in the lithotomic position, supine with legs extended and laid on St. Mark's holders and arms beneath the torso.

The tools used in CRS are based on electrosurgery and electro-evaporation, specifically it is usual to use ball-tipped electrosurgical handpiece to minimize blood lost.

The median incision is the from the xiphi-sternal junction to the pubis; at this point, if tumor nodules are visible, the surgeon can start with parietal peritonectomy or rather separating parietal peritoneum from the inferior surface of the anterior abdominal wall. The dissection of visceral peritoneum starts generally from bottom to top.

Omentectomy is often necessary and sometimes mandatory in order to better explore the peritoneal cavity.

CRS continues with dissection of the left hypochondrium: We start by dissecting the peritoneum behind the rectus muscle to the left diaphragmatic dome and mobilizing the left colic flexure, thus exposing the diaphragm with its vessels and exposing the spleen, which can be removed, if it is infiltrated by neoplastic tissue.

The approach to the right side is mirrored by the contralateral; it is essential to totally mobilize the liver from its peritoneal attachment, particularly the right and left triangular ligament, the falciform ligament, and the teres hepatic ligament; sometimes, the Glisson's capsule must be fulgurated if cancerous deposits are present.

As for the small intestine and its mesentery, it is important to free them and completely inspect them because if they are involved by the tumor, the surgeon will remove the affected part. The colon is another elective situs of peritoneal carcinomatosis, particularly the fusion layer between the parietal and visceral peritoneum of the right colon. Sometimes, it is necessary to proceed to partial or total

colectomy.

The pelvic peritonectomy is another important step in CRS. Two anatomic structures represent the polar star in this part of pelvic dissection: Posteriorly the ureters and anteriorly the muscular portion of bladder. The right and left ureters are identified and preserved, in the woman the ovarian vessels are ligated at the lower pole of the kidney, otherwise in men, the testicular vessels are avoided from the surgical field. After these procedures, it is usual to execute in woman hysterectomy with colic resection and in men an anterior resection of the rectum. If there are some visceral resection, the surgeon will restore intestinal functions with anastomoses or stomas[59].

PROTOCOLS OF HIPEC FOR CRC

Nowadays there are two attitudes to execute HIPEC: In closed or in open abdominal cavity (also defined coliseum technique)[60,61].

Close technique implies the insertion of two inflow drains under the left and right diaphragmatic cupola and an outflow drain in the pouch of Douglas. Temperature probes are also inserted within the abdominal cavity (behind the liver pedicle and near the first jejunal loop). Other temperature probes are set up outside the abdominal cavity on the inflow and outflow drains and inside the bladder within a Foley catheter. As a final step, there is a closure of laparotomy incision and the inflow and outflow drains are connected to a closed sterile circuit. Also, in this case there is no specific evidence that suggests which technique is better than other, and probably closed technique reduces risks of exposure of drugs to the personnel[62].

The intraperitoneal chemotherapy after cytoreductive surgery trial compared the benefit of HIPEC with early, postoperative, normothermic IP chemotherapy (EPIC) in patients affected by colorectal cancer and undergoing optimal CRS.

Enrolment began in March 2013 with completion date of March 2018 at Memorial Sloan Kettering Cancer Center and was given MMC in HIPEC and floxuridine in IPEC.

The outcome measure of the study is disease-free survival, within 3 years, though secondary measures were used to monitor surgical and chemotherapy-related toxicities up to 60 d postoperatively [63].

The PRODIGE7 study, a randomized, multicentre, phase III trial at the Institut di Cancer Val d' Aurelle (Montpellier, France), started to evaluate the benefit of HIPEC to complete CRS.

The recruitment of 270 patients with CRC and limited peritoneal dissemination was completed in 2013. Patients undergoing CRS were randomized intraoperatively to receive HIPEC or saline lavage only. In this study, oxaliplatin (460 mg/m²) in 2 L/m² of dextrose 5% over 30 min at a temperature of 42 °C was used. One hour before the HIPEC, 20 mg/m² of leucovorin and 400 mg/m² of 5-fluorouracil were given intravenously in the HIPEC arm[64].

The CAIRO-6 study, similarly to the previous study, focused on the role of perioperative systemic therapy on survival in patients undergoing CRS and HIPEC for CRC. This phase II/III study randomized patients to undergo neoadjuvant therapy intravenously with 5-fluorouracil, leucovorin, and oxaliplatin (FOLFOX) or capecitabine and oxaliplatin (CAPOX) with bevacizumab followed by CRS and HIPEC, then adjuvant systemic therapy with FOLFOX and CAPOX[65].

The control arm is represented by CRS and HIPEC only. Both the studies confirm the importance of full CRS in patients that received systemic chemotherapy.

The ProphylloCHIP-PRODIGE 15 (France) study started the recruitment of 150 patients in 2010. This is a multicentre, randomized, phase III study to demonstrate the role of HIPEC as a prophylactic measure in initial treatment and in the adjuvant setting in patients with high risk of developing colorectal peritoneal metastases[66].

The COLOPEC (Netherlands) study, enrolled 204 patients, aged from 18 to 75 years, between 2014 and 2017. The patients had CRC at T₄N₀₋₂M₀ stage, and the treatment consisted of intravenous injection of fluorouracil (400 mg/m²) and leucovorin (20 mg/m²), then, during the surgery, the use of oxaliplatin (460 mg/m²) for 30 min. COLOPEC demonstrated an absolute risk reduction of 15% in PMs[67].

CONCLUSION

In CRCs, PMs are underestimated and they are correlated with a poor prognosis. Despite the fact that the secondary localizations of tumor are visible in the chest or in the liver, during the execution of full-body computed tomography for tumor staging, PMs cannot be identified easily. Moreover, a failed treatment of PMs determines a median survival of 5 mo; on the contrary, a palliative systematic therapy increases the median survival from 5 to 15 mo. Unfortunately, the survival remains worse in respect to non-peritoneal metastases.

Furthermore, CRC affects in higher percentage the young ages, so it becomes necessary to discuss about a protocol of treatment to prevent the principal complications (malignant ascites and obstruction) of colorectal tumors, eliminate macroscopic malignancies on peritoneal surface, and increase the median

survival.

In light of the main studies collected regarding CRS plus HIPEC in CRC, it is still no very clear and shared the indications and technique used in PMs arising from CRC.

However, looking at the clinical trials and physiologic principles, CRS (open or laparoscopic) plus HIPEC can be a valid treatment especially in young patients (< 50 years) affected by locally advanced (pT4) CRC with PMs. In this way, it is possible to improve the overall survival and quality of life and reduce the tumor relapse.

ACKNOWLEDGEMENTS

This work was supported by Dr. Thom Douglas for the English language review.

FOOTNOTES

Author contributions: Ammerata G and Ammendola M contributed to the study design; Filippo R, Memeo R, Laface C, and Solaini L contributed to the data collection and statistical analysis; Cavaliere D and Navarra G contributed to drafting and revising the manuscript critically; Ranieri G, Currò G, and Ammendola M contributed to the final approval of the version submitted.

Conflict-of-interest statement: The authors have nothing to disclose.

Open-Access: This article is an open-access article that was selected by an in-house editor and fully peer-reviewed by external reviewers. It is distributed in accordance with the Creative Commons Attribution NonCommercial (CC BY-NC 4.0) license, which permits others to distribute, remix, adapt, build upon this work non-commercially, and license their derivative works on different terms, provided the original work is properly cited and the use is non-commercial. See: <https://creativecommons.org/licenses/by-nc/4.0/>

Country/Territory of origin: Italy

ORCID number: Giorgio Ammerata 0000-0001-5485-5221; Rosalinda Filippo 0000-0002-9254-8131; Carmelo Laface 0000-0002-5074-4951; Riccardo Memeo 0000-0002-1668-932X; Leonardo Solaini 0000-0002-5031-9285; Davide Cavaliere 0000-0001-8971-5704; Giuseppe Navarra 0000-0003-0372-1615; Girolamo Ranieri 0000-0002-7952-694X; Giuseppe Currò 0000-0001-9566-1378; Michele Ammendola 0000-0001-8043-6100.

S-Editor: Zhang H

L-Editor: Wang TQ

P-Editor: Zhang H

REFERENCES

- 1 **Spratt JS**, Adcock RA, Sherrill W, Travathen S. Hyperthermic peritoneal perfusion system in canines. *Cancer Res* 1980; **40**: 253-255 [PMID: 7356508]
- 2 **Palta JR**. Design and Testing of a Therapeutic Infusion Filtration System. Columbia: University of Missouri, 1977
- 3 **Jacquet P**, Sugarbaker PH. Peritoneal-plasma barrier. *Cancer Treat Res* 1996; **82**: 53-63 [PMID: 8849943 DOI: 10.1007/978-1-4613-1247-5_4]
- 4 **Spratt JS**, Adcock RA, Muskovin M, Sherrill W, McKeown J. Clinical delivery system for intraperitoneal hyperthermic chemotherapy. *Cancer Res* 1980; **40**: 256-260 [PMID: 6766084]
- 5 **Sugarbaker PH**, Gianola FJ, Speyer JC, Wesley R, Barofsky I, Meyers CE. Prospective, randomized trial of intravenous versus intraperitoneal 5-fluorouracil in patients with advanced primary colon or rectal cancer. *Surgery* 1985; **98**: 414-422 [PMID: 3898450]
- 6 **Sugarbaker PH**. Treatment of peritoneal carcinomatosis from colon or appendiceal cancer with induction intraperitoneal chemotherapy. *Cancer Treat Res* 1996; **82**: 317-325 [PMID: 8849959 DOI: 10.1007/978-1-4613-1247-5_20]
- 7 **Koga S**, Hamazoe R, Maeta M, Shimizu N, Kanayama H, Osaki Y. Treatment of implanted peritoneal cancer in rats by continuous hyperthermic peritoneal perfusion in combination with an anticancer drug. *Cancer Res* 1984; **44**: 1840-1842 [PMID: 6424932]
- 8 **Koga S**. [Prophylactic and therapeutic continuous hyperthermic peritoneal perfusion for peritoneal metastases of gastric cancer]. *Gan No Rinsho* 1985; **31**: 1103-1105 [PMID: 3932711]
- 9 **Fujimoto S**, Shrestha RD, Kokubun M, Ohta M, Takahashi M, Kobayashi K, Kiuchi S, Okui K, Miyoshi T, Arimizu N. Intraperitoneal hyperthermic perfusion combined with surgery effective for gastric cancer patients with peritoneal seeding. *Ann Surg* 1988; **208**: 36-41 [PMID: 3133994 DOI: 10.1097/0000658-198807000-00005]
- 10 **Toi M**, Shiramizu T, Yonemura T, Ezaki T, Oka N, Yoshida T, Tsurumaru H. [Intraperitoneal cisplatin in peritoneal carcinomatosis patients]. *Gan No Rinsho* 1985; **31**: 522-526 [PMID: 4040582]
- 11 **Verwaal VJ**, van Ruth S, de Bree E, van Sloothen GW, van Tinteren H, Boot H, Zoetmulder FA. Randomized trial of

- cytoreduction and hyperthermic intraperitoneal chemotherapy versus systemic chemotherapy and palliative surgery in patients with peritoneal carcinomatosis of colorectal cancer. *J Clin Oncol* 2003; **21**: 3737-3743 [PMID: 14551293 DOI: 10.1200/JCO.2003.04.187]
- 12 **National Comprehensive Cancer Network.** Clinical Practice Guidelines in Oncology (NCCN Guidelines). Colon Cancer. Version 2. 2016. Available from: <https://www2.tri-kobe.org/nccn/guideline/archive/colorectal2016/english/colon.pdf>
 - 13 **Yonemura Y,** Fujimura T, Nishimura G, Falla R, Sawa T, Katayama K, Tsugawa K, Fushida S, Miyazaki I, Tanaka M, Endou Y, Sasaki T. Effects of intraoperative chemohyperthermia in patients with gastric cancer with peritoneal dissemination. *Surgery* 1996; **119**: 437-444 [PMID: 8644010 DOI: 10.1016/s0039-6060(96)80145-0]
 - 14 **Tsuyoshi H,** Inoue D, Kurokawa T, Yoshida Y. Hyperthermic intraperitoneal chemotherapy (HIPEC) for gynecological cancer. *J Obstet Gynaecol Res* 2020; **46**: 1661-1671 [PMID: 32715605 DOI: 10.1111/jog.14391]
 - 15 **Morano WF,** Aggarwal A, Love P, Richard SD, Esquivel J, Bowne WB. Intraperitoneal immunotherapy: historical perspectives and modern therapy. *Cancer Gene Ther* 2016; **23**: 373-381 [PMID: 27834358 DOI: 10.1038/cgt.2016.49]
 - 16 **Ceelen WP.** Use of hyperthermic intraperitoneal chemotherapy (HIPEC) in management of peritoneal carcinomatosis from colorectal origin. *Surg Technol Int* 2005; **14**: 125-130 [PMID: 16525964]
 - 17 **Birgisson H,** Enblad M, Artursson S, Ghanipour L, Cashin P, Graf W. Patients with colorectal peritoneal metastases and high peritoneal cancer index may benefit from cytoreductive surgery and hyperthermic intraperitoneal chemotherapy. *Eur J Surg Oncol* 2020; **46**: 2283-2291 [PMID: 32873455 DOI: 10.1016/j.ejso.2020.07.039]
 - 18 **Rosa F,** Galiandro F, Ricci R, Di Miceli D, Quero G, Fiorillo C, Cina C, Alfieri S. Cytoreductive surgery and hyperthermic intraperitoneal chemotherapy (HIPEC) for colorectal peritoneal metastases: analysis of short- and long-term outcomes. *Langenbecks Arch Surg* 2021; **406**: 2797-2805 [PMID: 34661754 DOI: 10.1007/s00423-021-02353-z]
 - 19 **Elias D,** Honoré C, Dumont F, Ducreux M, Boige V, Malka D, Burtin P, Dromain C, Goéré D. Results of systematic second-look surgery plus HIPEC in asymptomatic patients presenting a high risk of developing colorectal peritoneal carcinomatosis. *Ann Surg* 2011; **254**: 289-293 [PMID: 21709543 DOI: 10.1097/SLA.0b013e31822638f6]
 - 20 **Ferlay J,** Soerjomataram I, Dikshit R, Eser S, Mathers C, Rebelo M, Parkin DM, Forman D, Bray F. Cancer incidence and mortality worldwide: sources, methods and major patterns in GLOBOCAN 2012. *Int J Cancer* 2015; **136**: E359-E386 [PMID: 25220842 DOI: 10.1002/ijc.29210]
 - 21 **Benson AB,** Venook AP, Al-Hawary MM, Cederquist L, Chen YJ, Ciombor KK, Cohen S, Cooper HS, Deming D, Engstrom PF, Garrido-Laguna I, Grem JL, Grothey A, Hochster HS, Hoffe S, Hunt S, Kamel A, Kirilcuk N, Krishnamurthi S, Messersmith WA, Meyerhardt J, Miller ED, Mulcahy MF, Murphy JD, Nurkin S, Saltz L, Sharma S, Shibata D, Skibber JM, Sofocleous CT, Stoffel EM, Stotsky-Himelfarb E, Willett CG, Wuthrick E, Gregory KM, Freedman-Cass DA. NCCN Guidelines Insights: Colon Cancer, Version 2.2018. *J Natl Compr Canc Netw* 2018; **16**: 359-369 [PMID: 29632055 DOI: 10.6004/jnccn.2018.0021]
 - 22 **Hess KR,** Varadhachary GR, Taylor SH, Wei W, Raber MN, Lenzi R, Abbruzzese JL. Metastatic patterns in adenocarcinoma. *Cancer* 2006; **106**: 1624-1633 [PMID: 16518827 DOI: 10.1002/cncr.21778]
 - 23 **Hugen N,** van de Velde CJH, de Wilt JHW, Nagtegaal ID. Metastatic pattern in colorectal cancer is strongly influenced by histological subtype. *Ann Oncol* 2014; **25**: 651-657 [PMID: 24504447 DOI: 10.1093/annonc/mdt591]
 - 24 **Hennessy BT,** Coleman RL, Markman M. Ovarian cancer. *Lancet* 2009; **374**: 1371-1382 [PMID: 19793610 DOI: 10.1016/S0140-6736(09)61338-6]
 - 25 **Sugarbaker PH.** Peritonectomy procedures. *Ann Surg* 1995; **221**: 29-42 [PMID: 7826158 DOI: 10.1097/0000658-199501000-00004]
 - 26 **Neuwirth MG,** Alexander HR, Karakousis GC. Then and now: cytoreductive surgery with hyperthermic intraperitoneal chemotherapy (HIPEC), a historical perspective. *J Gastrointest Oncol* 2016; **7**: 18-28 [PMID: 26941981 DOI: 10.3978/j.issn.2078-6891.2015.106]
 - 27 **Kuijpers AM,** Aalbers AG, Nienhuijs SW, de Hingh IH, Wiezer MJ, van Ramshorst B, van Ginkel RJ, Havenga K, Heemsbergen WD, Hauptmann M, Verwaal VJ. Implementation of a standardized HIPEC protocol improves outcome for peritoneal malignancy. *World J Surg* 2015; **39**: 453-460 [PMID: 25245434 DOI: 10.1007/s00268-014-2801-y]
 - 28 **Witkamp AJ,** de Bree E, Kaag MM, Boot H, Beijnen JH, van Slooten GW, van Coevorden F, Zoetmulder FA. Extensive cytoreductive surgery followed by intra-operative hyperthermic intraperitoneal chemotherapy with mitomycin-C in patients with peritoneal carcinomatosis of colorectal origin. *Eur J Cancer* 2001; **37**: 979-984 [PMID: 11334722 DOI: 10.1016/s0959-8049(01)00058-2]
 - 29 **Zanon C,** Bortolini M, Chiappino I, Simone P, Bruno F, Gaglia P, Airoidi M, Deriu L, Mashiah A. Cytoreductive surgery combined with intraperitoneal chemohyperthermia for the treatment of advanced colon cancer. *World J Surg* 2006; **30**: 2025-2032 [PMID: 17058031 DOI: 10.1007/s00268-005-0486-y]
 - 30 **Elias D,** Antoun S, Goharin A, Otmány AE, Puizillout JM, Lasser P. Research on the best chemohyperthermia technique of treatment of peritoneal carcinomatosis after complete resection. *Int J Surg Investig* 2000; **1**: 431-439 [PMID: 11341599]
 - 31 **Elias D,** Blot F, El Otmány A, Antoun S, Lasser P, Boige V, Rougier P, Ducreux M. Curative treatment of peritoneal carcinomatosis arising from colorectal cancer by complete resection and intraperitoneal chemotherapy. *Cancer* 2001; **92**: 71-76 [PMID: 11443611 DOI: 10.1002/1097-0142(20010701)92:1<71::aid-cncr1293>3.0.co;2-9]
 - 32 **Vaira M,** Cioppa T, D'Amico S, de Marco G, D'Alessandro M, Fiorentini G, De Simone M. Treatment of peritoneal carcinomatosis from colonic cancer by cytoreduction, peritonectomy and hyperthermic intraperitoneal chemotherapy (HIPEC). Experience of ten years. *In Vivo* 2010; **24**: 79-84 [PMID: 20133981]
 - 33 **Asero S,** Caruso M, Vallone N, Luciani AG, Lombardo V, Terranova G, Ettore G, Giannone G. Cytoreductive surgery (cs) and hyperthermic intraperitoneal chemotherapy (hipec) in treatment of peritoneal surface malignances: report of a phase II clinical study. *In Vivo* 2009; **23**: 645-647 [PMID: 19567402]
 - 34 **Yonemura Y,** Canbay E, Ishibashi H. Prognostic factors of peritoneal metastases from colorectal cancer following cytoreductive surgery and perioperative chemotherapy. *ScientificWorldJournal* 2013; **2013**: 978394 [PMID: 23710154 DOI: 10.1155/2013/978394]
 - 35 **Braam HJ,** Boerma D, Wiezer MJ, van Ramshorst B. Hyperthermic intraperitoneal chemotherapy during primary tumour

- resection limits extent of bowel resection compared to two-stage treatment. *Eur J Surg Oncol* 2013; **39**: 988-993 [PMID: 23810334 DOI: 10.1016/j.ejso.2013.06.002]
- 36 **Cashin PH**, Dranichnikov F, Mahteme H. Cytoreductive surgery and hyperthermic intra-peritoneal chemotherapy treatment of colorectal peritoneal metastases: cohort analysis of high volume disease and cure rate. *J Surg Oncol* 2014; **110**: 203-206 [PMID: 24846340 DOI: 10.1002/jso.23610]
- 37 **Ceelen W**, Van Nieuwenhove Y, Putte DV, Pattyn P. Neoadjuvant chemotherapy with bevacizumab may improve outcome after cytoreduction and hyperthermic intraperitoneal chemoperfusion (HIPEC) for colorectal carcinomatosis. *Ann Surg Oncol* 2014; **21**: 3023-3028 [PMID: 24756812 DOI: 10.1245/s10434-014-3713-7]
- 38 **Hagendoorn J**, van Lammeren G, Boerma D, van der Beek E, Wiezer MJ, van Ramshorst B. Cytoreductive surgery and hyperthermic intraperitoneal chemotherapy for peritoneal carcinomatosis from colorectal and gastrointestinal origin shows acceptable morbidity and high survival. *Eur J Surg Oncol* 2009; **35**: 833-837 [PMID: 19019619 DOI: 10.1016/j.ejso.2008.10.006]
- 39 **Hompes D**, D'Hoore A, Wolthuis A, Fieuids S, Mirck B, Bruin S, Verwaal V. The use of Oxaliplatin or Mitomycin C in HIPEC treatment for peritoneal carcinomatosis from colorectal cancer: a comparative study. *J Surg Oncol* 2014; **109**: 527-532 [PMID: 24375059 DOI: 10.1002/jso.23546]
- 40 **Simkens GA**, van Oudheusden TR, Braam HJ, Wiezer MJ, Nienhuijs SW, Rutten HJ, van Ramshorst B, de Hingh IH. Cytoreductive surgery and HIPEC offers similar outcomes in patients with rectal peritoneal metastases compared to colon cancer patients: a matched case control study. *J Surg Oncol* 2016; **113**: 548-553 [PMID: 27110701 DOI: 10.1002/jso.24169]
- 41 **Morano WF**, Khalili M, Chi DS, Bowne WB, Esquivel J. Clinical studies in CRS and HIPEC: Trials, tribulations, and future directions-A systematic review. *J Surg Oncol* 2018; **117**: 245-259 [PMID: 29120491 DOI: 10.1002/jso.24813]
- 42 **Hildebrandt B**, Wust P, Ahlers O, Dieing A, Sreenivasa G, Kerner T, Felix R, Riess H. The cellular and molecular basis of hyperthermia. *Crit Rev Oncol Hematol* 2002; **43**: 33-56 [PMID: 12098606 DOI: 10.1016/s1040-8428(01)00179-2]
- 43 **Crezee J**, Franken NAP, Oei AL. Hyperthermia-Based Anti-Cancer Treatments. *Cancers (Basel)* 2021; **13** [PMID: 33808948 DOI: 10.3390/cancers13061240]
- 44 **de Andrade Mello P**, Bian S, Savio LEB, Zhang H, Zhang J, Junger W, Wink MR, Lenz G, Buffon A, Wu Y, Robson SC. Hyperthermia and associated changes in membrane fluidity potentiate P2X7 activation to promote tumor cell death. *Oncotarget* 2017; **8**: 67254-67268 [PMID: 28978031 DOI: 10.18632/oncotarget.18595]
- 45 **Chen T**, Guo J, Han C, Yang M, Cao X. Heat shock protein 70, released from heat-stressed tumor cells, initiates antitumor immunity by inducing tumor cell chemokine production and activating dendritic cells via TLR4 pathway. *J Immunol* 2009; **182**: 1449-1459 [PMID: 19155492 DOI: 10.4049/jimmunol.182.3.1449]
- 46 **Garg AD**, Krysko DV, Verfaillie T, Kaczmarek A, Ferreira GB, Marysael T, Rubio N, Firczuk M, Mathieu C, Roebroek AJ, Annaert W, Golab J, de Witte P, Vandenabeele P, Agostinis P. A novel pathway combining calreticulin exposure and ATP secretion in immunogenic cancer cell death. *EMBO J* 2012; **31**: 1062-1079 [PMID: 22252128 DOI: 10.1038/emboj.2011.497]
- 47 **Panaretakis T**, Kepp O, Brockmeier U, Tesniere A, Bjorklund AC, Chapman DC, Durchschlag M, Joza N, Pierron G, van Endert P, Yuan J, Zitvogel L, Madeo F, Williams DB, Kroemer G. Mechanisms of pre-apoptotic calreticulin exposure in immunogenic cell death. *EMBO J* 2009; **28**: 578-590 [PMID: 19165151 DOI: 10.1038/emboj.2009.1]
- 48 **Nagata S**, Tanaka M. Programmed cell death and the immune system. *Nat Rev Immunol* 2017; **17**: 333-340 [PMID: 28163302 DOI: 10.1038/nri.2016.153]
- 49 **Newton JM**, Flores-Arredondo JH, Suki S, Ware MJ, Krzykawska-Serda M, Agha M, Law JJ, Sikora AG, Curley SA, Corr SJ. Non-Invasive Radiofrequency Field Treatment of 4T1 Breast Tumors Induces T-cell Dependent Inflammatory Response. *Sci Rep* 2018; **8**: 3474 [PMID: 29472563 DOI: 10.1038/s41598-018-21719-w]
- 50 **Chen Q**, Fisher DT, Kucinska SA, Wang WC, Evans SS. Dynamic control of lymphocyte trafficking by fever-range thermal stress. *Cancer Immunol Immunother* 2006; **55**: 299-311 [PMID: 16044255 DOI: 10.1007/s00262-005-0022-9]
- 51 **Chen Q**, Appenheimer MM, Muhitch JB, Fisher DT, Clancy KA, Miecznikowski JC, Wang WC, Evans SS. Thermal facilitation of lymphocyte trafficking involves temporal induction of intravascular ICAM-1. *Microcirculation* 2009; **16**: 143-158 [PMID: 19031292 DOI: 10.1080/10739680802353850]
- 52 **Evans SS**, Wang WC, Bain MD, Burd R, Ostberg JR, Repasky EA. Fever-range hyperthermia dynamically regulates lymphocyte delivery to high endothelial venules. *Blood* 2001; **97**: 2727-2733 [PMID: 11313264 DOI: 10.1182/blood.v97.9.2727]
- 53 **Kodiha M**, Chu A, Lazrak O, Stochaj U. Stress inhibits nucleocytoplasmic shuttling of heat shock protein hsc70. *Am J Physiol Cell Physiol* 2005; **289**: C1034-C1041 [PMID: 15930140 DOI: 10.1152/ajpcell.00590.2004]
- 54 **Pfister K**, Radons J, Busch R, Tidball JG, Pfeifer M, Freitag L, Feldmann HJ, Milani V, Issels R, Multhoff G. Patient survival by Hsp70 membrane phenotype: association with different routes of metastasis. *Cancer* 2007; **110**: 926-935 [PMID: 17580361 DOI: 10.1002/cncr.22864]
- 55 **Shevtsov M**, Multhoff G. Heat Shock Protein-Peptide and HSP-Based Immunotherapies for the Treatment of Cancer. *Front Immunol* 2016; **7**: 171 [PMID: 27199993 DOI: 10.3389/fimmu.2016.00171]
- 56 **Pelz JO**, Stojadinovic A, Nissan A, Hohenberger W, Esquivel J. Evaluation of a peritoneal surface disease severity score in patients with colon cancer with peritoneal carcinomatosis. *J Surg Oncol* 2009; **99**: 9-15 [PMID: 18937291 DOI: 10.1002/jso.21169]
- 57 **Shen P**, Hawksworth J, Lovato J, Loggie BW, Geisinger KR, Fleming RA, Levine EA. Cytoreductive surgery and intraperitoneal hyperthermic chemotherapy with mitomycin C for peritoneal carcinomatosis from nonappendiceal colorectal carcinoma. *Ann Surg Oncol* 2004; **11**: 178-186 [PMID: 14761921 DOI: 10.1245/aso.2004.05.009]
- 58 **Kusamura S**, Dominique E, Baratti D, Younan R, Deraco M. Drugs, carrier solutions and temperature in hyperthermic intraperitoneal chemotherapy. *J Surg Oncol* 2008; **98**: 247-252 [PMID: 18726886 DOI: 10.1002/jso.21051]
- 59 **Mohamed F**, Cecil T, Moran B, Sugarbaker P. A new standard of care for the management of peritoneal surface malignancy. *Curr Oncol* 2011; **18**: e84-e96 [PMID: 21505593 DOI: 10.3747/co.v18i2.663]
- 60 **Glehen O**, Cotte E, Kusamura S, Deraco M, Baratti D, Passot G, Beaujard AC, Noel GF. Hyperthermic intraperitoneal

- chemotherapy: nomenclature and modalities of perfusion. *J Surg Oncol* 2008; **98**: 242-246 [PMID: 18726885 DOI: 10.1002/jso.21061]
- 61 **Ceelen W**. HIPEC with oxaliplatin for colorectal peritoneal metastasis: The end of the road? *Eur J Surg Oncol* 2019; **45**: 400-402 [PMID: 30392745 DOI: 10.1016/j.ejso.2018.10.542]
- 62 **Esquivel J**. Cytoreductive surgery and hyperthermic intraperitoneal chemotherapy for colorectal cancer: survival outcomes and patient selection. *J Gastrointest Oncol* 2016; **7**: 72-78 [PMID: 26941985 DOI: 10.3978/j.issn.2078-6891.2015.114]
- 63 **Rossi AJ**, Khan TM, Rehman SU, Nash GM, Hernandez JM. Early Postoperative Intraperitoneal Versus Hyperthermic Intraperitoneal Chemotherapy After Optimal Cytoreductive Surgery for Colorectal Cancer with Isolated Peritoneal Metastasis (ICARuS). *Ann Surg Oncol* 2021; **28**: 4100-4101 [PMID: 34032959 DOI: 10.1245/s10434-021-10110-1]
- 64 **van de Vlasakker VCJ**, Lurvink RJ, Cashin PH, Ceelen W, Deraco M, Goéré D, González-Moreno S, Lehmann K, Li Y, Moran B, Morris DL, Piso P, Quadros CA, Rau B, Somashekhar SP, Sommariva A, van der Speeten K, Spiliotis J, Sugarbaker PH, Teo MCC, Verwaal VJ, Yonemura Y, Glehen O, de Hingh IHJT. The impact of PRODIGE 7 on the current worldwide practice of CRS-HIPEC for colorectal peritoneal metastases: A web-based survey and 2021 statement by Peritoneal Surface Oncology Group International (PSOGI). *Eur J Surg Oncol* 2021; **47**: 2888-2892 [PMID: 34020808 DOI: 10.1016/j.ejso.2021.05.023]
- 65 **Rovers KP**, Bakkens C, Simkens GAAM, Burger JWA, Nienhuijs SW, Creemers GM, Thijs AMJ, Brandt-Kerkhof ARM, Madsen EVE, Ayez N, de Boer NL, van Meerten E, Tuijnman JB, Kusters M, Sluiter NR, Verheul HMW, van der Vliet HJ, Wiezer MJ, Boerma D, Wassenaar ECE, Los M, Hunting CB, Aalbers AGJ, Kok NFM, Kuhlmann KFD, Boot H, Chalabi M, Kruijff S, Been LB, van Ginkel RJ, de Groot DJA, Fehrmann RSN, de Wilt JHW, Bremers AJA, de Reuver PR, Radema SA, Herbschleb KH, van Grevenstein WMU, Witkamp AJ, Koopman M, Haj Mohammad N, van Duyn EB, Mastboom WJB, Mekenkamp LJM, Nedderend J, Lahaye MJ, Snaebjornsson P, Verhoef C, van Laarhoven HWM, Zwinderman AH, Bouma JM, Kranenburg O, van 't Erve I, Fijneman RJA, Dijkgraaf MGW, Hemmer PHJ, Punt CJA, Tanis PJ, de Hingh IHJT; Dutch Peritoneal Oncology Group (DPOG); Dutch Colorectal Cancer Group (DCCG). Perioperative systemic therapy and cytoreductive surgery with HIPEC versus upfront cytoreductive surgery with HIPEC alone for isolated resectable colorectal peritoneal metastases: protocol of a multicentre, open-label, parallel-group, phase II-III, randomised, superiority study (CAIRO6). *BMC Cancer* 2019; **19**: 390 [PMID: 31023318 DOI: 10.1186/s12885-019-5545-0]
- 66 **Goéré D**, Glehen O, Quenet F, Guilloit JM, Bereder JM, Lorimier G, Thibaudeau E, Ghouti L, Pinto A, Tuech JJ, Kianmanesh R, Carretier M, Marchal F, Arvieux C, Brigand C, Meeus P, Rat P, Durand-Fontanier S, Mariani P, Lakkis Z, Loi V, Pirro N, Sabbagh C, Texier M, Elias D; BIG-RENAPE group. Second-look surgery plus hyperthermic intraperitoneal chemotherapy versus surveillance in patients at high risk of developing colorectal peritoneal metastases (PROPHYLOCHIP-PRODIGE 15): a randomised, phase 3 study. *Lancet Oncol* 2020; **21**: 1147-1154 [PMID: 32717180 DOI: 10.1016/S1470-2045(20)30322-3]
- 67 **Klaver CE**, Musters GD, Bemelman WA, Punt CJ, Verwaal VJ, Dijkgraaf MG, Aalbers AG, van der Bilt JD, Boerma D, Bremers AJ, Burger JW, Buskens CJ, Evers P, van Ginkel RJ, van Grevenstein WM, Hemmer PH, de Hingh IH, Lammers LA, van Leeuwen BL, Meijerink WJ, Nienhuijs SW, Pon J, Radema SA, van Ramshorst B, Snaebjornsson P, Tuijnman JB, Te Velde EA, Wiezer MJ, de Wilt JH, Tanis PJ. Adjuvant hyperthermic intraperitoneal chemotherapy (HIPEC) in patients with colon cancer at high risk of peritoneal carcinomatosis; the COLOPEC randomized multicentre trial. *BMC Cancer* 2015; **15**: 428 [PMID: 26003804 DOI: 10.1186/s12885-015-1430-7]



Published by **Baishideng Publishing Group Inc**
7041 Koll Center Parkway, Suite 160, Pleasanton, CA 94566, USA
Telephone: +1-925-3991568
E-mail: bpgoffice@wjgnet.com
Help Desk: <https://www.f6publishing.com/helpdesk>
<https://www.wjgnet.com>

