

# Glycine Receptor Antibody-Associated Progressive Encephalomyelitis with Rigidity and Myoclonus (PERM) During SARS-CoV-2 Infection: a Video-Case Report

Sebastiano Giacomozzi, MD,<sup>1</sup> Valentina Barone, MD,<sup>1</sup> Elena Merli, MD,<sup>2</sup> Sara Contardi, MD,<sup>2</sup> Fortuna Ricciardiello, MSc,<sup>3</sup> Maria Pia Giannoccaro, MD, PhD,<sup>1,3</sup> Rocco Liguori, MD,<sup>1,3</sup> and Andrea Zini, MD<sup>2,\*</sup>

A spectrum of neurological manifestations has been described as possible complication of SARS-CoV-2 disease, either through direct or indirect mechanisms. Among these complications, a wide range of inflammatory or immune-mediated diseases have been temporally associated with SARS-CoV-2 infection.<sup>1</sup>

## Case Report

A 65-year-old man with no previous medical history was admitted to our hospital 7 days after the onset of mild respiratory symptoms along with progressive dysphagia and psychomotor agitation (Fig. 1). On admission, nasopharyngeal swab test was positive for SARS-CoV-2. Routine laboratory exams showed mild neutrophilic leucocytosis with raised inflammatory markers (c reactive protein 6.44 mg/dl, n.v. <0.50; interleukin 6 83.4 pg/ml, n.v. <6.4). Chest high-resolution computed tomography revealed mild bilateral ground-glass opacities, suspected of COVID-19 pneumonia. The patient rapidly developed acute dyspnoea with respiratory failure requiring non-invasive ventilation. On the second day of admission, neurological examination revealed diffuse pyramidal signs and multiple cranial nerves involvement with bilateral ophthalmoparesis and left facial cranial nerve deficit. Three days after admission, the patient was admitted to the intensive care unit and placed on invasive mechanical ventilation due to worsening of respiratory function and occurrence of dysautonomic storms with hypertension and tachycardia. Over the following days, the patient

developed severe muscle stiffness associated with spontaneous and stimulus-induced multifocal myoclonus (Video 1).

Given the clinical picture, a diagnostic work-up for differential diagnosis of complex brainstem syndromes was started. Cerebrospinal fluid (CSF) analysis revealed mild pleocytosis (leukocytes 95/mm<sup>3</sup>, n.v. <5; neutrophils 95.8%), with slightly elevated protein levels (60 mg/dl, n.v. <50) and oligoclonal bands type 2. CSF microbiological analyses were negative. 1.5 T gadolinium-enhancement brain magnetic resonance imaging (MRI) was unremarkable at 2 and 4 weeks after symptoms onset. Electroencephalogram (EEG) with polygraphy excluded a cortical origin of myoclonus. Neurophysiological studies documented a continuous motor unit activity at rest, unresponsive to low-dose benzodiazepines. Nineteen days after admission nasopharyngeal swab for SARS-CoV-2 was negative; laboratory investigations, including infectious and autoimmune panels, were negative. Antibody testing with cell-based assay panel revealed high-titer Glycine receptor (GlyR) antibodies in both serum (titer 1:3200) and CSF (titer 1:640); other onconeural and cell-surface antibodies (NMDAR, CASPR2, AMPAR, GABAAR, GABABR, LGI1, DPPX, Amphiphysin, CV2, MA2, Ri, Yo, Hu, Recoverine, SOX1, Titine, Zic4, GAD65, Tr) were negative in both serum and CSF. Diagnostic work-up for malignancy with total-body computed tomography (CT) scan was unremarkable. The patient was diagnosed with progressive encephalomyelitis with rigidity and myoclonus (PERM) and treated with intravenous immunoglobulins 0.4 g/kg daily for 5 days. No beneficial clinical response was observed, therefore high-dose corticosteroids (1 g/day intravenous

<sup>1</sup>Department of Biomedical and Neuromotor Sciences (DIBINEM), Alma Mater Studiorum-University of Bologna, Bologna, Italy; <sup>2</sup>IRCCS Istituto delle Scienze Neurologiche di Bologna, U.O.C. Neurologia e Rete Stroke Metropolitana, Bologna, Italy; <sup>3</sup>IRCCS Istituto delle Scienze Neurologiche di Bologna, U.O.C. Clinica Neurologica, Bologna, Italy

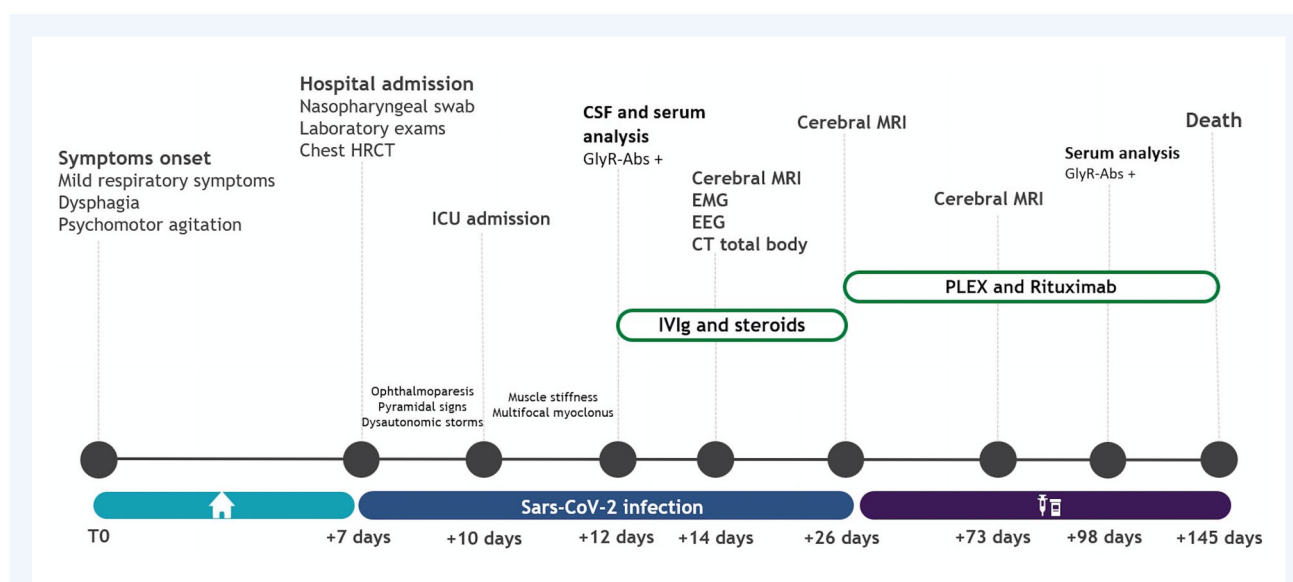
\*Correspondence to: Andrea Zini, IRCCS Istituto delle Scienze Neurologiche di Bologna, U.O.C. Neurologia e Rete Stroke Metropolitana, Ospedale Maggiore, Bologna, Italy; E-mail: [a.zini@ausl.bologna.it](mailto:a.zini@ausl.bologna.it)

**Keywords:** PERM, brainstem syndrome, stiff-person syndrome, SARS-CoV-2, COVID-19.

This is an open access article under the terms of the [Creative Commons Attribution-NonCommercial-NoDerivs](https://creativecommons.org/licenses/by-nc-nd/4.0/) License, which permits use and distribution in any medium, provided the original work is properly cited, the use is non-commercial and no modifications or adaptations are made.

Received 15 October 2022; revised 27 December 2022; accepted 19 February 2023.

Published online 16 March 2023 in Wiley Online Library ([wileyonlinelibrary.com](https://www.wileyonlinelibrary.com)). DOI: 10.1002/mdc3.13712



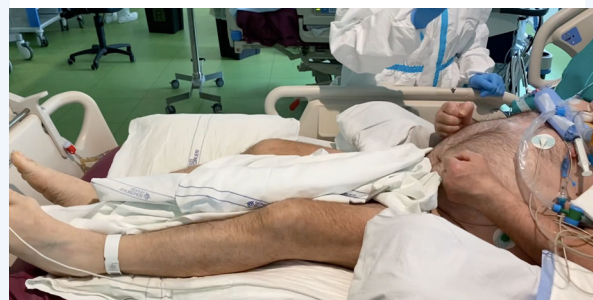**Figure 1.** Timeline of clinical symptoms, diagnostic work-up and treatment during the disease course. HRCT High-resolution computed tomography; ICU intensive care unit; MRI magnetic resonance imaging; CSF cerebral spinal fluid; GlyR-Abs glycine receptor antibodies; EMG electromyography; EEG electroencephalogram; CT computed tomography; IVIg Intravenous immunoglobulins; PLEX plasma exchange.

methylprednisolone) for 5 days followed by four sessions of plasma exchange were administered without efficacy. Fourteen weeks after symptoms onset, anti-glyR antibodies were still positive at high titer in the serum (1:1600) and 3 T gadolinium-enhancement brain magnetic resonance imaging was unremarkable. Rituximab (375 mg/m<sup>2</sup> per week for 4 weeks) was started with a slight clinical benefit. Unfortunately, the patient died of septic shock 9 weeks later.

## Discussion

PERM is a rare life-threatening disease belonging to the spectrum of Stiff-Person Syndrome (SPS) disorders.<sup>2</sup> It is characterized by a subacute progressive course with brainstem involvement, hyperekplexia, prolonged tonic spasms, autonomic symptoms and respiratory failure.<sup>2,3</sup> In 2008, Hutchinson et al. firstly reported the association between GlyR antibodies and PERM.<sup>4</sup> GlyR antibodies are found in 50% of patients with PERM and they are believed to play a direct role in the pathogenesis of the disorder through their antagonistic action on glycine receptors. Other antibodies have been associated less frequently with PERM, including GAD65 (glutamic acid decarboxylase-65), amphiphysin and DPPX (dipeptidyl-peptidase-like protein 6) antibodies.<sup>3</sup> Most cases of PERM usually have an immune-mediated etiology. Tumors, such as thymoma and Hodgkin's lymphoma, can be found in about 20% of patients, suggesting a paraneoplastic etiology.<sup>3,5</sup> In our case, no evidence of malignancy was documented.

Regarding SARS-CoV-2 infection, previous reports have associated it with neurological disorders through various pathogenetic



**Video 1.** The reported patient 10 days after admission showing multiple cranial nerves involvement (right abducent, left oculomotor and left facial cranial nerves palsies), peri-oral myoclonia, sub-continuous right pectoralis muscle myokymia, hyperekplexia (with massive tactile stimulus-induced startle response despite deep sedation) and diffuse hyperreflexia, despite ongoing therapy with midazolam, propofol, fentanyl (all of them continuously), clonazepam (2.5 mg tid) and levetiracetam (1000 mg tid). Video content can be viewed at <https://onlinelibrary.wiley.com/doi/10.1002/mdc3.13712>

mechanisms, including direct viral CNS invasion and immune-mediated processes, either para-infectious or post-infectious.<sup>1,6</sup> Furthermore, a single case of bulbar signs associated with spasticity and startle response has been described after SARS-CoV-2 infection. However, no PERM-associated antibodies were detected and the authors did not specify the temporal window between the infection and the symptoms onset.<sup>7</sup>

Although evidence of SARS-CoV-2 infection in the CSF with PCR or antibody testing was not performed in our patient,

temporal correlation and diagnostic findings might suggest a triggered immune-mediated response resulting in PERM. Indeed, an autoimmune cross-reactivity mechanism which might be involved in some COVID-19-associated neurological manifestations could also be implicated in the postinfectious syndrome of our patient. However, the causality between SARS-CoV-2 infection and inflammatory disease onset remains to be clarified.

In conclusion, PERM is a rare disease that should be considered in differential diagnosis of brainstem syndromes. To our knowledge, no PERM cases with the detection of glycine receptor antibodies has been previously reported during SARS-CoV-2 infection.

## Acknowledgment

Open access funding provided by BIBLIOSAN.

## Author Roles

(1) Research Project: A. Study Concept and Design, B. Acquisition of Data, C. Analysis and Interpretation of Data, D. Supervision; (2) Manuscript Preparation: A. Writing of the First Draft, B. Review and Revision.

S.G.: 1A, 1B, 2A

V.B.: 1A, 1B, 2A

E.M.: 1A, 1D, 2B

S.C.: 1B, 1D, 2B

F.R.: 1B, 1C

M.P.G.: 1B, 1C, 1D, 2B

R.C.: 1B, 1D, 2B

A.Z.: 1B, 1D, 2B

## Disclosures

**Ethical Compliance Statement:** The authors confirm that the approval of an institutional review board was not required for

this work. Patient family members gave consent to film for publication. The authors confirm that they have read the Journal's position on issues involved in ethical publication and affirm that this work is consistent with those guidelines. Patient family members signed an informed consent for the video recording and for the publication of the case report.

**Funding Sources and Conflicts of Interest:** The authors received no financial support for the research, authorship and publication of this article. The authors declare no conflict of interest relative to the current research.

**Financial Disclosures for the Previous 12 Months:** The authors received no financial support for the research, authorship and publication of this article. ■

## References

1. Aghagholi G, Gallo Marin B, Katchur NJ, Chaves-Sell F, Asaad WF, Murphy SA. Neurological Involvement in COVID-19 and Potential Mechanisms: A Review. *Neurocrit Care* 2021;34(3):1062–1071. <https://doi.org/10.1007/s12028-020-01049-4>.
2. Meinck HM, Thompson PD. Stiff man syndrome and related conditions. *Mov Disord* 2002;17(5):853–866. <https://doi.org/10.1002/mds.10279>.
3. Crisp SJ, Balint B, Vincent A. Redefining progressive encephalomyelitis with rigidity and myoclonus after the discovery of antibodies to glycine receptors. *Curr Opin Neurol* 2017;30(3):310–316. <https://doi.org/10.1097/WCO.0000000000000450>.
4. Hutchinson M, Waters P, McHugh J, et al. Progressive encephalomyelitis, rigidity, and myoclonus: a novel glycine receptor antibody. *Neurology* 2008;71(16):1291–1292. <https://doi.org/10.1212/01.wnl.0000327606.50322.f0>.
5. Carvajal-González A, Leite MI, Waters P, et al. Glycine receptor antibodies in PERM and related syndromes: characteristics, clinical features and outcomes [published correction appears in *Brain*. 2014 Dec;137(Pt 12):e315]. Press, Raomand [corrected to Press, Rayomand] [published correction appears in *Brain*. 2014 Jan;137(Pt 1):1]. *Brain* 2014;137(Pt 8):2178–2192. <https://doi.org/10.1093/brain/awu142>.
6. Beghi E, Giussani G, Westenberg E, et al. Acute and post-acute neurological manifestations of COVID-19: present findings, critical appraisal, and future directions. *J Neurol* 2022;269(5):2265–2274. <https://doi.org/10.1007/s00415-021-10848-4>.
7. Islam M, Nayyer M, Madarshahian D, Jenkins TM. New Neurological Syndromes with COVID-19 Infection: Is Immune System Hyperactivity to Blame? (P3-9.003). *Neurology* 2022;98(18 Supplement):1921.