

## Paradoxical Psoriasis: A Dermoscopic and Histopathologic Teaching Point

Marco Adriano Chessa<sup>1,2</sup>, Luca Rapparini<sup>1,2</sup>, Federica Filippi<sup>1</sup>, Carlotta Baraldi<sup>1</sup>, Bianca Maria Piraccini<sup>1</sup>, Iria Neri<sup>1</sup>

1 Dermatology Unit, IRCCS Azienda Ospedaliero-Universitaria di Bologna, Bologna, Italy

2 Department of Medical and Surgical Sciences, Alma Mater Studiorum University of Bologna, Italy

**Citation:** Chessa MA, Rapparini L, Filippi F, Baraldi C, Piraccini BM, Neri I. Paradoxical psoriasis: A Dermoscopic and Histopathologic Teaching Point. *Dermatol Pract Concept*. 2024;14(1):e2024013. DOI: <https://doi.org/10.5826/dpc.1401a13>

**Accepted:** June 12, 2023; **Published:** January 2024

**Copyright:** ©2024 Chessa et al. This is an open-access article distributed under the terms of the Creative Commons Attribution-NonCommercial License (BY-NC-4.0), <https://creativecommons.org/licenses/by-nc/4.0/>, which permits unrestricted noncommercial use, distribution, and reproduction in any medium, provided the original authors and source are credited.

**Funding:** None.

**Competing Interests:** None.

**Authorship:** All authors have contributed significantly to this publication.

**Corresponding Author:** Luca Rapparini, MD, Dermatology Unit, IRCCS Azienda Ospedaliero-Universitaria di Bologna, Department of Medical and Surgical Sciences, Alma Mater Studiorum University of Bologna, Via Massarenti 1, 40138 Bologna, Italy. ORCID 0000-0002-4029-941X. Phone: +390512144838 E-mail: [luca.rapparini2@studio.unibo.it](mailto:luca.rapparini2@studio.unibo.it)

### Case Presentation

A 50-year-old woman presented an erythematous desquamative plantar eruption occurred 6 months prior to the visit (Figure 1A). Several treatments with topical potent corticosteroids and antimycotics were given in the clinical suspect of dyshidrotic eczema, without improvement.

Dermoscopy showed white scales and regularly distributed red dots, a pattern usually detected in psoriasis (Figure 1B) [1].

Histological examination showed parakeratosis, hypogranulosis and psoriasiform epidermal hyperplasia and neutrophils in the stratum corneum, forming Munro micro-abscesses, confirming the diagnosis of psoriasis (Figure 1C).

A further investigation of medical history revealed that the patient was affected by Crohn disease, and successfully treated with adalimumab in the last 5 years. A diagnosis of paradoxical psoriasis was proposed, and in agreement with the gastroenterologist, biological therapy was switched to ustekinumab. In addition, calcipotriol/betamethasone

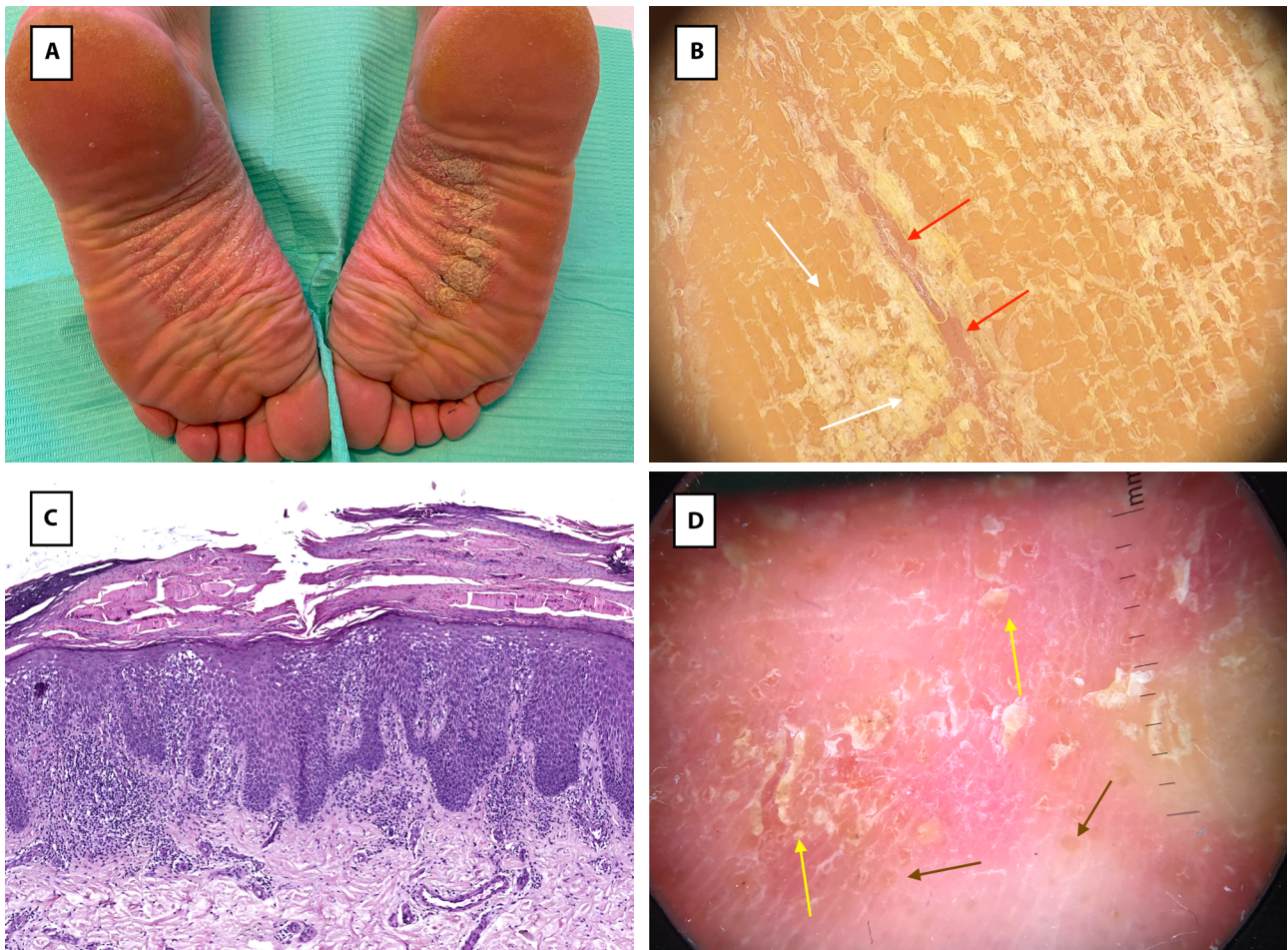
dipropionate ointment was started. At 3 months of follow-up, the plantar lesions were completely resolved, without Crohn's disease relapses.

### Teaching Point

Paradoxical psoriasis is a well-documented manifestation in patients with inflammatory bowel disease treated with anti-TNF- $\alpha$  agents [2]. The pathological mechanism of the onset of psoriasis due to anti-TNF- $\alpha$  seems related to the migration of T cells to the skin induced by IFN- $\alpha$  produced by plasmacytoid dendritic cells.

Dermoscopy in palmoplantar localization could be crucial for a differential diagnosis: in chronic dyshidrotic eczema yellow scales and brownish dots/globules are usually detected (Figure 1D) corresponding to tiny spongiotic vesicles; while psoriasis is characterized by white scales and regular distributed red dots.

In these cases, the withdrawal from anti-TNF- $\alpha$  usually induces a complete remission of the skin lesions, thus confirming a reversible and drug-related side effect.



**Figure 1.** (A) Erythematous desquamative plantar eruption with rhagades. (B) Dermoscopy of palmoplantar psoriasis: white scales (white arrows) and regular distributed red dots (red arrows). (C) Histology of palmoplantar psoriasis: parakeratosis, hypogranulosis, psoriasiform epidermal hyperplasia, neutrophil in the stratum corneum, dilated capillaries and perivascular lymphocytes in the dermis (H&E, 10x). (D) Dermoscopy of dyshidrotic eczema: yellow scales (yellow arrows) and brownish dots/globules (brown arrows).

In our case, given the personal history of Crohn disease, a switch to a biological drug of another class was successfully undertaken.

**Patient Consent:** Informed consent for the use of information and images has been obtained from the patient.

## References

1. Çetinarslan T, Türel Ermertcan A, Temiz P. Dermoscopic clues of palmoplantar hyperkeratotic eczema and palmoplantar psoriasis:

A prospective, comparative study of 90 patients. *J Dermatol.* 2020;47(10):1157-1165. DOI: 10.1111/1346-8138.15487. PMID: 32691449.

2. Pugliese D, Guidi L, Ferraro PM, et al. Paradoxical psoriasis in a large cohort of patients with inflammatory bowel disease receiving treatment with anti-TNF alpha: 5-year follow-up study. *Aliment Pharmacol Ther.* 2015;42(7):880-888. DOI: 10.1111/apt.13352. PMID: 26235565.