

## The Fate of Apically Extruded Sealers: Radiographical Disappearance or Biological Integration? A Narrative Review

Fausto Zamparini<sup>1</sup> , Andrea Spinelli<sup>1</sup> , Stefano Palma<sup>1</sup> , Alessio Buonavoglia<sup>1</sup> , Luca Guerrini<sup>2</sup> , Maria Giovanna Gandolfi<sup>3</sup> , Carlo Prati<sup>1</sup> 

<sup>1</sup>Endodontic Clinical Section, Dental School, University of Bologna, Via san vitale 59, Bologna, Italy

<sup>2</sup>Department of Life, Health and Environmental Sciences, University of L'Aquila, LAquila, Italy

<sup>3</sup>Laboratory of Biomaterials, Dental School, University of Bologna, Via san vitale 59, Bologna, Italy

### ABSTRACT

**Objective:** Over the past 2 decades, several novel materials have been introduced into endodontic practice, specifically designed to be bioactive and biointeractive with apical bone tissues. However, despite their widespread adoption, there remains limited consensus on the biological consequences of accidental apical extrusion, particularly when premixed bioceramic sealers are used. This review aims to analyse both the immediate and long-term effects of apical extrusion of new bioactive root canal sealers compared to traditional bioinert obturation materials.

**Methods:** Open search strategy was performed on indexed public databases (Scopus, PubMed, Embase). Data were gathered from clinical reports, in vivo animal studies, and in vitro experiments that investigated clinical outcomes, apical healing, occurrence of post-operative pain, occurrence of apical extrusion as well as tissue responses, inflammatory potential, and sealer resorption.

**Results:** The review highlights variations in the biological behaviour depending on different sealer formulations and their interaction with periapical tissues. Apical extrusions of biologically active sealers such as premixed bioceramic sealers may result in dynamic radiographical modifications during the follow-up. This behaviour has also been observed in minor percentages for traditional zinc oxide sealers, in similar percentages for calcium hydroxide-based sealers. No modifications of apical extruded sealer were observed for epoxy resin-based sealers.

**Conclusion:** The extrusion of any endodontic material beyond the apical foramen continues to pose potential risks, particularly in the presence of pre-existing periapical pathologies. For clinicians, it is important to understand the properties and composition of each sealer. There is a need for further long-term high-quality clinical trials to establish the long-term impact of sealers' radiographical disappearance when extruded into periapical issues. Establishment of a standardised terminology to accurately describe these phenomena and to prevent misinterpretation or inconsistency in future investigations is also recommended.

**Keywords:** apical extrusion, biological properties, CaSi, premixed sealers, review

**Cite this article as:** Zamparini F, Spinelli A, Palma S, et al. The fate of apically extruded sealers: Radiographical disappearance or biological integration? A narrative review. *Eur Endod J.* 2026;11(3): 90-102.

#### Corresponding author:

Fausto Zamparini

✉ fausto.zamparini2@unibo.it

**Received:** June 17, 2025

**Revision Requested:** August 14, 2025

**Last Revision Received:** October 16, 2025

**Accepted:** October 29, 2025

**Publication Date:** March 30, 2026

DOI: 10.65717/eej.2026.25100

This work is licensed under a Creative Commons

Attribution-NonCommercial 4.0 International License.



### HIGHLIGHTS

- There is a lack of consensus regarding the effects of an apical extrusion, especially with new premixed bioceramic root canal sealers
- The chemical composition of endodontic sealers influences their physicochemical properties and adverse effects when in contact with periapical tissues.
- Apical extrusions of premixed bioceramic sealers may result in dynamic radiographical modifications during the follow-up
- The extrusion of obturation materials (guttapercha and sealer) exceeding 2.0mm is an undesired event, it is important to follow a correct management of working length and apical gauging during endodontic therapy

## INTRODUCTION

Apical extrusion is referred to the presence of root canal filling materials, i.e. gutta-percha (GP) and/or sealers, into the periapical tissues. The American Academy of Endodontics<sup>1</sup> distinguishes between the term “overfilling,” characterised by the extrusion of material beyond the apex with complete obturation of the root canal space, and “over-extension” where the extrusion occurs in conjunction with an inadequately sealed root canal space.

Apical limit for canal preparation and obturation remains one of the main topics of debate in endodontics.<sup>2</sup> The cemento-dentinal junction is clinically unidentifiable<sup>3</sup> and may vary in location and morphology.<sup>4</sup> The apical foramen is an anatomical structure that already belongs to the periodontium and can be generally located with an electronic apex locator.<sup>3,4</sup> However, the presence of chronic periapical lesions, apical infections, apical resorption, or wide apexes can determine difficulties in locating the apical limit.

Several new materials, claimed to be bioactive and biointeractive to the apical bone tissues, have been developed and introduced in clinical practice for 20 years. Currently, there is a lack of consensus regarding the effects of apical extrusion, especially with new bioactive root canal sealers. The aim of this review is to analyse the immediate and delayed effects of apical extrusion of new bioactive root canal sealers compared to traditional bioinert obturation materials. Data from both clinical investigations and laboratory studies were summarised to report key points useful for clinicians.

## METHODOLOGY

### Literature Review Methodology

The present narrative review was prepared following the recommendations proposed by Ferrari (2015).<sup>5</sup> An open literature review methodology in databases (Scopus, PubMed and Embase) was performed for each topic following the criteria used in a recently published narrative review.<sup>6</sup>

The list of words differently combined using Boolean operators “AND”/“OR” included the words: root canal treatment, GP extrusion, root canal sealer, sealer extrusion, post-treatment pain, neurological complications, apical resorption, sealer solubilisation, apical extrusion, and radiographical disappearance. The search was limited to English-language studies.

### Inclusion Criteria

Inclusion criteria encompassed both *in vitro* and *in vivo* studies, including studies where the effect of root canal filling material when in contact to biological tissues (i.e. sealer extrusions) is explicitly reported.

### Exclusion Criteria

Abstracts, case reports, or studies with incomplete data (e.g. obtained from public databases or gray literature) were excluded from the analysis. Studies with no explicit mention of the effect of root canal filling materials in contact to biological tissues (i.e. sealer extrusion) were not included in this study.

### Data Extraction

Data extraction was performed independently by 2 reviewers (FZ and SP). The findings were synthesised and presented in a narrative format, highlighting the positive or negative effects of root canal filling

material extrusion in periapical areas. Finally, clinical studies on root canal treatment were included and analysed when mention of apical extrusion events was explicitly specified.

## RESULTS

Apical extrusion of root canal filling materials can remain stable in the bone tissue for many years and also after tooth extraction and implant rehabilitation. Filling material remnants can be easily detected in radiographic examinations in post-extractive areas, but also in experimental Environmental Scanning Electron Microscope—Energy Dispersive X-ray Analysis (ESEM-EDX) investigations on histological slides. As an emblematic example, Figure 1 reports the accidental findings of a previous root canal filling extrusion close to a retrieved implant histological sample (unpublished data). The atomic composition of the electron dense granules, easily detected by ESEM, was investigated using EDX, revealing constitutional elements belonging to sealers or GP (such as Silicon or Zinc). Root canal filling materials can be distinguished as GP or sealers, which implies 2 different conditions that are examined separately.

### Gutta-Percha Extrusion

Gutta-Percha is one of the most inert filling materials and is generally well tolerated by periapical tissues, although in very rare cases, it may induce foreign body reactions.<sup>7</sup> Main causative agents of GP extrusion are the uncontrolled management of apical diameter and/or working length.

The chemical composition of commercial GP cones varies from 1 manufacturer to the other; these devices commonly contain a matrix of trans-1,4-polyisoprene (varying between 14.5% and 21.8% in weight), waxes and resins (1%-10.4% in weight, added as plasticizing agents), and zinc oxide (36.6%-84.3% in weight), barium sulfate (0%-31.2% in weight), together with small percentages of colouring agents and antioxidants.<sup>8</sup>

Macrophages are responsible for its complete absorption, particularly over long follow-up periods.<sup>9,10</sup> Some studies showed that GP extruded into periradicular tissues can activate an immune response with resorption of extruded GP and a small portion within the apical portion of the root canal.<sup>10,11</sup>

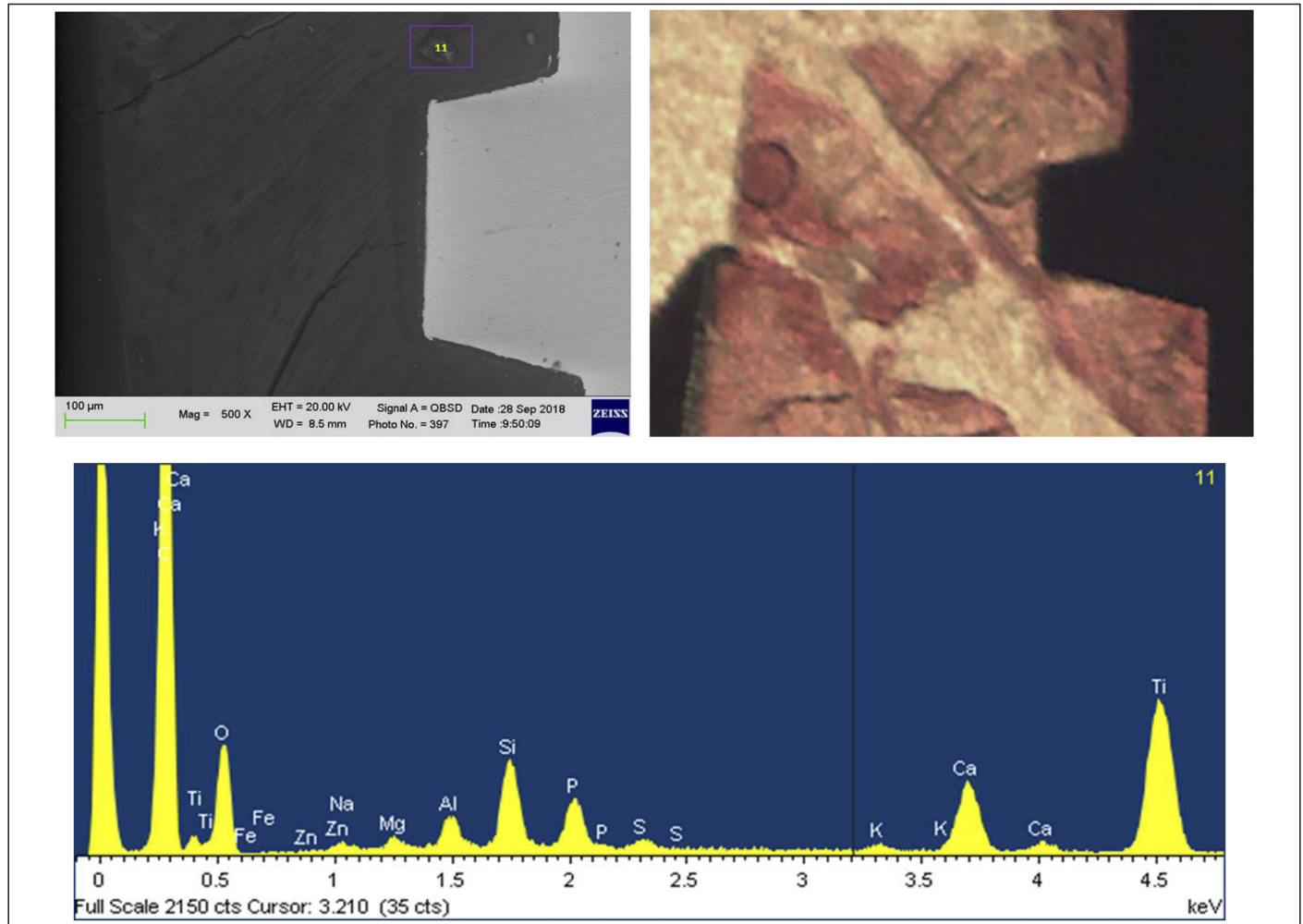
This phenomenon could have some implications: on 1 hand, it may enhance the stability of the apical seal through the formation of connective tissue at the periapex, but it could lead to a leak of apical seal and a possible reactivation of endodontic periapical pathologies.<sup>10,11</sup>

Particle size and composition of GP are related to the degree of inflammation and irritation of the periapical tissues.

Composition depends on the specific manufacturer, and small-sized particles are associated with more intense tissue reactions.<sup>12</sup>

The aspect of GP toxicity has been analysed only in old studies, and only a few laboratory studies have been conducted on new GP formulations, such as patented bioactive GP cone<sup>13</sup> or GP containing Niobium Phosphate Bioglass.<sup>14</sup>

The potential toxicity of the GP cone is attributed to the release of zinc ions in contact with periapical fluids.<sup>15-17</sup> The dispersion of these ions at the periapical area may presumably stimulate the accumulation



**Figure 1.** Image of 1 retrieved implant bone biopsies analysed through ESEM-EDX to assess the mineralisation degree. ESEM-EDX analyses detected some electron dense granules containing Zn and Si, suggesting extruded obturation material embedded into bone tissue.

of macrophages that support a foreign body reaction up to 60 days after its extrusion. The GP also contains trans-1,4 polyisoprene that is related to several biological<sup>18-20</sup> and chemical processes when it is degraded by periapical fluids.

The GP degradation is supported by the presence of oxygen, which explains the low degradation rate of GP inside the canal with respect to the periapical area.<sup>21</sup> An increased rate of polymer degradation was also observed in infected teeth, identifying the presence of microorganisms as an additional and concomitant cause of GP degradation.<sup>21</sup>

Two genes coding for enzymes capable of cleaving trans-1,4 polyisoprene were identified: RoxA<sup>22</sup> and Lcp (Latex clearing protein).<sup>23</sup> Several homologous genes have been found in the genome of *Actinomyces* (i.e. *Streptomyces*, *Gordonia polyisoprenivorans*)<sup>24</sup> which are generally related to endodontic treatment failures and may be responsible for a faster degradation of the GP cone, apical seal, and 3D-endodontic filling. Analysis of the residual weight of a sample of cis-1,4-polyisoprene degraded by bacteria showed a weight loss of about 18% after 10 weeks of incubation at 30°C.<sup>25</sup> Moreover, the GP cone was more porous, reducing its ability to properly seal the canal.<sup>26</sup>

The GP resorption can also be triggered by uncontrolled heat sources that accelerated aging<sup>18,26</sup>. Ferreira et al<sup>26</sup> showed the presence of OH

and C=O groups after the use of warming GP techniques, particularly at temperatures of 140°C.

The GP extrusion can be problematic for maxillary teeth, especially molars. Although in rare case reports, extruded GP ended up inside the maxillary sinus, determining inflammation of the sinus membrane and subsequent sinusitis.<sup>27,28</sup> In some cases, this iatrogenic sinusitis can be resolved only with surgical removal of the extruded GP.

The long-term radiographic behaviour of GP extrusion is often ambiguous, depending on its radiopacity. The radiopacity of GP cones was shown to range from 7.25-7.53 mm Al,<sup>29,30</sup> comparable to some commercial sealers.<sup>31,32</sup>

### Sealer Extrusion

According to the American Dental Association, material extrusion exceeding 2 mm beyond the radiographic apex is considered a technical error in root canal therapy. This is attributed to the inherent cytotoxicity of all sealers to periradicular tissues, regardless of their type or formulation.<sup>33</sup> However, in cases of resorbed roots due to inflammatory processes or wide apices, extrusion can be particularly difficult to prevent.

Anatomical factors and certain obturation techniques—such as those involving heated GP, higher sealer fluidity, or larger apical

diameters—can increase the risk of extrusion.<sup>34,35</sup> Furthermore, specific methods of sealer application, such as the use of applicator syringes, may contribute to material extrusion if not performed correctly.<sup>36</sup>

### Sealer Typologies and Composition

The chemical composition of different sealers influences their physicochemical properties and adverse effects when in contact with periapical tissues.

Root canal sealers can be classified in zinc oxide eugenol (ZOE)-based sealers, calcium hydroxide-based cements, epoxy resin-based cements, glass-ionomer-based sealers, silicone-based sealers<sup>37</sup> and, lately, hydraulic calcium-silicate sealers (HCSC).

A brief description of sealer composition and biological effects on cells is provided: the first sealers could be defined as traditional bioinert sealers—materials specifically designed to remain stable after setting and not to exert any reaction in the periapical tissues, according to International Organization for Standardization (ISO) 6876/12. The HCSC are on the other hand defined as bioactive sealers because they are designed to promote a positive reaction to bone and periapical tissues.<sup>38,39</sup>

### Traditional Sealers

#### Zinc Oxide Eugenol–Based Root Canal Sealers

For many years, zinc oxide and eugenol cement has been widely used both with warm vertical compaction techniques and cold obturation techniques. In addition to its main components, zinc oxide and eugenol, it contains barium sulfate and bismuth dioxide as radiopacifying agents.<sup>40,41</sup> The eugenol component of these materials greatly influences its biological properties, and it is highly irritant when apically extruded according to a number of clinical and laboratory studies.<sup>35,42-44</sup> Generally, these sealers are stable in the short term, but some cases of radiographical disappearance at the apical portion of the root canal were observed after 4 years.<sup>45</sup>

#### Calcium Hydroxide–Based Root Canal Sealers

These sealers release  $\text{Ca(OH)}_2$  with bactericidal effects and are available as powder-liquid (CRCS) or paste-paste (Sealapex, Apexit, and Apexit Plus) formulations. The CRCS is a zinc oxide and eugenol-based sealer containing eucalyptol, an antibacterial agent, and calcium hydroxide; Sealapex has a base paste containing zinc oxide, calcium hydroxide, butylbenzene, sulfonamide, and zinc stearate, and a catalyst paste with fillers and radiopacifying agents (barium sulfate and titanium dioxide); Apexit and Apexit Plus have an activator paste (disalicylate, bismuth hydroxide) and a base paste consisting of calcium hydroxide, hydrated colophonium, and fillers. Generally, these sealers have high solubility as reported in both *in vitro* studies.<sup>46,47</sup> Certain formulations (Sealapex) reported irregular setting and poor adhesion capabilities.<sup>46,47</sup>

#### Epoxy Resin-based Root Canal Sealers

Epoxy resin-based sealers have an excellent marginal sealing ability even in the presence of smear layer, increased radiopacity making it more visible radiographically, and greater flowability with effective penetration into the dentinal tubules and accessory canals. The AH Plus is the most widely used epoxy resin-based cement; it consists of an epoxy paste based on a diepoxide (bisphenol A diglycidyl ether) and fillers, and an amine paste containing a primary monoamine,

a secondary diamine, silicone oil, and fillers.<sup>48,49</sup> This sealer demonstrated initial cytotoxicity due to the release of amine in periapical tissue. However, after its complete set (24-48 hours), the materials remain stable and unaltered in the tissues according to clinical and laboratory investigations.<sup>32,42,43</sup>

### Glass-ionomer Based Sealers

The ISO refers to this cement as a “glass polyalkenoate cement” because it is formed by polymeric water-soluble acids, basic aluminosilicate glasses containing fluoride and phosphate, and water. The element that increases the radiopacity of the sealers is strontium (Sr), which replaces calcium within the glass structure.<sup>50</sup> A glass-ionomer used as a root canal sealer (e.g., Vitrebond) contains a hydrophilic methacrylate group and forms a bond stronger than that of ZOE. Additionally, the HEMA component of the sealer, combined with its good flowability, allows the cement to penetrate dentinal tubules effectively.<sup>51</sup>

Their main feature is the long-term release of fluoride and calcium ions, which is beneficial for dentin remineralisation; for this reason, glass-ionomer sealers are considered bioactive.<sup>52</sup> Glass-ionomer based sealers show low cytotoxicity toward periapical tissues: as demonstrated by Uçok et al<sup>53</sup>, when Ketac-Endo is implanted in bone, it does not stimulate an osteoclastic response, which allows bone to grow in proximity without the interposition of fibrous tissue.

### Silicone-based Sealers

There are different formulations of silicone-based sealers that vary in composition and physicochemical properties. One of the first silicone-based sealers was RoekoSeal, which is composed of polydimethylsiloxane, silicone, paraffin oil, and zirconium dioxide as a radiopacifier. A few years later, the same company developed GuttaFlow, which is based on the same formulation as RoekoSeal, but with the addition of finely milled GP particles.<sup>44</sup>

Silicone-based sealers exhibit excellent sealing ability, low solubility, and reduced cytotoxicity.<sup>54,55</sup> One of the limitations of these sealers is their variable setting time, which can be affected by the presence of moisture or sodium hypochlorite in the root canal.<sup>56</sup>

The latest product released by the same company in 2015 is a silicone-based sealer composed of polydimethylsiloxane combined with GP particles and bioglass powders (Guttaflow Bioseal).<sup>57</sup> The bioglass particles enhance the bioactive properties of the material<sup>58</sup>: according to previous studies,<sup>40,59</sup> GuttaFlow Bioseal can promote the differentiation of human periodontal ligament stem cells into cementoblast-like cells, thereby increasing the regenerative potential for periapical tissues. A recent study compared this sealer with a silicone-based material (GuttaFlow2) and an epoxy resin-based sealer (AH Plus), revealing that GuttaFlow Bioseal induced less inflammation in the first week. Interestingly, a higher macrophage infiltration was initially noted for the bioglass-enriched sealer.<sup>60</sup>

### Bioactive Sealers

#### Hydraulic Calcium Silicate-based Sealer

The first to be used in endodontics was MTA (Mineral Trioxide Aggregate), which, due to a prolonged setting time, low radiopacity, and poor handling as an endodontic sealer, was replaced by a second generation of calcium silicate cements with improved physicochemical characteristics.<sup>38,39</sup>

Pro-Root MTA (Mineral Trioxide Aggregate) was one of the first hydraulic cements studied and analysed. It is a hydraulic calcium-silicate cement derivative of a type I ordinary Portland cement with 4:1 proportions of bismuth oxide added for radiopacity. ProRoot MTA cement exhibits high bioactivity, as evidenced by the rapid formation of a calcium phosphate-rich layer containing apatite nano-spherulites within hours of exposure to a phosphate-containing solution.<sup>61</sup>

The excellent bioactivity of ProRoot MTA provided significant clinical advantages over traditional cements for certain dental applications like root-end material in endodontic surgery and/or root repair material in perforations.<sup>61</sup>

The properties of these materials were tested also by environmental scanning electron microscopy connected with ESEM-EDX. There was the discovery of apatite spherulites on calcium silicate cements.<sup>62</sup> Fresh cements showed higher cell proliferation than aged cements, probably favored by the presence of Si-OH gel and by the early formation of apatite nano-spherulites.

### Premixed Calcium Silicate Cements

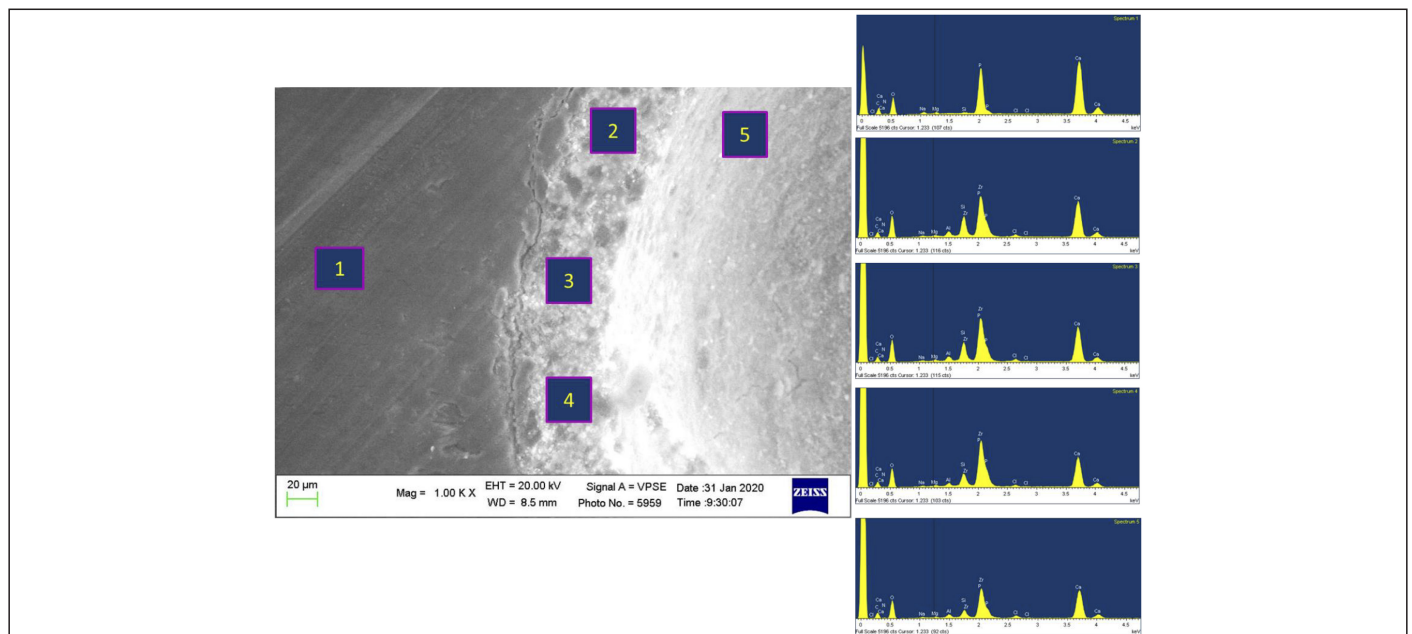
These sealers are designed as ready-to-use material in a single compartment, which still requires water to initiate its setting reaction. Premixed cements have an “external water supply,” while automix and powder-liquid formulations have an “internal water supply.” These materials are usually referred to by the term “bioceramic,” highlighting their high biocompatibility and their composition, with the presence of metallic elements (i.e., radiopacifiers) and a non-metallic one (calcium silicates or calcium phosphates). All formulations of calcium silicate cements contain a certain percentage of tricalcium silicate (alite) up to a maximum of 35%, and only some contain dicalcium silicate (belite) from 5% to 15%, which increases the amount of silicates present. The bioactivity and solubility of the material are directly influenced by the percentages of alite and belite present within it.<sup>53-65</sup>

These materials exhibit several biologically advantageous properties, including antimicrobial activity due to increased pH in the microenvironment. Studies<sup>38,39,63,66</sup> demonstrated their ability to bond with dentin by forming a porous structure that facilitates the diffusion of  $\text{Ca}^{2+}$ ,  $\text{OH}^-$ , and  $\text{CO}_3^{2-}$  ions (Figure 2). These ions contribute to the formation of B-type carbonate-apatite, a non-stoichiometric form of hydroxyapatite with carbonate groups substituting for phosphate groups. This distinct composition makes it particularly active in tissue metabolism.<sup>64</sup>

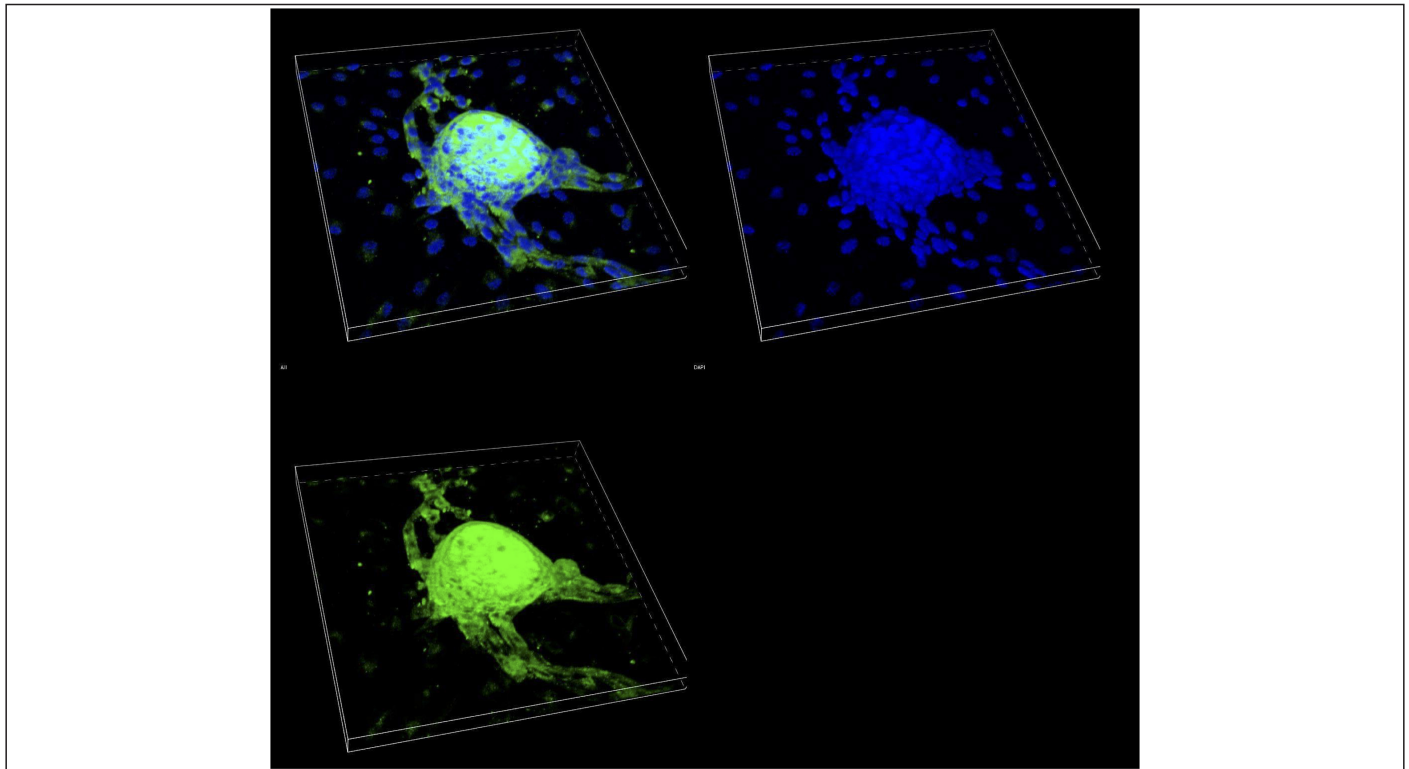
Calcium silicate sealers can also interact with periapical cells enhancing bone healing. The periapical area has a high number of multipotent cells,<sup>67</sup> a vast vascular network, and mesenchymal stem cells (VW-MSCs)<sup>68-74</sup> with direct<sup>75,76</sup> and indirect<sup>77</sup> roles in bone regeneration. Animal model studies have confirmed that the differentiation of VW-MSCs can be enhanced by the presence of various biomaterials containing calcium phosphates, calcium silicates, and bioglass.<sup>78-85</sup> Ceraseal, AH Plus Bioceramic, and Endosequence BC fully support the colonisation by VW-MSCs and induce their differentiation in the osteogenic direction through significant expression of osteopontin, a protein expressed in the early and final stages of osteoblastic differentiation.<sup>85-87</sup> Figure 3 demonstrates the osteoblastic differentiation of 1 MSC population when cultured in contact to 1 premixed Bioceramic sealer.

Similarly, the release of silicates and calcium ions from these materials promotes the adhesion and proliferation of MSCs<sup>84</sup> and stimulates the production of bone-associated proteins<sup>77,88</sup> unlike hydrophobic and non-bioactive sealers such as AH Plus.<sup>89</sup>

Tricalcium silicates are capable of establishing a direct bond with the osteoid matrix deposited on the surface of the material extruded by VW-MSCs differentiated into osteoblasts.<sup>90</sup> For some of these cements, such as MTA Plus and ProRoot MTA, direct contact with



**Figure 2.** ESEM-EDX analysis of the apical portion of 1 endodontically treated incisor filled with Ceraseal and Single cone. The tooth was extracted due to coronal root fracture 3 months after filling. The analysis reports an adaptation of the sealer to the root canal and an interface with high presence of Ca and P and low percentage of Si, suggesting the formation of a layer of calcium phosphate and a “hybrid” interface sealer root. One continuous micro gap (1-2 microns) between the sealer and the root was also detected.



**Figure 3.** CLSM images (200x magnification) of cultured MSCs in contact to 1 premixed bioceramic sealer after 21 days. It is possible to observe the differentiation and migration of these cells, forming 1 mineralised core. Immunostaining of osteocalcin (green signal) and counterstaining of cell nuclei through DAPI.

native bone has been observed, with no interposition of connective tissue or presence of necrotic areas.<sup>90</sup>

Premixed calcium silicate sealers can induce mesenchymal cell migration, promote osteogenic differentiation, reduce levels of pro-inflammatory cytokines (TNF- $\alpha$  and IL-6), and support macrophage polarisation from a pro-inflammatory M1 phenotype to an M2 phenotype. This M2 phenotype enhances fibroblastic cell proliferation promoting periapical healing. A recent *in vivo* study also confirmed that premixed calcium silicate sealers formulated to be used with warm obturation protocols, such as BC Sealer HiFlow, are biocompatible, being able to induce the formation of fibrous capsules and promoting mineralisation over time.<sup>91</sup>

Despite their many benefits compared to other root canal sealers, calcium silicate-based sealers seem to have some limitations, including extended setting times, lower radiopacity, and *in vitro* high solubility.

### Sealer Extrusion and Post-treatment Healing

Apical sealer extrusions can negatively impact post-treatment healing outcomes when associated with incomplete 3-dimensional obturation of the endodontic space (overextension) or when correlated with a diagnosis of periapical periodontitis at the initial radiographic evaluation. Overextensions determine an incomplete apical seal and root canal filling. One previous study analysed the periapical lesions in failed root canal treatments<sup>92</sup> revealing root canal sealer remnants encapsulated in fibrous tissue. The incomplete constitution of periapical bone tissue may be due to the sealer cytotoxicity toward periapical tissues and/or development of a foreign body reaction. Data from a number of previous studies showed no significant differences in healing outcomes linked to the type of extruded

sealers; however, HCSC or new premixed sealers were not included in comparisons.<sup>33,35,93-95</sup>

### Sealer Extrusion and Post-treatment Pain

Postoperative pain data in endodontics vary from 3% to 58% in different studies,<sup>96</sup> with a higher incidence in teeth that have 3 or more canals.<sup>97,98</sup> Post-treatment pain can be associated with different factors (rubber dam clamp, local anaesthetics, prolonged mouth opening) including the composition of the sealer and the technique used to obturate the root canal.<sup>99</sup> A significant correlation has been established between the extent of extrusion and the onset of clinical symptoms,<sup>96</sup> for a local inflammatory response in periapical tissues.<sup>96,100,101</sup>

A number of studies reported no statistically significant results in supporting the concept that sealer extrusion is related to post-operative pain. However, the difference in sealer composition is widely considered a predisposing factor.<sup>102,103</sup> Higher incidence rates of post-treatment pain have been reported with the extrusion of epoxy resin-based sealers (AH Plus) compared to other sealers.<sup>104,105</sup>

As for pain duration, 1 study<sup>102</sup> shows that after 24 hours, the percentage of pain-free patients in the group treated with a resin-based sealer is 53%, compared to 65% in the group treated with a premixed sealer. After 48 hours, the percentage difference remains fairly stable, with 78% in the resin-based sealer group and 93% in the premixed sealer group.<sup>102</sup>

Eugenol in ZOE-based sealers was also related to post-operative pain when apically extruded.<sup>93</sup> Ruparel et al<sup>100</sup> demonstrated that eugenol is a potent activator of 2 receptors in trigeminal neurons, TRPV1 and TRPA1, which mediate peripheral pain caused by thermal

and inflammatory stimuli and are responsible for significant release of calcitonin gene-related peptide (CGRP). A similar behaviour was observed for the AH Plus. In contrast, tricalcium silicate-based sealers (Total Fill BC) did not activate these receptors but also reduced basal CGRP levels.<sup>106</sup>

**Sealer Extrusion and Neurological Complications**

Only a few case series and reports in the literature discuss the incidence and prognosis of neurological injuries caused by sealer extrusion. However, these cases often resolve spontaneously within a few days after treatment completion (Figure 4). An important key point is to establish a correct working length and a correct apical gauging. Moreover, selecting a sealer with minimal neurotoxic effects, such as calcium silicate-based sealers, can reduce the risk.<sup>107</sup>

**Fate of Extruded Sealer**

Extruded sealer beyond the apex could be solubilised by periapical tissue fluids, phagocytised by macrophages, or encapsulated within fibrous connective tissue. These physical, chemical, and biological processes are closely linked to the type and quantity of extruded material.<sup>35</sup> In the following paragraphs, the various biological and clinical factors that may be involved in the resorption of the extruded sealer over time were analysed. Table 1 summarises the main different clinical and biological features of the different sealer typologies.

**Solubilisation of Sealer**

The extent of material solubilisation depends on its physico-chemical properties, particularly its dimensional stability.<sup>57,108</sup> High

dimensional stability involves a stable seal of the root canal system,<sup>109</sup> whilst dissolution of the sealer due to increased solubility may determine fluid percolation, promoting bacterial growth in the root canal system.<sup>35</sup>

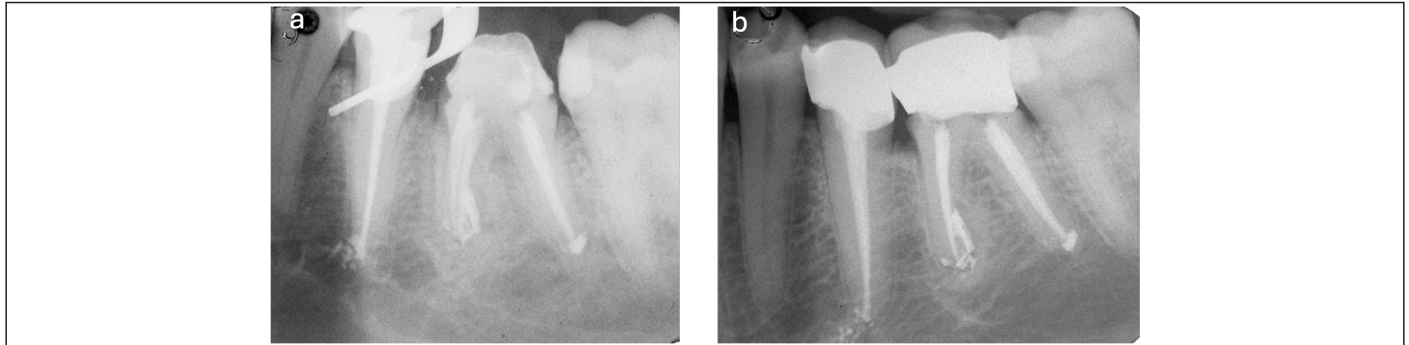
AH Plus exhibits low in vitro solubility due to cross-linking in its resin polymers, clinically confirmed in the frequent radiographic detection of the cement over time (Figure 5).<sup>110</sup>

When compared to calcium hydroxide-based sealers (e.g., Apexit) or zinc oxide-eugenol sealers (e.g., Pulp Canal Sealer), AH Plus demonstrates significantly lower solubility. Apexit and Pulp Canal Sealer show higher solubility values, resulting in greater removal rates over time. However, despite showing high solubility, Apexit exhibits fewer dimensional changes compared to other calcium hydroxide-based sealers (CRCS and Sealapex).<sup>111</sup>

Despite poor stability, Sealapex showed a greater deposition of mineralised tissue and prevents the onset of an inflammatory reaction at the periapical level<sup>112</sup>; this is attributed to the higher release of calcium ions and to the higher alkalinity values reached compared to other cements.<sup>112</sup>

Silicone-based sealers (GuttaFlow Bioseal) show significantly lower solubility when compared to zinc oxide and eugenol-based sealers.<sup>113</sup>

The HSCS show a slight expansion during the first week, primarily due to their intrinsic hydrophilic properties rather than calcium

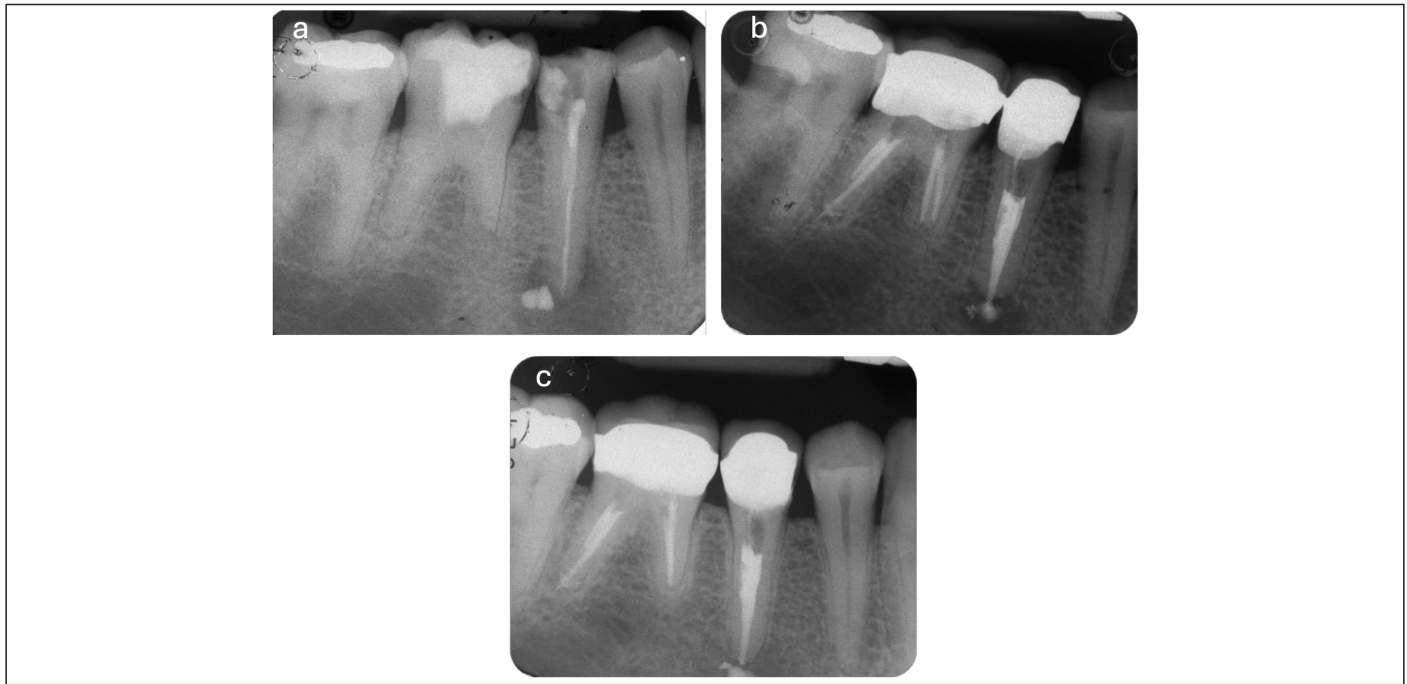


**Figure 4.** (a) Extrusion of an epoxy resin-based sealer (AH Plus) occurred near the emergence of the alveolar nerve. Temporary paraesthesia developed 5 days after the filling procedure, likely due to the proximity of the apical area to the alveolar nerve. The symptoms subsequently subsided, and no further complications were observed (b).

**Table 1.** Overview of the Different Clinically and Biological Features of Various Sealers Typologies

Features and Sealer Typologies	ZOE	Epoxy-resin based	Calcium-hydroxide-based	Silicone based	Glass Ionomer	MTA	Premixed Hydraulic Calcium Silicate
Pain upon extrusion	+	±	+	nr	nr	nr	-
Radiopacity	+	++	+	-	-	-	++
Apical resorption	+	-	±	-	-	nr	++
Biological activity	+	-	++	nr	nr	++	++
Phagocytosis	+	nr	nr	nr	nr	-	±
Solubility	+	-	++	-	nr	-	++
Neurotoxicity	++	+	±	nr	nr	+	++

The symbol (+) indicates that studies have reported a positive correlation with the corresponding feature. The symbol (±) denotes the presence of conflicting findings in the literature. The symbol (-) indicates that studies have shown a negative correlation with the corresponding feature. The abbreviation "nr" stands for "not reported" indicating that no relevant data were provided in the referenced study.



**Figure 5.** Apical extrusion of epoxy resin-based sealer. The extruded material remained unchanged at both 6 months (b) and 48 months (c); nevertheless, periapical healing was observed.

or phosphate precipitation.<sup>114</sup> It has been observed that hydraulic cements with rapid setting times show a faster formation of CSH, resulting in reduced solubility and increased compactness of the material, which in turn enhances its radiopacity values.<sup>115,116</sup> However, a number of clinical studies evidenced high in vitro solubility values for both HCSC and premixed sealers, possibly linked to water adsorption and high porosity values.<sup>29,38,39,49</sup> These concepts could have a clinical reason when considering sealer extruded in the periapical area, a region with high moisture and often with an acidic pH (such in presence of active periapical lesions). Acidic pH and excessive moisture are known factors that could lead to a non-complete setting of HCSC and wash-out.<sup>117,118</sup>

### Phagocytosis and Circulatory Influence

Another mechanism of material resorption is macrophage-mediated phagocytosis. Extruded sealers determine a macrophage response, transforming into giant cells. These giant cells could contribute to the development of refractory periapical lesions.<sup>10,103</sup> It has been noted that zinc oxide-eugenol-based cements are less prone to fragmenting into smaller particles for phagocytosis by macrophages,<sup>119</sup> and over longer periods of time, they may be surrounded by fibrous connective tissue.<sup>120</sup>

The circulatory system also plays a role in reducing the presence of extruded sealer, distributing via the bloodstream and lymphatic system. However, no inflammatory reactions have been reported in remote sites following this distribution.<sup>121</sup> No recent studies have investigated these effects on newly developed sealers; therefore, some variations could be expected towards new sealers.

### Bioactivity and Osteoclastic Activation

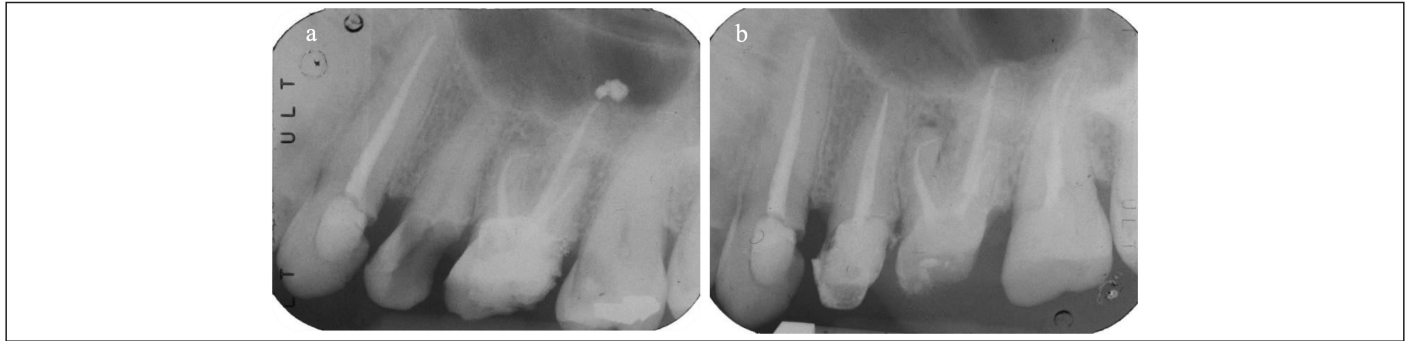
Only HCSC and premixed bioceramic sealers can be reabsorbed from osteoclasts,<sup>38</sup> but the alkalising activity of these materials inhibits the recruitment and activation of osteoclasts, reducing their resorption in physiological conditions.<sup>122-124</sup>

### Dissolution of Radiopacifying Agents

Clinically apparent sealer resorption may result from the dissolution of radiopacifying agents such as barium sulfate or bismuth oxide. These agents can diffuse into the extrusion area, potentially altering its morphology, or be absorbed by cells that transport them to other organs for elimination.<sup>125,126</sup> Animal models on ProRoot MTA<sup>126</sup> have shown that bismuth oxide is released into connective tissues due to its reactivity with collagen fibers and blood.<sup>126,127</sup> Moreover, bismuth oxide binds silicate reticular sites increasing its stability.<sup>128</sup> Although other radiopacifying agents do not participate in the setting reaction of a sealer,<sup>129</sup> a more or less elevated percentage of them ends up accumulating within the periapical tissues and at the renal level.<sup>126,127</sup> A particularly interesting result of Janini et al<sup>130</sup> concerns 2 cements (Bio-C Repair and EndoSequence BC RRM Putty) containing the same radiopacifying agent (zirconium oxide). Despite their compositional similarity, the 2 materials exhibited markedly different biological and systemic behaviours. In Bio-C Repair the concentrations of zirconium oxide at the renal level were found to be significant whilst for EndoSequence BC no renal presence of radiopacifier was observed, speculating that volumetric stability may lead to a more effective persistence of the radiopacifying agent within the matrix. A probable correlation could be established between the release pattern of radiopacifiers and the composition of the matrix of various sealers, their dimensional stability and possible systemic implications of accumulation in other organs.<sup>130</sup> Figure 6 reports an emblematic radiographic disappearance of apically extruded materials 12 months after filling procedures.

### Radiographic Persistence of Sealers

All previously discussed mechanisms can lead to resorption of the extruded sealer over time. From a radiographic point of view, this can be evaluated only in a loss of radiopacity of extruded material. Clinical data of apical extrusion events and the radiographical disappearance have been analysed by authors in relation to the sealer typology are reported in Table 2.



**Figure 6.** Apical extrusion of a premixed bioceramic sealer (NeoSealer Flo). (a) Periapical extrusion is evident in the 12-month follow-up radiograph. (b) The extruded material was completely resorbed, and bone healing was observed in the palatal root canal.

Resorption of an extruded sealer is significantly correlated with both the position of the affected tooth and the follow-up time considered: a significantly greater resorption, in fact, is more frequently described for posterior teeth and follow-up periods of 4 years or longer.<sup>131</sup> Over time, different sealers exhibit distinct radiographic behaviours:

- Zinc oxide-eugenol-based sealers: demonstrate significant radiographic disappearance, with 69% resorption of total extrusions observed at 4 years.<sup>45</sup>
- Resin-based sealers: epoxy-resin based sealers (AH Plus) show no resorption at 2 years of follow-up.<sup>32</sup>
- Glass-ionomer sealers<sup>132</sup> and silicone-based sealers<sup>133</sup>: no resorption was observed after 1 year
- Calcium hydroxide-based sealers: specific data for the Sealapex sealer<sup>134</sup> show that in about 58% of cases, the extruded material is completely resorbed within 1 year; in the remaining cases, traces of the material were found even at 3 years of follow-up.<sup>134</sup> Some studies<sup>135</sup> on Sealapex samples observed the presence of large cavities within the material's structure once hardened, which gradually disappeared over time, resulting in an increase in radiopacity values.
- Hydraulic calcium silicate sealers: the modification of radiopacity of calcium silicate hydraulic cements can be associated with the nucleation of calcium phosphates and formation of biological hydroxyapatite. This process gradually fills the voids, leading to a reduction in overall porosity.<sup>4,136</sup> However, both nucleation of apatite—having similar radiopacity values of mineralised tissues—and the progressive removal of the radiopacifier from

the bone tissue due to macrophage activity lead to a reduction of the radiopacity values in the periapical area.

- Premixed bioceramic sealers display variable resorption rates depending on their formulation. Specific findings include:

*Endosequence BC Sealer:* Exhibited a 10% resorption rate at 36 months of follow-up.<sup>137</sup>

*Ceraseal and AH Plus Bioceramic:* Showed a 50% resorption rate at 24 months.<sup>32,138</sup>

*BioRoot RCS:* Demonstrated no radiographic resorption over time, aligning with its high dimensional stability and bioactivity.<sup>139</sup>

*Total Fill BC Sealer:* Showed significant increases in radiopacity within the first 24 hours. Over the next 28 days, the mmAI values increase slightly.<sup>114</sup>

*Grey-MTAFlow:* the increase in radiopacity within the first 24 hours and the following 28 days is similar but lower compared to Total Fill BC Sealer.<sup>114</sup> Total Fill BC Sealer exhibits a more efficient precipitation process with lower solubility levels.<sup>38,114</sup>

### Knowledge Gaps and Research Priorities

The fate of extruded sealer has been mainly investigated in clinical studies by means of bidimensional radiographical analyses. This may result in biases and misinterpretation of the clinical events occurring in the periapical areas.

**Table 2.** Summary of Radiographic Behaviours of Various Endodontic Sealers Over Time, Including Resorption Rates, Type of Sealer, and Follow-up Duration of the Single Study

Sealer Type	Resorption Rate% (n/Extrusions)	Extrusion % (n/Total)	Follow-up Time (years)
Zinc-Oxide eugenol (ZOE) <sup>41</sup>	69 (41/59)	64 (59/92)	4
Epoxy resin-based <sup>32</sup>	0 (0/39)	0 (0/39)	2
Glass ionomer <sup>132</sup>	0 (0/378)	0 (0/378)	1
Silicone based <sup>133</sup>	0 (0/156)	0 (0/156)	1
Calcium-hydroxide-based <sup>134</sup>	58 (10/19)	31 (19/62)	1
Premixed hydraulic calcium silicate			
Endosequence BC <sup>137</sup>	16 (48/146)	47 (146/307)	3
Ceraseal <sup>32</sup>	50 (3/6)	13 (6/44)	2
AH Plus bioceramic <sup>138</sup>	50 (9/18)	47 (18/38)	2
BioRoot RCS <sup>139</sup>	0 (0/55)	0 (0/55)	1

The radiographical disappearance of extruded sealer on the radiograph does not automatically mean that it was completely removed from the periradicular tissues. The amount of material or its density may have been reduced to a point that it cannot be discerned on a periapical radiograph.<sup>35</sup> Nevertheless, it demonstrates active biological events that occurred in the periapical area on sealers with a specific chemical composition.

Three-dimensional analyses could be useful to accurately assess the dissemination and migration of extruded sealers. Clinically, CBCT has shown greater diagnostic accuracy and the ability to reveal lower success and healing rates under strict criteria compared with periapical radiographs.<sup>140</sup> However, despite this potential, the routine clinical use of CBCT for such purposes is not justified because of ethical considerations, including the as low as reasonably achievable (ALARA) principle and the higher radiation dose when compared with conventional radiography. Laboratory investigations may benefit from standardised micro CT investigations on the migration of any unset material in the bone tissue.

Finally, histological studies and ex vivo research should be more focused on the biological events that occur when sealer is extruded in bone tissues and to evaluate these events in different clinical simulations (periapical bone with no periapical lesions or periapical bone with active or chronic periapical lesions). Ex vivo analysis of apatite nucleation of the sealers, not only in vitro laboratory research, could be useful to exactly know the events occurring in the periapical apex.

## CONCLUSIONS

Clinicians should be aware of the type of material used for root canal filling. The apical extrusion of some sealers might have implications for post-operative pain and outcome. In the presence of extrusion risk factors such as a resorbed apex, it is recommended for the clinician to use materials that can potentially cause less pain in the following days, highly biocompatible and with low solubility.

In all cases, material extrusion exceeding 2.0 mm is an undesired event and correct management of working length and apical gauging is important to reduce this risk.

Radiographic monitoring remains a valuable method to evaluate the persistence of extruded sealers over time. Clinicians should interpret bidimensional radiographic findings with caution because the apparent disappearance or changes in the radiographic image do not necessarily correlate with the material resorption or transformation at the histological level.

Well-structured in vivo studies are needed, especially for newly developed sealers. Randomised clinical and radiological follow-up could help clinicians better understand their physicochemical behaviour and potential biological risks in cases of sealer extrusion. The establishment of a standardised terminology will be important to accurately describe these phenomena and to prevent misinterpretation or inconsistency in future investigations.

## Disclosures

**Data Availability Statement:** The data that support the findings of this study are available on request from the corresponding author.

**Peer-review:** Externally peer-reviewed.

**Author Contributions:** Concept – F.Z., C.P.; Design – F.Z., A.S.; Supervision – C.P.; Resources – C.P.; Materials – F.Z., A.S.; Data Collection and/or Processing – S.P., F.Z.; Analysis and/or Interpretation – A.S., F.Z.; Literature Search – S.P., F.Z.; Writing – F.Z., A.S.; Critical Review – L.G., A.B., M.G.G.

**Declaration of Interests:** The authors have no conflicts of interest to declare.

**Funding:** The authors declare that this study received no financial support.

## REFERENCES

1. American Association of Endodontists. *Glossary of Endodontic Terms*. 10th ed. Chicago: 2020.
2. Dummer PM, McGinn JH, Rees DG. The position and topography of the apical canal constriction and apical foramen. *Int Endod J*. 1984;17(4):192-198. [CrossRef]
3. Ponce EH, Vilar Fernández JA. The cemento-dentino-canal junction, the apical foramen, and the apical constriction: evaluation by optical microscopy. *J Endod*. 2003;29(3):214-219. [CrossRef]
4. Ricucci D, Langeland K. Apical limit of root canal instrumentation and obturation, part 2. A histological study. *Int Endod J*. 1998;31(6):394-409. [CrossRef]
5. Ferrari R. Writing narrative style literature reviews. *Med Writing*. 2015;24(4):230-235. [CrossRef]
6. Pelepenko LE, Hewitt B, de Oliveira RB, et al. Bismuth release from endodontic materials: proposed mechanisms for systemic circulation and organ accumulation. *J Hazard Mater*. 2025;494:138580. [CrossRef]
7. Tavares T, Soares IJ, Silveira NL. Reaction of rat subcutaneous tissue to implants of gutta-percha for endodontic use. *Endod Dent Traumatol*. 1994;10(4):174-178. [CrossRef]
8. Taddei P, Di Foggia M, Zamparini F, Prati C, Gandolfi MG. Guttapercha improves in vitro bioactivity and dentin remineralization ability of a bio-glass containing polydimethylsiloxane-based root canal sealer. *Molecules*. 2023;28(20):7088. [CrossRef]
9. Gutiérrez JH, Gigoux C, Escobar F. Histologic reactions to root canal fillings. *Oral Surg Oral Med Oral Pathol*. 1969;28(4):557-566. [CrossRef]
10. Nair PN, Sjögren U, Krey G, Sundqvist G. Therapy-resistant foreign body giant cell granuloma at the periapex of a root-filled human tooth. *J Endod*. 1990;16(12):589-595. [CrossRef]
11. Malagnino VA, Pappalardo A, Plotino G, Carlesi T. The fate of overfilling in root canal treatments with long-term follow-up: a case series. *Restor Dent Endod*. 2021;46(2):e27. [CrossRef]
12. Sjögren U, Sundqvist G, Nair PN. Tissue reaction to gutta-percha particles of various sizes when implanted subcutaneously in guinea pigs. *Eur J Oral Sci*. 1995;103(5):313-321. [CrossRef]
13. Aziz ZAC A, Kutty MG, Abu Kasim NH, Al-Haddad AYM. *Bioactive Coated Gutta-Percha as Root Canal Filling Matter*. 2016;International patent WO 2016/039616 A1.
14. Sampaio RF, Carvalho CN, Bradaschia-Correa V, et al. Apical sealing and bioactivity of an experimental gutta-percha containing niobium phosphate bioglass. *Polymers (Basel)*. 2023;15(7):1679. [CrossRef]
15. Pascon EA, Spångberg LS. In vitro cytotoxicity of root canal filling materials: 1. Gutta-percha. *J Endod*. 1990;16(9):429-433. [CrossRef]
16. Moorer WR, Genet JM. Antibacterial activity of gutta-percha cones attributed to the zinc oxide component. *Oral Surg Oral Med Oral Pathol*. 1982;53(5):508-517. [CrossRef]
17. Moorer WR, Genet JM. Evidence for antibacterial activity of endodontic gutta-percha cones. *Oral Surg Oral Med Oral Pathol*. 1982;53(5):503-507. [CrossRef]
18. Bode HB, Kerkhoff K, Jendrosseck D. Bacterial degradation of natural and synthetic rubber. *Biomacromolecules*. 2001;2(1):295-303. [CrossRef]
19. Sato S, Honda Y, Kuwahara M, Watanabe T. Degradation of vulcanized and nonvulcanized polyisoprene rubbers by lipid peroxidation catalyzed by oxidative enzymes and transition metals. *Biomacromolecules*. 2003;4(2):321-329. [CrossRef]
20. Somers AE, Bastow TJ, Burgar MI, Forsyth M, Hill AJ. Quantifying rubber degradation using NMR. *Pol Degrad Stab*. 2000;70(1):31-37. [CrossRef]
21. Silva Jr JBA, Paula RCM, Feitosa JPA, Gurgel-Filho ED, Maniglia-Ferreira C, Souza-Filho FJ. In vivo aging of guttapercha endodontic cone. *J Appl Pol Sc*. 2006;100:4082-4088.

22. Braaz R, Fischer P, Jendrossek D. Novel type of heme-dependent oxygenase catalyzes oxidative cleavage of rubber (poly-cis-1,4-isoprene). *Appl Environ Microbiol.* 2004;70(12):7388-7395. [\[CrossRef\]](#)
23. Rose K, Tenberge KB, Steinbüchel A. Identification and characterization of genes from *Streptomyces* sp. strain K30 responsible for clear zone formation on natural rubber latex and poly(cis-1,4-isoprene) rubber degradation. *Biomacromolecules.* 2005;6(1):180-188. [\[CrossRef\]](#)
24. Hiessl S, Böse D, Oetermann S, Eggers J, Pietruszka J, Steinbüchel A. Latex clearing protein—an oxygenase cleaving poly(cis-1,4-isoprene) rubber at the cis double bonds. *Appl Environ Microbiol.* 2014;80(17):5231-5240. [\[CrossRef\]](#)
25. Enoki M, Doi Y, Iwata T. Oxidative degradation of cis- and trans-1,4-polyisoprenes and vulcanized natural rubber with enzyme-mediator systems. *Biomacromolecules.* 2003;4(2):314-320. [\[CrossRef\]](#)
26. Maniglia-Ferreira C, Bönecker G, Silva JB Jr, de Paula RC, Feitosa JP, Souza-Filho FJ. Degradation of trans-polyisoprene after root filling with thermoplasticized techniques. *Int Endod J.* 2008;41(4):296-302. [\[CrossRef\]](#)
27. Ishikawa M, Mizuno T, Yamazaki Y, Satoh T, Notani K, Fukuda H. Migration of gutta-percha point from a root canal into the ethmoid sinus. *Br J Oral Maxillofac Surg.* 2004;42(1):58-60. [\[CrossRef\]](#)
28. Ektefaie MR, David HT, Poh CF. Surgical resolution of chronic tissue irritation caused by extruded endodontic filling material. *J Can Dent Assoc.* 2005;71(7):487-490.
29. Zamparini F, Siboni F, Prati C, Taddei P, Gandolfi MG. Properties of calcium silicate-monobasic calcium phosphate materials for endodontics containing tantalum pentoxide and zirconium oxide. *Clin Oral Investig.* 2019;23(1):445-457. [\[CrossRef\]](#)
30. Zamparini F, Lenzi J, Duncan HF, Spinelli A, Gandolfi MG, Prati C. The efficacy of premixed bioceramic sealers versus standard sealers on root canal treatment outcome, extrusion rate and post-obturation pain: a systematic review and meta-analysis. *Int Endod J.* 2024;57(8):1021-1042. [\[CrossRef\]](#)
31. Souza LC, Neves GST, Kirkpatrick T, Letra A, Silva R. Physicochemical and biological properties of AH Plus bioceramic. *J Endod.* 2023;49(1):69-76. [\[CrossRef\]](#)
32. Zamparini F, Spinelli A, Cardinali F, Ausiello P, Gandolfi MG, Prati C. The use of premixed calcium silicate bioceramic sealer with warm carrier-based technique: a 2-year study for patients treated in a master program. *J Funct Biomater.* 2023;14(3):164. [\[CrossRef\]](#)
33. Santoro V, Lozito P, Donno AD, Grassi FR, Introna F. Extrusion of endodontic filling materials: medico-legal aspects. Two cases. *Open Dent J.* 2009;3:68-73. [\[CrossRef\]](#)
34. Goldberg F, Artaza LP, De Silvio A. Effectiveness of different obturation techniques in the filling of simulated lateral canals. *J Endod.* 2001;27(5):362-364. [\[CrossRef\]](#)
35. Ricucci D, Rôças IN, Alves FRF, Loghin S, Siqueira JF Jr. Apically extruded sealers: fate and influence on treatment outcome. *J Endod.* 2016;42(2):243-249. [\[CrossRef\]](#)
36. Jasarasia N, Tikku AP, Bharti R. Analysis of porosity, sealer dissolution and apical extrusion of endodontic sealers: a micro computed tomography study. *J Oral Biol Craniofac Res.* 2023;13(4):495-499. [\[CrossRef\]](#) [published correction appears in *J Oral Biol Craniofac Res.* 2024;14(4):353-354. 10.1016/j.jobcr.2024.05.011]
37. Błaszczyk-Pośpiech A, Struzik N, Szymonowicz M, et al. Endodontic sealers and innovations to enhance their properties: a current review. *Materials (Basel).* 2025;18(18):4259. [\[CrossRef\]](#)
38. Prati C, Gandolfi MG. Calcium silicate bioactive cements: biological perspectives and clinical applications. *Dent Mater.* 2015;31(4):351-370. [\[CrossRef\]](#)
39. Camilleri J, Atmeh A, Li X, Meschi N. Present status and future directions: hydraulic materials for endodontic use. *Int Endod J.* 2022;55(Suppl 3):710-777. [\[CrossRef\]](#)
40. Allan NA, Walton RC, Schaeffer MA. Setting times for endodontic sealers under clinical usage and in vitro conditions. *J Endod.* 2001;27(6):421-423. [\[CrossRef\]](#) [published correction appears in Schaeffer A [corrected to Schaeffer MA]. *J Endod.* 2001;27(10):626. 10.1097/00004770-20011000-00007]
41. Kazemi RB, Safavi KE, Spångberg LS. Dimensional changes of endodontic sealers. *Oral Surg Oral Med Oral Pathol.* 1993;76(6):766-771. [\[CrossRef\]](#)
42. Kaur A, Shah N, Logani A, Mishra N. Biototoxicity of commonly used root canal sealers: a meta-analysis. *J Conserv Dent.* 2015;18(2):83-88. [\[CrossRef\]](#)
43. Jung S, Selker S, Hanisch MR, Libricht V, Schäfer E, Dammaschke T. Cytotoxic effects of four different root canal sealers on human osteoblasts. *PLoS One.* 2018;13(3):e0194467. [\[CrossRef\]](#)
44. Ørstavik D. Materials used for root canal obturation: technical, biological and clinical testing. *Endod Topics.* 2005;12(1):25-38. [\[CrossRef\]](#)
45. Augsburg RA, Peters DD. Radiographic evaluation of extruded obturation materials. *J Endod.* 1990;16(10):492-497. [\[CrossRef\]](#)
46. Desai S, Chandler N. Calcium hydroxide-based root canal sealers: a review. *J Endod.* 2009;35(4):475-480. [\[CrossRef\]](#)
47. Chang SW, Lee SY, Kang SK, Kum KY, Kim EC. In vitro biocompatibility, inflammatory response, and osteogenic potential of 4 root canal sealers: Sealapex, Sankin apatite root sealer, MTA Fillapex, and iRoot SP root canal sealer. *J Endod.* 2014;40(10):1642-1648. [\[CrossRef\]](#)
48. Bouillaguet S, Shaw L, Barthelemy J, Krejci I, Wataha JC. Long-term sealing ability of Pulp Canal Sealer, AH-Plus, GuttaFlow and Epiphany. *Int Endod J.* 2008;41(3):219-226. [\[CrossRef\]](#)
49. Gandolfi MG, Parrilli AP, Fini M, Prati C, Dummer PM. 3D micro-CT analysis of the interface voids associated with Thermafil root fillings used with AH Plus or a flowable MTA sealer. *Int Endod J.* 2013;46(3):253-263. [\[CrossRef\]](#)
50. Sidhu SK, Nicholson JW. A review of glass-ionomer cements for clinical dentistry. *J Funct Biomater.* 2016;7(3):16. [\[CrossRef\]](#)
51. Saunders WP, Saunders EM, Herd D, Stephens E. The use of glass ionomer as a root canal sealer—a pilot study. *Int Endod J.* 1992;25(5):238-244. [\[CrossRef\]](#)
52. Forsten L. Short- and long-term fluoride release from glass ionomers and other fluoride-containing filling materials in vitro. *Scand J Dent Res.* 1990;98(2):179-185. [\[CrossRef\]](#)
53. Uçok M. Biological evaluation of glass ionomer cements. *Int Endod J.* 1986;19(6):285-297. [\[CrossRef\]](#)
54. Collado-González M, Tomás-Catalá CJ, Oñate-Sánchez RE, Moraleda JM, Rodríguez-Lozano FJ. Cytotoxicity of GuttaFlow bioseal, GuttaFlow2, MTA Fillapex, and AH Plus on human periodontal ligament stem cells. *J Endod.* 2017;43(5):816-822. [\[CrossRef\]](#)
55. Kontakiotis EG, Tzanetakakis GN, Loizides AL. A 12-month longitudinal in vitro leakage study on a new silicon-based root canal filling material (Gutta-Flow). *Oral Surg Oral Med Oral Pathol Oral Radiol Endod.* 2007;103(6):854-859. [\[CrossRef\]](#)
56. Bouillaguet S, Wataha JC, Tay FR, Brackett MG, Lockwood PE. Initial in vitro biological response to contemporary endodontic sealers. *J Endod.* 2006;32(10):989-992. [\[CrossRef\]](#)
57. Gandolfi MG, Siboni F, Prati C. Properties of a novel polysiloxane-gutta-percha calcium silicate-bioglass-containing root canal sealer. *Dent Mater.* 2016;32(5):e113-e126. [\[CrossRef\]](#)
58. Camargo RV, Silva-Sousa YTC, Rosa RPF, et al. Evaluation of the physicochemical properties of silicone- and epoxy resin-based root canal sealers. *Braz Oral Res.* 2017;31:e72. [\[CrossRef\]](#)
59. Rodríguez-Lozano FJ, Collado-González M, Tomás-Catalá CJ, et al. GuttaFlow Bioseal promotes spontaneous differentiation of human periodontal ligament stem cells into cementoblast-like cells. *Dent Mater.* 2019;35(1):114-124. [\[CrossRef\]](#)
60. Santos JM, Pereira S, Sequeira DB, et al. Biocompatibility of a bioceramic silicone-based sealer in subcutaneous tissue. *J Oral Sci.* 2019;61(1):171-177. [\[CrossRef\]](#)
61. Gandolfi MG, Taddei P, Tinti A, Prati C. Apatite-forming ability (bioactivity) of ProRoot MTA. *Int Endod J.* 2010;43(10):917-929. [\[CrossRef\]](#)
62. Gandolfi MG, Van Landuyt K, Taddei P, Modena E, Van Meerbeek B, Prati C. Environmental scanning electron microscopy connected with energy dispersive x-ray analysis and Raman techniques to study ProRoot mineral trioxide aggregate and calcium silicate cements in wet conditions and in real time. *J Endod.* 2010;36(5):851-857. [\[CrossRef\]](#)

63. Donnermeyer D, Bürklein S, Dammascchke T, Schäfer E. Endodontic sealers based on calcium silicates: a systematic review. *Odontology*. 2019;107(4):421-436. [CrossRef]
64. Niu LN, Jiao K, Wang TD, et al. A review of the bioactivity of hydraulic calcium silicate cements. *J Dent*. 2014;42(5):517-533. [CrossRef]
65. Cardinali F, Camilleri J. A critical review of the material properties guiding the clinician's choice of root canal sealers. *Clin Oral Investig*. 2023;27(8):4147-4155. [CrossRef]
66. Sfeir G, Zogheib C, Patel S, Giraud T, Nagendrababu V, Bukiet F. Calcium silicate-based root canal sealers: a narrative review and clinical perspectives. *Materials (Basel)*. 2021;14(14):3965. [CrossRef]
67. Liao J, Al Shahrani M, Al-Habib M, Tanaka T, Huang GTJ. Cells isolated from inflamed periapical tissue express mesenchymal stem cell markers and are highly osteogenic. *J Endod*. 2011;37(9):1217-1224. [CrossRef]
68. Estrela C, Carmo Souza PO, Barbosa MG, et al. Mesenchymal stem cell marker expression in periapical abscess. *J Endod*. 2019;45(6):716-723. [CrossRef]
69. Leonardi R, Caltabiano M, Pagano M, Pezzuto V, Loreto C, Palestro G. Detection of vascular endothelial growth factor/vascular permeability factor in periapical lesions. *J Endod*. 2003;29(3):180-183. [CrossRef]
70. Virtej A, Løes SS, Berggreen E, Bletsa A. Localization and signaling patterns of vascular endothelial growth factors and receptors in human periapical lesions. *J Endod*. 2013;39(5):605-611. [CrossRef]
71. Abedin M, Tintut Y, Demer LL. Mesenchymal stem cells and the artery wall. *Circ Res*. 2004;95(7):671-676. [CrossRef]
72. Howson KM, Aplin AC, Gelati M, Alessandri G, Parati EA, Nicosia RF. The postnatal rat aorta contains pericyte progenitor cells that form spheroidal colonies in suspension culture. *Am J Physiol Cell Physiol*. 2005;289(6):C1396-C1407. [CrossRef]
73. Invernici G, Emanuelli C, Madeddu P, et al. Human fetal aorta contains vascular progenitor cells capable of inducing vasculogenesis, angiogenesis, and myogenesis in vitro and in a murine model of peripheral ischemia. *Am J Pathol*. 2007;170(6):1879-1892. [CrossRef]
74. Iurlaro M, Scatena M, Zhu WH, Fogel E, Wieting SL, Nicosia RF. Rat aorta-derived mural precursor cells express the Tie2 receptor and respond directly to stimulation by angiopoietins. *J Cell Sci*. 2003;116(17):3635-3643. [CrossRef]
75. Negri S, Wang Y, Sono T, et al. Human perivascular stem cells prevent bone graft resorption in osteoporotic contexts by inhibiting osteoclast formation. *Stem Cells Transl Med*. 2020;9(12):1617-1630. [CrossRef]
76. Pasanisi E, Ciavarella C, Valente S, Ricci F, Pasquinelli G. Differentiation and plasticity of human vascular wall mesenchymal stem cells, dermal fibroblasts and myofibroblasts: a critical comparison including ultrastructural evaluation of osteogenic potential. *Ultrastruct Pathol*. 2019;43(6):261-272. [CrossRef]
77. Hong MH, Lee JH, Jung HS, Shin H, Shin H. Biomineralization of bone tissue: calcium phosphate-based inorganics in collagen fibrillar organic matrices. *Biomater Res*. 2022;26(1):42. [CrossRef]
78. Chen Q, Shou P, Zheng C, et al. Fate decision of mesenchymal stem cells: adipocytes or osteoblasts? *Cell Death Differ*. 2016;23(7):1128-1139. [CrossRef]
79. Feng Z, Jin M, Liang J, et al. Insight into the effect of biomaterials on osteogenic differentiation of mesenchymal stem cells: a review from a mitochondrial perspective. *Acta Biomater*. 2023;164:1-14. [CrossRef]
80. Viti F, Landini M, Mezzelani A, Petecchia L, Milanese L, Scaglione S. Osteogenic differentiation of MSC through calcium signaling activation: transcriptomics and functional analysis. *PLoS One*. 2016;11(2):e0148173. [CrossRef]
81. Wang P, Zhao L, Liu J, Weir MD, Zhou X, Xu HHK. Bone tissue engineering via nanostructured calcium phosphate biomaterials and stem cells. *Bone Res*. 2014;2:14017. [CrossRef]
82. Turner J, Nandakumar A, Anilbhai N, Boccaccini AR, Jones JR, Jell G. The effect of Si species released from bioactive glasses on cell behaviour: a quantitative review. *Acta Biomater*. 2023;170:39-52. [CrossRef]
83. Rathinam E, Govindarajan S, Rajasekharan S, et al. The calcium dynamics of human dental pulp stem cells stimulated with tricalcium silicate-based cements determine their differentiation and mineralization outcome. *Sci Rep*. 2021;11(1):645. [CrossRef]
84. Sun J, Wei L, Liu X, et al. Influences of ionic dissolution products of dicalcium silicate coating on osteoblastic proliferation, differentiation and gene expression. *Acta Biomater*. 2009;5(4):1284-1293. [CrossRef]
85. Bernardini C, Zamparini F, Prati C, et al. Osteoinductive and regenerative potential of premixed calcium-silicate bioceramic sealers on vascular wall mesenchymal stem cells. *Int Endod J*. 2024;57(9):1264-1278. [CrossRef]
86. Huang W, Yang S, Shao J, Li YP. Signaling and transcriptional regulation in osteoblast commitment and differentiation. *Front Biosci*. 2007;12:3068-3092. [CrossRef]
87. Wang KX, Denhardt DT. Osteopontin: role in immune regulation and stress responses. *Cytokine Growth Factor Rev*. 2008;19(5-6):333-345. [CrossRef]
88. Jung GY, Park YJ, Han JS. Effects of HA released calcium ion on osteoblast differentiation. *J Mater Sci Mater Med*. 2010;21(5):1649-1654. [CrossRef]
89. Lee SH, Oh S, Al-Ghamdi AS, Mandorah AO, Kum KY, Chang SW. Sealing ability of AH Plus and GuttaFlow bioseal. *Bioinorg Chem Appl*. 2020;2020:8892561. [CrossRef]
90. Gandolfi MG, Iezzi G, Piattelli A, Prati C, Scarano A. Osteoinductive potential and bone-bonding ability of ProRoot MTA, MTA Plus and Biodentine in rabbit intramedullary model: microchemical characterization and histological analysis. *Dent Mater*. 2017;33(5):e221-e238. [CrossRef]
91. Santos JM, Coelho CM, Sequeira DB, et al. Subcutaneous implantation assessment of new calcium-silicate based sealer for warm obturation. *Biomedicines*. 2021;9(1):24. [CrossRef]
92. Yusuf H. The significance of the presence of foreign material periapically as a cause of failure of root treatment. *Oral Surg Oral Med Oral Pathol*. 1982;54(5):566-574. [CrossRef]
93. Aminoshariae A, Kulild JC. The impact of sealer extrusion on endodontic outcome: a systematic review with meta-analysis. *Aust Endod J*. 2020;46(1):123-129. [CrossRef]
94. Siqueira JF Jr, Rôças IN, Ricucci D, Hülsmann M. Causes and management of post-treatment apical periodontitis. *Br Dent J*. 2014;216(6):305-312. [CrossRef]
95. Siqueira JF Jr. Aetiology of root canal treatment failure: why well-treated teeth can fail. *Int Endod J*. 2001;34(1):1-10. [CrossRef]
96. Graunaitė I, Skuicaite N, Lodiene G, Agentiene I, Machiulskiene V. Effect of resin-based and bioceramic root canal sealers on postoperative pain: a split-mouth randomized controlled trial. *J Endod*. 2018;44(5):689-693. [CrossRef]
97. Arias A, de la Macorra JC, Hidalgo JJ, Azabal M. Predictive models of pain following root canal treatment: a prospective clinical study. *Int Endod J*. 2013;46(8):784-793. [CrossRef]
98. Genet JM, Hart AA, Wesselink PR, Thoden van Velzen SK. Preoperative and operative factors associated with pain after the first endodontic visit. *Int Endod J*. 1987;20(2):53-64. [CrossRef]
99. Bugea C, Cerutti F, Ongaro F, et al. Postoperative pain and one year follow up success rate of warm vertical compaction, single cone, coneless and bioconeless obturation methods. *J Osseointegration*. 2022;14(4):209-216.
100. Omoigui S. The biochemical origin of pain: the origin of all pain is inflammation and the inflammatory response. Part 2 of 3 - inflammatory profile of pain syndromes. *Med Hypotheses*. 2007;69(6):1169-1178. [CrossRef]
101. Matsuda S, Itoi H, Ryoke T, Yoshimura H. How should clinicians assess acute dental pain? *Med (Baltimore)*. 2022;101(45):e31727. [CrossRef]
102. Fonseca B, Coelho MS, Bueno CEDS, Fontana CE, Martin ASD, Rocha DGP. Assessment of extrusion and postoperative pain of a bioceramic and resin-based root canal sealer. *Eur J Dent*. 2019;13(3):343-348. [CrossRef]
103. Shashirekha G, Jena A, Pattanaik S, Rath J. Assessment of pain and dissolution of apically extruded sealers and their effect on the periradicular tissues. *J Conserv Dent*. 2018;21(5):546-550. [CrossRef]
104. Mekhdiava E, Del Fabbro M, Alovivi M, et al. Postoperative Pain following Root Canal Filling with Bioceramic vs. traditional Filling Techniques: a Systematic Review and Meta-Analysis of Randomized Controlled Trials. *J Clin Med*. 2021;10(19):4509. [CrossRef]

105. Bükler M, Sümbüllü M, Ali A, Ünal O, Arslan H. The effects of calcium silicate- and calcium hydroxide-based root canal sealers on postoperative pain: a randomized clinical trial. *J Endod.* 2023;49(12):1588-1594. [\[CrossRef\]](#)
106. Ruparel NB, Ruparel SB, Chen PB, Ishikawa B, Diogenes A. Direct effect of endodontic sealers on trigeminal neuronal activity. *J Endod.* 2014;40(5):683-687. [\[CrossRef\]](#)
107. Rosen E, Goldberger T, Taschieri S, Del Fabbro M, Corbella S, Tsesis I. The prognosis of altered sensation after extrusion of root canal filling materials: a systematic review of the literature. *J Endod.* 2016;42(6):873-879. [\[CrossRef\]](#)
108. De-Deus G, Souza EM, Silva EJNL, et al. A critical analysis of research methods and experimental models to study root canal fillings. *Int Endod J.* 2022;55(Suppl 2):384-445. [\[CrossRef\]](#)
109. Razdan A, Benetti AR, Bakhshandeh A, Darvann TA, Bjørndal L. Dimensional changes of endodontic sealers-An in vitro model simulating a clinical extrusion scenario during 18 months. *Clin Exp Dent Res.* 2023;9(2):299-313. [\[CrossRef\]](#)
110. Faria-Júnior NB, Tanomaru-Filho M, Berbert FL, Guerreiro-Tanomaru JM. Antibiofilm activity, pH and solubility of endodontic sealers. *Int Endod J.* 2013;46(8):755-762. [\[CrossRef\]](#)
111. McMichen FR, Pearson G, Rahbaran S, Gulabivala K. A comparative study of selected physical properties of five root-canal sealers. *Int Endod J.* 2003;36(9):629-635. [\[CrossRef\]](#)
112. Leonardo MR, Silva LA, Utrilla LS, Assed S, Ether SS. Calcium hydroxide root canal sealers--histopathologic evaluation of apical and periapical repair after endodontic treatment. *J Endod.* 1997;23(7):428-432. [\[CrossRef\]](#)
113. Khalil MM, Abdelrahman MH, El-Mallah S. Bond strength and solubility of a novel polydimethylsiloxane-gutta-percha calcium silicate-containing root canal sealer. *Dent Med Probl.* 2019;56(2):161-165. [\[CrossRef\]](#)
114. Bilvinaite G, Drukteinis S, Brukiene V, Rajasekharan S. Immediate and long-term radiopacity and surface morphology of hydraulic calcium silicate-based materials. *Materials (Basel).* 2022;15(19):6635. [\[CrossRef\]](#)
115. Firoozmand LM, Cordeiro MG, Da Silva MADS, De JesusTavarez RR, Matos Maia Filho E. Radiopacity of methacrylate and Silorane composite resins using a digital radiographic system. *ScientificWorldJournal.* 2016;2016: 6389347. [\[CrossRef\]](#)
116. Camerini R, Poggi G, Ridi F, Baglioni P. The kinetic of calcium silicate hydrate formation from silica and calcium hydroxide nanoparticles. *J Colloid Interface Sci.* 2022;605:33-43. [\[CrossRef\]](#)
117. Silva EJNL, Ferreira CM, Pinto KP, Barbosa AFA, Colaço MV, Sassone LM. Influence of variations in the environmental pH on the solubility and water sorption of a calcium silicate-based root canal sealer. *Int Endod J.* 2021;54(8):1394-1402. [\[CrossRef\]](#)
118. Ferreira CMA, de Lima CO, Pinto KP, et al. pH influences the volumetric change of calcium silicate- and epoxy resin-based root canal sealers: an ex vivo micro-CT study. *Aust Endod J.* 2023;49(Suppl 1):194-201. [\[CrossRef\]](#)
119. Orstavik D, Mjör IA. Histopathology and x-ray microanalysis of the subcutaneous tissue response to endodontic sealers. *J Endod.* 1988;14(1):13-23. [\[CrossRef\]](#)
120. Suzuki P, Souza Vd, Holland R, et al. Tissue reaction to Endométhasone sealer in root canal fillings short of or beyond the apical foramen. *J Appl Oral Sci.* 2011;19(5):511-516. [\[CrossRef\]](#)
121. Langeland K. Root canal sealants and pastes. *Dent Clin North Am.* 1974;18(2):309-327. [\[CrossRef\]](#)
122. Kaysinger KK, Ramp WK. Extracellular pH modulates the activity of cultured human osteoblasts. *J Cell Biochem.* 1998;68(1):83-89. (doi:10.1002/(sici)1097-4644(19980101)68:1<83::aid-jcb8>3.0.co;2-s)
123. Arnett TR. Extracellular pH regulates bone cell function. *J Nutr.* 2008;138(2):415S-418S. [\[CrossRef\]](#)
124. Hashiguchi D, Fukushima H, Yasuda H, et al. Mineral trioxide aggregate inhibits osteoclastic bone resorption. *J Dent Res.* 2011;90(7):912-917. [\[CrossRef\]](#)
125. de Azevedo Queiroz ÍO, Machado T, Alves CC, et al. Tracing the toxic ions of an endodontic tricalcium silicate-based sealer in local tissues and body organs. *J Trace Elem Med Biol.* 2021;68:126856. [\[CrossRef\]](#)
126. Marciano MA, Pelepenko LE, Francati TM, et al. Bismuth release from endodontic materials: in vivo analysis using Wistar rats. *Sci Rep.* 2023;13(1):9738. [\[CrossRef\]](#)
127. Schembri Wismayer P, Lung CY, Rappa F, Cappello F, Camilleri J. Assessment of the interaction of Portland cement-based materials with blood and tissue fluids using an animal model. *Sci Rep.* 2016;6:34547. [\[CrossRef\]](#)
128. Camilleri J, Cutajar A, Mallia B. Hydration characteristics of zirconium oxide replaced Portland cement for use as a root-end filling material. *Dent Mater.* 2011;27(8):845-854. [\[CrossRef\]](#)
129. Camilleri J, Gandolfi MG. Evaluation of the radiopacity of calcium silicate cements containing different radiopacifiers. *Int Endod J.* 2010;43(1):21-30. [\[CrossRef\]](#)
130. Janini ACP, Pelepenko LE, Moraes BF, et al. Chemical and in vivo analyses of calcium silicate-based materials in bone and connective tissues. *Int Endod J.* 2025;58(3):484-503. [\[CrossRef\]](#)
131. Goldberg F, Cantarini C, Alfie D, Macchi RL, Arias A. Relationship between unintentional canal overfilling and the long-term outcome of primary root canal treatments and nonsurgical retreatments: a retrospective radiographic assessment. *Int Endod J.* 2020;53(1):19-26. [\[CrossRef\]](#)
132. Friedman S, Löst C, Zarrabian M, Trope M. Evaluation of success and failure after endodontic therapy using a glass ionomer cement sealer. *J Endod.* 1995;21(7):384-390. [\[CrossRef\]](#)
133. Huuomonen S, Lenander-Lumikari M, Sigurdsson A, Ørstavik D. Healing of apical periodontitis after endodontic treatment: a comparison between a silicone-based and a zinc oxide-eugenol-based sealer. *Int Endod J.* 2003;36(4):296-301. [\[CrossRef\]](#)
134. Sari S, Okte Z. Success rate of Sealapex in root canal treatment for primary teeth: 3-year follow-up. *Oral Surg Oral Med Oral Pathol Oral Radiol Endod.* 2008;105(4):e93-e96. [\[CrossRef\]](#)
135. Caicedo R, von Fraunhofer JA. The properties of endodontic sealer cements. *J Endod.* 1988;14(11):527-534. [\[CrossRef\]](#)
136. Cutajar A, Mallia B, Abela S, Camilleri J. Replacement of radiopacifier in mineral trioxide aggregate; characterization and determination of physical properties. *Dent Mater.* 2011;27(9):879-891. [\[CrossRef\]](#)
137. Chybowski EA, Glickman GN, Patel Y, Fleury A, Solomon E, He J. Clinical outcome of non-surgical root canal treatment using a single-cone technique with endosequence bioceramic sealer: a retrospective analysis. *J Endod.* 2018;44(6):941-945. [\[CrossRef\]](#) [published correction appears in *J Endod.* 2018;44(7):1199. 10.1016/j.joen.2018.06.001]
138. Spinelli A, Zamparini F, Lenzi J, Gandolfi MG, Prati C. Clinical evaluation of a novel premixed tricalcium silicate containing bioceramic sealer used with warm carrier-based technique: a 12-month prospective pilot study. *Appl Sci.* 2023;13(21):11835. [\[CrossRef\]](#)
139. Bardini G, Casula L, Ambu E, Musu D, Mercadè M, Cotti E. Correction to: a 12-month follow-up of primary and secondary root canal treatment in teeth obturated with a hydraulic sealer. *Clin Oral Investig.* 2021;25(8):5121. [\[CrossRef\]](#)
140. Brochado Martins JF, Georgiou AC, Nunes PD, et al. CBCT-assessed outcomes and prognostic factors of primary endodontic treatment and retreatment: a systematic review and meta-analysis. *J Endod.* 2025;51(6):687-706. [\[CrossRef\]](#)