



ELSEVIER

Contents lists available at ScienceDirect

Oral Oncology

journal homepage: www.elsevier.com/locate/oraloncology



How reliable is assessment of true vocal cord-arytenoid unit mobility in patients affected by laryngeal cancer? a multi-institutional study on 366 patients from the ARYFIX collaborative group

M. Ferrari^{a,1,*}, F. Mularoni^{a,1}, S. Taboni^a, E. Crosetti^b, C. Pessina^c, A.L.C. Carobbio^a, N. Montalto^a, F. Marchi^{d,e}, A. Vural^f, A. Paderno^g, S. Caprioli^h, P. Gaudio^a, M. Fermi^{i,j}, F. Rigoni^a, T. Saccardo^a, G. Contro^a, A. Ruaro^a, A. Lo Manto^k, C. Varago^l, M. Baldovin^m, L. Bandolinⁿ, M. Filauro^{d,e}, C. Sampieri^{o,p}, F. Missale^q, A. Ioppi^r, F. Carta^s, M. Ramanzin^t, M. Ravanelli^u, V. Maiolo^v, I. Bertotto^w, F. Del Bon^x, D. Lancini^x, C. Mariani^s, V. Marrosu^s, M. Tatti^s, S. Çağlı^y, I. Yüce^y, M. Gündoğ^z, S. Dogan^{aa}, G. Anile^{ab}, C. Gottardi^{ab}, F. Busato^{ac}, A. Vallin^{d,e}, F. Gennarini^x, P. Bossi^{ad,ae}, M.G. Ghi^{ab}, M. Lionello^l, E. Zanoletti^a, G. Marioni^a, R. Maroldi^u, F. Mattioli^{af}, R. Puxeddu^{s,ag}, A. Bertolin^l, L. Presutti^{i,j}, C. Piazza^x, G. Succo^{b,ah}, G. Peretti^{d,e}, P. Nicolai^a

^a Otorhinolaryngology and Head and Neck Unit, Department of Neuroscience, Azienda Ospedale Università di Padova, Padova, Italy

^b Otorhinolaryngology Department – Head Neck Cancer Unit, San Giovanni Bosco Hospital, Turin, Italy

^c Radiology Unit, Sant'Antonio Hospital, University of Padova, Padova, Italy

^d Unit of Otorhinolaryngology, Head and Neck Surgery, IRCCS Ospedale Policlinico San Martino, Largo Rosanna Benzi 10, 16121 Genoa, Italy

^e Department of Surgical Sciences and Integrated Diagnostics (DISC), University of Genova, Genoa, Italy

^f Otorhinolaryngology Unit, Istanbul University - Cerrahpasa, Cerrahpasa Medical Faculty, Istanbul, Turkey

^g IRCCS Humanitas Research Hospital, via Manzoni 56, 20089 Rozzano, Milan, Italy

^h Radiology Unit, San Martino Hospital, Genoa, Italy

ⁱ Otorhinolaryngology Unit, Azienda Ospedaliera Universitaria di Bologna IRCCS, Bologna, Italy

^j Department of Surgical and Medical Sciences, University of Bologna, Bologna, Italy

^k Otorhinolaryngology Unit, Infermi Hospital, Rimini, Italy

^l Otorhinolaryngology Unit, Vittorio Veneto Hospital, Treviso, Italy

^m Otorhinolaryngology Unit, San Martino di Belluno Hospital, Belluno, Italy

ⁿ Otorhinolaryngology Unit, Hospital of Santorso, Vicenza, Italy

^o Department of Experimental Medicine (DIMES), University of Genova, Italy

^p Unit of Head and Neck Tumors, Hospital Clínic, Barcelona, Spain

^q Department of Otorhinolaryngology, Head and Neck Surgery, Maastricht University Medical Center, 6202 AZ Maastricht, the Netherlands

^r Department of Otorhinolaryngology-Head and Neck Surgery, "S. Chiara" Hospital, Azienda Provinciale per i Servizi Sanitari (APSS), Trento, Italy

^s Otorhinolaryngology Unit, Azienda Ospedaliero-Universitaria di Cagliari, Cagliari, Italy

^t Radiology Unit, Hospital of Vicenza, Vicenza, Italy

^u Radiology Unit, ASST Spedali Civili di Brescia, University of Brescia, Brescia, Italy

^v Pediatric and Adult Cardiothoracic and Vascular, Oncohematologic and Emergency Radiology Unit (IRCCS AOUBO), University of Bologna, Italy

^w Radiology Unit, IRCCS Istituto di Candiolo, Turin, Italy

^x Otorhinolaryngology Unit, ASST Spedali Civili di Brescia, University of Brescia, Brescia, Italy

^y Otorhinolaryngology Unit, Erciyes University, Kayseri, Turkey

^z Department of Radiation Oncology, Erciyes University, Kayseri, Turkey

^{aa} Department of Radiology, Erciyes University, Kayseri, Turkey

^{ab} Unit of Medical Oncology 2, "Istituto Oncologico Veneto", Padova, Italy

^{ac} Unit of Radiation Oncology, Policlinico Abano, Padova, Italy

^{ad} Department of Biomedical Sciences, Humanitas University, Via Rita Levi Montalcini 4, 20072 Pieve Emanuele, Milan, Italy

^{ae} IRCCS Humanitas Research Hospital, via Manzoni 56, 20089 Rozzano, Milan, Italy

^{af} Otorhinolaryngology Unit, University of Modena, Modena, Italy

^{ag} King's College Hospital London, Dubai, United Arab Emirates

* Corresponding author at: Section of Otorhinolaryngology – Head and Neck Surgery, Department of Neurosciences, University of Padua, "Azienda Ospedale Università di Padova", Via Giustiniani 2, 35128, Padua.

E-mail address: marco.ferrari@unipd.it (M. Ferrari).

<https://doi.org/10.1016/j.oraloncology.2024.106744>

Received 10 January 2024; Received in revised form 1 March 2024; Accepted 5 March 2024

Available online 22 March 2024

1368-8375/© 2024 The Author(s). Published by Elsevier Ltd. This is an open access article under the CC BY license (<http://creativecommons.org/licenses/by/4.0/>).

ARTICLE INFO

Keywords:

Larynx
Squamous cell carcinoma
Arytenoid
Vocal cord
Mobility
Endoscopy
Imaging
Agreement
Reliability

ABSTRACT

Purpose: In clinical practice the assessment of the “vocal cord-arytenoid unit” (VCAU) mobility is crucial in the staging, prognosis, and choice of treatment of laryngeal squamous cell carcinoma (LSCC). The aim of the present study was to measure repeatability and reliability of clinical assessment of VCAU mobility and radiologic analysis of posterior laryngeal extension.

Methods: In this multi-institutional retrospective study, patients with LSCC-induced impairment of VCAU mobility who received curative treatment were included; pre-treatment endoscopy and contrast-enhanced imaging were collected and evaluated by raters. According to their evaluations, concordance, number of assigned categories, and inter- and intra-rater agreement were calculated.

Results: Twenty-two otorhinolaryngologists evaluated 366 videolaryngoscopies (total evaluations: 2170) and 6 radiologists evaluated 237 imaging studies (total evaluations: 477). The concordance of clinical rating was excellent in only 22.7% of cases. Overall, inter- and intra-rater agreement was weak. Supraglottic cancers and transoral endoscopy were associated with the lowest inter-observer reliability values. Radiologic inter-rater agreement was low and did not vary with imaging technique. Intra-rater reliability of radiologic evaluation was optimal.

Conclusions: The current methods to assess VCAU mobility and posterior extension of LSCC are flawed by weak inter-observer agreement and reliability. Radiologic evaluation was characterized by very high intra-rater agreement, but weak inter-observer reliability. The relevance of VCAU mobility assessment in laryngeal oncology should be re-weighted. Patients affected by LSCC requiring imaging should be referred to dedicated radiologists with experience in head and neck oncology.

Introduction

Intermediate and advanced stage laryngeal squamous cell carcinoma (LSCC) is frequently associated with impairment of mobility of true vocal cord and arytenoid. This alteration depends on the site and extension of the tumor and can be detected through laryngeal endoscopy.

In clinical practice, mobility impairment of the true vocal cord and arytenoid is classified as “paresis”/“hypomobility” or “paralysis”/“fixation”. Succo *et al.* identified four potential mechanisms underlying this clinical finding, each with different prognostic and therapeutic implications.[1] According to their observations, only some LSCC determining laryngeal mobility impairment actually extend into the posterior laryngeal compartment. Tumor extension into this compartment is best assessed through imaging and is conventionally defined when LSCC invades the posterior portion of the inferior paraglottic space by crossing the so-called “magic plane”, which is a virtual paracoronal plane perpendicular to the thyroid lamina and passing through the vocal process of the arytenoid cartilage.[2] This extension is crucial in laryngeal oncology since it has heterogeneous prognostic relevance relative to the surgical procedure that is undertaken: while posterior LSCC showed poor prognosis in patients treated with open partial horizontal laryngectomy (OPHL) [3,4] or transoral laser microsurgery,[5,6] such a prognostic difference was not observed after total laryngectomy (TL).[7] Conversely, little is known about the prognostic effect of posterior laryngeal involvement in patients undergoing radiation therapy (RT) with or without sequential/concomitant combination with chemotherapy.

In the 8th Edition of the TNM classification of glottic LSCC, T2 tumors are characterized by incomplete impairment of true vocal cord mobility, while a tumor determining its fixation is designated as T3. [8,9] Interestingly, this criterion is not limited to the clinical classification of the tumor (*i.e.*, cT), but it is also incorporated into the criteria of postoperative classification (*i.e.*, pT). In other words, an intralaryngeal LSCC determining fixation of the true vocal cord at pre-treatment endoscopy (*i.e.*, cT3) should currently be defined as pT3 even in the absence of other criteria at definitive pathology pertaining to

T3 category. The same applies to T2 glottic cancers when partial mobility impairment is diagnosed.

Currently, there is no distinction within the classification between true vocal cord and arytenoid mobility.[10] Although different patterns of mobility impairment could be surmised, granular distinction between true vocal cord and arytenoid mobility is challenging and likely flawed by substantial subjectivity. Moreover, the likelihood of involvement of intrinsic muscles and the cricoarytenoid joint is similar in patients with true vocal fold and in those with arytenoid fixation.[11] Thus, in the present study the true vocal cord and arytenoid will be considered as a single morphofunctional unit referred to as “vocal cord-arytenoid unit” (VCAU), consistent with TNM classification.[8,10].

VCAU fixation has been traditionally considered as a tumor-related contraindication to organ preservation surgery.[12–14] However, with the identification of different mechanisms determining VCAU mobility impairment and clarification of the involved anatomical structures, this dogma has been challenged.[1] Similarly, mobility impairment is recognized as an adverse prognostic factor in patients undergoing non-surgical organ preservation treatment.[15].

Given these premises, clinical examination with videolaryngoscopy plays a pivotal role in staging and therapeutic decision-making in patients affected by intermediate-to-advanced LSCC. However, the assessment of VCAU mobility is based on the subjective interpretation of the examiner, and no data on the repeatability of this evaluation are available. The aim of the present multi-institutional retrospective study was to measure the repeatability and reliability of clinical assessment of VCAU mobility by concordance and agreement analysis. The study also assessed reliability of radiologic classification of LSCC relative to the “magic plane”.

Materials and methods

ARYFIX dataset

The dataset of ARYFIX, which is a collaborative study detailed in Table 1, was exploited to perform the following analyses. Data were pseudonymized and transferred to the coordinating center (University of Padua – “Azienda Ospedale Università di Padova”; Padua, Italy) for fully anonymized analysis. Analysis of data was conducted in accordance with the 1964 Helsinki declaration and its later amendments and was

¹ MF and FM equally share the first authorship.

Table 1

Design, inclusion period, and inclusion and exclusion criteria of the ARYFIX collaborative study. CRT, chemoradiotherapy; LSCC, laryngeal squamous cell carcinoma; OPHL, open partial horizontal laryngectomy; RT, radiotherapy; TL, total laryngectomy; VCAU, vocal cord-arytenoid unit.

| ARYFIX collaborative study | |
|------------------------------|---|
| Study design | Retrospective cohort analysis |
| Inclusion period | 2004-2021 |
| Participating centers | <ul style="list-style-type: none"> University of Padua – “Azienda Ospedale Università di Padova” (Padua, Italy) University of Genoa – “IRCCS Ospedale Policlinico San Martino” (Genoa, Italy) “IRCCS Istituto di Candiolo” (Candiolo, Italy) “Ospedale San Giovanni Bosco di Torino” (Turin, Italy) “Ospedale di Vittorio Veneto - ULSS 2 Marca Trevigiana” (Vittorio Veneto, Italy) University of Bologna – “IRCCS Policlinico Sant’Orsola-Malpighi” (Bologna, Italy) University of Modena – “Policlinico di Modena” (Modena, Italy) Erciyes University (Kayseri, Turkey) University of Cagliari – “Azienda Ospedaliero-Universitaria di Cagliari” (Cagliari, Italy) University of Brescia – “ASST Spedali Civili di Brescia” (Brescia, Italy) |
| Inclusion criteria | <ul style="list-style-type: none"> Non-recurrent LSCC Clinical diagnosis of partial or total VCAU mobility impairment made in the center where treatment was delivered Any of the following treatments with curative intent: <ul style="list-style-type: none"> TL w/o adjuvant RT/CRT Type II/III OPHL w/o adjuvant RT/CRT RT/CRT w/o salvage TL Induction CT followed by RT/CRT w/o salvage TL Induction CT followed by TL w/o adjuvant RT/CRT Availability of pre-treatment videolaryngoscopy and/or contrast-enhanced local imaging |
| Exclusion criteria | <ul style="list-style-type: none"> Previous cancer of the head and neck and/or oncologic treatment involving the head and neck cM1 at presentation Hypopharyngeal cancers Unavailable follow-up information |

endorsed by the Institutional Review Board (approval code: 190n/AO/21).

Clinical and radiologic rating

Otorhinolaryngologists, head and neck surgeons from the participating institutions were asked to evaluate videolaryngoscopies to assess VCAU mobility using the 4- and 3-category classifications reported in [Table 2](#).

Radiologists from the participating centers were asked to analyze pre-treatment contrast-enhanced local imaging (*i.e.*, computed tomography [CT] and/or magnetic resonance [MR]) sequences and classify tumor extension as reported in [Table 2](#).[\[2,16\]](#).

Concordance and agreement analysis

The following outcomes of agreement between raters were measured: concordance, number of assigned categories (NOAC), inter-rater agreement, intra-rater agreement. Details on outcomes are reported in [Table 2](#).[\[17\]](#) In view of the main declared aim of the study and the need to account for likelihood of by-chance-agreement, inter-rater agreement was considered the primary outcome.

Mode-based reclassification of cases

The *mode* of rates per single case was calculated to classify VCAU mobility as interpreted by the majority of raters. Overall survival (OS), defined as survival from the date of diagnosis, was measured with the

Kaplan-Meier method and stratified according to the initial classification (intended as the actual classification of VCAU mobility attributed in the center where the patient was treated) and mode-based re-classifications of VCAU mobility with log-rank test. Locoregional control (LRC), defined as the time to local and/or regional recurrence (with death considered as censoring episode), was analyzed analogously. Five-year survival estimates are reported with 95 % confidence interval (95 % CI).

Impact of mobility assessment on T category assignment

To measure the impact of VCAU mobility on T category assignment, each case was re-evaluated using the principles reported in [Supplementary Table 1](#). Cases with mobility-dependent T category were counted and studied to check whether at least one of the VCAU mobility rates provided by clinicians (referring to the 4-category classification) would have implied a change in T category (*i.e.*, up-classification or down-classification).

Results

Study cohort and expert evaluations

The study included 366 patients whose pre-treatment videolaryngoscopies were available. According to medical records, 192 (52.5 %) and 174 (47.5 %) VCAU mobility was considered as partially (*i.e.*, paresis/hypomobility) or totally deficient (*i.e.*, paralysis/fixation), respectively. Pre-treatment videolaryngoscopies were acquired with either a front transnasal fiberoptic technique (158, 43.2 %), back transnasal fiberoptic technique (131, 35.8 %), or transoral endoscopy with 70° scope (77, 21.0 %). Videolaryngoscopies were evaluated by 22 otorhinolaryngologists - head and neck surgeons from 8 institutions, with heterogeneous experience in laryngeal oncology (mean: 6.7 years, range: 3–22). Each videolaryngoscopy received between 4 and 9 evaluations (mean and median: 6 evaluations), for a total of 2170 evaluations. Pre-treatment imaging was available in 237 (64.8 %) patients (168/237 [70.9 %] CT, 49/237 [20.7 %] MR, 20/237 [8.4 %] both) and was evaluated by 6 radiologists with experience in head and neck oncology (mean: 5.5 years, range: 4–11). Each case received between 2 and 3 evaluations (mean: 2.3; median: 2.0) for a total of 477 evaluations.

Concordance

When applying the 4-category classification of VCAU mobility, concordance was excellent in 83 (22.7 %) cases, good in 102 (27.9 %), poor in 104 (28.4 %), and very poor in 77 (21.0 %) ([Figure 1](#)). According to the 3-category classification, the concordance profile was as follows: 163 (44.5 %) cases showed excellent concordance, 95 (26.0 %) good, 67 (18.3 %) poor, and 41 (11.2 %) very poor ([Figure 1](#)). Based on the radiologic classification of tumor extension, concordance was excellent in 115 (61.2 %), poor in 29 (15.4 %), and very poor in 44 (23.4 %).

Number of assigned categories

The NOAC distribution was as follows:

- 4-category classification: 1 category (83, 22.7 %), 2 categories (210, 57.4 %), 3 categories (68, 18.6 %), and 4 categories (3, 1.4 %).
- 3-category classification: 1 category (163, 44.5 %), 2 categories (175, 47.8 %), and 3 categories (28, 7.7 %).

Inter- and intra-rater agreement

Inter-rater agreement of clinical VCAU mobility assessment was weak, with $\kappa = 0.46$ and 0.40 with the 4- and 3-category classifications, respectively. Details on sub-cohort analyses are reported in [Table 3](#). Intra-rater agreement was minimal and weak, with mean $\kappa = 0.30$ and

Table 2

Classifications and agreement outcomes employed in the study. NA, not available; VCAU, vocal cord-arytenoid unit. *Owing to the mass effect of the tumor, inadequate framing during the videolaryngoscopy, or other reasons. **Selected based on the non-unique nature of raters (i.e., raters assigning ratings to a particular subject are not assumed to be the same raters assigning ratings to another subject); ***Ten clinical raters were asked to re-evaluate 52 cases, each after a 6-month period from the first evaluation, when the results were blinded; two radiologic raters were asked to re-evaluate 59 cases after a 12-month period from the first evaluation, when the results were blinded.

| Classification | VCAU mobility | Description | Synonyms |
|--------------------------------------|--|---|--|
| 4-category classification | Normal | VCAU displays a physiological motion | NA |
| | Partially reduced | VCAU displays reduced mobility, but some movement can be detected | VCAU paresis VCAU hypomobility |
| | Totally reduced | VCAU displays no mobility (both true vocal cord and arytenoid are fixed) | VCAU paralysis VCAU fixation |
| 3-category classification | Not evaluable | VCAU mobility cannot be evaluated* | NA |
| | Normal | VCAU displays a physiological motion | NA |
| | Reduced | VCAU displays any degree of reduced mobility | NA |
| Radiologic classification | Not evaluable | VCAU mobility cannot be evaluated* | NA |
| | Anterior | The tumor is limited to the anterior laryngeal compartment, defined according to the “magic plane” [2,16] | NA |
| | Posterior | The tumor involves the posterior laryngeal compartment, defined according to the “magic plane” [2,16] | NA |
| | Not evaluable | Tumor extension relative to the “magic plane” [2,16] cannot be determined | NA |
| Outcome | Definition | Note | |
| Single-case concordance | The ratio, expressed in percentage, between the maximum number of concordant evaluations and the total number of evaluations per single case | Concordance was arbitrarily defined as excellent if 100 %, good between 80 % and 99 %, poor between 51 % and 79 %, and very poor if 50 % or lower | |
| Mean concordance | The average of single-case concordance values | Used to provide data on the entire series and sub-cohorts | |
| Number of assigned categories | The number of categories assigned by raters | Used to express the variability of interpretation of VCAU mobility. For instance, in a given case with VCAU mobility classified as either partially or totally reduced by raters, the NOAC was 2. If in another case VCAU mobility was classified as normal, partially reduced, totally reduced, and not evaluable by different raters, then the NOAC was 4, indicating a higher propensity to different mobility interpretation. | |
| Inter-rater agreement | Fleiss’ κ^{**} | Kappa statistics, which is considered the gold standard to assess consistency of judgement in the research and clinical environment, was employed to account for the probability of by-chance-agreement | As per international standard, level of agreement was classified according to the following thresholds of κ : none (0–0.20), minimal (0.21–0.39), weak (0.40–0.59), moderate (0.60–0.79), strong (0.80–0.90), and almost perfect (>0.90). The κ -dependent rate of reliable data was also estimated by squaring κ value, according to McHugh et al.[17] |
| Intra-rater agreement | Cohen’s κ^{***} | | |

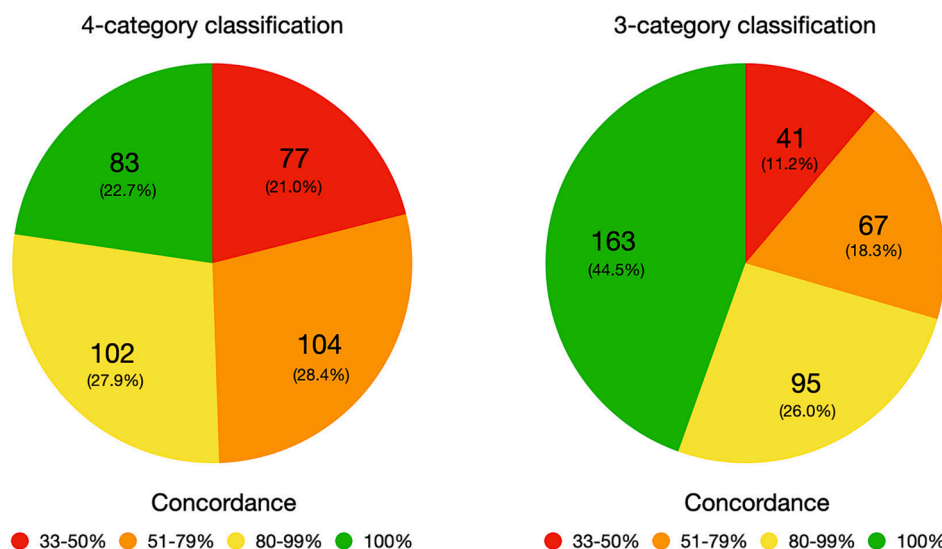


Fig. 1. Pie-charts displaying the distribution of per-single-case concordance according to the 4- and 3-category classifications.

0.44 with the 4- and 3-category classification, respectively. Most raters (7/10, 70.0 %) showed a none-to-weak repeatability in terms of clinical VCAU assessment with the 4-category classification, whereas 6/10 (60.0 %) raters showed moderate-to-strong repeatability with the 3-category classification (Supplementary Table 2). Inter-rater

agreement of radiologic assessment was minimal, with $\kappa = 0.36$, and did not vary with technique (Table 3). Intra-rater agreement of the radiologic evaluation was strong-to-almost perfect ($\kappa = 0.83–0.97$).

Table 3

Summary of concordance and Fleiss' κ values of the inter-rater agreement analysis (2170 evaluations). Cat., category; CI, confidence interval. *Estimated fraction of reliable information is calculated by squaring κ value, as reported by McHugh et al.[17].

| Cluster | Sub-cohort | Classification | Mean concordance | Fleiss' κ (95 %-CI) | Level of agreement | Estimated fraction of reliable information* |
|---------------------|---------------------------|----------------|------------------|----------------------------|--------------------|---|
| Entire cohort | | 4-cat. | 74.9 % | 0.46 (0.41–0.52) | Weak | 21.2% |
| | | 3-cat. | 83.8 % | 0.40 (0.34–0.46) | Weak | 16.0% |
| Site (epicenter) | Supraglottis | Radiologic | 71.5 % | 0.36 (0.22–0.50) | Minimal | 13.0% |
| | | 4-cat. | 80.8 % | 0.39 (0.30–0.48) | Minimal | 15.2 % |
| | Glottis | 3-cat. | 88.0 % | 0.24 (0.13–0.35) | Minimal | 5.8 % |
| | | 4-cat. | 75.1 % | 0.52 (0.45–0.58) | Weak | 27.0 % |
| Experience (years) | ≤4 | 3-cat. | 85.2 % | 0.33 (0.26–0.40) | Minimal | 10.9 % |
| | | 4-cat. | 69.2 % | 0.52 (0.42–0.62) | Weak | 27.0 % |
| | 4–6 | 3-cat. | 85.1 % | 0.30 (0.22–0.38) | Minimal | 9.0 % |
| | | 4-cat. | 65.1 % | 0.39 (0.31–0.48) | Minimal | 15.2 % |
| | >6 | 3-cat. | 85.5 % | 0.23 (0.16–0.31) | Minimal | 5.3 % |
| | | 4-cat. | 54.4 % | 0.52 (0.33–0.71) | Weak | 27.0 % |
| Endoscopy technique | Front fiberoptic | 3-cat. | 86.2 % | 0.25 (0.18–0.32) | Minimal | 6.3 % |
| | | 4-cat. | 72.2 % | 0.45 (0.37–0.53) | Weak | 20.3 % |
| | Back fiberoptic | 3-cat. | 82.5 % | 0.27 (0.19–0.35) | Minimal | 7.3 % |
| | | 4-cat. | 74.9 % | 0.47 (0.38–0.57) | Weak | 22.1 % |
| | Transoral rigid endoscopy | 3-cat. | 86.2 % | 0.36 (0.20–0.35) | Minimal | 13.0 % |
| | | 4-cat. | 80.3 % | 0.33 (0.21–0.46) | Minimal | 10.9 % |
| Imaging technique | CT alone | 3-cat. | 93.1 % | 0.01 (-0.04–0.06) | Minimal | 0.0 % |
| | MR w/o CT | Radiologic | 62.7 % | 0.36 (0.20–0.52) | Minimal | 13.0 % |
| | | Radiologic | 72.5 % | 0.33 (-0.06–0.73) | Minimal | 10.9 % |

Mode-based re-classification and its prognostic significance

Mode-based re-classification of VCAU mobility according to the 4-category classification was distributed as follows: normal mobility (67, 18.3 %), hypomobility (146, 39.9 %), fixation (144, 39.3 %), and mobility not evaluable (9, 2.5 %) (Table 4, Figure 2). Thus, 290 (79.2 %) patients fell under the “reduced mobility” category according to the 3-category classification. Overall, 145 (39.6 %) cases were reclassified differently to their initial classification of VCAU mobility. Mode-based re-classification of tumor extension based on available contrast-enhanced imaging was distributed as follows: anterior in 57 (30.3 %) tumors, posterior in 81 (43.1 %), extension with respect to the “magic plane” not evaluable in 6 (3.2 %), mode not calculable (i.e., equal number of different evaluations) in 93 (39.2 %). OS and LRC outcomes of groups generated through mode-based re-classification are detailed in the Table 4 and Supplementary Data.

Impact of mobility assessment on T category assignment

In 25 (6.8 %) tumors, T category was classified as mobility-dependent with no other factors determining assignment to T2 (11 cases) or T3 (14 cases) category. Of these cases, the entirety received at least one VCAU mobility evaluation that would have led to down-staging, whereas only 2 (0.5 %) received at least one VCAU mobility evaluation that would have led to up-staging from T2 to T3.

Table 4

Contingency table displaying the results of re-classification according to the 4-category classification alongside with 5-year overall survival (5-y OS) and locoregional control (LRC) estimates.

| Initial classification | Re-classification | Re-classification | | | | 5-y OS | 5-y LRC |
|------------------------|-------------------|-------------------|------------------|-------------------|---------------|--------|---------|
| | | Normal mobility | Hypomobility | Fixation | Not evaluable | | |
| Hypomobility (n = 192) | 60 | 101 | 25 | 6 | 75.5 % | 86.5 % | |
| | (5-y OS: 78.9 %) | (5-y OS: 75.9 %) | (5-y OS: 70.5 %) | (5-y OS: 60.0 %) | | | |
| Fixation (n = 174) | 7 | 45 | 119 | 3 | 63.1 % | 83.8 % | |
| | (5-y OS: 68.6 %) | (5-y OS: 67.6 %) | (5-y OS: 59.9 %) | (5-y OS: 100.0 %) | | | |
| 5-y OS | | 78.0 % | 73.5 % | 61.8 % | 80.0 % | | |
| 5-y LRC | | 90.9 % | 82.5 % | 86.5 % | 100.0 % | | |

Discussion

The present collaborative study aimed to test the reliability of a very basic assessment in laryngeal oncology, namely VCAU mobility. Progressive loss of VCAU mobility is an important phase in the natural history of LSCC. Impairment of vocal fold mobility is initially determined by paraglottic space and vocal muscle infiltration.[18–22] Subsequent fixation of the arytenoid can be caused by 4 different mechanisms, including 1) a “weight effect” determined by supraglottic LSCC; [14,19,23] 2) extension into the posterior portion of the inferior paraglottic space, where the thyroarytenoid muscles are located and where the vocal process should rotate during vocal fold abduction; [4,19,20] 3) cricoarytenoid junction and lateral cricoarytenoid muscle involvement;[11,24] 4) posterior cricoarytenoid muscle infiltration with hypopharyngeal and recurrent laryngeal nerve involvement.[1,11]

Impairment of VCAU mobility represents a sign of LSCC progression to an intermediate-to-advanced stage. This is well expressed by its long-term inclusion in the criteria to stage laryngeal cancer. The terms “impaired cord mobility” and “vocal cord fixation” have appeared since the 1st Edition of Cancer Staging Manual was published by the American Joint Committee on Cancer, in 1977.[25] These VCAU mobility alterations were introduced to identify T2 cancers in the glottis and T3 cancers in any laryngeal subsite, respectively. The founding Editors of the Cancer Staging Manual adroitly noted that “as new information becomes available about etiology and various methods of diagnosis and treatment, the classification and staging of cancer will change”.[25] To date, however, “impaired cord mobility” and “vocal cord fixation” were maintained throughout all TNM Editions and are part of the nomenclature

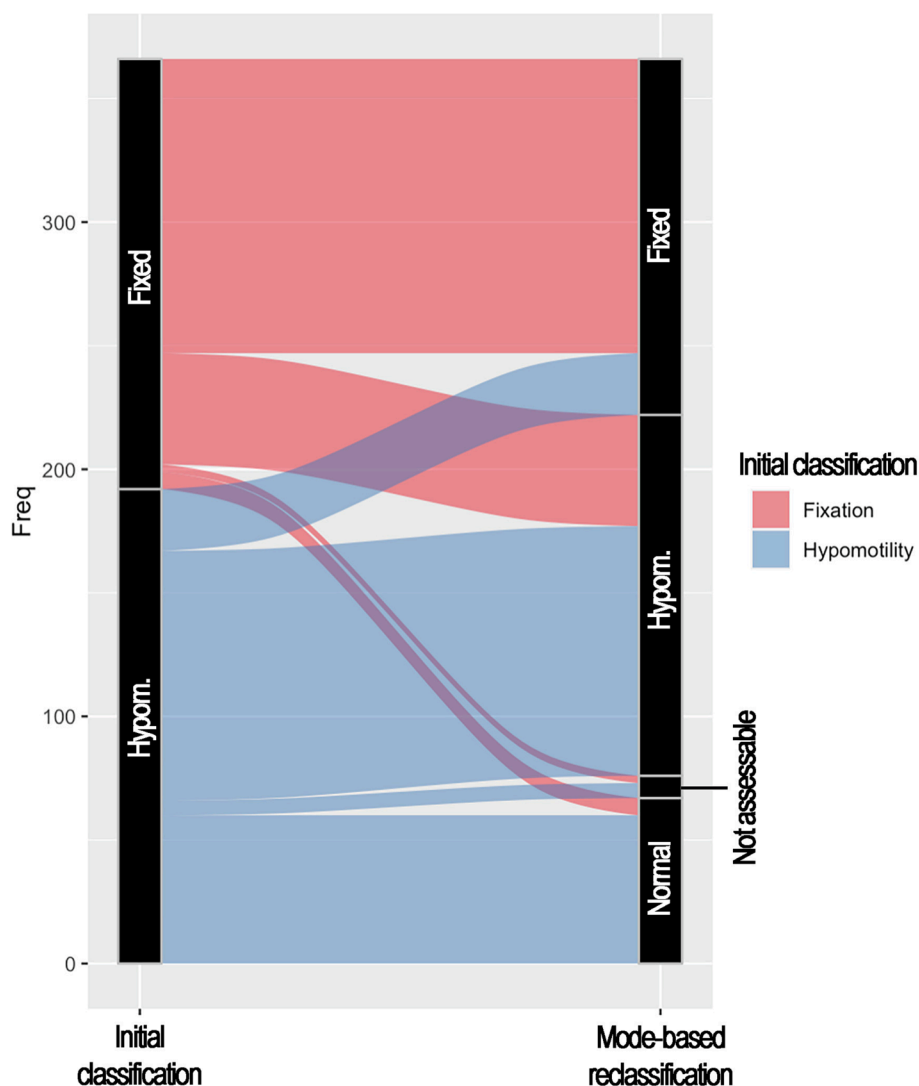


Fig. 2. Alluvial plot displaying the re-classification process from the initial classification to the 4-category classification. Freq, absolute frequency; hypom., hypomobility.

pertaining to laryngeal physiopathology.[26] Impaired mobility of the true vocal cord was also advocated to further stratify T2 glottic cancers into T2a (with normal mobility) and T2b (with impaired mobility), with the second group displaying a worse prognosis.[27–29] Although this prognostic stratification was corroborated by a meta-analysis,[30] these subcategories were not incorporated into the TNM classification. A prognostic gradient from VCAU normal mobility to fixation has also been observed in the present study, with OS decreasing from 78.0 % to 61.8 % and LRC from 90.9 % to 82.5–86.5 % at 5 years (Table 4; Figure 3).

Besides having implications on tumor staging and prognosis, the degree of VCAU mobility impairment has always been considered to be a relevant factor for treatment selection. For instance, patients with LSCC with impaired vocal fold mobility are potential candidates to OPHL, [31,32] whereas fixation generally suggests the need for total laryngectomy.[33] However, vertical laryngectomy and more recently OPHL, with special reference to type II + ARY or type III + ARY/CAU OPHL, [34] was demonstrated to be effective in highly selected cases of LSCC with VCAU fixation. [1,16,35,36] Although there is no consensus in this regard, some authors suggested neoadjuvant chemotherapy prior to OPHL in such circumstances.[37–40] On the non-surgical side, neither impaired mobility nor fixation are absolute contraindications to organ preservation strategies.[15,41] VCAU remobilization during induction

or definitive treatment is considered a sign of response to treatment.[41] However, pretreatment VCAU fixation substantially reduces locoregional control.[42] When comparing the results of the Veterans Affairs Laryngeal Cancer Study Group and RTOG 91–11 studies with a trial conducted by “Groupe d’Etude des Tumeurs de la Tête et du Cou” (GETTEC) (rate of VCAU fixation: 188/332 [56.6 %],[43,44] 240/518 [46.3 %],[45,46] and 68/68 [100 %] [47], respectively), one could argue that the non-inferiority of non-surgical treatment to total laryngectomy is questionable in patients with VCAU fixation. Indeed, the GETTEC study showed that the 2-year OS of the total laryngectomy group was higher compared with the induction chemotherapy group in patients with VCAU fixation.[47] Consistently, a recent National Cancer Database study on 10,216 patients reported that those with vocal cord-fixed cT3M0 LSCC who underwent surgery had higher survival compared with those receiving non-surgical treatment.[48].

Although the correlation between VCAU mobility and LSCC stage, prognosis, and response to treatment is unquestionable, the findings on inter- and intra-observer reliability presented herein pose substantial doubts on whether its clinical assessment should have a key role in laryngeal oncology. When using the 4-category classification of VCAU mobility, almost half of cases showed a low concordance (181/366, 49.5 %), which means that one in two cases would have a high chance of receiving a dissimilar judgement if evaluated by a different physician.

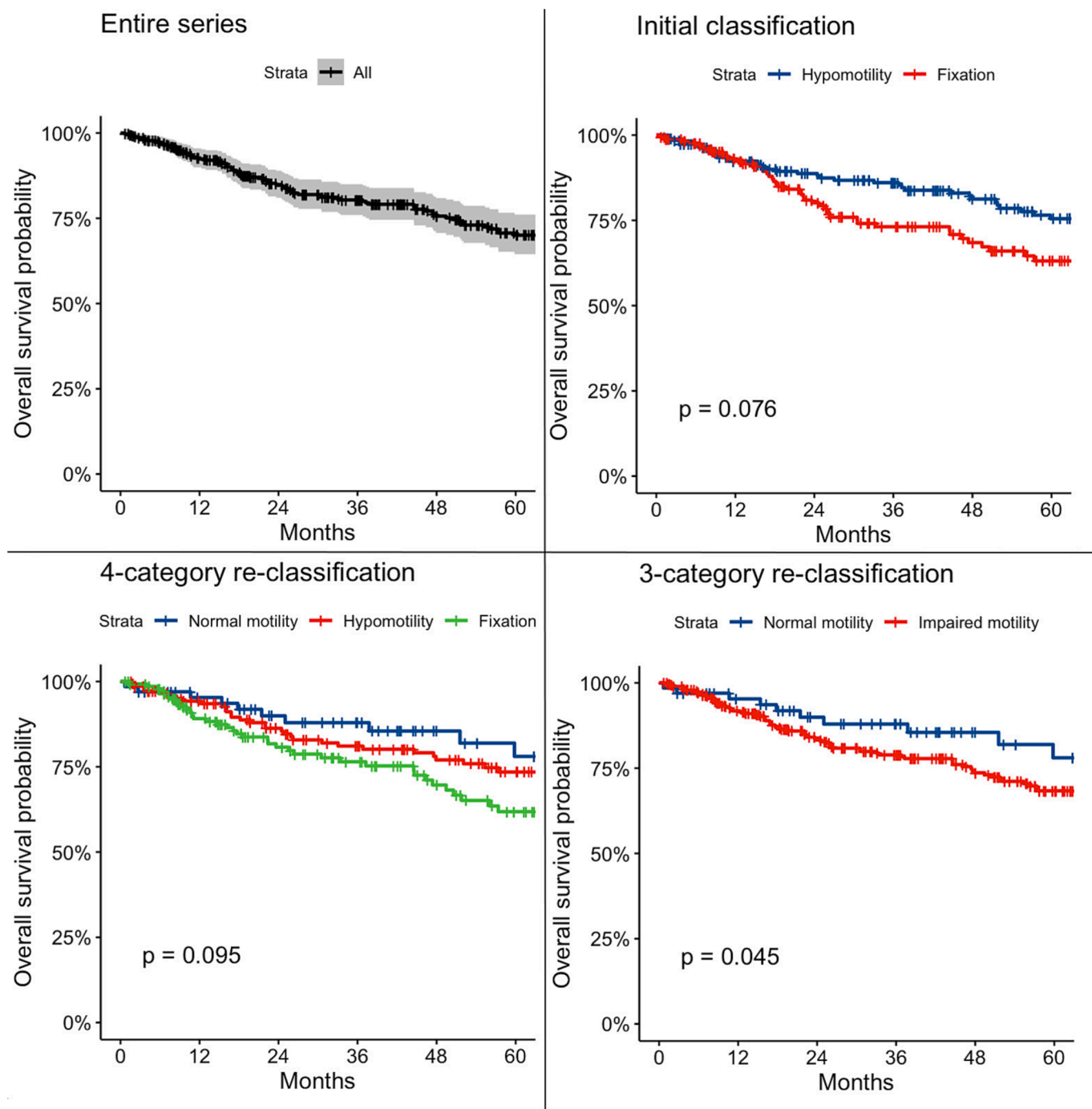


Fig. 3. Survival plots showing overall survival for the entire series and stratified according to the initial classification, 4-category classification, and 3-category classification.

Consistently, inter-rater κ was low ($\kappa = 0.46$) and was not improved by simplifying the classification to 3 categories ($\kappa = 0.40$). Of note, the fact that κ values did not improve with years of experience suggests that VCAU mobility assessment is scarcely trainable in terms of inter-observer reliability. The causes responsible for this poor inter-observer reliability are potentially numerous, including: 1) lack of defined visual criteria to diagnose and grade mobility reduction; 2) lack of a standardized methodology to perform laryngeal endoscopy; 3) confounding effect determined by exophytic tumors and/or pooling (as witnessed by lower inter-rater agreement values in supraglottic LSCC); and 4) the fact that real-time clinical judgement can be influenced by the full picture of the case (e.g., history, symptoms, imaging) to a greater

extent than the asynchronous evaluation of a recorded video. Irrespective of the specific cause, these data unveil the urgent need for more reliable and reproducible methods to assess VCAU mobility. Of note, this would likely be more relevant to prognosis and therapy of LSCC with VCAU mobility impairment, since the impact on staging is rather limited with only 6.8 % of tumors being mobility-dependent in terms of T category assignment in the present cohort. Overall, subjective evaluation of LSCC-induced mobility impairment leads to inconsistencies in interpretation among healthcare providers, possible misclassification of cancer stage, lack of reproducibility of scientific results, and the potential for overly aggressive or insufficient treatment.

Interestingly, intra-rater agreement seemed to be more dependent

upon simplicity of VCAU mobility classification, with 60.0 % of raters showing a moderate-to-strong repeatability with the 3-category classification. These findings suggest that longitudinal evaluation of a patient affected by LSCC, as happens during induction or definitive non-surgical treatment, should be performed by the same operator and by adopting a simple classification in order to minimize the risk of inconsistent evaluations. Moreover, reliability of videolaryngoscopies was higher when the exam was conducted with a transnasal fiberoptic technique, irrespective of the front or back setting, compared with transoral endoscopic evaluations. Transoral endoscopy of the larynx might easily elicit the pharyngeal and/or laryngeal adductor reflex, [49,50] which could both impact VCAU mobility and somehow influence its evaluability.

Radiologic assessment of anterior-posterior extension of LSCC did not show a satisfactory inter-rater agreement ($\kappa = 0.36$), with no relevant differences in cases studied with CT alone versus MR with or without CT. However, intra-rater agreement was very high ($\kappa = 0.83-0.97$). Since the “magic plane” is well defined and relatively easy to be delineated, [2] poor inter-observer reliability might be related to different criteria used by radiologists to contour the macroscopic border of the tumor within the paraglottic space. Thus, implementation of radiologic techniques that optimize delineation of the tumor, such as diffusion weighted imaging-including MR and dual-layer spectral detector CT, [51,52] would be relevant to overcome this potential limitation. These data suggest that transversal (*i.e.*, of different patients) and longitudinal (*i.e.*, of the same patients at different time points) imaging evaluation should be performed by a selected group of radiologists with high expertise in head and neck radiology, and not dispersed throughout diverse radiology services and institutions. Moreover, assessment of LSCC local extension may be unnecessarily challenging if the neck is not imaged following the recommended anteriorly oriented plane parallel to the true vocal cords. [53] This suboptimal scenario did not represent an exclusion criterion for the present study and might have impacted inter-rater agreement. As a final remark, taking into account the poor reliability of clinical VCAU assessment and the additional information provided by imaging, the logical conclusion is that radiologic analysis should be prioritized over endoscopic evaluation of VCAU mobility to infer posterior laryngeal extension. [1,2,54,55].

Based on the results presented herein, some potential solutions can be proposed, the first being the omission of laryngeal mobility from the TNM classification of LSCC in view of the poor intra- and inter-observer reliability of videolaryngoscopic assessment. However, VCAU mobility impairment is an undisputable clinical sign of deep cancer extension and its exclusion from the criteria to stratify patients in different T categories should be considered cautiously. One potential strategy might be to consider instead the radiologic involvement of key anatomic areas that are strategic in the physiopathology of VCAU paresis/paralysis (*e.g.*, the posterior portion of the paraglottic space and cricoarytenoid joint). In this setting, mobility impairment would be used as guidance for radiologic assessment of specific patterns of local cancer spread and not as a criterion for T classification. Another solution might be to resort to an artificial intelligence-based tool capable of classifying videolaryngoscopies in terms of laryngeal mobility [56–58]. This strategy would bypass the subjectivity of human judgement, but would require large-scale applicability to be incorporated among the criteria for staging LSCC.

The present study has three main limitations that warrant comment. First, the concept of VCAU included both the true vocal cord and arytenoid. This inclusive definition does not differentiate fixation of only one among these two structures (with the other maintaining some mobility) from partial mobility deficit of both of them. This implies, for instance, that the scenario consisting of a fixed true vocal cord with mobile arytenoid was classified as VCAU with partially reduced mobility, but, according to the TNM classification criteria, [9,10] it would have been categorized as T3 LSCC. However, this limitation could have influenced only the analysis of the impact of mobility assessment on T category assignment: within the 11 T2 mobility-dependent LSCC

there might be cases with fixed true vocal cord and mobile arytenoid, to be actually classified as T3. This potential misclassification does not significantly affect any of the results of the present study. Moreover, the poor reliability observed using a more simplistic approach based on the concept of VCAU suggests that sophistication of mobility assessment by differentiating true vocal cord and arytenoid could even worsen reproducibility. Second, videolaryngoscopies and imaging were not uniform in terms of technical features, including the execution technique and resolution; this might have influenced agreement to some extent. Third, the experience of raters ranged considerably, possibly impacting on results such as mode-based re-classification. However, these limitations confer a “real-world” nature to the study, which is in line with the need for universal applicability of staging and prognostic systems such as TNM. [9].

Conclusions

The present study demonstrated, through a large number of clinical and radiologic evaluations, that the current methods to assess VCAU mobility and posterior extension beyond the “magic plane” in LSCC are flawed by weak inter-observer agreement and reliability. This finding challenges the role that is currently attributed to VCAU mobility impairment in terms of staging, prognosis, and selection of treatment.

Supraglottic LSCC were associated with lower inter-rater agreement than cancers of the glottis. Transnasal fiberoptic techniques conferred higher reliability, irrespective of the front or back setting, compared with transoral endoscopy. Years of experience in laryngeal oncology were not directly associated with inter-observer reliability. Intra-rater agreement of VCAU mobility assessment was substantially improved when adopting a classification distinguishing only normal, impaired or not valuable motion. Thus, longitudinal evaluation of patients should preferably be performed by a single operator.

Radiologic evaluation was characterized by very high intra-rater agreement but weak inter-observer reliability, regardless of imaging technique adopted. Accordingly, patients with intermediate-to-advanced LSCC should be referred to dedicated radiologists with experience in head and neck oncology; radiologic analysis rather than endoscopic evaluation of VCAU mobility should be relied on to infer posterior laryngeal extension.

As a step forward of this project, the ARYFIX collaborative group will perform a retrospective survival analysis to assess the outcomes of different treatment strategies on patients with VCAU mobility-impaired LSCC.

CRedit authorship contribution statement

M. Ferrari: Writing – review & editing, Writing – original draft, Software, Methodology, Investigation, Formal analysis, Conceptualization. **F. Mularoni:** Writing – review & editing, Writing – original draft, Validation, Investigation, Formal analysis, Data curation, Conceptualization. **S. Taboni:** Writing – review & editing, Validation, Investigation, Formal analysis, Data curation. **E. Crosetti:** Visualization, Investigation, Data curation. **C. Pessina:** Investigation. **A.L.C. Carobbio:** . **N. Montalto:** Writing – original draft, Visualization, Formal analysis, Data curation. **F. Marchi:** Writing – review & editing, Investigation, Data curation. **A. Vural:** Writing – review & editing, Validation, Investigation, Data curation. **A. Paderno:** Writing – review & editing, Investigation, Data curation. **S. Caprioli:** Investigation, Data curation. **P. Gaudioso:** Investigation, Data curation. **M. Fermi:** Validation, Data curation. **F. Rigoni:** Visualization, Data curation. **T. Saccardo:** Validation, Data curation. **G. Contro:** Writing – review & editing, Investigation, Data curation. **A. Ruaro:** Validation, Data curation. **A. Lo Manto:** Data curation. **C. Varago:** Visualization, Data curation. **M. Baldovin:** Validation, Data curation. **L. Bandolin:** Visualization, Data curation. **M. Filauero:** Visualization, Data curation. **C. Sampieri:** Validation. **F. Misale:** Visualization, Data curation. **A. Ioppi:** Validation, Data curation.

F. Carta: Validation, Data curation. **M. Ramanzin:** Data curation. **M. Ravanelli:** Investigation, Data curation. **V. Maiolo:** Visualization, Data curation. **I. Bertotto:** Data curation. **F. Del Bon:** Visualization, Data curation. **D. Lancini:** Data curation. **C. Mariani:** Visualization. **V. Marrosu:** Visualization. **M. Tatti:** Visualization. **S. Çağlı:** Data curation. **I. Yüce:** Visualization. **M. Gündoğ:** Visualization. **S. Dogan:** Visualization. **G. Anile:** Writing – review & editing, Data curation. **C. Gottardi:** Validation. **F. Busato:** Validation. **A. Vallin:** Visualization. **F. Genarini:** Visualization. **P. Bossi:** Supervision. **M.G. Ghi:** . **M. Lionello:** Supervision, Data curation. **E. Zanoletti:** Supervision. **G. Marioni:** Supervision. **R. Maroldi:** Supervision. **F. Mattioli:** Supervision. **R. Puxeddu:** Supervision. **A. Bertolin:** Supervision. **LK. Presutti:** . **C. Piazza:** Supervision. **G. Succo:** Supervision. **G. Peretti:** Supervision. **P. Nicolai:** Supervision.

Declaration of competing interest

The authors declare that they have no known competing financial interests or personal relationships that could have appeared to influence the work reported in this paper.

Appendix A. Supplementary data

Supplementary data to this article can be found online at <https://doi.org/10.1016/j.oraloncology.2024.106744>.

References

- [1] Succo G, Cirillo S, Bertotto I, et al. Arytenoid fixation in laryngeal cancer: Radiological pictures and clinical correlations with respect to conservative treatments. *Cancers* 2019;11(3). <https://doi.org/10.3390/cancers11030360>.
- [2] Ravanelli M, Paderno A, Del BF, et al. Prediction of posterior paraglottic space and cricoarytenoid unit involvement in endoscopically T3 glottic cancer with arytenoid fixation by magnetic resonance with surface coils. *Cancers* 2019;11(1):1–11. <https://doi.org/10.3390/cancers11010067>.
- [3] Del Bon F, Piazza C, Lancini D, et al. Open partial horizontal laryngectomies for T3–T4 laryngeal cancer: Prognostic impact of anterior vs. posterior laryngeal compartmentalization. *Cancers* 2019;11(3). <https://doi.org/10.3390/cancers11030289>.
- [4] Lucioni M, Lionello M, Guida F, et al. The thyro-cricopharyngeal space (TCAS): Clinical and prognostic implications in laryngeal cancer. *Acta Otorhinolaryngol Ital* 2020;40(2):106–12. <https://doi.org/10.14639/0392-100X-N0373>.
- [5] Vilaseca I, Aviles-Jurado FX, Valduvicio I, et al. Transoral laser microsurgery in locally advanced laryngeal cancer: Prognostic impact of anterior versus posterior compartments. *Head Neck* 2021;43(12):3832–42. <https://doi.org/10.1002/HED.26878>.
- [6] Peretti G, Piazza C, Mora F, Garofolo S, Guastini L. Reasonable limits for transoral laser microsurgery in laryngeal cancer. *Curr Opin Otolaryngol Head Neck Surg* 2016;24(2):135–9. <https://doi.org/10.1097/MOO.0000000000000240>.
- [7] Marchi F, Missale F, Sampieri C, et al. Laryngeal compartmentalization does not affect the prognosis of T3–T4 laryngeal cancer treated by upfront total laryngectomy. *Cancers* 2020;12(8):1–18. <https://doi.org/10.3390/cancers12082241>.
- [8] Amin MB, Edge SB, Greene FL, et al. American Joint Committee on Cancer (AJCC). *AJCC Cancer Staging Manual* 2017.
- [9] Union for International Cancer Control (UICC). *Tumor Node Metastasis (TNM) Classification of Malignant Tumours*. (Brierley JD, Gospodarowicz MK, Wittekind C, eds.). Wiley-Blackwell; 2017.
- [10] Published 2022. [https://staging.seer.cancer.gov/tnm/input/2.0/larynx_glottic/clin_t?breadcrumbs=\(-schema_list-\),\(-view_schema-,-larynx_glottic-](https://staging.seer.cancer.gov/tnm/input/2.0/larynx_glottic/clin_t?breadcrumbs=(-schema_list-),(-view_schema-,-larynx_glottic-)
- [11] Katilmiş H, Öztürkcan S, Özdemir I, et al. A clinico-pathological study of laryngeal and hypopharyngeal carcinoma: Correlation of cord-arytenoid mobility with histopathological involvement. *Otolaryngol Head Neck Surg* 2007;136(2):291–5. <https://doi.org/10.1016/J.OTOHNS.2006.08.022>.
- [12] Kirchner JA. Pathways and Pitfalls in Partial Laryngectomy. <https://doi.org/10.1177/000348948409300404>. 1984;93(4):301–305. doi:10.1177/000348948409300404.
- [13] Kirchner JA, Som ML. Clinical significance of fixed vocal cord. *Laryngoscope* 1971; 81(7):1029–44. <https://doi.org/10.1288/00005537-197107000-00005>.
- [14] Brasnu D, Laccourreye H, Dulmet E, Jaubert F. Mobility of the vocal cord and arytenoid in squamous cell carcinoma of the larynx and hypopharynx: an anatomical and clinical comparative study. *Ear Nose Throat J* 1990;69(5):324–30.
- [15] Forastiere AA, Ismaila N, Lewin JS, et al. Use of larynx-preservation strategies in the treatment of laryngeal cancer: American society of clinical oncology clinical practice guideline update. *J Clin Oncol* 2018;36(11):1143–69. <https://doi.org/10.1200/JCO.2017.75.7385>.
- [16] Succo G, Crosetti E, Bertolin A, et al. Treatment for T3 to T4a laryngeal cancer by open partial horizontal laryngectomies: Prognostic impact of different pathologic tumor subcategories. *Head Neck* 2018;40(9):1897–908. <https://doi.org/10.1002/hed.25176>.
- [17] McHugh ML. Interrater reliability: The kappa statistic. *Biochemia Medica* 2012;22(3):276–82. <https://doi.org/10.11613/BM.2012.031/FULLARTICLE>.
- [18] Fermi M, Lo Manto A, Di Massa G, et al. Paraglottic Space Invasion in Glottic Laryngeal Cancer: A Clinical-Pathological Study. *Laryngoscope* 2023;133(5): 1184–90. <https://doi.org/10.1002/LARY.30335>.
- [19] Kirchner JA. Two hundred laryngeal cancers: Patterns of Growth And Spread As Seen in Serial Section. *Laryngoscope* 1977;87(4):474–82. <https://doi.org/10.1288/00005537-197704000-00002>.
- [20] Hirano M, Kurita S, Matsuoka H, Tateishi M. Vocal Fold Fixation in Laryngeal Carcinomas. *Acta Otolaryngol* 1991;111(2):449–54. <https://doi.org/10.3109/00016489109137418>.
- [21] Lionello M, Bertolin A, Nardello E, et al. Could the infiltration of the thyroarytenoid muscle define the pT2 glottic carcinoma? *Head Neck* 2019;41(10): 3639–46. <https://doi.org/10.1002/HED.25893>.
- [22] Yilmaz T, Hoşal AŞ, Gedikoglu G, Turan E, Ayas K. Prognostic Significance of Depth of Invasion in Cancer of the Larynx. *Laryngoscope* 1998;108(5):764–8. <https://doi.org/10.1097/00005537-199805000-00025>.
- [23] Tani M, Amatsu M. Discrepancies between clinical and histopathologic diagnoses in T3 pyriform sinus cancer. *Laryngoscope* 1987;97(1):93–6. <https://doi.org/10.1288/00005537-198701000-00018>.
- [24] Çağlı S, Öztürk M, Yüce I, Deniz K, Güneş E. The value of routine clinical and radiologic studies in predicting neoplastic invasion of cricoarytenoid units. *Am J Neuroradiol* 2009;30(10):1936–40. <https://doi.org/10.3174/ajnr.A1692>.
- [25] *Cancer Staging Manual*. 1st ed. American Joint Committee on Cancer; 1977.
- [26] Rosen CA, Mau T, Remacle M, et al. Nomenclature proposal to describe vocal fold motion impairment. *Eur Arch Otorhinolaryngol* 2016;273(8):1995–9. <https://doi.org/10.1007/S00405-015-3663-0/METRICS>.
- [27] Harwood AR, DeBoer G. Prognostic Factors in T2 Glottic Cancer. *Cancer* 1980;45: 991–5. [https://doi.org/10.1002/1097-0142\(19800301\)45:5](https://doi.org/10.1002/1097-0142(19800301)45:5)
- [28] Van den Bogaert W, Ostyn F, Van der Schueren E. The significance of extension and impaired mobility in cancer of the vocal cord. *Int J Radiat Oncol Biol Phys* 1983;9(2):181–4. [https://doi.org/10.1016/0360-3016\(83\)90096-2](https://doi.org/10.1016/0360-3016(83)90096-2).
- [29] Gorphe P, Blanchard P, Breuskin I, Temam S, Tao Y, Janot F. Vocal fold mobility as the main prognostic factor of treatment outcomes and survival in stage II squamous cell carcinomas of the glottic larynx. *J Laryngol Otol* 2015;129(9):903–9. <https://doi.org/10.1017/S002221511500184X>.
- [30] McCoul ED, Har-El G. Meta-analysis of impaired vocal cord mobility as a prognostic factor in T2 glottic carcinoma. *Archives of otolaryngology–head & neck surgery* 2009;135(5):479–86. <https://doi.org/10.1001/ARCHOTO.2009.47>.
- [31] Piquet JJ, Chevalier D. Subtotal laryngectomy with crico-hyoidoepiglottopexy for the treatment of extended glottic carcinomas. *Am J Surg* 1991;162(4):357–61. [https://doi.org/10.1016/0002-9610\(91\)90148-7](https://doi.org/10.1016/0002-9610(91)90148-7).
- [32] Chevalier D, Laccourreye O, Laccourreye H, Brasnu D, Piquet JJ. Cricohyoidoepiglottopexy for glottic carcinoma with fixation or impaired motion of the true vocal cord: 5-year oncologic results with 112 patients. *Ann Otol Rhinol Laryngol* 1997;106(5):364–9. <https://doi.org/10.1177/000348949710600502>.
- [33] Ambrosch P, Fazel A. Functional organ preservation in laryngeal and hypopharyngeal cancer *GMS current topics in otorhinolaryngology, head and neck surgery* 2011;10: Doc02. <https://doi.org/10.3205/cto000075>.
- [34] Succo G, Peretti G, Piazza C, et al. Open partial horizontal laryngectomies: A proposal for classification by the working committee on nomenclature of the European Laryngological Society. *Eur Arch Otorhinolaryngol* 2014;271(9): 2489–96. <https://doi.org/10.1007/S00405-014-3024-4/FIGURES/6>.
- [35] Biller HF, Lawson W. Partial laryngectomy for vocal cord cancer with marked limitation or fixation of the vocal cord. *Laryngoscope* 1986;96(1):61–4. <https://doi.org/10.1288/00005537-198601000-00011>.
- [36] Lesinski SG, Bauer WC, Ogura JH. Hemilaryngectomy for t3 (fixed cord) epidermoid carcinoma of larynx. *Laryngoscope* 1976;86(10):1563–71. <https://doi.org/10.1288/00005537-197610000-00010>.
- [37] Laccourreye O, Salzer SJ, Brasnu D, Shen W, Laccourreye H, Weinstein GS. Glottic Carcinoma with a Fixed True Vocal Cord: Outcomes after Neoadjuvant Chemotherapy and Supracricoid Partial Laryngectomy with Cricohyoidoepiglottopexy. *Otolaryngol Head Neck Surg* 1996;114(3):400–6. <https://doi.org/10.1016/S0194-59989670209-7>.
- [38] Laccourreye O, Brasnu D, Biacabe B, Hans S, Seckin S, Weinstein G. Neo-adjuvant chemotherapy and supracricoid partial laryngectomy with cricohyoidopexy for advanced endolaryngeal carcinoma classified as T3–T4: 5- Year oncologic results. *Head Neck* 1998;20(7):595–9. [https://doi.org/10.1002/\(SICI\)1097-0347\(199810\)20:7<595::AID-HED3>3.0.CO;2-K](https://doi.org/10.1002/(SICI)1097-0347(199810)20:7<595::AID-HED3>3.0.CO;2-K).
- [39] Luna-Ortiz K, Reynoso-Noveron N, Zacarias-Ramon LC, Alvarez-Avitia M, Luna-Peteuil Z, Garcia-Ortega DY. Supracricoid Partial Laryngectomy With and Without Neoadjuvant Chemotherapy in Glottic Cancer. *Laryngoscope* 2022;132(1):156–62. <https://doi.org/10.1002/LARY.29713>.
- [40] Luna-Ortiz K, Villavicencio-Valencia V, Rodriguez-Falconi A, et al. Induction chemotherapy followed by supracricoid partial laryngectomy (SCPL) with cricohyoidoepiglottopexy (CHEP) in T3N0 arytenoid fixation-related glottic cancer. *B-ENT* 2016;12(4):271–7.
- [41] Solares CA, Wood B, Rodriguez CP, et al. Does vocal cord fixation preclude nonsurgical management of laryngeal cancer? *Laryngoscope* 2009;119(6):1130–4. <https://doi.org/10.1002/LARY.20225>.

- [42] Milinis K, King R, Lancaster J, et al. Predictors of non-functional larynx following (chemo)radiotherapy for locally advanced laryngeal cancer. *Clin Otolaryngol* 2023;48(5):773–8. <https://doi.org/10.1111/COA.14074>.
- [43] Wolf G, Fisher S, Hong W, et al. Induction chemotherapy plus radiation compared with surgery plus radiation in patients with advanced laryngeal cancer. *N Engl J Med* 1991;324(24):1685–90. <https://doi.org/10.1056/NEJM199106133242402>.
- [44] Spaulding MB, Fischer SG, Wolf GT. Tumor response, toxicity, and survival after neoadjuvant organ-preserving chemotherapy for advanced laryngeal carcinoma. The Department of Veterans Affairs Cooperative Laryngeal Cancer Study Group. <https://doi.org/10.1200/JCO.1994.12.8.1592>. 2016;12(8):1592-1599. doi:10.1200/JCO.1994.12.8.1592.
- [45] Forastiere AA, Zhang Q, Weber RS, et al. Long-term results of RTOG 91–11: a comparison of three nonsurgical treatment strategies to preserve the larynx in patients with locally advanced larynx cancer. *J Clin Oncol* 2013;31(7):845–52. <https://doi.org/10.1200/JCO.2012.43.6097>.
- [46] Forastiere AA, Goepfert H, Maor M, et al. Concurrent Chemotherapy and Radiotherapy for Organ Preservation in Advanced Laryngeal Cancer. *N Engl J Med* 2003;349(22):2091–8. <https://doi.org/10.1056/NEJMoa031317>.
- [47] Richard JM, Sancho-Garnier H, Pessey JJ, et al. Randomized trial of induction chemotherapy in larynx carcinoma. *Oral Oncol* 1998;34(3):224–8. [https://doi.org/10.1016/S1368-8375\(97\)00090-0](https://doi.org/10.1016/S1368-8375(97)00090-0).
- [48] Ideker HC, Walker RJ, Mazul A, Massa ST. Determining the Efficacy of Surgical Versus Non-Surgical Management in T3M0 Laryngeal Cancer With Cord Fixation. *Ann Otol Rhinol Laryngol* 2024;133(1):78–86. <https://doi.org/10.1177/00034894231187478>.
- [49] Sivakumar S, Physiology PA, Reflex G. *StatPearls*. Published online March 12, 2023..
- [50] Domer AS, Kuhn MA, Belafsky PC. Neurophysiology and Clinical Implications of the Laryngeal Adductor Reflex. *Current Otorhinolaryngology Reports* 2013;1(3):178–82. <https://doi.org/10.1007/S40136-013-0018-5/FULLTEXT.HTML>.
- [51] Zheng T, Xiao Y, Yang F, Dai G, Wang F, Chen G. The value of dual-layer spectral detector CT in preoperative T staging of laryngeal and hypopharyngeal squamous cell carcinoma. *Eur J Radiol* 2024;171:111287. <https://doi.org/10.1016/j.ejrad.2024.111287>.
- [52] Smits HJG, Raaijmakers CPJ, de Ridder M, et al. Improved delineation with diffusion weighted imaging for laryngeal and hypopharyngeal tumors validated with pathology. *Radiother Oncol*. Published online February 23, 2024:110182. doi:10.1016/j.radonc.2024.110182.
- [53] Khan A, Fawzy WMS, Habib SS, Sultan M. Novel and pragmatic exploration of variation in glottic parameters in non-parallel versus parallel vocal cord CT planes with potential reporting pitfalls. *PLoS One* 2023;18(10):e0293659.
- [54] Chiesa-Estomba CM, Ravanelli M, Farina D, et al. Imaging checklist for preoperative evaluation of laryngeal tumors to be treated by transoral microsurgery: guidelines from the European Laryngological Society. *Eur Arch Otorhinolaryngol* 2020;277(6):1707–14. <https://doi.org/10.1007/S00405-020-05869-0/FIGURES/5>.
- [55] Benazzo M, Sovardi F, Preda L, et al. Imaging Accuracy in Preoperative Staging of T3–T4 Laryngeal Cancers. *Cancers* 2020;12(5). <https://doi.org/10.3390/CANCERS12051074>.
- [56] Villani FP, Paderno A, Fiorentino MC, Casella A, Piazza C, Moccia S. Classifying Vocal Folds Fixation from Endoscopic Videos with Machine Learning. *Annu Int Conf IEEE Eng Med Biol Soc* 2023;2023:1–4. <https://doi.org/10.1109/EMBC40787.2023.10340017>.
- [57] Yousef AM, Deliyiski DD, Zacharias SRC, de Alarcon A, Orlikoff RF, Naghibolhosseini M. A Deep Learning Approach for Quantifying Vocal Fold Dynamics During Connected Speech Using Laryngeal High-Speed Videendoscopy. *J Speech Lang Hear Res* 2022;65(6):2098–113. https://doi.org/10.1044/2022_JSLHR-21-00540.
- [58] Fehling MK, Grosch F, Schuster ME, Schick B, Lohscheller J. Fully automatic segmentation of glottis and vocal folds in endoscopic laryngeal high-speed videos using a deep Convolutional LSTM Network. *PLoS One* 2020;15(2):e0227791.

Update

Oral Oncology

Volume 155, Issue , August 2024, Page

DOI: <https://doi.org/10.1016/j.oraloncology.2024.106887>



Corrigendum



Corrigendum to “How reliable is assessment of true vocal cord-arytenoid unit mobility in patients affected by laryngeal cancer? a multi-institutional study on 366 patients from the ARYFIX collaborative group” [Oral Oncol. 152C (2024) 106744]

M. Ferrari^{a,b,*}, F. Mularoni^{a,b,1}, S. Taboni^b, E. Crosetti^c, C. Pessina^d, A.L.C. Carobbio^b, N. Montalto^b, F. Marchi^{e,f}, A. Vural^g, A. Paderno^h, S. Caprioliⁱ, P. Gaudio^{a,b}, M. Fermi^{j,k}, F. Rigoni^{a,b}, T. Saccardo^{a,b}, G. Contro^b, A. Ruaro^{a,b}, A. Lo Manto^l, C. Varago^m, M. Baldovinⁿ, L. Bandolin^o, M. Filauro^{e,f}, C. Sampieri^{p,q}, F. Missale^r, A. Ioppi^s, F. Carta^t, M. Ramanzin^u, M. Ravanelli^v, V. Maiolo^w, I. Bertotto^x, F. Del Bon^y, D. Lancini^y, C. Mariani^t, V. Marrosu^t, M. Tatti^t, S. Çağlı^z, I. Yüce^z, M. Gündoğ^{aa}, S. Dogan^{ab}, G. Anile^{ac}, C. Gottardi^{ac}, F. Busato^{ad}, A. Vallin^{e,f}, F. Gennarini^y, P. Bossi^{ae,af}, M.G. Ghi^{ac}, M. Lionello^m, E. Zanoletti^{a,b}, G. Marioni^a, R. Maroldi^v, F. Mattioli^{ag}, R. Puxeddu^{t,ah}, A. Bertolin^m, L. Presutti^{j,k}, C. Piazza^y, G. Succo^{ca}, G. Peretti^{e,f}, P. Nicolai^{a,b}

^a Department of Neuroscience, University of Padova, Padova, Italy

^b Unit of Otorhinolaryngology – Head and Neck Surgery, Azienda Ospedale Università Padova, Padova, Italy

^c Otorhinolaryngology Department – Head Neck Cancer Unit, San Giovanni Bosco Hospital, Turin, Italy

^d Radiology Unit, Sant'Antonio Hospital, University of Padova, Padova, Italy

^e Unit of Otorhinolaryngology, Head and Neck Surgery, IRCCS Ospedale Policlinico San Martino, Largo Rosanna Benzi 10, 16121 Genoa, Italy

^f Department of Surgical Sciences and Integrated Diagnostics (DISC), University of Genova, Genoa, Italy

^g Otorhinolaryngology Unit, Istanbul University - Cerrahpasa, Cerrahpasa Medical Faculty, Istanbul, Turkey

^h IRCCS Humanitas Research Hospital, via Manzoni 56, 20089 Rozzano, Milan, Italy

ⁱ Radiology Unit, San Martino Hospital, Genoa, Italy

^j Otorhinolaryngology Unit, Azienda Ospedaliera Universitaria di Bologna IRCCS, Bologna, Italy

^k Department of Surgical and Medical Sciences, University of Bologna, Bologna, Italy

^l Otorhinolaryngology Unit, Infermi Hospital, Rimini, Italy

^m Otorhinolaryngology Unit, Vittorio Veneto Hospital, Treviso, Italy

ⁿ Otorhinolaryngology Unit, San Martino di Belluno Hospital, Belluno, Italy

^o Otorhinolaryngology Unit, Hospital of Santorso, Vicenza, Italy

^p Department of Experimental Medicine (DIMES), University of Genova, Italy

^q Unit of Head and Neck Tumors, Hospital Clínic, Barcelona, Spain

^r Department of Otorhinolaryngology, Head and Neck Surgery, Maastricht University Medical Center, 6202 AZ Maastricht, The Netherlands

^s Department of Otorhinolaryngology-Head and Neck Surgery, “S. Chiara” Hospital, Azienda Provinciale per i Servizi Sanitari (APSS), Trento, Italy

^t Otorhinolaryngology Unit, Azienda Ospedaliero-Universitaria di Cagliari, Cagliari, Italy

^u Radiology Unit, Hospital of Vicenza, Vicenza, Italy

^v Radiology Unit, ASST Spedali Civili di Brescia, University of Brescia, Brescia, Italy

^w Pediatric and Adult Cardiothoracic and Vascular, Oncohematologic and Emergency Radiology Unit (IRCCS AOUBO), University of Bologna, Italy

^x Radiology Unit, IRCCS Istituto di Candiolo, Turin, Italy

^y Otorhinolaryngology Unit, ASST Spedali Civili di Brescia, University of Brescia, Brescia, Italy

^z Otorhinolaryngology Unit, Erciyes University, Kayseri, Turkey

^{aa} Department of Radiation Oncology, Erciyes University, Kayseri, Turkey

^{ab} Department of Radiology, Erciyes University, Kayseri, Turkey

^{ac} Unit of Medical Oncology 2, “Istituto Oncologico Veneto”, Padova, Italy

^{ad} Unit of Radiation Oncology, Policlinico Abano, Padova, Italy

^{ae} Department of Biomedical Sciences, Humanitas University, Via Rita Levi Montalcini 4, 20072 Pieve Emanuele, Milan, Italy

DOI of original article: <https://doi.org/10.1016/j.oraloncology.2024.106744>.

* Corresponding author at: Department of Neuroscience, University of Padova, Unit of Otorhinolaryngology – Head and Neck Surgery, Azienda Ospedale – Università Padova, Padova, Italy.

E-mail address: marco.ferrari@unipd.it (M. Ferrari).

<https://doi.org/10.1016/j.oraloncology.2024.106887>

Available online 8 June 2024

1368-8375/© 2024 The Author(s). Published by Elsevier Ltd. All rights are reserved, including those for text and data mining, AI training, and similar technologies.

^{af} IRCCS Humanitas Research Hospital, via Manzoni 56, 20089 Rozzano, Milan, Italy

^{ag} Otorhinolaryngology Unit, University of Modena, Modena, Italy

^{ah} King's College Hospital London, Dubai, United Arab Emirates

^{ai} Oncology Department, University of Turin, Turin, Italy

The authors regret that affiliation number 1 of the original publication is amended to two different affiliations, as follows: “Department of Neuroscience, University of Padova, Padova, Italy” and “Unit of

Otorhinolaryngology – Head and Neck Surgery, Azienda Ospedale - Università Padova, Padova, Italy”.

The authors would like to apologise for any inconvenience caused.

¹ MF and FM equally share the first authorship.