

Alma Mater Studiorum Università di Bologna
Archivio istituzionale della ricerca

Prevalence and risk indicators of midfacial peri-implant soft tissue dehiscence at single site in the esthetic zone: A cross-sectional clinical and ultrasonographic study

This is the final peer-reviewed author's accepted manuscript (postprint) of the following publication:

Published Version:

Tavelli, L., Barootchi, S., Majzoub, J., Chan, H.-., Stefanini, M., Zucchelli, G., et al. (2022). Prevalence and risk indicators of midfacial peri-implant soft tissue dehiscence at single site in the esthetic zone: A cross-sectional clinical and ultrasonographic study. JOURNAL OF PERIODONTOLOGY, 93(6), 857-866 [10.1002/JPER.21-0402].

Availability:

This version is available at: <https://hdl.handle.net/11585/872410> since: 2022-02-28

Published:

DOI: <http://doi.org/10.1002/JPER.21-0402>

Terms of use:

Some rights reserved. The terms and conditions for the reuse of this version of the manuscript are specified in the publishing policy. For all terms of use and more information see the publisher's website.

This item was downloaded from IRIS Università di Bologna (<https://cris.unibo.it/>).
When citing, please refer to the published version.

(Article begins on next page)

Prevalence and risk indicators of midfacial peri-implant soft tissue dehiscence at single site in the esthetic zone: A cross-sectional clinical and ultrasonographic study

Lorenzo Tavelli*†‡§, DDS, MS, Shayan Barootchi*§, DMD, Jad Majzoub*, BDS, Hsun-Liang Chan*, DDS, MS, Martina Stefanini||, DDS, PhD, Giovanni Zucchelli*||, DDS, PhD, Oliver D. Kripfgans ¶¶**, PhD, Hom-Lay Wang*, DDS, MSD, PhD, Istvan A. Urban, DMD, MD, PhD*†††

* Department of Periodontics & Oral Medicine, University of Michigan School of Dentistry, Ann Arbor, MI, USA

† Department of Oral Medicine, Infection, and Immunity, Division of Periodontology, Harvard School of Dental Medicine, Boston, MA, USA

‡ Doctoral School of Medicine, University of Szeged, Szeged, Hungary

§ Center for clinical Research and evidence synthesis In oral Tissue Regeneration (CRITERION), Ann Arbor, MI, USA

|| Department of Biomedical and Neuromotor Sciences, University of Bologna, Bologna, Italy

¶¶ Biointerfaces Institute and Department of Biomedical Engineering, College of Engineering, Ann Arbor, MI, USA

¶¶ Department of Radiology, University of Michigan Medical School, Ann Arbor, MI, USA

†† Urban Regeneration Institute, Budapest, Hungary

Corresponding authors

Lorenzo Tavelli, DDS, MS

This is the author manuscript accepted for publication and has undergone full peer review but has not been through the copyediting, typesetting, pagination and proofreading process, which may lead to differences between this version and the [Version of Record](#). Please cite this article as [doi: 10.1002/adfm.10902](https://doi.org/10.1002/adfm.10902).

This article is protected by copyright. All rights reserved.

Department of Periodontics and Oral Medicine, University of Michigan, School of Dentistry, Ann Arbor, USA

1011 N University Avenue, Ann Arbor, MI, USA

Email: tavelli@umich.edu

Word count (without references): 3091

Tables and figures: 3 tables and 2 figures

Running title: Prevalence and risk indicators of midfacial peri-implant soft tissue dehiscence

One sentence summary: Peri-implant soft tissue dehiscences at single implant sites are common findings, in the esthetic region and they were found to be significantly associated with presence of an adjacent implant, increased time in function of the implant, higher distance between the implant platform and the crestal bone, reduced keratinized mucosa width and mucosal thickness.

Acknowledgment and conflict of interest: The study was supported by grants from Delta Dental Foundation (AWD010089 and AWD015480), American Academy of Periodontology Sunstar Innovation Award (AWD007224), and University of Michigan Department of Periodontics and Oral Medicine Clinical Research Grant (N026036). The authors do not have any financial interests, either directly or indirectly, in the products or information enclosed in the paper except Drs. Hsun-Liang Chan and Oliver D. Kripfgans are the inventor of the ultrasonography machine used in this study.

Author contributions: L.T., S.B., HL.C., M.S., G.Z., OD.K., HL. W. and IA.U contributed to the conception and design of the work. L.T., S.B., J.M collected the data; S.B. analyzed the data; L.T., S.B., J.M., HL.C. and OD.K contributed to imaging and results interpretation. L.T., S.B., and OK.D. designed the schematic illustrations and L.T., S.B. and HL.W. led the writing. L.T., S.B., HL.C., M.S., G.Z., OD.K., HL. W. and IA.U contributed to the manuscript and approved its final version.

ABSTRACT

This article is protected by copyright. All rights reserved.

Background: Esthetic complications of dental implants in the esthetic zone can have a major negative impact on patients' quality of life and perception of implant therapy. The aim of the present study was to evaluate the prevalence of peri-implant soft tissue dehiscence (PSTD) and the clinical and ultrasonographic risk indicators for this condition.

Methods: Subjects with one or more healthy single dental implants in the esthetic area were identified and recruited. Clinical and ultrasonographic measurements, including PSTD class and subclass, pocket depth, keratinized mucosa width (KMW), mucosal thickness (MT) at 1 mm and 3 mm, buccal bone distance (BBD) and buccal bone thickness, were evaluated in healthy implants and implants with PSTD.

Results: 153 subjects with a total of 176 dental implants were included. The prevalence of PSTD was 54.2% and 56.8% on a patient and implant level, respectively. The most frequent type of PSTD was the one characterized by having both an implant-supported crown longer than the clinical crown of the homologous tooth and a visible abutment/implant fixture exposed to the oral cavity. The multivariate analysis showed that the presence of an adjacent implant, a longer time of the implant in function, limited MT, reduced KMW and increased BBD were significantly associated with the presence of a PSTD.

Conclusions: PSTDs are common findings in the esthetic region. Several risk indicators for this condition, such as presence of an adjacent implant, increased time in function of the implant, higher BBD, lower KMW and MT were identified.

Key words: Dental implant, Ultrasonography, Soft tissue, gingival recession, implant therapy

1. Introduction

Dental implants have indeed revolutionized modern dentistry. While nowadays implant therapy represents a predictable option for replacing missing or hopeless teeth, implant-related complications are not rare findings¹⁻⁴. Esthetic complications of implant therapy can have a major negative impact on patients' quality of life, including anxiety in smiling, socializing, and speaking in public^{5,6}. Patients' esthetic demands have progressively increased that even a minimal discrepancy in the length of the implant-supported crown (compared to the homologous contralateral tooth) or the appearance of a metal component of the implant is considered totally unacceptable^{2,7,8}. These

esthetic complications around dental implants have been reported with several terms in the literature, however without a uniform definition. A previous report found an incidence of “recession of the soft tissue margin” around dental implants to be 57% after 6 months⁹, while Small and Tarnow concluded that an apical shift of the mucosal margin of 1 mm should be anticipated after abutment connection¹⁰. Nevertheless, without a uniform definition of implant esthetic complications/mucosal recession, only limited conclusions can be drawn regarding the prevalence of these conditions and factors associated with their incidence².

A recent article from our group proposed a definition for these complications “peri-implant soft tissue dehiscence/deficiencies” (PSTD), suggesting for the first time a classification of the different types of PSTDs⁷. It has been speculated that PSTD and gingival recession share some risk factors/indicators, including the amount, or lack of keratinized mucosa width (KMW), mucosal thickness (MT), the bucco-lingual position and the dehiscence of the buccal bone, among others^{7,11-13}. Ultrasonography has been proved to be a non-invasive and reliable technology for characterizing periodontal and peri-implant structures, such as soft tissue thickness, buccal bone levels and buccal bone thickness¹⁴⁻¹⁶.

Therefore, the aim of the present study was to evaluate the prevalence of PSTD and some clinical and ultrasonographic risk indicators for this condition.

2. Material and methods

2.1 Study registration and design

The current study was approved by the University of Michigan Medical School Institutional Review Board (IRB MED) (HUM00176741), in accordance with the Helsinki Declaration of 1975, as revised in 2013. An informed consent was obtained from all individuals who had participated in the study. The present manuscript follows the STROBE statement for improving the quality of reports of cross-sectional studies¹⁷.

2.2 Setting and participants

Subjects with one or more healthy dental implants in the esthetic area (from the right first premolar to the left first premolar) were identified and recruited from a population attending the Graduate Periodontics clinic at the Department of Periodontics and Oral Medicine, School of Dentistry, University of Michigan, Ann Arbor, USA between February 2020 and June 2021. The inclusion criteria were: 1) systemically and periodontally healthy subjects, 2) having at least one anterior dental implant with two adjacent natural teeth and/or dental implants, 3) dental implant(s) diagnosed as healthy ("absence of erythema, bleeding on probing, swelling and suppuration"^{18, 19}), 4) dental implants rehabilitated with a single implant-supported crown, 5) loading time of at least 24 months²⁰, 6) presence of the homologous contralateral natural tooth, 7) available information regarding implant characteristics and 8) patients willing to provide an informed consent and attend the study. Exclusion criteria included: 1) Multiple adjacent dental implants with PSTDs, 2) implants in the second premolar or molar region, 3) one or two adjacent edentulous area, 4) implant(s) restored with three (or more)-unit fixed bridges, single crown with cantilever or removable prosthesis, 5) diagnosis of periodontitis, 6) any confirmed peri-implant disease^{18,19}, 6) documented history of peri-implantitis or previous surgical procedures at the implant site, 7) previous soft tissue graft at the implant site and 8) missing information on the implant characteristics. The patient recruitment process, clinical assessment and ultrasonographic examination were performed by two calibrated study team members (L.T. and S.B.) following a standardized protocol as previously described^{14, 21}.

2.3 Data collection and clinical measurements

At the time of the visit, patient demographics (age, sex, smoking habit,...), and implant characteristics (type, date of surgery, prosthesis installation, ...) were obtained, as well as the following parameters by a single examiner (L.T.) :

- Presence or absence of PSTD, defined as the apical shift of the mucosal margin compared to the gingival margin of the homologous contralateral natural tooth⁷. In case of a PSTD, the class (I, II or III/IV) and subclass (a, b or c) were also identified⁷. Since the implant-supported crown was not removed in the present study, implants with a PSTD characterized by a crown profile located outside (more facial to) an imaginary curve line connecting the profile of the adjacent teeth at the level of the mucosal margin were considered as class III/IV.
- Presence or absence of an implant-supported crown longer than the clinical crown of the homologous contralateral natural tooth

- Presence or absence of the exposure of the abutment and/or implant fixture to the oral cavity
- Presence of adjacent (mesial/distal) implants
- Probing pocket depth (PD) using a periodontal probe ‡‡
- Keratinized mucosa width (KMW), defined as the vertical distance between the mucogingival junction and the mucosal margin in the mid-facial region, and measured with a periodontal probe ‡‡

2.4 Ultrasonographic image acquisition and measurements

The ultrasound equipment setup and the scanning procedures have been previously described in detail ²¹⁻²⁵. Briefly, a commercially available ultrasound imaging device §§ was coupled with a 24 MHz (64 μ m axial image resolution) and miniature-sized (approximately 30 mm long, x 18 mm wide x 12 mm thick) probe prototype (L30-8) to generate ultrasound images (pixel size 0.05 mm) ²⁶ (Figure 1 and 2).

Single image frames (“still images”) at the mid-facial aspect of the implant(s) of interest were saved in “B-mode” in the Digital Imaging and Communications in Medicine (DICOM) format. “B-mode” generates 2D grey scale images in which brightness is the result of the returned echo signal and its strength, which depends on the acoustical properties of the implant components and the peri-implant soft and hard structures. The US probe was oriented perpendicular to the occlusal plane and parallel to the long axis of the implant at its midfacial aspect ^{21, 24}.

The following measurements were computed using a commercially available software package|||, as previously described ^{14, 21, 23-25, 27, 28} and were carried out by a single experienced examiner (J.M.), who has been calibrated in previous trials ($k \geq 0.87$):

- Mucosal thickness (MT): horizontal thickness of the peri-implant soft tissue, calculated as the distance between the soft tissue margin and the abutment/implant fixture/buccal bone on a line parallel to the long axis of the implant body in the mid-facial scan. MT was measured at 1 and 3 mm (MT1 and MT3, respectively) from the soft tissue margin.
- Peri-implant buccal bone distance (BBD): Distance between the implant platform and the peri-implant bone crest evaluated on a line parallel to the long axis of the implant body in the mid-facial scan.

- Peri-implant buccal bone thickness (BBT): evaluated 0.5 mm apical to the bone crest as the distance between the peri-implant crestal bone and a line parallel to the long axis of the implant body in the mid-facial scan.

2.5 Study outcomes

The primary goal of the study was to assess the prevalence of facial PSTDs at single implants in the esthetic region. The secondary outcomes were to compare the clinical and ultrasonographic parameters among implants with and without PSTDs, identifying possible risk indicators for PSTDs.

2.6 Data Collection and statistical analysis

All clinical, ultrasonographic and demographic data were entered into a single prefabricated spreadsheet. Descriptive statistics were used to illustrate the overall clinical and ultrasonographic-related parameters with means and standard deviations (SD) for continuous measures, among implants with and without PSTDs.

To test for statistically significant relationships among the collected variables of interest to the primary outcome PSTD (Yes/No), logistic regression models were fit with generalized estimating equation (GEE), that accounted for repeated measures (more than 1 implant per patient) across observed sample.

A stepwise regression approach was utilized to univariately introduce the variables of interest for testing their predictive values and kept for multi-variate modeling if obtained a p of < 0.05 .

For significant predictors, the final coefficients from the multi-variate model were recorded, and exponentiated to produce odds ratios (OR). Confidence intervals (CI) were produced and a p value of 0.05 was set for statistical significance. The analyses were performed in software R by an author (SB) with experience in biostatistics.

3. Results

3.1 Experimental population and dental implants characteristics

One-hundred and fifty-three subjects (80 males and 73 females, with a mean age of 59.5 ± 15.6 years) with a total of 176 dental implants were included in the present study (Table 1). Among them, 54.2% patients had at least one implant with a PSTD. On an implant-level, 100 dental implants (56.8%) displayed a PSTD and 76 (43.2%) did not. Eighty-four percent (84%) of the implants with a PSTD showed a crown longer than the clinical crown of the homologous tooth, while the exposure of the abutment or implant fixture to the oral cavity was present in 74% of sites with a PSTD. The most frequent type of PSTD was the one characterized by having both an implant-supported crown longer than the clinical crown of the homologous tooth and a visible abutment/implant fixture exposed to the oral cavity (58% of the PSTD cases). Most of the implants with PSTD were diagnosed with class III/IV (58%), while 39% and 3% of cases were classified as PSTD class II and class I, respectively. The most frequent PSTD subclasses were subclass c and subclass b (52% and 40%, respectively) (Table 2).

The mean time in function of the implants with PSTD was 9.3 ± 4.5 years, while for implants without PSTD was 4.9 ± 1.6 years. Implants with PSTD had an adjacent dental implant (without PSTD) in 54% of cases, while implants without PSTD had an adjacent implant (without PSTD) in 5.3% of cases. The mean PD was 2.6 ± 0.6 mm and 2.6 ± 0.8 mm in implants with and without PSTD, respectively, while the mean KMW was 2.2 ± 1.7 mm and 4.5 ± 1.7 mm in implants with and without PSTD, respectively.

3.2 Ultrasonographic outcomes

Table 1 presents descriptive summaries of the measured clinical variables. The measurements of MT at the midfacial ultrasonographic scans tended to be higher at sites without PSTD compared to implants with PSTD (mean MT1 of 1.51 ± 0.58 mm vs 0.65 ± 0.36 mm and mean MT3 of 2.05 ± 0.79 mm vs 1.35 ± 0.56 mm, respectively). The average BBD was also higher at implants with a PSTD (3.25 ± 2.07 mm for implants with a PSTD versus 1.73 ± 1.20 mm for implants without), while a mean BBT of 0.91 ± 0.43 mm, and 1.48 ± 0.66 mm was observed for implants with and without PSTD, respectively (Table 1).

3.3 Risk indicators for the presence of a peri-implant soft tissue deficiency (PSTD)

Table 3 displays the results of the logistic regression models for the outcome of PSTD. The univariate analysis showed that the variables of

- Presence of an adjacent implant (OR 14.4 (95% CI [3.22, 64.8]), $p < 0.001$),
- Implants' time in function (OR 1.73 (95% CI [1.47, 2.03]), $p < 0.001$),
- KMW (OR 0.49 (95% CI [0.38, 0.63]), $p < 0.001$),
- MT1 (OR 0.08 (95% CI [0.04, 0.17]), $p < 0.001$),
- MT3 (OR 0.37 (95% CI [0.22, 0.63]), $p < 0.001$),
- BBD (OR 1.86 (95% CI [1.35, 2.56]), $p < 0.001$), and
- BBT (OR 0.09 (95% CI [0.02, 0.37]), $p = 0.001$)

were significantly related to higher odds of the presence of a PSTD.

The multi-variate analysis confirmed that the presence of an adjacent implant increases the odds of having a PSTD by a factor of approximately 11 (OR 10.9 (95% CI [2.98, 40.2]), $p < 0.001$), as well as the time (in years) of the implants in function (OR 1.4 (95% CI [0.71, 2.73]), $p = 0.001$). Additionally, the model showed an inverse correlation between MT both at 1 mm (OR 0.11 (95% CI [0.04, 0.24]), $p < 0.001$), and 3 mm (OR 0.34 (95% CI [0.14, 0.82]), $p = 0.01$) from the mucosal margin, and the amount of KMW (OR 0.73 (95% CI [0.55, 0.97]), $p < 0.001$), with the presence of PSTD among the population cohort. Relative to the peri-implant buccal bone, BBD also was significantly associated with the presence of a PSTD (OR 1.41 (95% CI [1.02, 1.95]), $p < 0.001$). Furthermore when we utilized cross-validation to predict the accuracy of the model, we observed that it was 86.3% accurate (based on a decision rule in which a patient is predicted to have a PSTD as long as their risk is greater than 50%, Figure 1 of the supplementary file presents a receiver operating characteristic curve with all possible sensitivity and specificity values that can be obtained from decision rules using with any threshold).

4. Discussion

The present cross-sectional study, with the aid of clinical and ultrasonographic measurements, identified the prevalence of dental implants with PSTD at a cross-sectional level, as well as risk indicators for the presence of this condition. Based on the definition of PSTD proposed by Burkhard et al.²⁹, and later on adopted by Zucchelli and coworkers^{7, 30}, using the contralateral homologous

tooth as a reference, it is not unexpected that most of the implants evaluated in our study displayed PSTD (56.8%). On a patient-level, it was found that having at least one implant with PSTD was more common than having implants without this condition (54.2% vs 45.8%). It should be highlighted that our population cohort included patients which had implants placed both in a private practice and in a university setting, which would increase the generalizability of our findings.

Previous studies defined soft tissue dehiscence as the exposure of the prosthetic abutment or the implant neck^{20, 31, 32}, and therefore a comparison between our findings and these studies was not attempted. Given the fact that PSTD is an esthetic complication often associated with esthetic concerns/complaints from patients^{8, 31}, it is reasonable to assume that the definition of PSTD should not solely include cases with exposure of the abutment/implant fixture but should also include conditions characterized by an implant-supported crown longer than the clinical crown of the homologous contralateral tooth. In this view, the present study represents the first report investigating the prevalence of PSTDs, together with their types, classes, and subclasses, according to the recent classification by Zucchelli et al.⁷.

We observed that most of the PSTDs are characterized by a crown longer than the homologous contralateral tooth (84%), with or without concomitant exposure of the abutment/implant fixture (58% and 26% of all the PSTD cases, respectively). This finding has implications on treatment of these defects, since the correction of PSTDs with inadequate crown length requires crown removal in combination with the prosthetic-surgical technique or the submerge approach^{7, 31, 33}. Clinicians are therefore advised that crown removal is necessary in most of the PSTD treatments. We also found that the exposure of the abutment/implant fixture was present in 74% of sites with PSTDs. Aside from patient esthetic concern, the exposure of the implant surface, especially if rough, may facilitate plaque accumulation on the implant fixture which is considered the main risk factor for peri-implantitis^{19, 34, 35}. While the main indication for the treatment of PSTDs without abutment/implant exposed remains patient esthetic concern^{2, 5, 7}, PSTDs with rough implant surface exposed to the oral cavity should be treated for maintaining peri-implant health and preventing future complications^{2, 36, 37}. It is important to further highlight that having a crown with an inadequate length and abutment/implant fixture exposed are common findings, with an overall prevalence (considering all the implants examined in our study) of 47.7% (PSTD with inadequate crown length) and 42% (PSTD with exposure of the abutment and or implant fixture).

The multivariate analysis demonstrated that having an adjacent implant, the time in function of the implants, KMW, MT and BBD are risk indicators for PSTD. Previous studies concluded that limited KMW was associated with PSTD^{20, 32, 38} and our findings further confirm this correlation. However, readers should bear in mind that as this study was conducted in a cross-sectional design, it was not conducted and does not allow for a direct exploration of causality, thus whether a narrow band of KMW is a risk factor for PSTD or a consequence of this condition has yet to be elucidated with prospectively and longitudinal studies. It is reasonable to assume that there are scenarios in which inadequate KMW can contribute to the development of this condition, and other cases in which KMW becomes narrow as a result of the PSTD.

In addition, the use of ultrasonography allowed us to evaluate BBD and BBT which otherwise could only be assessed with cone-beam computed tomography (CBCT), which involves a dose of radiations that may not be recommended for an observational study. Ultrasonography may also be considered the technology of choice for assessing MT, given the limitations of transgingival horizontal probing (needing anesthesia, having patient discomfort and reduced accuracy), optical scanners (needing at least two time points, unless the STL file were combined with the DICOM scan from the CBCT³⁹), and CBCT alone (radiation, and inaccuracy)^{40, 41}. Nevertheless, it has to be mentioned that a method's error of 0.015 mm and 0.08-0.2 mm was observed for MT and BBD, respectively, when obtained with US compared to direct measurements^{23, 27}. Interestingly, US was found to be more accurate than CBCT in identifying crestal bone level and MT^{23, 27}.

We observed that BBD has an OR for PSTD of 1.41. In other words, each millimeter increase in the distance between the crestal bone and the implant platform, raises the odds of having a PSTD by a factor of approximately 41%.

Previous studies investigated the effect of BBD and BBT on the position of the mucosal margin⁴²⁻⁴⁵. Nevertheless, there is no consensus in the recent literature⁴⁶. A recent animal study reported that dental implants with BBT < 1.5 mm were more often associated with PSTD compared to implants with thick buccal bone⁴². However, other authors did not find a correlation between BBT and PSTD, even for implants missing the buccal bone wall^{20, 44}. In our analysis, when other factors were taken into account, BBT was not found to be associated with PSTD. It may be reasonable to assume that

buccal bone resorption in the vertical (BBD) - but not horizontal (BBT) – aspect can negatively affect the stability of the mucosal margin.

We also observed an inverse correlation between MT and PSTD, corroborating the notion that a thicker mucosa can improve the stability of the peri-implant mucosal margin and the esthetic outcomes^{5,47}. This concept has previously been proven in the natural dentition¹² and seems to be valid also at implant sites. In addition, a recent network meta-analysis from our group further highlighted the importance of the dimension of the peri-implant soft tissues, demonstrating that MT augmentation has also beneficial effects on marginal bone level stability³⁶.

Among the limitations of the present study, it has to be mentioned that the cross-sectional design allows for the identification of risk indicators only. Longitudinal studies are needed to further explore these risk indicators and to assess their possible role as risk factors for PSTD. In addition, although the present study incorporated ultrasonography as a non-invasive and reliable technology for assessing the peri-implant soft and hard structures, CBCT could have added additional information to our analysis, such as the bucco-lingual position of the implant. Nevertheless, CBCT is not advised for diagnosis of PSTDs for obvious ethical considerations involving radiation exposure.

Lastly, readers have to bear in mind that the implants in the present study did not receive a soft tissue graft at the implant placement nor at delayed time points. Therefore, future studies are needed to evaluate the prevalence of PSTDs and associated risk indicators at soft tissue grafted vs non-augmented implant sites. Similarly, the correlation of PSTDs with other factors, such as apico-coronal implant positioning and bone augmentation at implant placement, or staged, should be investigated in prospective studies.

5. Conclusions

Peri-implant soft tissue dehiscences are common findings in the esthetic region. Implants having a crown longer than the homologous tooth were the most frequently observed type of PSTD. The analysis demonstrated that presence of an adjacent implant, increased time in function of the implant, higher distance between the implant platform and the crestal bone, lower KMW and MT were significantly associated with the presence of a PSTD.

Conflict of interest: The authors do not have any financial interests, either directly or indirectly, in the products or information enclosed in the paper except Drs. Hsun-Liang Chan and Oliver D. Kripfgans are the inventor of the ultrasonography machine used in this study.

Footnotes

‡‡ PCP UNC 15, Hu-Friedy, Chicago, IL, USA

§§ ZS3, Mindray, Mountain View, CA, USA

|||| Horos™, version 3.3.6, Horos Project

¶¶ Rstudio Version 1.1.383, Rstudio, Inc., Boston, MA, USA

Data availability statement: The data that support the findings of this study are available from the corresponding author upon reasonable request.

REFERENCES

1. Chackartchi T, Romanos GE, Sculean A. Soft tissue-related complications and management around dental implants. *Periodontol 2000* 2019;81:124-138.
2. Wang, H, Barootchi S, Tavelli L, Wang HL. The peri-implant phenotype and implant esthetic complications. Contemporary overview. *J Esthet Restor Dent* 2021;33:212-223.
3. Barootchi S, Wang HL. Peri-implant diseases: Current understanding and management. *Int J Oral Implantol (Berl)* 2021;14:263-282.

4. Barootchi S, Ravid A, Tavelli L, Wang HL. Nonsurgical treatment for peri-implant mucositis: A systematic review and meta-analysis. *Int J Oral Implantol (Berl)* 2020;13:123-139.
5. Zucchelli G, Tavelli L, McGuire MK, et al. Autogenous soft tissue grafting for periodontal and peri-implant plastic surgical reconstruction. *J Periodontol* 2020;91:9-16.
6. Anderson LE, Inglehart MR, El-Kholy K, Eber R, Wang HL. Implant associated soft tissue defects in the anterior maxilla: a randomized control trial comparing subepithelial connective tissue graft and acellular dermal matrix allograft. *Implant Dent* 2014;23:416-425.
7. Zucchelli G, Tavelli L, Stefanini M, et al. Classification of facial peri-implant soft tissue dehiscence/deficiencies at single implant sites in the esthetic zone. *J Periodontol* 2019;90:1116-1124.
8. Rocuzzo M, Gaudio L, Bunino M, Dalmaso P. Surgical treatment of buccal soft tissue recessions around single implants: 1-year results from a prospective pilot study. *Clin Oral Implants Res* 2014;25:641-646.
9. Bengazi F, Wennstrom JL, Lekholm U. Recession of the soft tissue margin at oral implants. A 2-year longitudinal prospective study. *Clin Oral Implants Res* 1996;7:303-310.
10. Small PN, Tarnow DP. Gingival recession around implants: a 1-year longitudinal prospective study. *Int J Oral Maxillofac Implants* 2000;15:527-532.
11. Fu JH, Su CY, Wang HL. Esthetic soft tissue management for teeth and implants. *J Evid Based Dent Pract* 2012;12:129-142.
12. Barootchi S, Tavelli L, Zucchelli G, Giannobile WV, Wang HL. Gingival phenotype modification therapies on natural teeth: A network meta-analysis. *J Periodontol* 2020;91:1386-1399.
13. Barootchi S, Tavelli L, Gianfilippo RD, et al. Acellular dermal matrix for root coverage procedures: 9-year assessment of treated isolated gingival recessions and their adjacent untreated sites. *J Periodontol* 2021;92:254-262.
14. Barootchi S, Chan HL, Namazi SS, Wang HL, Kripfgans OD. Ultrasonographic characterization of lingual structures pertinent to oral, periodontal, and implant surgery. *Clin Oral Implants Res* 2020;31:352-359.
15. Siqueira R, Sinjab K, Pan YC, Soki F, Chan HL, Kripfgans O. Comprehensive peri-implant tissue evaluation with ultrasonography and cone-beam computed tomography: A pilot study. *Clin Oral Implants Res* 2021.
16. Tavelli L, Barootchi S, Majzoub J, et al. Ultrasonographic tissue perfusion analysis at implant and palatal donor sites following soft tissue augmentation: A clinical pilot study. *J Clin Periodontol* 2021;48:602-614.

17. von Elm E, Altman DG, Egger M, et al. The Strengthening the Reporting of Observational Studies in Epidemiology (STROBE) statement: guidelines for reporting observational studies. *J Clin Epidemiol* 2008;61:344-349.
18. Renvert S, Persson GR, Pirih FQ, Camargo PM. Peri-implant health, peri-implant mucositis, and peri-implantitis: Case definitions and diagnostic considerations. *J Clin Periodontol* 2018;45 Suppl 20:S278-S285.
19. Berglundh T, Armitage G, Araujo MG, et al. Peri-implant diseases and conditions: Consensus report of workgroup 4 of the 2017 World Workshop on the Classification of Periodontal and Peri-Implant Diseases and Conditions. *J Periodontol* 2018;89 Suppl 1:S313-S318.
20. Sanz-Martin I, Regidor E, Navarro J, Sanz-Sanchez I, Sanz M, Ortiz-Vigon A. Factors associated with the presence of peri-implant buccal soft tissue dehiscences: A case-control study. *J Periodontol* 2020.
21. Chan HL, Kripfgans OD. Ultrasonography for diagnosis of peri-implant diseases and conditions: a detailed scanning protocol and case demonstration. *Dentomaxillofac Radiol* 2020:20190445.
22. Barootchi S, Chan HL, Namazi SS, Wang HL, Kripfgans OD. Ultrasonographic characterization of lingual structures pertinent to oral, periodontal, and implant surgery. *Clin Oral Implants Res* 2020.
23. Chan HL, Wang HL, Fowlkes JB, Giannobile WV, Kripfgans OD. Non-ionizing real-time ultrasonography in implant and oral surgery: A feasibility study. *Clin Oral Implants Res* 2017;28:341-347.
24. Tavelli L, Barootchi S, Majzoub J, et al. Ultrasonographic Tissue Perfusion Analysis at Implant and Palatal Donor Sites Following Soft Tissue Augmentation: A Clinical Pilot Study. *J Clin Periodontol* 2021.
25. Barootchi S, Tavelli L, Majzoub J, Chan HL, Wang HL, Kripfgans OD. Ultrasonographic Tissue Perfusion in Peri-implant Health and Disease. *J Dent Res* 2021:220345211035684.
26. Sassaroli E, Crake C, Scorza A, Kim DS, Park MA. Image quality evaluation of ultrasound imaging systems: advanced B-modes. *J Appl Clin Med Phys* 2019;20:115-124.
27. Tattan M, Sinjab K, Lee E, et al. Ultrasonography for chairside evaluation of periodontal structures: A pilot study. *J Periodontol* 2019.
28. Chan HL, Sinjab K, Li J, Chen Z, Wang HL, Kripfgans OD. Ultrasonography for noninvasive and real-time evaluation of peri-implant tissue dimensions. *J Clin Periodontol* 2018;45:986-995.
29. Burkhardt R, Joss A, Lang NP. Soft tissue dehiscence coverage around endosseous implants: a prospective cohort study. *Clin Oral Implants Res* 2008;19:451-457.

30. Zucchelli G, Mazzotti C, Mounssif I, Mele M, Stefanini M, Montebugnoli L. A novel surgical-prosthetic approach for soft tissue dehiscence coverage around single implant. *Clin Oral Implants Res* 2013;24:957-962.
31. Mazzotti C, Stefanini M, Felice P, Bentivogli V, Mounssif I, Zucchelli G. Soft-tissue dehiscence coverage at peri-implant sites. *Periodontol 2000* 2018;77:256-272.
32. Romandini M, Pedrinaci I, Lima C, Soldini MC, Araoz A, Sanz M. Prevalence and risk/protective indicators of buccal soft tissue dehiscence around dental implants. *J Clin Periodontol* 2021;48:455-463.
33. Stefanini M, Marzadori M, Tavelli L, Bellone P, Zucchelli G. Peri-implant Papillae Reconstruction at an Esthetically Failing Implant. *Int J Periodontics Restorative Dent* 2020;40:213-222.
34. Renvert S, Persson GR, Pirih FQ, Camargo PM. Peri-implant health, peri-implant mucositis, and peri-implantitis: Case definitions and diagnostic considerations. *J Periodontol* 2018;89 Suppl 1:S304-S312.
35. Bianchini MA, Galarraga-Vinueza ME, Apaza-Bedoya K, De Souza JM, Magini R, Schwarz F. Two to six-year disease resolution and marginal bone stability rates of a modified resective-implantoplasty therapy in 32 peri-implantitis cases. *Clin Implant Dent Relat Res* 2019;21:758-765.
36. Tavelli L, Barootchi S, Avila-Ortiz G, Urban IA, Giannobile WV, Wang HL. Peri-implant soft tissue phenotype modification and its impact on peri-implant health: A systematic review and network meta-analysis. *J Periodontol* 2021;92:21-44.
37. Parvini P, Galarraga-Vinueza ME, Obreja K, Magini RS, Sader R, Schwarz F. Prospective study assessing three-dimensional changes of mucosal healing following soft tissue augmentation using free gingival grafts. *J Periodontol* 2021;92:400-408.
38. Lin GH, Chan HL, Wang HL. The significance of keratinized mucosa on implant health: a systematic review. *J Periodontol* 2013;84:1755-1767.
39. Couso-Queiruga E, Tattan M, Ahmad U, Barwacz C, Gonzalez-Martin O, Avila-Ortiz G. Assessment of gingival thickness using digital file superimposition versus direct clinical measurements. *Clin Oral Investig* 2021;25:2353-2361.
40. Tavelli L, Barootchi S, Majzoub J, Siqueira R, Mendonca G, Wang HL. Volumetric changes at implant sites: A systematic appraisal of traditional methods and optical scanning-based digital technologies. *J Clin Periodontol* 2021;48:315-334.
41. Mandelaris GA, Scheyer ET, Evans M, et al. American Academy of Periodontology Best Evidence Consensus Statement on Selected Oral Applications for Cone-Beam Computed Tomography. *J Periodontol* 2017;88:939-945.

42. Monje A, Chappuis V, Monje F, et al. The Critical Peri-implant Buccal Bone Wall Thickness Revisited: An Experimental Study in the Beagle Dog. *Int J Oral Maxillofac Implants* 2019;34:1328-1336.
43. Spray JR, Black CG, Morris HF, Ochi S. The influence of bone thickness on facial marginal bone response: stage 1 placement through stage 2 uncovering. *Ann Periodontol* 2000;5:119-128.
44. Raes S, Eghbali A, Chappuis V, Raes F, De Bruyn H, Cosyn J. A long-term prospective cohort study on immediately restored single tooth implants inserted in extraction sockets and healed ridges: CBCT analyses, soft tissue alterations, aesthetic ratings, and patient-reported outcomes. *Clin Implant Dent Relat Res* 2018;20:522-530.
45. Hammerle CHF, Tarnow D. The etiology of hard- and soft-tissue deficiencies at dental implants: A narrative review. *J Periodontol* 2018;89 Suppl 1:S291-S303.
46. Avila-Ortiz G, Gonzalez-Martin O, Couso-Queiruga E, Wang HL. The peri-implant phenotype. *J Periodontol* 2020;91:283-288.
47. Malloa J, Arnett M, Chan HL, George FM, Kaigler D, Wang HL. The Association Between Buccal Mucosa Thickness and Periimplant Bone Loss and Attachment Loss: A Cross-Sectional Study. *Implant Dent* 2018;27:575-581.

Tables and Figures Legend

Table 1. Characteristics of the population and dental implants

Table 2. Characteristics of the peri-implant soft tissue dehiscences (PSTDs)

Table 3. Uni- and multi-variate results of the logistic regression models assessing the correlation of PSTDs to the observed variables

Figure 1. Clinical and ultrasonographic presentation of an implant without PSTD (A, A' and A''), PSTD with longer crown (B, B' and B''), PSTD with an adequate crown length and abutment exposed (C, C' and C''), PSTD with a crown longer than the clinical crown of the homologous tooth and with abutment exposed (D, D' and D''). The midfacial ultrasonographic scans show the soft tissue (ST) highlighted in green, the implant-supported crown (Cr), the abutment (Ab), the implant threads

above the bone (IT) and the peri-implant crestal bone (CB) and the ultrasonographic outcomes of interest (BBT, BBD, MT1 and MT3).

Figure 2. Subject with two dental implants in the lateral incisor position (A-F). The left implant shows a soft tissue dehiscence with the abutment exposed, while the implant on the right does not display a soft tissue dehiscence. A) Midfacial ultrasonographic scan of the implant with peri-implant soft tissue dehiscence, where the soft tissue component (ST) is highlighted in green. The implant-supported crown (Cr), the abutment (Ab), the implant threads above the bone crest (IT) and the peri-implant crestal bone (CB) are displayed. Note that the implant has the abutment exposed to the oral cavity and several threads above the CB. Thin mucosa (MT1= 0.39 mm and MT3= 0.89 mm) and buccal bone distance (distance from the implant platform to the CB, BBD= 2.35 mm, highlighted in red) may have contribute to the clinical manifestation of the PSTD. The implant on the left side displays a thicker mucosa (MT1 = 1.39 mm and MT3 = 1.84 mm) without bone loss (BBD = 0) (C). D) Occlusal view of the two implants where it is possible to appreciate that the right was placed more buccally than the implant on the right (PSTD class III). E-F) Transverse ultrasonographic scan showing the soft and hard structures of the right and left implant, respectively. The adjacent teeth (T) are also highlighted.

Supplementary Figure. Receiver operating characteristic curve showing all possible sensitivity and specificity values for the presence of a peri-implant soft tissue dehiscence with varying thresholds.

Table 1. Characteristics of the population and dental implants (PD: Probing implant depths. KMW: keratinized mucosa width. MT1: mucosal thickness evaluated 1 mm below the soft tissue margin. MT3: mucosal thickness evaluated 3 mm below the soft tissue margin. BBD: Buccal bone distance. BBT: buccal bone thickness.)

Characteristic	Peri-implant soft tissue dehiscence (PSTD)
----------------	--

	No	Yes
Subjects (N)	70	83
Males (N, %)	42, 60	38, 45.8
Age (mean \pm SD) (years)	63.7 \pm 13.6	59.2 \pm 15.6
Implants (N, %)	76, 43.2	100, 56.8
Bone level implants (N, %)	76, 100	100, 100
Implants therapy done at a university setting	41, 53.9	58, 58
Implants therapy done at a private practice	35, 46.1	42, 42
Years in function (mean \pm SD) (years)	4.9 \pm 1.6	9.3 \pm 4.5
Maxilla (N, %)	70, 92.1	64, 64
Mandible (N, %)	6, 7.9	36, 36
Central incisors (N, %)	20, 26.3	22, 22
Lateral incisors (N, %)	18, 23.7	15, 15
Canine (N, %)	4, 5.3	9, 9
Premolar (N, %)	34, 44.7	54, 54
Presence of adjacent implant (N, %)	4, 5.3	54, 54
PD (mean \pm SD) (mm)	2.6 \pm 0.8	2.6 \pm 0.6
KMW (mean \pm SD) (mm)	4.5 \pm 1.7	2.2 \pm 1.7
MT1 (mean \pm SD) (mm)	1.51 \pm 0.58	0.65 \pm 0.36

MT3 (mean ± SD) (mm)	2.05 ± 0.79	1.35 ± 0.56
BBD (mean ± SD) (mm)	1.73 ± 1.20	3.25 ± 2.07
BBT (mean ± SD) (mm)	1.48 ± 0.66	0.91 ± 0.43

Table 2. Characteristics of the peri-implant soft tissue dehiscences (PSTDs)

PSTD Characteristic	Cases (%)
Crown longer than the homologous tooth (overall)	84
Crown longer than the homologous tooth with abutment/implant exposed	58
Crown longer than the homologous tooth without abutment/implant fixture exposed	26
Abutment/implant fixture exposed (overall)	74
Abutment/implant fixture exposed and crown with an adequate length	16
Abutment/implant fixture exposed and crown longer than the homologous tooth	58
PSTD class I	3
PSTD class II	39
PSTD class III/IV	58
PSTD subclass a	8

PSTD subclass b	40
PSTD subclass c	52

Table 3. Uni- and multi-variate results of the logistic regression models assessing the correlation of PSTDs to the observed variables.

Variable	Univariate analysis			Multivariate analysis		
	OR	95% CI	<i>p</i> -value	OR	95% CI	<i>p</i> -value
Gender (Male)	0.55	0.28, 1.1	0.09			
Age	0.98	0.94, 1.03	0.11			
Smoking	2.22	0.76, 6.51	0.14			
Presence of Adjacent implant	14.4	3.22, 64.8	<0.001	10.9	2.98, 40.2	<0.001
Years in function (time since installment of final prosthesis)	1.73	1.47, 2.03	<0.001	1.4	0.71, 2.73	0.001
KMW (mm)	0.49	0.38, 0.63	<0.001	0.73	0.55, 0.97	0.03
MT1 (mm)	0.08	0.04, 0.17	<0.001	0.11	0.04, 0.24	<0.001
MT3 (mm)	0.37	0.22, 0.63	<0.001	0.34	0.14, 0.82	0.01
BBD (mm)	1.86	1.35, 2.56	<0.001	1.41	1.02, 1.95	0.02
BBT (mm)	0.09	0.02, 0.37	0.001			

Legend. BBD: Buccal bone distance. BBT: buccal bone thickness. KMW: keratinized mucosa width. MT1: mucosal thickness evaluated 1 mm below the mucosal margin. MT3: mucosal thickness evaluated 3 mm below the mucosal margin.
OR: odds ratio.

CI: confidence intervals.

Figure 1. Clinical and ultrasonographic presentation of an implant without PSTD (A, A' and A''), PSTD with longer crown (B, B' and B''), PSTD with an adequate crown length and abutment exposed (C, C' and C''), PSTD with a crown longer than the clinical crown of the homologous tooth and with abutment exposed (D, D' and D''). The midfacial ultrasonographic scans show the soft tissue (ST) highlighted in green, the implant-supported crown (Cr), the abutment (Ab), the implant threads above the bone (IT) and the peri-implant crestal bone (CB) and the ultrasonographic outcomes of interest (BBT, BBD, MT1 and MT3).

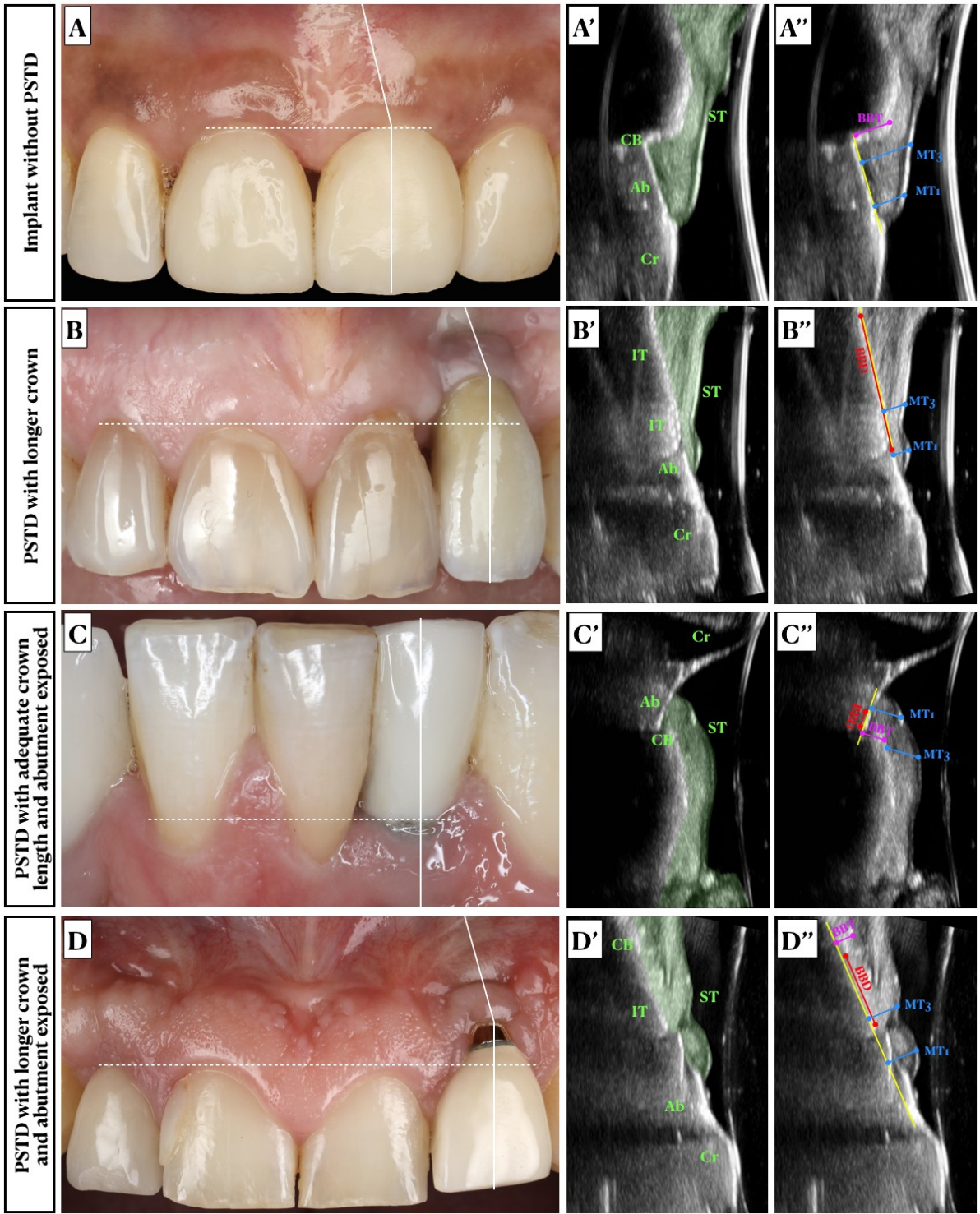
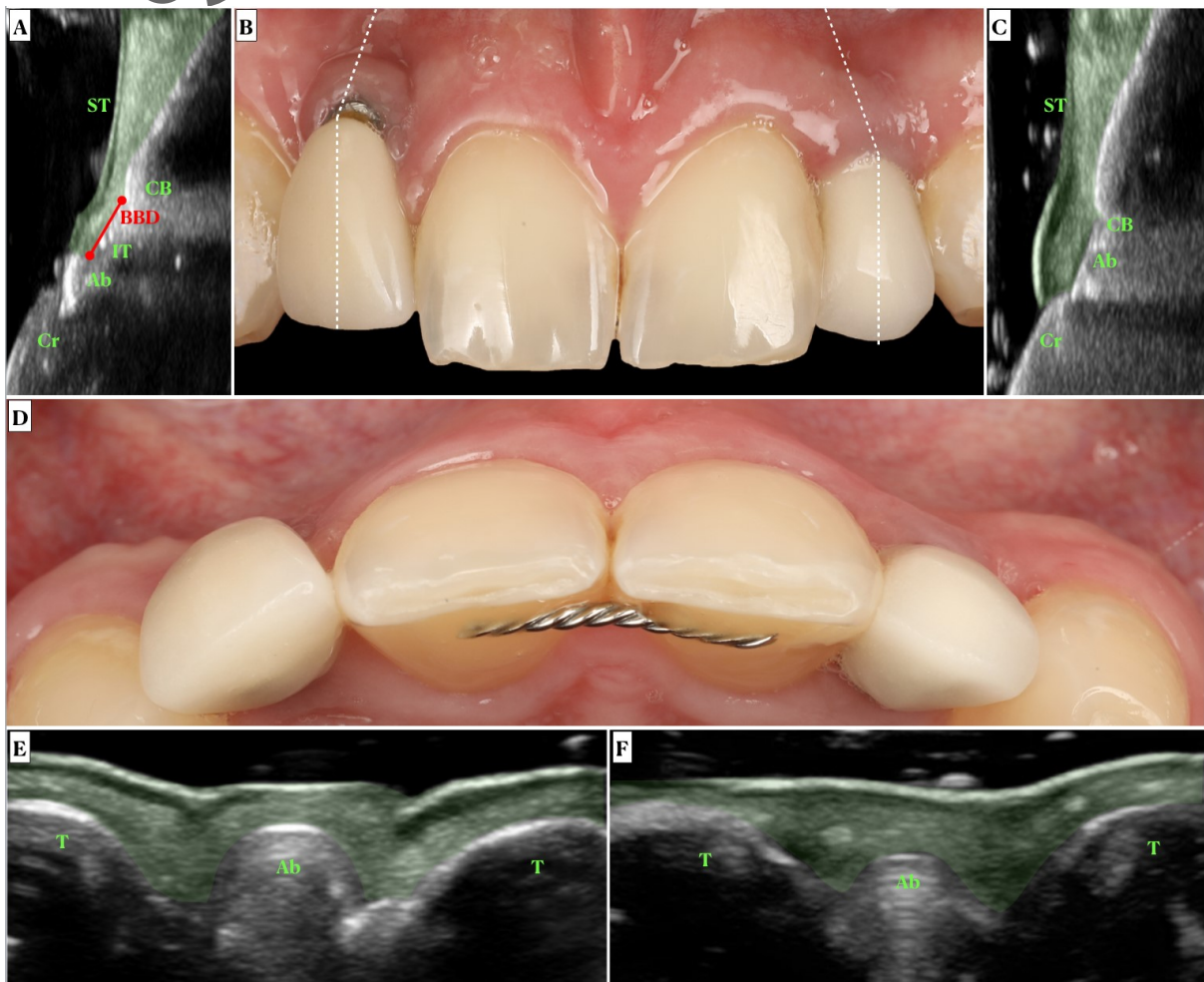


Figure 2. Subject with two dental implants in the lateral incisor position (A-F). The left implant shows a soft tissue dehiscence with the abutment exposed, while the implant on the right does not display a soft tissue dehiscence. A) Midfacial ultrasonographic scan of the implant with peri-implant soft tissue dehiscence, where the soft tissue component (ST) is highlighted in green. The implant-

supported crown (Cr), the abutment (Ab), the implant threads above the bone crest (IT) and the peri-implant crestal bone (CB) are displayed. Note that the implant has the abutment exposed to the oral cavity and several threads above the CB. Thin mucosa (MT1= 0.39 mm and MT3= 0.89 mm) and buccal bone distance (distance from the implant platform to the CB, BBD= 2.35 mm, highlighted in red) may have contributed to the clinical manifestation of the PSTD. The implant on the left side displays a thicker mucosa (MT1 = 1.39 mm and MT3 = 1.84 mm) without bone loss (BBD = 0) (C). D) Occlusal view of the two implants where it is possible to appreciate that the right was placed more buccally than the implant on the right (PSTD class III). E-F) Transverse ultrasonographic scan showing the soft and hard structures of the right and left implant, respectively. The adjacent teeth (T) are also highlighted.



A