

Case Report

---

# Chronic Central Serous Chorioretinopathy with Pigment Epithelium Detachment Treated with Sildenafil: A Case Report

Alessandro Finzi<sup>a</sup> Nicola Valsecchi<sup>a</sup> Filippo Tassi<sup>b</sup> Mauro Cellini<sup>a</sup>  
Luigi Fontana<sup>a</sup>

<sup>a</sup>Ophthalmology Unit, Department of Experimental, Diagnostic and Specialty Medicine, IRCSS Azienda Ospedaliero-Universitaria di Bologna, Bologna, Italy; <sup>b</sup>Ophthalmology Unit, Policlinico di Monza, University of Milano Bicocca, Monza, Italy

## Keywords

Central serous chorioretinopathy · Pigment epithelium detachment · Sildenafil · Angio-optical coherence tomography · Choroidal ischemia · Endothelial dysfunction

## Abstract

Central serous chorioretinopathy (CSCR) is a retinal disease that may be complicated by the development of serous retinal pigment epithelial detachment (PED). The exact molecular mechanisms of CSCR have remained uncertain as well as there is no effective medical therapy. Herein, we describe a case of a 43-year-old male suffering from chronic CSCR with PED and visual acuity reduction (20/40) that showed improvement in visual acuity (20/25) and metamorphopsia 2 weeks after daily intake of 20 mg sildenafil tablets. Optical coherence tomography (OCT) scan showed resolution of PED with residual degeneration of the photoreceptor inner and outer segment layer and retinal pigmented epithelium. The patient continued treatment with sildenafil 20 mg for 2 months. Six months after the discontinuation of therapy, visual acuity was maintained, with absence of PED at OCT. Our case supports the hypothesis that phosphodiesterase type 5 (PDE-5) inhibitors may be an alternative in the treatment of patients with CSCR, alone or combined with other medications.

© 2022 The Author(s).  
Published by S. Karger AG, Basel

## Introduction

Central serous chorioretinopathy (CSCR) is an idiopathic retinal disease characterized by a localized serous detachment of the sensory retina, secondary to an alteration of the choriocapillaris. In some cases, CSCR may be complicated by the development of serous retinal pigment epithelial detachment (PED).

Several systemic drugs have been proposed for treating CSCR. Inhibitors of carbonic anhydrase IV have been evaluated, and a clinical trial observed that patients treated with oral acetazolamide have a faster resolution of subretinal fluid and a faster improvement of visual acuity [1]. Furthermore, systemic drugs that interfere with the glucocorticoid pathway have been tested, including ketoconazole, mifepristone (RU486), finasteride, rifampin, antiadrenergic, spironolactone, eplerenone, and melatonin [2].

Sildenafil is primarily used in erectile dysfunction that inhibits phosphodiesterase type 5 (PDE-5) and type 6 in all vascular tissues, thus determining vasodilation and increasing vascular blood flow [3]. In the present report, we describe a case of a patient with chronic CSCR and PED treated with sildenafil, who presented a resolution of the serous detachment of the neuroepithelium and pigment epithelium with residual degeneration of the photoreceptor inner-outer segment layer and retinal pigmented epithelium (RPE) and remarkable visual improvement.

## Case Report

A 43-year-old Caucasian male with a known history of chronic CSCR in the left eye presented for an eye examination in our Ophthalmology Unit, complaining of the persistence of blurry vision and metamorphopsia in the left eye. The patient had been previously treated with oral 500 mg of acetazolamide daily for 4 weeks and later with eplerenone 25 mg/day for 3 months with no significant improvement.

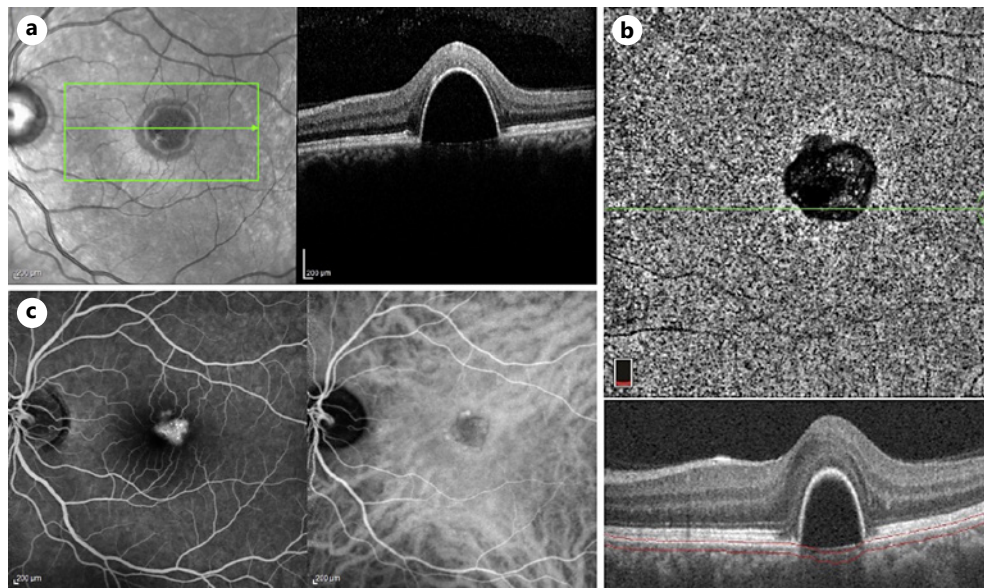
Best corrected visual acuity (BCVA) was 20/20 (Snellen) in the right eye and 20/40 in the left eye; intraocular pressure was 18 mmHg and anterior segment unremarkable in both eyes. Posterior segment examination of the left eye showed a localized round area of subretinal fluid in the macula region.

The patient underwent fluorescein angiography (FA) and indocyanine angiography (ICGA), optical coherence tomography (OCT) with Spectralis HRA-OCT (Heidelberg Engineering, Heidelberg, Germany), and optical coherence tomography angiography (OCTA) with AngioVue (Optovue Inc., Fremont, CA, USA). OCT scan revealed the presence of a PED in the parafoveal region and a corresponding increased transmission of fluorescence related to the RPE alteration. In contrast, the ICGA scan showed hyperfluorescence and blockage of the normal choroidal vasculature in correspondence to the PED. OCT scans and angiography images are shown in Figure 1.

We prescribed oral sildenafil 20 mg/day (the minimum dosage indicated to be effective in treating patients with pulmonary hypertension [4, 5]) for 2 months. After 2 weeks of therapy, the patient reported an improvement in visual acuity and a reduction of metamorphopsia in the left eye.

At eye examination, BCVA improved from 20/40 at baseline to 20/25 with a complete resolution of the PED, residual degeneration of the photoreceptor inner and outer segment layer, and RPE at OCT. A moderate increase of choriocapillaris thickness was also observed (Fig. 2). The patient continued a daily intake of sildenafil for 2 months with no adverse reactions during therapy.

Six months after the discontinuation of the therapy, the patient was re-evaluated. He did not refer metamorphopsia. At examination, the BVCA in the left eye was 20/25, and OCT scan revealed a complete resolution of the serous detachment of the neuroepithelium with residual degeneration of the photoreceptor inner and outer segment layer and RPE (Fig. 3).



**Fig. 1.** **a** Optical coherence tomography (OCT) of the macula showed the presence of pigment epithelium detachment (PED) in the left eye. **b** OCT angiography of choriocapillaris showed no significant signals in blood vessels. **c** Fluorescein angiography revealed a corresponding increased transmission of fluorescence related to the RPE alteration. In contrast, indocyanine green angiography showed hyperfluorescence and blockage of the normal choroidal vasculature in correspondence to PED.

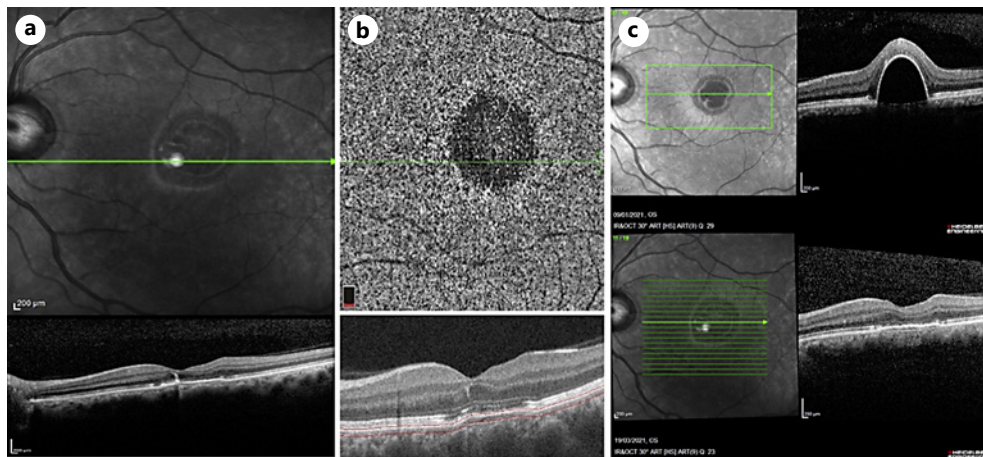
## Discussion

CSCR is an idiopathic disease that affects different anatomical structures in the posterior segment of the eye. The pathogenesis remains enigmatic, despite new advances in imaging techniques.

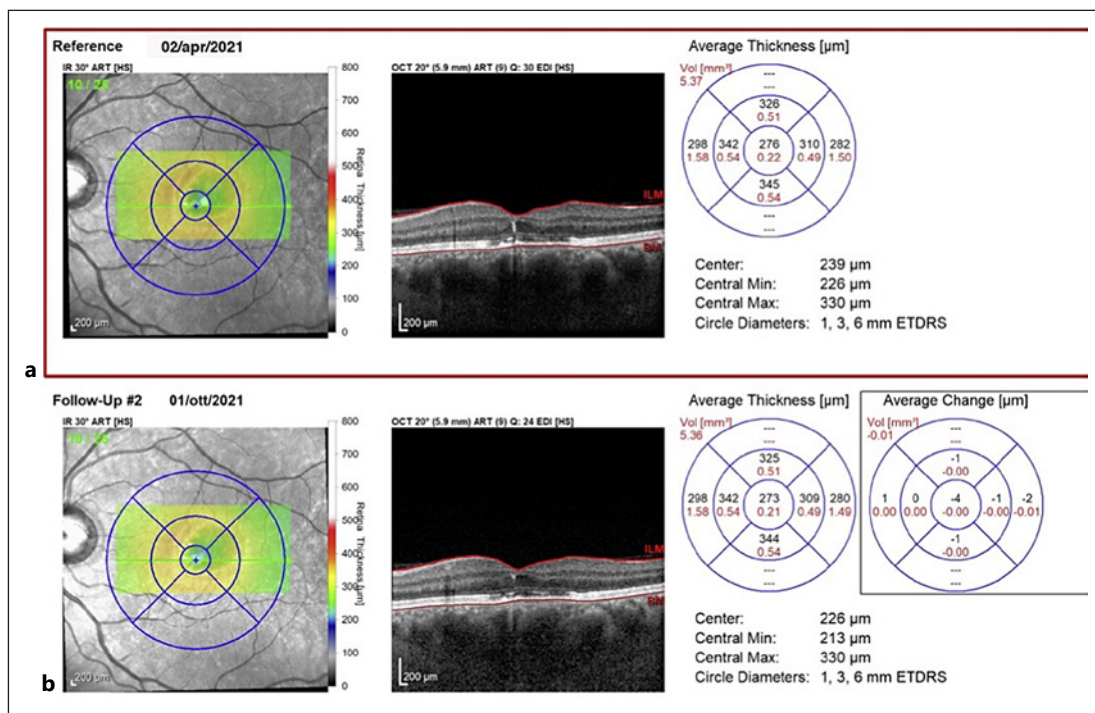
Recent studies underline the primary role of choriocapillaris and RPE in the development of the disease [6]. It is supposed that ischemia in the choriocapillaris induces an increase in the permeability of vessels, particularly in the Sattler's layer, determining an increase in hydrostatic pressure in the interstitial space. This mechanism would induce a functional alteration of the RPE and an accumulation of fluid in the subretinal space. Moreover, it has been suggested that dysfunction in RPE cells leads to a loss of polarity and an active fluid pumping from the choroid to the retina layer, determining an accumulation of subretinal fluid [7].

The primary cause of ischemia has not been well-understood, and different theories have been proposed. Some studies showed a reduction in the venous outflow and an increase in plasminogen activator inhibitor 1 (PAI-1) enzyme, suggesting that thrombotic mechanisms could drive the development of ischemia in the choriocapillaris [8]. Moreover, patients with CSCR have increased cortisol and aldosterone levels in the blood. Aldosterone acts by stimulating angiotensin receptor 1 (AGTR1) that leads to an endothelial dysfunction and oxidative stress in the choroidal vessels, whereas cortisol determines oxidative stress in RPE cells; these mechanisms lead to inflammation, reduction in the production of nitric oxide (NO) and increase in the production of endothelin-1 (ET-1) that determines vasospasm and ischemia in the choriocapillaris. Also, an increase in proinflammatory cytokines could determine endothelial dysfunction and alteration of RPE cells, primarily in chronic CSCR [9].

PDE-5 inhibitors are a class of drugs used in erectile dysfunction, lower urinary symptoms, and pulmonary hypertension [10]. Previous studies have hypothesized that sildenafil intake could increase the risk of developing CSCR [11–15] [14] (Table 1); however, a study by French



**Fig. 2.** a OCT and b OCTA showed resolution of the PED with absence of choriocapillaris alterations after 2 weeks of treatment with sildenafil. c Choriocapillaris thickness before (176 microns) and after the treatment with sildenafil (190 microns).



**Fig. 3.** a OCT scans reveal absence of PED which persists 6 months after the discontinuation of the therapy (b).

et al. demonstrated no significant correlation between PDE-5 inhibitors usage and CSCR in a post-marketing surveillance [16].

Recently, a study by Breazzano et al. in 4 patients with chronic CSCR showed that treatment with sildenafil 40–80 mg twice a daily resolved the subretinal fluid and improved the visual acuity in 2 patients. Moreover, Coleman et al. observed that discontinuation of PDE-5 inhibitor determined a recurrence of serous detachment in a patient successfully treated with sildenafil 60 mg daily [17, 18]. See Table 2.

**Table 1.** Literature review of clinical cases and case series that suggest an increased risk of CSCR in patients treated with PDE-5 inhibitors

Patients, n	Age, years	Sex	Visual acuity after PDE-5 inhibitors intake	OCT after PDE-5 inhibitors intake	Previous treatment	Drug and dosage	Time of treatment	Outcome
Mohammadpour et al., [11]	35	M	20/20 OD 20/80 OS	Subretinal fluid and PED	n	Sildenafil 400 mg	3 days	20/25 OS and improvement of macular edema after 4 weeks of cessation
Roy et al., [12]	45	M	6/60 OD 6/6 OS	OD serous detachment	n	Tadalafil	5 days prior to visual problems	6/6 OD and subretinal fluid reduction after 1 month of cessation
Gordon-Bennett et al., [13]	51	M	6/5 OD 3/24 OS	OS serous macular detachment	n	Tadalafil repeated doses >20 mg	n	6/12 OS 5 days after cessation, subretinal fluid reduced
Fraunfelder et al., [14]	51 (mean)	All men	n	n	n	Sildenafil 50–100 mg (1–6 times per week)	1 day to 2 years	6 patients improved vision after sildenafil cessation, 3 patients had a recurrence when resumed therapy, 2 patients continued to present CSCR after cessation
Quiram et al., [15]	68 70	M M	20/40 OU at first examination 20/200 OU	Subretinal fluid and vitelliform lesions Subretinal fluid, vitelliform lesions, drusenoid deposits	n n	Sildenafil 50–100 mg Sildenafil 50–100 mg	2 times a week for 2 years 3–4 times a week for at least 1 year	Resolution of serous detachment after cessation. No recurrences after 16 months of follow-up 20/70 OD, 20/80 OS with resolution of fluid in OD and reduction in OS after 2 months of discontinuation. Patients restarted sildenafil and vision decreased to 20/200 in OS with increase in subretinal fluid

**Table 2.** Literature review of clinical cases and case series that showed the effects of treatment with PDE-5 inhibitors in patients with CSCR

Patients, n	Age, years	Sex	Visual acuity	OCT	Previous treatment	Drug and dosage	Time of treatment	Outcome
Colemann et al., [17]	50	M	20/20 OU, metamorphopsia OD	OD subretinal fluid and PED	n	Sildenafil 60 mg	Once daily for 5 months (dechallenge after PED resolution)	20/20 OU and resolution of subretinal fluid within 2 weeks Recurrence after 3 weeks of cessation of sildenafil Resolution of subretinal fluid within 2 weeks after rechallenge Symptom-free while on sildenafil for 5 months
Breazzano et al., [18]	42 37 49 42	M M M M	20/50 OS 20/30 OD 20/50 OD 20/200 OD	OS su-retinal fluid and PED in chronic CSCR OD subretinal fluid and small PED in chronic CSCR OD subretinal fluid and small PED in chronic CSCR OD subretinal fluid and small PED in chronic CSCR	n n Eplerenone Eplerenone and PDT	Sildenafil 40–80 mg Sildenafil 40–80 mg Sildenafil 40–80 mg Sildenafil 40–80 mg	Twice daily for 5 months Twice daily for 5 months Twice daily for 5 months Twice daily for 5 months	20/20, resolution of subretinal fluid, PED remained 20/20, resolution of subretinal fluid within 1 month, PED remained 20/20 after cessation of Sildenafil and 4 intravitreal aflibercept injections Persistence of both subretinal fluid and PED after 1 month of treatment

In our case, the patient had an improvement in visual acuity and a complete resolution of serous detachment after 2 weeks of treatment with a daily intake of 20 mg of sildenafil; moreover, the patient continued the treatment for 2 months, and at 6 months follow-up after the discontinuation of sildenafil, visual acuity and PED resolution were maintained.

Several studies showed that PDE-5 and PDE-6 inhibitors might increase choroidal perfusion and improve endothelial function, reducing the ischemic environment that drives the pathogenesis of serous detachment [19, 20]. However, it is necessary to avoid overdoses of the drug that could cause excessive choroid perfusion with worsening CSCR. The case herein reported suggests that PDE-5 inhibitors could be a valuable tool in treating patients with chronic CSCR when the minimum dosage considered to be effective in treating pulmonary hypertension is used.

Further studies should investigate the efficacy and safety of these drugs in treating patients with CSCR to clarify their effects on the choriocapillaris microvasculature and identify the minimum effective dosage.

## Statement of Ethics

All procedures were performed in accordance with the ethical standards of the Institutional Review board and with the World Medical Association Declaration of Helsinki and its later amendments or comparable ethical standards. Written informed consent was obtained from the patient for publication of this case report and any accompanying images. The Institutional Review Board of the University of Bologna gave permission for conducting this study and for using patient data (date of approval February 22, 2021). A copy of the written consent is available for review by the Editor-in-Chief of this journal.

## Conflict of Interest Statement

The authors declare that they have no competing interests.

## Funding Sources

This research received no specific grant from any funding agency in the public, commercial, or not-for-profit sectors.

## Author Contributions

Dr. Alessandro Finzi – conceptualizing, analyzing images, writing the manuscript, and approved final manuscript; Dr. Nicola Valsecchi – writing the manuscript and approved final manuscript; Dr. Filippo Tassi and DR. Mauro Cellini – conceptualizing, treating patients, obtaining images and revising the manuscript, and approved final manuscript; Prof. Luigi Fontana – writing, reviewing the manuscript, and approved final manuscript.

## Data Availability Statement

All data generated or analyzed during this study are included in this article. Further inquiries can be directed to the corresponding author.

## References

- 1 Pikkell J, Beiran I, Ophir A, Miller B. Acetazolamide for central serous retinopathy. *Ophthalmology*. 2002 Sep; 109(9):1723–5.
- 2 Daruich A, Matet A, Dirani A, Bousquet E, Zhao M, Farman N, et al. Central serous chorioretinopathy: recent findings and new physiopathology hypothesis. *Prog Retin Eye Res*. 2015 Sep;48:82–118.
- 3 Schwarz ER, Kapur V, Rodriguez J, Rastogi S, Rosanio S. The effects of chronic phosphodiesterase-5 inhibitor use on different organ systems. *Int J Impot Res*. 2007 Apr;19(2):139–48.
- 4 Galiè N, Ghofrani HA, Torbicki A, Barst RJ, Rubin LJ, Badesch D, et al. Sildenafil citrate therapy for pulmonary arterial hypertension. *N Engl J Med*. 2005 Nov 17;353(20):2148–57.
- 5 Vitulo P, Stanziola A, Confalonieri M, Libertucci D, Oggioni T, Rottoli P, et al. Sildenafil in severe pulmonary hypertension associated with chronic obstructive pulmonary disease: a randomized controlled multicenter clinical trial. *J Heart Lung Transplant*. 2017 Feb;36(2):166–74.
- 6 Nicholson B, Noble J, Forooghian F, Meyerle C. Central serous chorioretinopathy: update on pathophysiology and treatment. *Surv Ophthalmol*. 2013 Mar;58(2):103–26.
- 7 Spitznas M. Pathogenesis of central serous retinopathy: a new working hypothesis. *Graefes Arch Clin Exp Ophthalmol*. 1986;224(4):321–4.
- 8 Iijima H, Iida T, Murayama K, Imai M, Gohdo T. Plasminogen activator inhibitor 1 in central serous chorioretinopathy. *Am J Ophthalmol*. 1999 Apr;127(4):477–8.
- 9 Terao N, Koizumi H, Kojima K, Yamagishi T, Nagata K, Kitazawa K, et al. Association of upregulated angiogenic cytokines with choroidal abnormalities in chronic central serous chorioretinopathy. *Invest Ophthalmol Vis Sci*. 2018 Dec 14;59(15):5924.
- 10 Andersson KE. PDE5 inhibitors: pharmacology and clinical applications 20 years after sildenafil discovery. *Br J Pharmacol*. 2018 Jul;175(13):2554–65.
- 11 Mehrdad M, Mehdi K, Masoud KN. Central serous chorioretinopathy following ingestion of sildenafil citrate. *Clin Optom*. 2019;11:73–5. <https://doi.org/10.2147/OPTO.S210877.31372081>.
- 12 Roy R, Panigrahi PK, Saurabh K, Das D, Lobo A. Central serous chorioretinopathy following oral tadalafil intake. *Clin Exp Optom*. 2014;97(5):473–4.
- 13 Gordon-Bennett P, Rimmer T. Central serous chorioretinopathy following oral tadalafil. *Eye*. 2012;26(1):168–9.
- 14 Fraunfelder FW, Fraunfelder FT. Central serous chorioretinopathy associated with sildenafil. *Retina*. 2008; 28(4):606–9.
- 15 Quiram P, Dumars S, Parwar B, Sarraf D. Viagra-associated serous macular detachment. *Graefes Arch Clin Exp Ophthalmol*. 2005;243(4):339–44.
- 16 French DD, Margo CE. Central serous chorioretinopathy and phosphodiesterase-5 inhibitors: a case-control postmarketing surveillance study. *Retina*. 2010 Feb;30(2):271–4.
- 17 Coleman DJ, Lee W, Daly S, Breazzano MP, Sparrow J, Tsang SH, et al. Central serous chorioretinopathy treatment with a systemic PDE5 and PDE6 inhibitor (sildenafil). *Am J Ophthalmol Case Rep*. 2021 Mar 1;21:100998.
- 18 Breazzano MP, Coleman DJ, Chen RWS, Chang S, Daly S, Tsang SH, et al. Prospective impact of sildenafil on chronic central serous chorioretinopathy: PISCES trial. *Ophthalmol Retina*. 2020 Nov;4(11):1119–23.
- 19 Coleman DJ, Lee W, Chang S, Silverman RH, Lloyd HO, Daly S, et al. Treatment of macular degeneration with sildenafil: results of a two-year trial. *Ophthalmologica*. 2018;240(1):45–54.
- 20 Yiu G, Vuong VS, Tran S, Migacz J, Cunefare D, Farsiu S, et al. Vascular response to sildenafil citrate in aging and age-related macular degeneration. *Sci Rep*. 2019 Mar 25;9(1):5049.