

# Neovascularization markers in canine urothelial carcinomas: A cross-sectional study

Fabio Gentilini<sup>1</sup> | Roberta Salaroli<sup>1</sup> | Raimondo Tornago<sup>1,2</sup> | Maria Elena Turba<sup>3</sup> | Tolulope Grace Ogundipe<sup>1</sup> | Augusta Zannoni<sup>1</sup> | Monica Forni<sup>1</sup> | Michela Campigli<sup>4</sup> | Tommaso Furlanello<sup>4</sup>

<sup>1</sup>Department of Veterinary Medical Sciences, University of Bologna, Ozzano dell'Emilia, Bologna, Italy

<sup>2</sup>Centro veterinario Meranese, Merano, BZ, Italy

<sup>3</sup>Genefast srl, Forlì, Italy

<sup>4</sup>Veterinary Clinic and Laboratory San Marco, Veggiano, Padua, Italy

## Correspondence

Fabio Gentilini, Department of Veterinary Medical Sciences, University of Bologna, Ozzano dell'Emilia, Bologna, Italy.  
Email: [fabio.gentilini@unibo.it](mailto:fabio.gentilini@unibo.it)

## Present address

Raimondo Tornago, Centro veterinario Meranese, Merano, BZ, Italy

## Abstract

**Background:** In humans, there is a growing body of evidence that neovascularization is crucial for tumour growth and progression in urothelial carcinomas (UC) which also typically exhibit overactivation of the RAS-MAPK pathway. In canine UC (cUC), the same pathway has been aberrantly activated due to V595E BRAF variant and BRAF inhibitors has been evaluated as more effective treatment. However, BRAF inhibition is hampered in humans by rapidly occurring of chemoresistance. Targeting angiogenesis has been speculated to increase the effectiveness of BRAF inhibitors and to delay the development of chemoresistance.

**Objectives:** This study aimed to investigate the level of angiogenic markers in urine samples of UC affected dogs ( $n = 15$ ) in comparison to an unmatched control group ( $n = 16$ ) along with the clinical, morphological and molecular features.

**Methods:** In urine, both vascular endothelial growth factor (VEGF) concentration, using an ELISA assay, and MMP2 and 9 activities, using the zymographic assay, were measured. BRAF analysis was carried out using a digital PCR method.

**Results:** Urinary VEGF concentration (mean pg/g\_uCrea  $6.9 \pm 27.7$  vs.  $1074 \pm 1797$ ,  $p < 0.01$ ) and MMP activity (mean  $6.8 \times 10^6 \pm 9.2 \times 10^6$  vs.  $2.5 \times 10^7 \pm 2.3 \times 10^7$ ,  $p < 0.05$ ) were higher in affected dogs than in healthy controls. Urinary active MMP9 was significantly correlated with T3 stage, it was absent in dogs with undetectable VEGF and it correlated well with urinary VEGF concentration. In this cohort, 10/10 UC affected dogs exhibited the V595E BRAF variation.

**Conclusion:** The findings are consistent with the presence of overactive neovascularization in cUC. Urinary active MMP9 may be suitable for use as tumour progression biomarker. The addition of angiogenesis targeting may be rationale for novel therapeutic strategies.

## KEYWORDS

BRAF inhibitor, dogs, matrix metalloproteinase, neovascularization, urothelial carcinoma, VEGF

This is an open access article under the terms of the [Creative Commons Attribution-NonCommercial-NoDerivs](https://creativecommons.org/licenses/by-nc-nd/4.0/) License, which permits use and distribution in any medium, provided the original work is properly cited, the use is non-commercial and no modifications or adaptations are made.

© 2023 The Authors. *Veterinary Medicine and Science* published by John Wiley & Sons Ltd.

## 1 | INTRODUCTION

Bladder cancer encompasses ~2% of all naturally occurring cancers in dogs. Among these, urothelial carcinoma (UC) is the most common with an increasing incidence over the last 30 years (Cannon & Allstadt, 2015; Fulkerson & Knapp, 2015; Knapp et al., 2014). It is typically diagnosed in older female and neutered dogs are at increased risk (Knapp et al., 2014). Although the cause of UC is multifactorial, environmental factors, such as household insecticide use and herbicide exposure, play a strong role, as does genetic background in predisposed breed as Scottish Terriers (Glickman et al., 2004; Luethcke et al., 2019). Canine UC (cUC) shares many features with its human counterpart including epidemiology, clinical signs, biological behaviour and response to therapy, in addition to macroscopic, histopathological and molecular features (De Brot et al., 2018). For that reason, most grading systems are based on the WHO scheme which includes cellular atypia, cellular and nuclear pleomorphism, mitotic activity, depth of invasion, and lymphovascular invasion (Owen, 1980; Patrick et al., 2006; Valli et al., 1995). More recently, a two-tier grading system has been suggested to better represent the canine pathology (Avallone et al., 2021). Regardless of the systems used, most cUCs are high grade (Avallone et al., 2021; Owen, 1980; Patrick et al., 2006; Valli et al., 1995).

Based on growth pattern, UCs are further classified into papillary or nonpapillary and infiltrating or noninfiltrating tumours (Meuten & Meuten, 2016).

The survival and proliferation of tumour cells depends upon an adequate blood supply to provide oxygen and nutrients. Indeed, rapidly growing tumours are more heavily vascularized. The accelerated growth of tumour cells leads to a hypoxic microenvironment which in turn stimulates angiogenesis via vascular endothelial growth factor (VEGF) secretion (You et al., 2021; Zhang et al., 2020). During angiogenesis, new vessels emerge from existing endothelial lined vessels together with degradation of the vascular basement membrane and remodelling of the extracellular matrix (ECM), followed by endothelial cell migration, proliferation and de-novo generation of matrix components (Quintero-Fabián et al., 2019). Degradation of the ECM involves various different proteases of which the most crucial are the MMPs. Activated MMPs also participate in tumour neovascularization and subsequent metastasis. The angiogenic response is thus directly and indirectly mediated by VEGF and MMPs through modulation of the balance between pro- and anti-angiogenic factors (Jabłońska-Trypuć et al., 2016). This explains the prognostic power of VEGF and of its ever-growing related biomolecules such as matrix metalloproteinases 2 (MMP2) and 9 (MMP9) (Aresu et al., 2014; Folkman, 1971; Hao et al., 2007; Lugano et al., 2020; Massimini et al., 2021). Interestingly, microarray studies of canine invasive UC have indicated the presence of luminal and basal cUC subtypes similar to those found in human invasive UC and, among others, the enriched gene MMP9 is found in invasive basal tumours, but not in luminal tumours (Dhawan et al., 2015). Although there are marker similarities between human UC and its canine counterpart, differences also exist. For example, although activating mutations in the MAPK pathway occur in invasive UC of both

species, BRAF mutations are common in dogs (79.0%–90.9%) but rare in humans (Decker et al., 2015; Dhawan et al., 2018; Fulkerson et al., 2017; Gentilini et al., 2022; Mochizuki et al., 2015; Tagawa et al., 2020). BRAF is part of the MAPK signalling pathway and its activating mutations lead to uncontrolled cell growth (Ghosh & Chin, 2009; Haluska et al., 2006; Quintero-Fabián et al., 2019).

In fact, the V595E variation of the BRAF oncogene is one of the most important driver mutations of cancer and thus it may represent a key therapeutic target. In recent years, three BRAF inhibitors specifically intended for BRAF activating mutations have been marketed and one of these is being evaluated for use in dogs (Bollag et al., 2010; Flaherty et al., 2012; Roskoski, 2019; Rossman et al., 2021). Unfortunately, their effectiveness is hampered by development of chemoresistance via reactivation of the MAPK pathway or the activation of alternative signalling pathways (Holderfield et al., 2014; Samatar & Poulikakos, 2014). It is increasingly evident that combination therapy either by concurrent targeting of additional proteins in the MAPK signalling pathway or by targeting angiogenesis is required to delay chemoresistance. In fact, combined therapy with BRAF inhibitor and the antiangiogenesis drug bevacizumab may act synergistically against tumour growth (Comunanza et al., 2017). The complex interplay between VEGF and BRAF mutations and the correlation between angiogenesis and the evolution of BRAFV600E kinase inhibitor-acquired resistance are still poorly understood.

This study is aimed to investigate the level of angiogenic markers VEGF, MMP2 and 9 along with other features of the cUC to support an evidence-based therapeutic approach targeting angiogenesis in this tumour.

## 2 | METHODS

### 2.1 | Clinical cases and samples

The medical records of 15 dogs diagnosed with UC of the bladder which had their respective urine stored frozen were retrieved. The 15 cases had a histologic diagnosis of UC ( $n = 13$ ) or cytological evidence of the disease ( $n = 2$ ). The histological sections and cytological smears were from biopsies or brushes collected endoscopically or by surgical excision. Urine was collected either by spontaneous micturition ( $n = 12$ ) or via catheterization ( $n = 3$ ). An unmatched control group of 16 frozen stored urine represented by leftovers diagnostic samples was selected and retrieved by searching the medical records for dogs which had undergone to urinalysis for routine controls as neutering, dental care or routine screening for vaccination. The dogs underwent a complete clinicopathological examination including biochemical panel with C-reactive protein measurement, complete blood count including blood smear examination, serum capillary electrophoresis, urinalysis including dipstick, sediment examinations and biochemical urinary panel and complete haemostatic profile including ATIII and d-dimers/FDP measurements. The dogs retrospectively evaluated healthy based on unrewarding findings and whose urines were available were included.

## 2.2 | Histology and cytology

Tissue samples were collected into 10% neutral-buffered formalin and allowed to fix for at least 24 h. Samples were processed, embedded in paraffin wax, sectioned and stained with hematoxylin and eosin for routine histopathological examination by a board-certified anatomic pathologist. Urine was centrifuged at  $800 \times g$  for 5 min. The supernatant was removed and transferred to a separate tube. The pellet was mixed using a vortex mixer and used to make cytological smears stained with modified May-Grunwald Giemsa and cover slipped for cytological examination by a board-certified clinical pathologist. In 13 cases out of 15 the diagnosis was made based upon histology, whereas the remaining case diagnosis was based on cytological evaluation.

## 2.3 | Urinary total protein and creatinine measurement

Urinary total proteins were measured using a pyrogallol red assay, whereas urinary creatinine (U<sub>crea</sub>) was measured using the kinetic modification of the Jaffe procedure. Both methods were automatized on the AU2700 chemistry analyser (Beckman Coulter) and calibrated using specific urinary calibrators (OS system reagents).

## 2.4 | Vascular endothelial growth factor urinary concentrations

Urinary VEGF concentration was measured using a commercial ELISA kit (LifeSpan Biosciences), recommended for use with dog urine, following the manufacturer's instructions.

## 2.5 | Zymography and MMP2 and 9 activity urinary quantification

Urine MMP2 and 9 (proenzymes and active enzymes) were measured by gelatin zymography as previously described with some modifications (Gentilini et al., 2005). Briefly, MMP2 and MMP9 activity was analysed on 10% Tris-Glycine polyacrylamide precast gels with 0.1% gelatin (Novex 10% Zymogram Gelatin Gels, Invitrogen UK). A volume of 5  $\mu$ L of samples were mixed with an equal volume of sample buffer (Tris-Glycine SDS Sample Buffer 2X, Invitrogen UK) and loaded in the gel wells. Electrophoresis was performed at a constant voltage of 125 V for 90 min in Tris-Glycine SDS running buffer 1 $\times$  (Novex Tris-Glycine SDS Running Buffer, Invitrogen UK). An MMP2 and MMP9 human standard (Chemicon International) was run together on the same gel. Following electrophoresis, the gels were washed for 30 min in renaturing buffer 1 $\times$  (Zymogram Renaturing Buffer, Invitrogen UK), equilibrated at room temperature for 30 min in developing buffer 1 $\times$  (Zymogram Developing Buffer, Invitrogen UK) and then incubated with a fresh aliquot of the same buffer at 37°C for 48 h in order

to increase test sensitivity, especially for MMP2 which resulted in all cases much fainter than MMP9. Bands of gelatinolytic activity were developed after staining gels for 1 h with Simply Blue Safe Stain (Invitrogen UK) then the gels were destained overnight in deionized water. Gelatinolytic bands corresponding to canine MMP2 and MMP9 were identified on the basis of the molecular weight of approximately 68 and 92 kDa, respectively, as described by Bergman et al. (2007) and Leibman et al. (2000). Gel images were captured with computerized system (ChemiDoc Imaging System, Bio-Rad) and gelatinolytic bands were measured with densitometric analysis software (Image Lab, Bio-Rad). The resulting data are expressed as arbitrary units.

## 2.6 | V595E variant detection

The genomic DNA (gDNA) was purified from all the formalin-fixed paraffin-embedded (FFPE) slides which could be retrieved ( $n = 10$ ) using the Maxwell RSC DNA FFPE Kit run on an automated extractor (Maxwell RSC 48, Promega) which relies on a magnetic particle mover and paramagnetic beads. Three histological slides and the only two cytological smears could not be recovered.

The V595E BRAF variation detection was carried out using a digital PCR (dPCR) assay previously validated (Gentilini et al., 2022). Briefly, using the following procedures: The dPCRs were carried out using a mixture containing 1 $\times$  of master mix (QuantStudio 3D Digital PCR Master Mix v2; Thermo Fisher Scientific), 1 $\times$  of primer mix (TaqMan SNP Genotyping Assay, Thermo Fisher) and 2  $\mu$ L of gDNA template and molecular biology grade water to reach a final volume of 20  $\mu$ L. The PCRs were carried out using a three-step protocol: initial denaturation at 95°C for 10 min followed by 40 cycles at 95°C for 30 s, 60°C for 2 min and 71°C for 2 min. Then, the reaction mix is loaded on a chip (QuantStudio 3D Digital PCR 20K Chip Kit v2), the chip is sealed and placed in the Flex 2  $\times$  Flat PCR System for thermal cycling (Thermo Fisher). At the end, the chip is inserted into the chip reader (QuantStudio 3D Digital PCR instrument) and analysed using the QuantStudio 3D AnalysisSuite Software. Only chips with at least 17 500 wells correctly read were considered adequate and analysed.

## 2.7 | Statistical analysis

Descriptive statistics were carried out using Microsoft Excel, including the Analyse-it package Software. Correlation analysis of angiogenic factors: activated MMP2, activated MMP9, proenzyme of MMP2, proenzyme of MMP9 and VEGF included the calculation of both Spearman's  $r_s$  and Kendall's tau correlation factors. Comparison between groups, testing the null hypothesis that groups (healthy controls and UC affected dogs) were not different, were carried out using the Wilcoxon-Mann-Whitney test. The multiple comparisons of angiogenic factors between the stages were carried out using the Tukey-Kramer test. The survival curves were calculated with the Kaplan-Meier estimates method using the Stata v.11.0 software. In any case a  $p$  value  $<0.05$  were considered statistically significant.

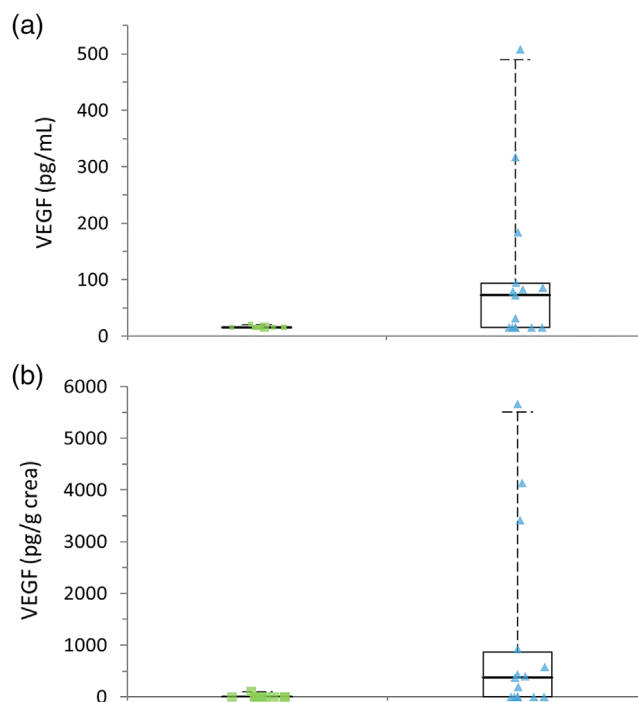
**TABLE 1** Description of urothelial carcinoma-affected cohort and unmatched control group.

	Healthy	Affected	p Value
Age	6.5 (3–10)	11 (8–13)	<0.001
Sex	Male 10 (62.5%)–female 6 (37.5%)	Male 4 (26.6%)–female 11 (73.3%)	0.045
Weight (median range)	23.5 (4.5–64.7)	12.0 (4.4–35.0)	0.166
Breeds	4 Mixed breeds 2 West highland white terriers 2 Labrador retrievers 1 Each: Alaskan Malamute, Miniature Poodle, Shiba Inu, Maltese, Siberian Husky, German Shepherd, Golden Retriever and Pitt Bull	8 Mixed breeds 2 Scottish Terriers 1 Each: Lagotto Romagnolo, Alaskan Malamute, Beagle, Labrador Retriever and Fox Terrier	

### 3 | RESULTS

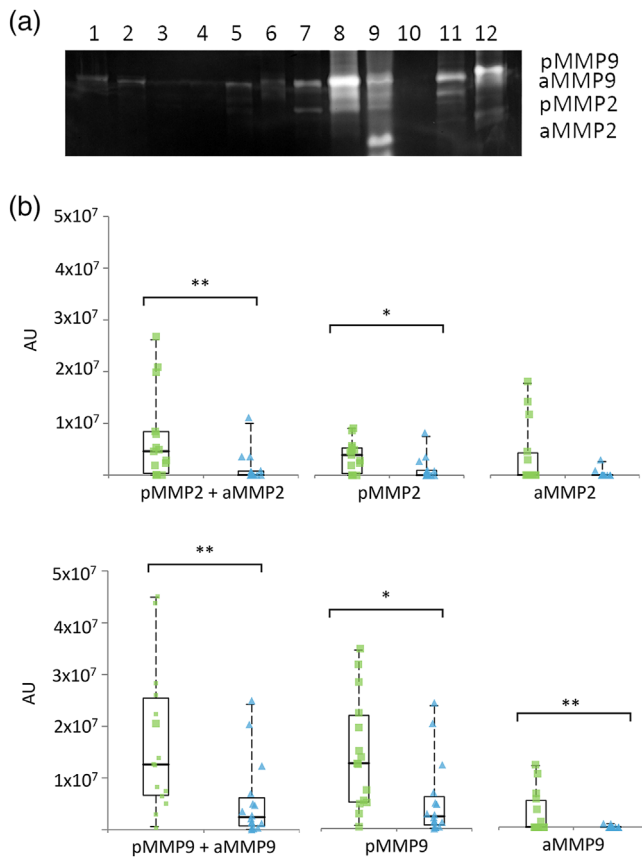
Overall, 15 cases of cUC were included in the study. The affected dog's cohort included eight mixed-breed dogs, two Scottish Terrier dogs and five dogs of different other breeds. All diseased dogs ranged between 8 and 13 years of age (median 11 years). Eleven affected dogs were female, whereas four were male. The median weight was 12.0 kg (range: 4.4–35.0 kg; first quartile 8.1 kg; third quartile 17.3 kg). The unmatched control group was different from the affected dogs' group for the factors sex (males overrepresented: 62.5% vs. 26.6%,  $p < 0.05$ ) and age (control were younger: mean (range): 6.5 (3–10) vs. 11 (8–13,  $p < 0.01$ ), whereas the weight was not different (Table 1). The significant features of the UC affected dogs' group are reported in Table 1. The staging was accomplished using computed tomography in 10 out of 15 (66.7%), chest radiographs in 7 out of 15 (46.7%), bladder endoscopy in 9 out of 15 (60.0%), ultrasonography in 5 out of 15 (33.3%) or combinations thereof. According with the WHO staging system one case was an in situ carcinoma (Tis/N0/M0), five cases were T1/N0/M0, five cases were T2/N0/M0 and four cases were T3 without ( $n = 2$ ) or with ( $n = 2$ ) nodal involvement (Humphrey et al., 2016; Knapp et al., 2014; Owen, 1980). Eleven out of 15 cases had undergone therapy with either NSAID (meloxicam  $n = 2$ , piroxicam  $n = 6$  and others  $n = 1$ ), antineoplastic drugs (mitoxantrone  $n = 5$ , carboplatin  $n = 3$ , vinblastine  $n = 1$  and not specified  $n = 1$ ) or surgery ( $n = 3$ ) under different combinations. In all cases, antineoplastic therapies were instituted after the diagnosis had been made. Complete follow up until the fatal outcome was available for 10 out of 15 cases (66.7%). The overall median survival time was 152 days (25th–75th percentile: 24–574 days) (Figure S1A). Those subjects diagnosed at stage 3 had survival time significantly shorter than stage 2 (Figure S1B).

Urinary concentrations of VEGF were expressed either as such (Figure 1a) or dilution-normalized by dividing their concentration for the U creatinine as mg/dL (Figure 1b). Complete VEGF findings in UC-affected, and healthy dogs are reported in Figure 1. Urinary VEGF concentrations were higher in affected dogs than healthy controls (mean pg/g\_uCrea:  $1074 \pm 1797$  vs.  $6.9 \pm 27.7$ ,  $p < 0.01$ ). Three dogs showed very high VEGF concentrations. Unfortunately, no clues could be drawn on the meaning of these outliers; they were either stage 1, 2 or 3, two dogs were mixed-breed, two dogs weighted below 10 kg, two were females and two were neutered. The only common feature shared



**FIGURE 1** Box-plot graphs comparing urinary VEGF concentration as such (pg/mL) (a) or corrected for the concentration of the urine (pg/g creatinine) (b) between groups (green: healthy dogs; blue: urothelial carcinoma affected dogs). VEGF, vascular endothelial growth factor; creatinine, creatinine.

by all three dogs was that all three dogs had detectable activated MMP9 compared with the 6/15 (40.0%) of all the cohort. Conversely, six dogs without detectable VEGF in their urine were more homogeneously characterized being four T1 stage, including the only in situ carcinoma, and two T2 stage and no one has activated MMP9 in their urines; furthermore, 5/6 (83.3%) were neutered females compared with the 11/15 of the entire cohort (73.3%). Finally, both the Scottish Terriers in this study belong to this subgroup having undetectable VEGF and aMMP9. In total, MMPs urinary activity as measured as zymolytic activity (Figure 2a) were higher in the UC-affected dogs when compared with healthy dogs (Figure 2b): aggregate MMPs mean  $6.8 \times 10^6 \pm 9.2 \times 10^6$  vs.  $2.5 \times 10^7 \pm 2.3 \times 10^7$ ,  $p < 0.05$ ; pMMP2  $1.1 \times 10^6 \pm 2.2 \times 10^6$  vs.  $3.6 \times 10^6 \pm 3.0 \times 10^6$ ,  $p < 0.05$ ; aMMP2



**FIGURE 2** (a) Example of gelatinase activity in canine urine from urothelial carcinoma-affected and healthy control dogs. Lane 1–5: healthy control dogs; lane 6–11: carcinoma-affected dogs; lane 12 human MMP9 (p: proenzyme and a: active enzyme) and MMP2 (p: proenzyme and a: active enzyme) standard (b) box-plot graphs comparing relative abundance of proenzymes (pMMP9 and pMMP2), active enzymes (aMMP9 and aMMP2) and total metalloproteinases 9 (pMMP9 + aMMP9) and 2 (pMMP2 + aMMP2) between groups (green: urothelial carcinoma affected dogs; blue: healthy dogs) as determined by densitometric analysis expressed as means  $\pm$  SEM. \*\* and \*\*\* statistically significant difference for  $p < 0.05$  and  $p < 0.01$ , respectively. AU, arbitrary unit; MMP, matrix metalloproteinase.

$2.4 \times 10^5 \pm 7.5 \times 10^5$  vs.  $4.7 \times 10^6 \pm 9.9 \times 10^6$ ,  $p < 0.01$ ; pMMP9  $5.4 \times 10^6 \pm 7.4 \times 10^6$  vs.  $1.4 \times 10^7 \pm 1.1 \times 10^7$ ,  $p < 0.05$ ; aMMP9  $8.0 \times 10^4 \pm 2.2 \times 10^5$  vs.  $2.6 \times 10^6 \pm 4.1 \times 10^6$ ,  $p < 0.05$ . The source of MMPs activity is unlikely to be derived from the leukocytes; in fact, sediment examination showed that 9/15 cases did not have white blood cells at high-power field (WBC/HPF at 400x) while the remaining cases had low values ranging between 1 and 6 WBC/HPF. The number of WBC/HPF is not correlated to MMPs activity (Spearman's  $r_s = 0.16$ ,  $p = 0.94$ ) (Figure S2).

Correlation analysis of angiogenic factors showed that VEGF better correlates with aMMP9 (Spearman's  $r_s$  0.499), and pMMP9 with pMMP2 (Spearman's  $r_s$  0.687) and aMMP2 (Spearman's  $r_s$  0.606) (Figure 3a,b).

Finally, higher levels of aMMP9 (stage 1 vs. stage 3:  $1.1 \times 10^6 \pm 2.6 \times 10^6$  vs.  $7.0 \times 10^6 \pm 5.4 \times 10^6$ ,  $p < 0.05$ ; stage 2

vs. stage 3:  $0.9 \times 10^6 \pm 1.5 \times 10^6$  vs.  $7.0 \times 10^6 \pm 5.4 \times 10^6$ ,  $p < 0.05$ ) were found in those dogs with T3 stages (Figure 4).

BRAF variant V595E could be tested in 10 out of 15 sample and all (10/10) were positive for the variant. The 10 cases investigated with V595E testing included one case of in situ carcinoma (Tis/N0/M0), 2 cases were T1/N0/M0, 5 cases were T2/N0/M0 and 2 cases were T3/N0/M0.

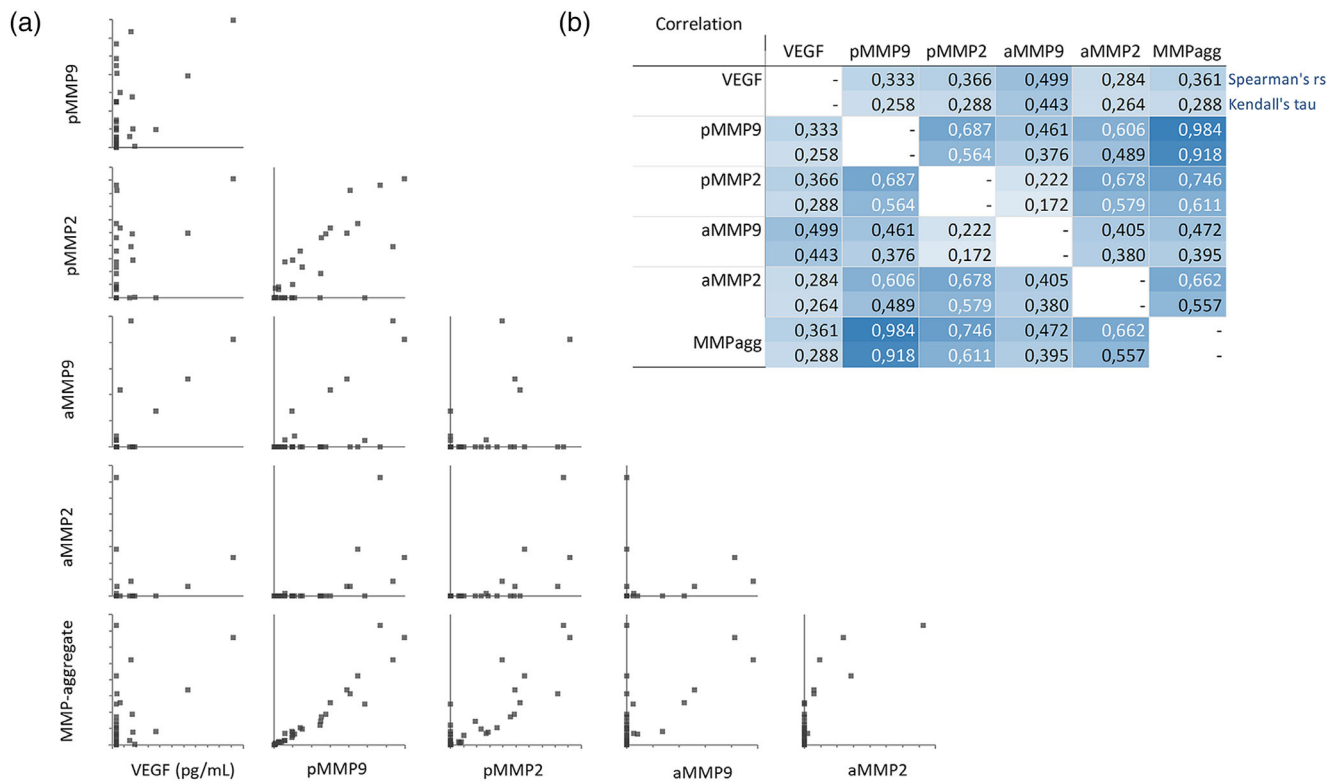
## 4 | DISCUSSION

The main conclusions of this study are that angiogenic mechanisms are overly active in cUC and that some of the markers, such as aMMP9, increase with tumour stage. The study also supports the possibility that active MMP9 is the more reliable markers of cUC tumour progression being significantly correlated with T3 stages and the most correlated with urinary VEGF concentration. The high prevalence of the V595E BRAF variation (10/10 dogs) meant that it was not possible to investigate its relationship with the angiogenesis switch.

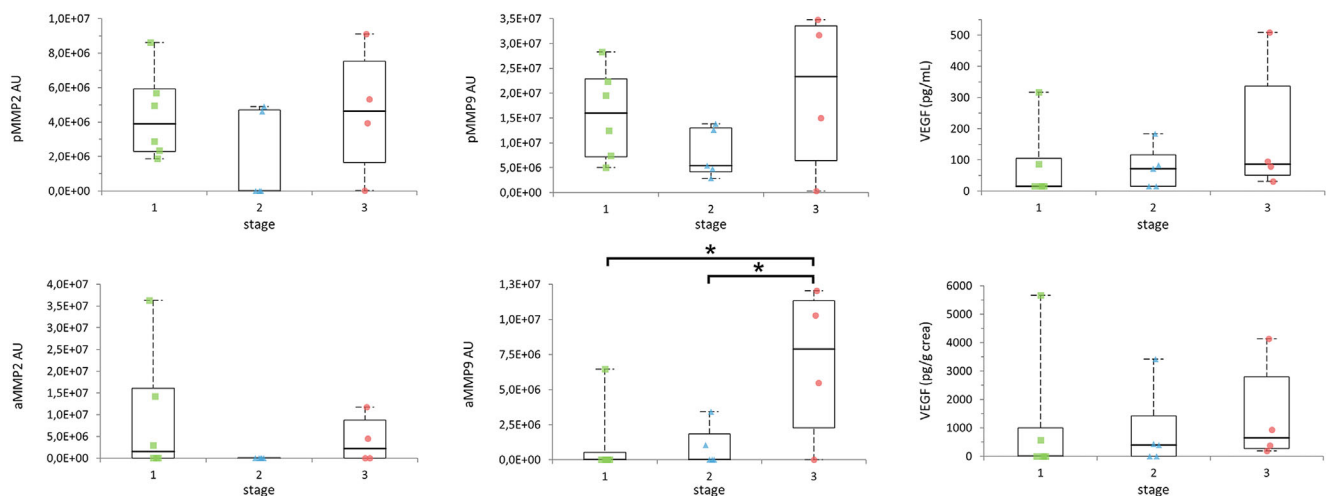
It is well established that early signs of UC in dogs may be subtle and may go unnoticed until more severe signs develop; hence, at diagnosis approximately 90% of tumours are stage T2 or T3 (McMillan et al., 2012; Vilar et al., 2004). Similarly, in our study most cases were diagnosed at advanced T2 or T3 stages. Thus, unlike in human UC, complete excision of cUC is rarely possible because of location and local invasion (McMillan et al., 2012; Vilar et al., 2004). Consequently, partial cystectomy, chemotherapy and cyclooxygenase inhibitors are the mainstay of treatment for primary and metastatic UC in dogs. However, remission rates for combination therapy with platinum agents and cox inhibitors are only 35%–50% (McMillan et al., 2012; Mohammed et al., 2003; Knapp et al., 2013). This highlights the importance of considering alternative therapeutic targets and designing new tests to enable diagnosis earlier in the course of disease. In this regard, it is worth noting that only two dogs in this study had undetectable levels of both urinary VEGF and aMMP at the time of diagnosis. Further studies should be carried out to determine the role, if any, of VEGF and aMMP9 for the early detection of UC in urine of dogs considered to be at an increased risk of UC.

This study has several limitations since it is retrospective in nature and since a limited number of dogs with cUC were enrolled. Furthermore, the use of surplus patient urine samples for the control group meant that these samples were not matched for age or sex with the cohort of diseased dogs. Nevertheless, to our knowledge the only study investigating the effect of age and sex on the concentration of angiogenic factors in human urine did not find any significant differences (Monier et al., 2002). Although the control group contained dogs retrospectively judged to be healthy based on physical examination and thorough clinicopathology analyses, we cannot completely rule out occult disease or undisclosed medications. However, in the event of occult disease, we would have expected increased activity/concentration of the angiogenic markers, thus reducing rather than overestimating any differences with the cUC group.





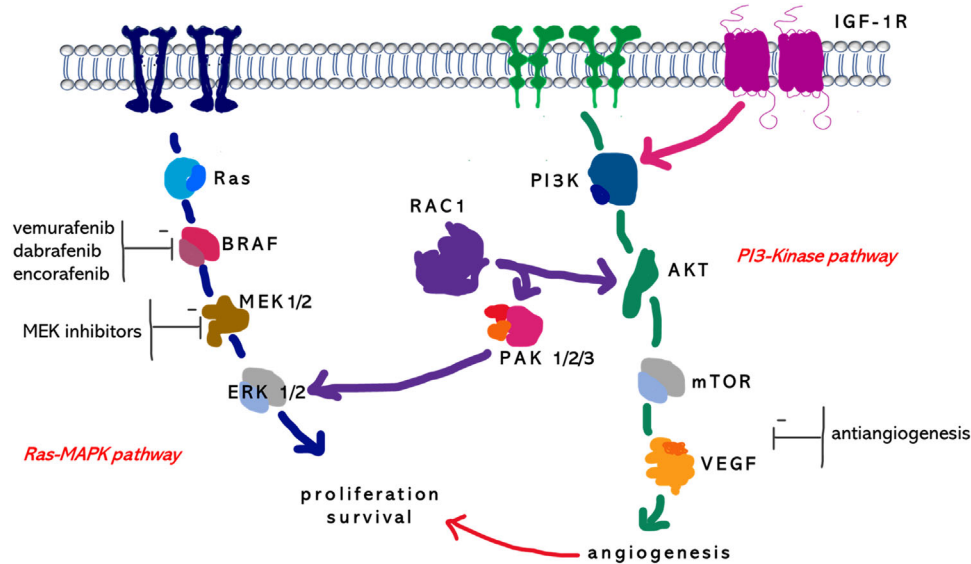
**FIGURE 3** Correlation analysis of angiogenic factors: (a) scatter plot matrix showing all pairwise scatter plots for angiogenic factors: aMMP2: activated MMP2; aMMP9: activated MMP9; pMMP2: proenzyme of MMP2; pMMP9: proenzyme of MMP9; MMPagg: aggregate MMP activity. (b) Correlation matrix: both Spearman's rs (up in each cell) and Kendall's tau (below in each cell) correlation factors are reported. VEGF, vascular endothelial growth factor.



**FIGURE 4** Angiogenic factors levels according with WHO stages. aMMP9 is significantly higher ( $p < 0.05$ ) in T3 stage than either T1 or T2 stages. \* Statistically significant difference for  $p < 0.05$ . AU, arbitrary unit; MMP, matrix metalloproteinase; VEGF, vascular endothelial growth factor.

Despite these limitations, it is clear that, particularly in T3 stages cUC, all angiogenic factors were consistently increased and reached significance in case of aMMP9. Higher values of urinary VEGF were associated with aMMP9 while the absence of detectable VEGF in urine

was associated with absence of aMMP9 and lower tumour stages. This suggests that angiogenesis is crucial in sustaining tumour growth and local invasion and implies that angiogenesis is not induced by antitumour treatments being already active at the sampling time.



**FIGURE 5** Schematic representation of the pathways aberration involved in the oncogenesis and the possible role of alternative pathways (RAC1-PAK) and (IGF/IGF-1R) supporting the resistance against BRAF inhibitors. Moreover, the interconnections between the Ras-MAPK pathways and neoangiogenesis are represented. IGF-1R: insulin-like growth factor-1 receptor; PI3K: phosphatidylinositol 3-Kinase; AKT: AKT serine/threonine kinase; mTOR: mechanistic target of rapamycin; VEGF: vascular endothelial growth factor; RAC1: ras-related C3 botulinum toxin substrate 1; PAK 1/2/3 p21-activated kinase 1/2/3; Ras: rat sarcoma virus; BRAF: B-raf proto-oncogene, serine/threonine kinase; MEK 1/2: MAP kinase-ERK kinase 1/2; ERK: extracellular regulated MAP kinase.

MMP9 has a prominent role in cancer progression. Recently, a canine expression signature capable of distinguishing luminal vs. basal tumour subtypes has been identified and the enriched genes in basal tumours included MMP9 (Dhawan et al., 2018). Other studies have suggested that MMP9 activity levels are significantly enhanced in the urine of human patients with highly invasive cancers, whereas urine from healthy controls has no or very low MMP activities (Moses et al., 1998; Sier et al., 2000). Additionally, Nutt et al. (2003) showed that there was no significant relationship between urinary MMP9 activity and endothelial growth factor status of the tumour, and suggested that MMP9 should be considered a drug development target for the treatment of human bladder cancer. More recently, Yin et al. (2018) reported that the levels of MMP9 and VEGF are higher in the proliferative stage of infantile haemangioma than other stages and that both MMP9 and VEGF are likely to serve as markers for the development of haemangioma. Therefore, new therapeutic drugs targeting MMP9 may be promising both in canine and human oncology. Indeed, the similarities in underlying pathway aberrations help to confirm the role of canine tumours as a spontaneous model for human UC. The findings reported here strengthen the feasibility of cross-species assay suitability for simultaneous parallel comparative oncology investigations in canine and human bladder cancer patients and to further optimize outcomes in both species.

BRAF inhibitors are being evaluated as novel therapies for cUC (Rossman et al., 2021). In upcoming years, they will likely be introduced as standard treatment in those tumours carrying BRAF activating mutations. Despite their efficacy, long-term control of disease is limited by the chemoresistance which eventually develops. The interplay

between angiogenesis and the BRAF inhibitor-acquired resistance is still poorly understood but it has been shown that RAS-MAPK pathway overactivation and cell survival due to BRAF mutations and PI3K-AKT pathway activating angiogenesis mutually magnify each other throughout different key molecules (Figure 5). In particular, RAC1-PAK pathway upregulation sustains both tumour angiogenesis and the RAS-MAPK pathway eventually counteracting the BRAF inhibitors (De et al., 2019). Another less clear mechanism involves tumour-secreted IGF1 activating the IGF1/IGF1R axis and leading to BRAF inhibitors chemoresistance through vascular remodelling (Figure 5) (Xu et al., 2022).

In conclusion, neoangiogenesis processes are active in cUC. This study fosters further efforts to determine the precise role of targeting angiogenesis alone or in combination with molecularly targeted therapy in the treatment and detection of cUC.

#### AUTHOR CONTRIBUTIONS

Conceptualization; data curation; methodology; project administration; resources; supervision; validation; writing – original draft: Fabio Gentilini. Data curation; investigation; writing – original draft: Roberta Salaroli. Data curation; validation; writing – review and editing: Raimondo Tornago. Data curation; resources; writing – review and editing: Maria Elena Turba. Data curation; investigation; writing – review and editing: Tolupe Grace Ogundipe. Data curation; investigation; validation; writing – review and editing: Augusta Zannoni and Michela Campigli. Data curation; investigation; resources; validation; writing – review and editing: Monica Forni. Conceptualization; investigation; methodology; resources; supervision; validation; writing – review and editing: Tommaso Furlanello.

## ETHICS STATEMENT

The Ethics review board, Committee for Animal Welfare, of the University of Bologna considers that this type of project does not fall under the legislation for the protection of animals used for scientific purposes, national decree-law 26/2014. Only leftover samples from routine diagnostic were used in the study. Their search aims, layout and methods and all other aspects mentioned here have been evaluated by the University of Bologna Ethic Committee (COBA) and formally approved under the protocol ID 147351.

## DATA AVAILABILITY STATEMENT

The data that support the findings of this study are available on request from the corresponding author. The data are not publicly available due to privacy or ethical restrictions.

## ORCID

Fabio Gentilini  <https://orcid.org/0000-0002-0970-4827>

Roberta Salaroli  <https://orcid.org/0000-0002-8819-2857>

Tolulope Grace Ogundipe  <https://orcid.org/0000-0002-3976-6391>

Monica Forni  <https://orcid.org/0000-0003-1310-6202>

## PEER REVIEW

The peer review history for this article is available at <https://www.webofscience.com/api/gateway/wos/peer-review/10.1002/vms3.1287>.

## REFERENCES

- Aresu, L., Aricò, A., Comazzi, S., Gelain, M. E., Riondato, F., Mortarino, M., Morello, E., Stefanello, D., & Castagnaro, M. (2014). VEGF and MMP-9: Biomarkers for canine lymphoma. *Veterinary and Comparative Oncology*, 12(1), 29–36. <https://doi.org/10.1111/j.1476-5829.2012.00328.x>
- Avallone, G., Rasotto, R., Chambers, J. K., Miller, A. D., Behling-Kelly, E., Monti, P., Berlato, D., Valenti, P., & Roccabianca, P. (2021). Review of histological grading systems in veterinary medicine. *Veterinary Pathology*, 58(5), 809–828. <https://doi.org/10.1177/0300985821999831>
- Bergman, M. R., Teerlink, J. R., Mahimkar, R., Li, L., Zhu, B.-Q., Nguyen, A., Dahi, S., Karliner, J. S., & Lovett, D. H. (2007). Cardiac matrix metalloproteinase-2 expression independently induces marked ventricular remodeling and systolic dysfunction. *American Journal of Physiology. Heart and Circulatory Physiology*, 292(4), H1847–1860. <https://doi.org/10.1152/ajpheart.00434.2006>
- Bollag, G., Hirth, P., Tsai, J., Zhang, J., Ibrahim, P. N., Cho, H., Spevak, W., Zhang, C., Zhang, Y., Habets, G., Burton, E. A., Wong, B., Tsang, G., West, B. L., Powell, B., Shelloe, R., Marimuthu, A., Nguyen, H., Zhang, K. Y. J., ... Nolop, K. (2010). Clinical efficacy of a RAF inhibitor needs broad target blockade in BRAF-mutant melanoma. *Nature*, 467(7315), 596–599. <https://doi.org/10.1038/nature09454>
- Cannon, C. M., & Allstadt, S. D. (2015). Lower urinary tract cancer. *Veterinary Clinics of North America—Small Animal Practice*, 45(4), 807–824. <https://doi.org/10.1016/j.cvsm.2015.02.008>
- Comunanza, V., Corà, D., Orso, F., Consonni, F. M., Middonti, E., Di Nicolantonio, F., Buzdin, A., Sica, A., Medico, E., Sangiolo, D., Taverna, D., & Bussolino, F. (2017). VEGF blockade enhances the antitumor effect of BRAFV600E inhibition. *EMBO Molecular Medicine*, 9(2), 219–237. <https://doi.org/10.15252/emmm.201505774>
- De, P., Aske, J. C., & Dey, N. (2019). RAC1 takes the lead in solid tumors. *Cells*, 8(5), e382. <https://doi.org/10.3390/cells8050382>
- De Brot, S., Robinson, B., Scase, T., Grau-Roma, L., Wilkinson, E., Boorjian, S., Gardner, D., & Mongan, N. (2018). The dog as an animal model for bladder and urethral urothelial carcinoma: Comparative epidemiology and histology. *Oncology Letters*, 16(2), 1641–1649. <https://doi.org/10.3892/ol.2018.8837>
- Decker, B., Parker, H. G., Dhawan, D., Kwon, E. M., Karlins, E., Davis, B. W., Ramos-Vara, J. A., Bonney, P. L., Mcniel, E. A., Knapp, D. W., & Ostrander, E. A. (2015). Homologous mutation to human BRAF V600E is common in naturally occurring canine bladder cancer—evidence for a relevant model system and urine-based diagnostic test. *Molecular Cancer Research*, 13(6), 993–1002. <https://doi.org/10.1158/1541-7786.MCR-14-0689>
- Dhawan, D., Hahn, N. M., Ramos-Vara, J. A., & Knapp, D. W. (2018). Naturally-occurring canine invasive urothelial carcinoma harbors luminal and basal transcriptional subtypes found in human muscle invasive bladder cancer. *PLoS Genetics*, 14(8), e1007571. <https://doi.org/10.1371/journal.pgen.1007571>
- Dhawan, D., Paoloni, M., Shukradas, S., Choudhury, D. R., Craig, B. A., Ramos-Vara, J. A., Hahn, N., Bonney, P. L., Khanna, C., & Knapp, D. W. (2015). Comparative gene expression analyses identify luminal and basal subtypes of canine invasive urothelial carcinoma that mimic patterns in human invasive bladder cancer. *PLoS ONE*, 10(9), e0136688. <https://doi.org/10.1371/journal.pone.0136688>
- Flaherty, K. T., Infante, J. R., Daud, A., Gonzalez, R., Keefe, R. F., Sosman, J., Hamid, O., Schuchter, L., Cebon, J., Ibrahim, N., Kudchadkar, R., Burris, H. A., Falchook, G., Algazi, A., Lewis, K., Long, G. V., Puzanov, I., Lebowitz, P., Singh, A., ... Weber, J. (2012). Combined BRAF and MEK inhibition in melanoma with BRAF V600 mutations. *New England Journal of Medicine*, 367(18), 1694–1703. <https://doi.org/10.1056/NEJMoa1210093>
- Folkman, J. (1971). Tumor angiogenesis: Therapeutic implications. *New England Journal of Medicine*, 285(21), 1182–1186. <https://doi.org/10.1056/NEJM197111182852108>
- Fulkerson, C. M., Dhawan, D., Ratliff, T. L., Hahn, N. M., & Knapp, D. W. (2017). Naturally occurring canine invasive urinary bladder cancer: A complementary animal model to improve the success rate in human clinical trials of new cancer drugs. *International Journal of Genomics*, 2017, 6589529. <https://doi.org/10.1155/2017/6589529>
- Fulkerson, C. M., & Knapp, D. W. (2015). Management of transitional cell carcinoma of the urinary bladder in dogs: A review. *Veterinary Journal*, 205(2), 217–225. <https://doi.org/10.1016/j.tvjl.2015.01.017>
- Gentilini, F., Calzolari, C., Turba, M. E., Agnoli, C., Fava, D., Forni, M., & Bergamini, P. F. (2005). Prognostic value of serum vascular endothelial growth factor (VEGF) and plasma activity of matrix metalloproteinase (MMP) 2 and 9 in lymphoma-affected dogs. *Leukemia Research*, 29(11), 1263–1269. <https://doi.org/10.1016/j.leukres.2005.04.005>
- Gentilini, F., Palgrave, C. J., Neta, M., Tornago, R., Furlanello, T., McKay, J. S., Sacchini, F., & Turba, M. E. (2022). Validation of a liquid biopsy protocol for canine BRAFV595E variant detection in dog urine and its evaluation as a diagnostic test complementary to cytology. *Frontiers in Veterinary Science*, 9, 909934. <https://doi.org/10.3389/fvets.2022.909934>
- Ghosh, P., & Chin, L. (2009). Genetics and genomics of melanoma. *Expert Review of Dermatology*, 4(2), 131. <https://doi.org/10.1586/edm.09.2>
- Glickman, L. T., Raghavan, M., Knapp, D. W., Bonney, P. L., & Dawson, M. H. (2004). Herbicide exposure and the risk of transitional cell carcinoma of the urinary bladder in Scottish Terriers. *Journal of the American Veterinary Medical Association*, 224(8), 1290–1297. <https://doi.org/10.2460/javma.2004.224.1290>
- Haluska, F. G., Tsao, H., Wu, H., Haluska, F. S., Lazar, A., & Goel, V. (2006). Genetic alterations in signaling pathways in melanoma. *Clinical Cancer Research*, 12(7), 2301s–2307s. <https://doi.org/10.1158/1078-0432.CCR-05-2518>
- Hao, L., Zhang, C., Qiu, Y., Wang, L., Luo, Y., Jin, M., Zhang, Y., Guo, T. B., Matsushima, K., & Zhang, Y. (2007). Recombination of CXCR4, VEGF, and MMP-9 predicting lymph node metastasis in human breast cancer. *Cancer Letters*, 253(1), 34–42. <https://doi.org/10.1016/j.canlet.2007.01.005>



- Holderfield, M., Deuker, M. M., McCormick, F., & McMahon, M. (2014). Targeting RAF kinases for cancer therapy: BRAF-mutated melanoma and beyond. *Nature Reviews Cancer*, 14(7), 455–467. <https://doi.org/10.1038/nrc3760>
- Humphrey, P. A., Moch, H., Cubilla, A. L., Ulbright, T. M., & Reuter, V. E. (2016). The 2016 WHO classification of tumours of the urinary system and male genital organs-part B: Prostate and bladder tumours. *European Urology*, 70(1), 106–119. <https://doi.org/10.1016/j.eururo.2016.02.028>
- Jabłońska-Trypuć, A., Matejczyk, M., & Rosochacki, S. (2016). Matrix metalloproteinases (MMPs), the main extracellular matrix (ECM) enzymes in collagen degradation, as a target for anticancer drugs. *Journal of Enzyme Inhibition and Medicinal Chemistry*, 31(Suppl 1), 177–183. <https://doi.org/10.3109/14756366.2016.1161620>
- Knapp, D. W., Henry, C. J., Widmer, W. R., Tan, K. M., Moore, G. E., Ramos-Vara, J. A., Lucroy, M. D., Greenberg, C. B., Greene, S. N., Abbo, A. H., Hanson, P. D., Alva, R., & Bonney, P. L. (2013). Randomized trial of cisplatin versus firocoxib versus cisplatin/firocoxib in dogs with transitional cell carcinoma of the urinary bladder. *Journal of Veterinary Internal Medicine*, 27(1), 126–133. <https://doi.org/10.1111/jvim.12013>
- Knapp, D. W., Ramos-Vara, J. A., Moore, G. E., Dhawan, D., Bonney, P. L., & Young, K. E. (2014). Urinary bladder cancer in dogs, a naturally occurring model for cancer biology and drug development. *ILAR Journal*, 55(1), 100–118. <https://doi.org/10.1093/ilar/ilu018>
- Leibman, N. F., Lana, S. E., Hansen, R. A., Powers, B. E., Fettman, M. J., Withrow, S. J., & Ogilvie, G. K. (2000). Identification of matrix metalloproteinases in canine cutaneous mast cell tumors. *Journal of Veterinary Internal Medicine*, 14(6), 583–586. [https://doi.org/10.1892/0891-6640\(2000\)014<0583:iommic>2.3.co;2](https://doi.org/10.1892/0891-6640(2000)014<0583:iommic>2.3.co;2)
- Luethcke, K. R., Ekena, J., Chun, R., & Trepanier, L. A. (2019). Glutathione S-transferase theta genotypes and environmental exposures in the risk of canine transitional cell carcinoma. *Journal of Veterinary Internal Medicine*, 33(3), 1414–1422. <https://doi.org/10.1111/jvim.15504>
- Lugano, R., Ramachandran, M., & Dimberg, A. (2020). Tumor angiogenesis: Causes, consequences, challenges and opportunities. *Cellular and Molecular Life Sciences*, 77(9), 1745–1770. <https://doi.org/10.1007/s00018-019-03351-7>
- Massimini, M., Romanucci, M., De Maria, R., & Della Salda, L. (2021). An update on molecular pathways regulating vasculogenic mimicry in human osteosarcoma and their role in canine oncology. *Frontiers in Veterinary Science*, 8, 722432. <https://doi.org/10.3389/fvets.2021.722432>
- McMillan, S. K., Knapp, D. W., Ramos-Vara, J. A., Bonney, P. L., & Adams, L. G. (2012). Outcome of urethral stent placement for management of urethral obstruction secondary to transitional cell carcinoma in dogs: 19 cases (2007–2010). *Journal of the American Veterinary Medical Association*, 241(12), 1627–1632. <https://doi.org/10.2460/javma.241.12.1627>
- Meuten, D., & Meuten, T. (2016). Tumors of the urinary system. In *Tumors in domestic animals* (pp. 632–688). Wiley. <https://doi.org/10.1002/9781119181200.ch15>
- Mochizuki, H., Shapiro, S. G., & Breen, M. (2015). Detection of BRAF mutation in urine DNA as a molecular diagnostic for canine urothelial and prostatic carcinoma. *PLoS ONE*, 10(12), e0144170. <https://doi.org/10.1371/journal.pone.0144170>
- Mohammed, S. I., Craig, B. A., Mutsaers, A. J., Glickman, N. W., Snyder, P. W., deGortari, A. E., Schlittler, D. L., Coffman, K. T., Bonney, P. L., & Knapp, D. W. (2003). Effects of the cyclooxygenase inhibitor, piroxicam, in combination with chemotherapy on tumor response, apoptosis, and angiogenesis in a canine model of human invasive urinary bladder cancer. *Molecular Cancer Therapeutics*, 2(2), 183–188.
- Monier, F., Mollier, S., Guillot, M., Rambeaud, J. J., Morel, F., & Zaoui, P. (2002). Urinary release of 72 and 92 kDa gelatinases, TIMPs, N-GAL and conventional prognostic factors in urothelial carcinomas. *European Urology*, 42(4), 356–363. [https://doi.org/10.1016/s0302-2838\(02\)00350-0](https://doi.org/10.1016/s0302-2838(02)00350-0)
- Moses, M. A., Wiederschain, D., Loughlin, K. R., Zurakowski, D., Lamb, C. C., & Freeman, M. R. (1998). Increased incidence of matrix metalloproteinases in urine of cancer patients. *Cancer Research*, 58(7), 1395–1399.
- Nutt, J. E., Durkan, G. C., Mellon, J. K., & Lunec, J. (2003). Matrix metalloproteinases (MMPs) in bladder cancer: The induction of MMP9 by epidermal growth factor and its detection in urine. *BJU International*, 91(1), 99–104. <https://doi.org/10.1046/j.1464-410x.2003.04020.x>
- Owen, L. N., & World Health Organization. Veterinary Public Health Unit & WHO Collaborating Center for Comparative Oncology. (1980). *TNM classification of tumours in domestic animals edited by L.N. Owen*. World Health Organization. <https://apps.who.int/iris/handle/10665/68618>
- Patrick, D. J., Fitzgerald, S. D., Sesterhenn, I. A., Davis, C. J., & Kiupel, M. (2006). Classification of canine urinary bladder urothelial tumours based on the World Health Organization/International Society of Urological Pathology consensus classification. *Journal of Comparative Pathology*, 135(4), 190–199. <https://doi.org/10.1016/j.jcpa.2006.07.002>
- Quintero-Fabián, S., Arreola, R., Becerril-Villanueva, E., Torres-Romero, J. C., Arana-Argáez, V., Lara-Riegos, J., Ramírez-Camacho, M. A., & Alvarez-Sánchez, M. E. (2019). Role of matrix metalloproteinases in angiogenesis and cancer. *Frontiers in Oncology*, 9, 1370. <https://doi.org/10.3389/fonc.2019.01370>
- Roskoski, R. (2019). Targeting ERK1/2 protein-serine/threonine kinases in human cancers. *Pharmacological Research*, 142, 151–168. <https://doi.org/10.1016/j.phrs.2019.01.039>
- Rossmann, P., Zabka, T. S., Ruple, A., Tuerck, D., Ramos-Vara, J. A., Liu, L., Mohallem, R., Merchant, M., Franco, J., Fulkerson, C. M., Bhide, K. P., Breen, M., Aryal, U. K., Murray, E., Dybdal, N., Utturkar, S. M., Fourez, L. M., Enstrom, A. W., Dhawan, D., & Knapp, D. W. (2021). Phase I/II trial of vemurafenib in dogs with naturally occurring, BRAF-mutated urothelial carcinoma. *Molecular Cancer Therapeutics*, 20(11), 2177–2188. <https://doi.org/10.1158/1535-7163.MCT-20-0893>
- Samatar, A. A., & Poulikakos, P. I. (2014). Targeting RAS-ERK signalling in cancer: Promises and challenges. *Nature Reviews Drug Discovery*, 13(12), 928–942. <https://doi.org/10.1038/nrd4281>
- Sier, C. F., Casetta, G., Verheijen, J. H., Tizzani, A., Agape, V., Kos, J., Blasi, F., & Hanemaaijer, R. (2000). Enhanced urinary gelatinase activities (matrix metalloproteinases 2 and 9) are associated with early-stage bladder carcinoma: A comparison with clinically used tumor markers. *Clinical Cancer Research*, 6(6), 2333–2340.
- Tagawa, M., Tambo, N., Maezawa, M., Tomihari, M., Watanabe, K.-I., Inokuma, H., & Miyahara, K. (2020). Quantitative analysis of the BRAF V595E mutation in plasma cell-free DNA from dogs with urothelial carcinoma. *PLoS ONE*, 15(4), e0232365. <https://doi.org/10.1371/journal.pone.0232365>
- Valli, V. E., Norris, A., Jacobs, R. M., Laing, E., Withrow, S., Macy, D., Tomlinson, J., Mccaw, D., Ogilvie, G. K., Pidgeon, G., & Henderson, R. A. (1995). Pathology of canine bladder and urethral cancer and correlation with tumour progression and survival. *Journal of Comparative Pathology*, 113(2), 113–130. [https://doi.org/10.1016/s0021-9975\(05\)80027-1](https://doi.org/10.1016/s0021-9975(05)80027-1)
- Vilar, F. O., de Araújo, L. A. P., & Lima, S. V. C. (2004). Total bladder replacement with de-epithelialized ileum. Experimental study in dogs. *International Brazilian Journal of Urology*, 30(3), 237–244. <https://doi.org/10.1590/s1677-55382004000300013>
- Xu, G., Luo, Y., Wu, W., Liu, X., Yu, X., Bao, Y., He, X., Yu, J., Li, Y., Yang, J., Zhang, R., Yu, C., Chen, H., Xu, J., Hu, J., Jing, J., & Shi, H. (2022). The evolution of acquired resistance to BRAFV600E kinase inhibitor is sustained by IGF1-driven tumor vascular remodeling. *Journal of Investigative Dermatology*, 142(2), 445–458. <https://doi.org/10.1016/j.jid.2021.07.162>
- Yin, R. R., Hao, D., & Chen, P. (2018). Expression and correlation of MMP-9, VEGF, and p16 in infantile hemangioma. *European Review for Medical and Pharmacological Sciences*, 22(15), 4806–4811. [https://doi.org/10.26355/eurrev\\_201808\\_15615](https://doi.org/10.26355/eurrev_201808_15615)
- You, L., Wu, W., Wang, X., Fang, L., Adam, V., Nepovimova, E., Wu, Q., & Kuca, K. (2021). The role of hypoxia-inducible factor 1 in tumor immune evasion. *Medicinal Research Reviews*, 41(3), 1622–1643. <https://doi.org/10.1002/med.21771>

Zhang, P.-C., Liu, X., Li, M.-M., Ma, Y.-Y., Sun, H.-T., Tian, X.-Y., Wang, Y., Liu, M., Fu, L.-S., Wang, Y.-F., Chen, H.-Y., & Liu, Z. (2020). AT-533, a novel Hsp90 inhibitor, inhibits breast cancer growth and HIF-1 $\alpha$ /VEGF/VEGFR-2-mediated angiogenesis in vitro and in vivo. *Biochemical Pharmacology*, 172, 113771. <https://doi.org/10.1016/j.bcp.2019.113771>

#### SUPPORTING INFORMATION

Additional supporting information can be found online in the Supporting Information section at the end of this article.

**How to cite this article:** Gentilini, F., Salaroli, R., Tornago, R., Turba, M. E., Ogundipe, T. G., Zannoni, A., Forni, M., Campigli, M., & Furlanello, T. (2024). Neoangiogenesis markers in canine urothelial carcinomas: A cross-sectional study. *Veterinary Medicine and Science*, 10, e1287.

<https://doi.org/10.1002/vms3.1287>