



CASE REPORT

Angioedema after rt-PA infusion led to airway emergency: a case report of rescue treatment with fresh frozen plasma

Carlo Alberto Mazzoli ^{a,*}, Maura Ida D'Angelo^a, Luigi Simonetti^b, Luigi Cirillo^{c,d}, Andrea Zini^e, Mauro Gentile^e, Giovanni Gordini^a, Carlo Coniglio^a

^a Ospedale Maggiore, Intensive Care and Prehospital Emergency Service, Department of Anesthesia, Bologna, Italy

^b Ospedale Maggiore, Neuroradiology Unit, IRCCS Istituto delle Scienze Neurologiche di Bologna, Bologna, Italy

^c Ospedale Bellaria, Neuroradiology Unit, IRCCS Istituto delle Scienze Neurologiche di Bologna, Bologna, Italy

^d University of Bologna, Diagnostic and Experimental Medicine, Department of Specialty, DIMES, Bologna, Italy

^e Ospedale Maggiore, Department of Neurology and Stroke Center, IRCCS Istituto delle Scienze Neurologiche di Bologna, Bologna, Italy

Received 3 September 2020; accepted 2 April 2021

Available online 28 April 2021

KEYWORDS

Acute ischemic stroke;
Angioedema;
Fresh frozen plasma;
Airway management;
Bradykinin;
Recombinant tissue plasminogen activator

Abstract The authors report the case of a 71-year-old woman presented to the Emergency Department with acute ischemic stroke. She was treated with rt-PA and interventional endovascular revascularization and developed rapidly progressing angioedema that led to emergency intubation. The standard treatment was not very effective and the swelling improved after infusion of fresh frozen plasma.

Angioedema after rt-PA infusion could be a life-threatening emergency that requires quick airway management by skilled professionals. As this condition is triggered by several factors, such as unregulated histamine and bradykinin production, the traditional treatment recommended by the guidelines may not be sufficient and the use of FFP can be considered as a safe and valuable aid.

© 2021 Sociedade Brasileira de Anestesiologia. Published by Elsevier Editora Ltda. This is an open access article under the CC BY-NC-ND license (<http://creativecommons.org/licenses/by-nc-nd/4.0/>).

Introduction

Administration of recombinant tissue plasminogen activator (rt-PA) is a standard of care for patients with acute ischemic stroke (AIS). Orolingual angioedema is a well-known and well-documented side effect of this drug¹ and

* Corresponding author.

E-mail: carloalberto.mazzoli@gmail.com (C.A. Mazzoli).

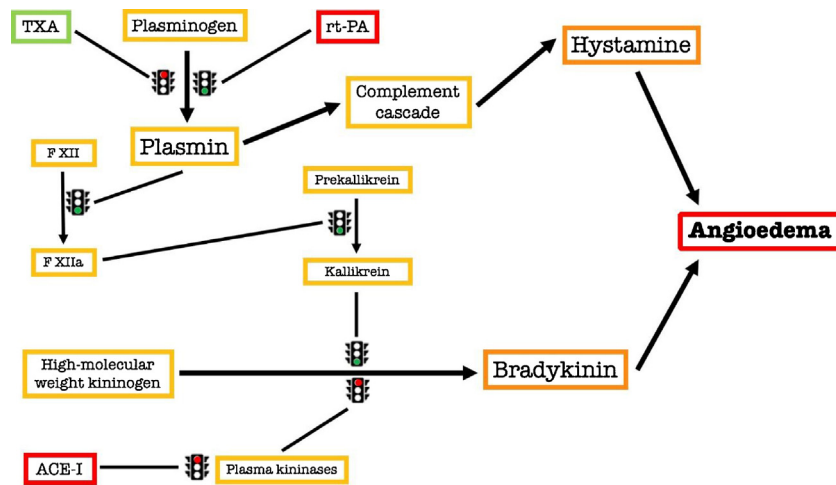


Figure 1 The Angioedema Cascade. TXA, tranexamic acid; rt-PA, recombinant tissue plasminogen activator; F XII, coagulation factor XII or Hageman factor; F XIIa, activated coagulation factor XII; ACE-I, Angiotensin-converting-enzyme inhibitors.

AHA/ASA guidelines² on AIS management describe the emergency treatment of this condition. In the majority of cases of angioedema, the severity is mild to moderate but in small percentages could lead to an airway emergency with an immediate need for intubation. The complete pathway that generates the angioedema after rt-PA administration is still debated, but it is established that it is due to the increased production of histamine and bradykinin caused by rt-PA, as shown in Figure 1. An episode of angioedema is more easily triggered in patients with hereditary angioedema where a C1-inhibitor deficiency is concomitant; this rare condition is not always known to the patient and can, therefore, be unintentionally omitted during the collection of the medical history.

A further associated risk factor is the treatment with ACE-Inhibitors (ACE-I), that could promote the formation of bradykinin and worsen or even trigger an angioedema.

Several protocols have been proposed for acute treatment and are based on the use of steroids, H1 antagonist, H2 antagonist and adrenaline, but in some cases could be ineffective.

Below we describe a case of angioedema that led to airway emergency unresponsive to traditional therapies and successfully treated with fresh frozen plasma (FFP).

Case report

A 71-year-old woman with a recent medical history of hypertension treated with ramipril and hydrochlorothiazide was admitted to the Emergency Department for the acute onset of global aphasia, right hemiparesis, total gaze palsy, and complete right hemianopia (baseline NIH Stroke Scale 12). The patient had no known allergies to medications. CT angiography and CT perfusion showed a left MCA M1 segment occlusion and a wide ischemic penumbra, respectively. In the absence of contraindication, the patient was declared eligible for combined treatment, starting rt-PA and quickly brought to the Cath Lab for interventional endovascular revascularization. The procedure was per-

formed under general anesthesia (GA) with midazolam, ketamine, and rocuronium for the induction and low doses of propofol and remifentanyl for the maintenance. Complete revascularization (TICI 3) was obtained with two thrombo-aspiration passes. At the end of the procedure, after the removal of the endotracheal tube (ETT), the anesthesiologist noticed lip and tongue swelling on the left side of the mouth.

The patient began to be tachypneic with snoring breath sounds and SpO₂ 89% in room air which raised to 93% with a non-rebreather oxygen mask. Considering the progressively worsening of swelling, hydrocortisone 100 mg, chlorphenamine 30 mg, and both intramuscular and nebulized epinephrine (500 mcg and 1 mg) were administered at first, with no sign of improvement.

Due to the deterioration of neurological status and the signs of impending airway obstruction, the patient was intubated with the aid of a video-laryngoscope in accordance with precautions for patients with suspected COVID-19 infection; the maneuvers resulted in difficult ETT placement due to the worsening swelling of tongue and glottis. Synchronized electrical cardioversion was necessary to treat atrial fibrillation with rapid ventricular response that occurred during intubation and led to hemodynamic instability that promptly resolved just after sinus rhythm was restored. A rhinolaryngoscopy was performed approximately one hour after the ETT placement, which showed a further worsening of the swelling pattern of the glottis and the base of the tongue.

At this point, the diagnosis of bradykinin-mediated angioedema was suggested for two reasons, the first is that remifentanyl and rocuronium could precipitate angioedema by enhancing the release of histamine, but the emergency drugs administered up to that point, although they all had an antihistamine function, had not improved the clinical situation. The second reason is that angioedema of half of the tongue, despite being more frequently contralateral to the ischaemic hemisphere, is associated with rt-PA administration, in particular with concomi-

tant ACE-I assumption and it is widely described in the literature.³

Thus, due to the lack of improvement of angioedema with conventional medical therapy the administration of icatibant was considered, but, as the drug was not readily available, it was decided to administer fresh frozen plasma (FFP) as rescue treatment in order to restore kininase II levels.

The patient showed rapid improvement of tongue edema shortly after starting FFP infusion (600 mL).

A cuff-leak test was performed after 12 hours from ICU admission and showed persistent airway obstruction. Serum trypsinase levels were normal as expected.

A brain CT after 36 hours showed a small ischemic lesion in the Rolandic Area, concomitant white matter lesions in the F3 area, and no evidence of intracranial hemorrhage. The patient was extubated 36 hours later once the angioedema had completely resolved and the second cuff-leak test was negative.

Accurate monitoring of coagulation was carried out during the whole ICU stay and in the following days. There was no need for a supply of fibrinogen.

Considering that the patient was a foreigner and lived alone in Bologna, during the first few days we were able to communicate indirectly with her son through a third person, but due to the significant language barrier, it was not possible to investigate whether the patient herself or a close relative suffered this condition before.

To our knowledge, the patient was not screened for C1-esterase deficiency.

She was transferred from ICU to Stroke Unit on day 3 and then discharged a week later without sequelae.

Discussion

This case describes the management of angioedema following rt-PA infusion and requiring emergency intubation. Angioedema associated with rt-PA administration is a relatively infrequent event, ranging from 1% to 5% of incidence, but can have very serious consequences. The most important risk factor is ACE-I⁴ use and the underlying pathophysiology is of great relevance to understand the treatment options. ACE-I inhibits kininase II, one of three zinc metalloproteinases that metabolize bradykinin, thus increasing plasma levels of this kinin-family member. Indeed, patients assuming ACE-I may show higher serum levels of bradykinin.

Plus rt-PA cleaves plasminogen into plasmin which turns kininogen into bradykinin.¹ The pathway is represented in Figure 1.

Bradykinin is a powerful vasodilator and increases vascular permeability, allowing fluid to move into interstitial tissues.

The patient may also have a concomitant and unrecognized C1-esterase deficiency causing a condition called hereditary angioedema; C1-esterase usually limits bradykinin production by inhibiting kallikrein and factor XIIa, so those patients present recurrent episodes of angioedema. In this case report, this option cannot be ruled out with certainty.

The rationale for the use of FFP is to restore kininase II to increase the degradation of excessive bradykinin.

A further option is icatibant, which acts as a bradykinin inhibitor by blocking the binding to the bradykinin B2 receptor. The use of this drug is suggested by AHA/ASA guidelines, but it is quite expensive and not readily available in every hospital.

Tranexamic acid could play a role by reducing plasmin production, but – in this case – its use was avoided due to the risk of worsening intracranial thrombosis.

The use of FFP for ACE-I induced angioedema has already been described,⁵ but there is still limited experience on this strategy and no validated algorithms; moreover, there are numerous case reports on the use of FFP to treat angioedema, but none of them is associated with rt-PA infusion for concomitant AIS. Probably, the main reason is the concern that FFP may worsen intracranial thrombosis, although there is no evidence of this effect and thus this treatment, especially if justified by an emergency situation, can be considered safe.

Patients presenting to the Emergency Department for AIS may have potential risks of airway obstruction due to problems related to brain injury itself and sedation during the angiographic procedure; angioedema may further precipitate this condition and lead to emergency management of a difficult airway. It is of paramount importance that the anesthesiologist who has to manage this type of patient is aware of the risk of angioedema in patients undergoing thrombolysis, especially when assuming ACE-I.

In case of emergency, the prompt recognition of the problem is also fundamental to the initial treatment, whose timeliness can be translated into a faster resolution of the symptoms and, therefore, a shorter duration of hospitalization.

It may happen that the conventional therapy suggested by the guidelines may not be readily available or ineffective, so FFP administration may play a role to restore kininase II levels as already described by some authors. FFP is less expensive than icatibant and usually readily available, even in small hospitals, where rt-PA infusion is initiated while arranging for patient transfer to the stroke center.

To our knowledge, this is the first case of angioedema associated with rt-PA infusion successfully treated with FFP; although the patient was discharged without neurological sequelae, further studies on the use of FFP for the management of angioedema in this type of patient are advisable.

Conflicts of interest

The authors declare no conflicts of interest.

References

1. Hurford R, Rezvani S, Kreimei M, et al. Incidence, predictors and clinical characteristics of orolingual angio-oedema complicating thrombolysis with tissue plasminogen activator for ischaemic stroke. *J Neurol Neurosurg Psychiatry*. 2015;86:520–3.
2. Powers WJ, Rabinstein AA, Ackerson T, Adeoye OM, Bambakidis NC, Becker K, et al. Guidelines for the early management of patients with acute ischemic stroke: a guideline for healthcare professionals from the american heart association/american stroke association. *Stroke*. 2018;49:46–110.

3. Hill MD, Lye T, Moss H, et al. Hemi-orolingual angioedema and ACE inhibition after alteplase treatment of stroke. *Neurology*. 2003;60:1525–7.
4. Kostis WJ, Shetty M, Chowdhury YS, et al. ACE Inhibitor-Induced Angioedema: a Review. *Curr Hypertens Rep*. 2018;20:55.
5. Hassen GW, Kalantari H, Parraga M, et al. Fresh frozen plasma for progressive and refractory angiotensin-converting enzyme inhibitor-induced angioedema. *J Emerg Med*. 2013;44:764–72.