


Multitarget microangiopathy in a young healthy man with COVID-19 disease: A case report

Roda Matilde, Pazzaglia Alberto, Guaraldi Fabio,
Taroni Leonardo, Natalie di Geronimo,
Fresina Michela, Schiavi Costantino

A 41-year-old man presented to the emergency department complaining of decrease of vision in his left eye. Initial examination was consistent with retrobulbar optic neuritis, and an intravenous drip of methylprednisolone was started. On the third day, the fundus examination revealed the appearance of multiple Purtscher-like cotton-wool spots in the posterior pole and nasally to the optic disc, slight retinal whitening around the fovea, and cherry-red spot. The patient reported flu-like symptoms, and he tested positive at PCR (polymerase chain reaction) test for 2019-nCoV (2019 novel coronavirus) infection. Assuming possible 2019-nCoV-related vascular damage, we prescribed low-molecular-weight heparin. The lesions were regressing at follow-up, and we registered a complete visual recovery.

Key words: COVID-19, incomplete CRAO, paracentral acute middle maculopathy, Purtscher's retinopathy, retinal microangiopathy

The 2019 novel coronavirus (2019-nCoV) appeared in the Chinese city of Wuhan at the end of 2019 and precipitously spread worldwide.^[1] The pathogenesis of 2019-nCoV is still debated, but it seems that the 2019-nCoV could induce immune dysfunction, endothelial injury, complement-associated coagulopathy, and systemic microangiopathy.^[2] Some previous reports described a vascular retinal involvement in patients with 2019-nCoV infection.^[3] We aim to expand our knowledge about possible ophthalmologic manifestations of 2019-nCoV, reporting the first case of incomplete central retinal artery occlusion (CRAO) resembling Purtscher-like retinopathy combined with paracentral acute middle maculopathy (PAMM) in a young patient with the 2019-nCoV disease.

Access this article online	
Quick Response Code:	Website: www.ijjo.in
	DOI: 10.4103/ijjo.IJO_1422_21

Unit of Ophthalmology, - IRCCS Policlinico di Sant'Orsola, Department of Experimental, Diagnostic and Specialty Medicine (DIMES) – Alma Mater Studiorum University of Bologna, Italy

Correspondence to: Dr. Roda Matilde, Ophthalmology Unit, S. Orsola-Malpighi University Hospital, Via Pelagio Palagi, 9, 40138 Bologna, Italy. E-mail: matilde.roda@hotmail.com

Received: 26-May-2021

Revision: 13-Jun-2021

Accepted: 12-Jul-2021

Published: 27-Jan-2022

Case Report

A 41-year-old man presented to the ophthalmological emergency complaining decrease of vision in the left eye. The best-corrected visual acuity (BCVA) was 20/20 in the right eye and hand motion in the left eye; a relative afferent pupillary defect and dyschromatopsia were present in his left eye, and fundus examination showed no abnormalities. The visual field (VF) showed a nasal defect in the left eye [Fig. 1a]. Based on clinical findings, we supposed a case of optic neuritis and an intravenous drip of methylprednisolone (1 g/die for 3 days) was started. On the third day, the fundus examination revealed the appearance of multiple Purtscher-like cotton-wool spots in the posterior pole and nasally to the optic disc, slight retinal whitening around the fovea, and cherry-red spot [Fig. 2a]. The patient reported flu-like symptoms, and he tested positive at PCR (polymerase chain reaction) test for 2019-nCoV infection. Systemic examination revealed no disease; laboratory test, echocardiogram, and color Doppler of the cervical arteries were normal, and screening for thrombophilia showed no abnormal values. Assuming possible 2019-nCoV-related vascular damage, we prescribed low-molecular-weight heparin. Based on the clinical course, we reviewed the diagnosis as atypical CRAO resembling Purtscher-like retinopathy, and we thought of the 2019-nCoV infection as the only probable explanatory etiology. One month later, at the end of his quarantine, the BCVA was 20/100, and the fundus photograph showed the disappearance of most cotton-wool spots and retinal whitening [Fig. 2b]. Fluorescein angiography (FA) showed a delay in choroidal filling in the peripapillary temporal area and an arm-to-retina circulation time of 18 seconds (average value: ≤ 15 seconds) [Fig. 3]. The areas of occlusion of the retinal arterioles corresponded to the areas where the cotton-wool spots were found. Optical coherence tomography showed disorganization of inner retinal layers and loss of temporal nerve fibers and focal areas of hyperreflective change at the level of the inner nuclear layer typical of PAMM [Fig. 4]. The VF showed an improvement of the nasal defect [Fig. 1b and c]. After 3 months, the BCVA is 20/20, but the patient still noted some scotomas mapped out on microperimetry [Fig. 5].

Discussion

Atypical cases of CRAO with partial visual recovery were described as a rare subtype of CRAO likely due to partial occlusion of the central retinal artery.^[4] Fundoscopic changes were similar to the ones described in Purtscher's retinopathy: multiple cotton-wool spots in the posterior pole and surrounding the optic disc, and retinal whitening.^[5] The pathological mechanism for atypical incomplete CRAO and Purtscher-like

This is an open access journal, and articles are distributed under the terms of the Creative Commons Attribution-NonCommercial-ShareAlike 4.0 License, which allows others to remix, tweak, and build upon the work non-commercially, as long as appropriate credit is given and the new creations are licensed under the identical terms.

For reprints contact: WKHLRPMedknow_reprints@wolterskluwer.com

Cite this article as: Matilde R, Alberto P, Fabio G, Leonardo T, di Geronimo N, Michela F, *et al.* Multitarget microangiopathy in a young healthy man with COVID-19 disease: A case report. Indian J Ophthalmol 2022;70:673-5.

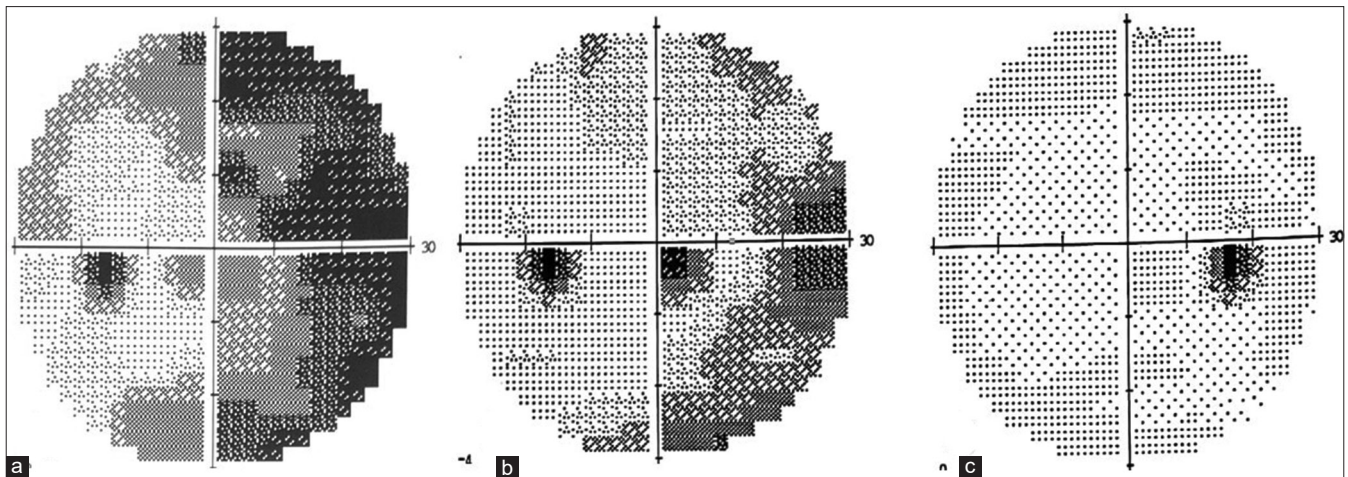


Figure 1: The visual field showed a gradual improvement of nasal defect (a) at 1-day, (b) at 1-month, and (c) at 3-month after the visual loss

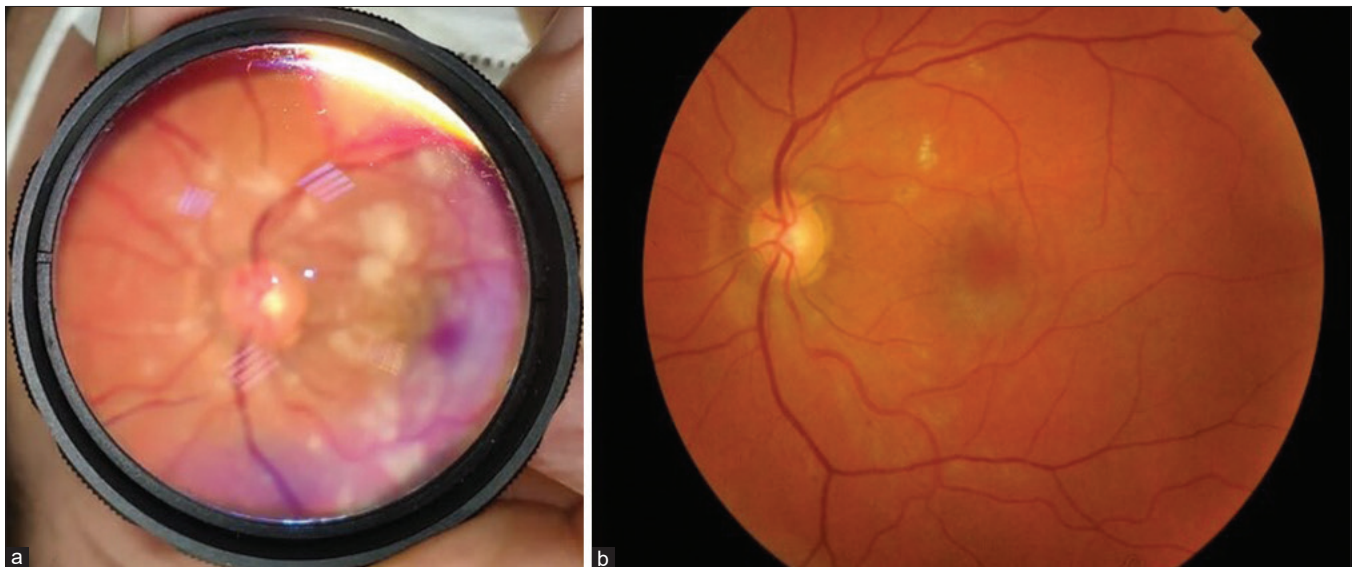

Figure 2: Color fundus photograph (a) 3 days after the visual decrease shows Purtscher-like cotton-wool spots in the posterior pole and surrounding the optic disc, cherry-red spot, retinal whitening, and hyperemic optic disc; (b) 1 month later shows the disappearance of most of cotton-wool spots and retinal whitening

retinopathy remains unknown. However, they are both characterized by the occlusion of precapillary arterioles and microvascular infarct at the retinal nerve fiber layer level, forming cotton-wool spots, usually due to microembolization, disseminated intravascular coagulopathy, or complement activation. Gass *et al.*^[5] suggested the Purtscher's retinopathy as a subtype of CRAO. We described a case of a young patient who presented with fundus alterations similar to Purtscher-like retinopathy, without any traumatic injury or other systemic diseases associated with Purtscher's retinopathy, and without fulfilling three out of the five criteria necessary for the diagnosis of Purtscher's retinopathy (Purtscher flecken, retinal hemorrhages, cotton-wool spots, probable explanatory etiology, and complementary investigation compatible with diagnosis).^[6] Moreover, the fundus examination revealed a cherry-red spot (typical of CRAO), and FA showed a filling defect of the choroid circulation that has not been reported in eyes with Purtscher's retinopathy. Available evidence

demonstrates that the 2019-nCoV infection induces immune dysfunction, widespread endothelial injury, and systemic microangiopathy.^[2] Moreover, a critical role could be played by leukoembolization and complement activation.^[7] In particular, the cotton-wool spots and PAMM lesions are a sign of retinal microangiopathy and endothelium dysfunction likely associated with a direct viral effect and the complement cascade's activation. The cotton-wool spots are typical of an inner retinal infarction due to superficial capillary plexus damage; instead, PAMM lesions are due to infarction of the middle retinal layer caused by impaired perfusion of the deep vascular complex or the deep retinal capillary plexus.^[8] The improvement of VF defects reflected the mildly impaired retinal perfusion, and it is described in incomplete CRAO.^[9] The intravenous steroids probably reduced the complement cascade activation and improved the retina ischemic condition,^[2] and low-molecular-weight heparin prevented other thromboembolic events and mitigate cytokine storm, too.^[10]

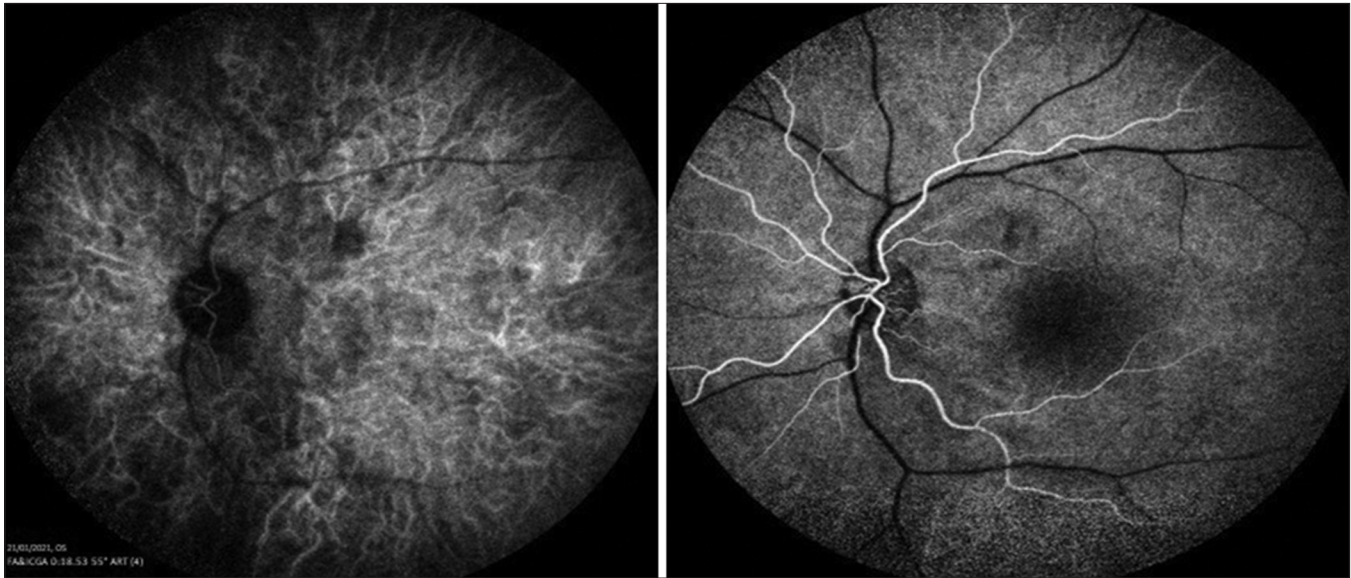


Figure 3: Fluorescein angiography showed a delay in choroidal filling in the peripapillary temporal area, and an arm-to-retina circulation time of 18 seconds (average value: ≤ 15 seconds)

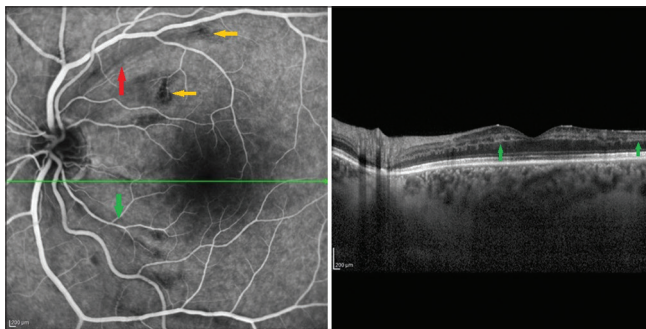


Figure 4: Optical coherence tomography at 1-month follow-up shows disorganization of inner retinal layers, loss of temporal nerve fibers (red narrows), focal areas of hyperreflective change in the inner and outer plexiform layers suggesting a paracentral acute middle maculopathy (green narrows), and focal areas of hyporeflective corresponded areas to the areas where the cotton-wool spots were found (yellow narrows)

Conclusion

To our knowledge, there is no other reported case of 2019-nCoV infection manifesting as incomplete CRAO resembling Purtscher-like retinopathy combined with PAMM. We support the hypothesis by Gass *et al.*^[5] that incomplete CRAO and Purtscher's retinopathy could share the pathogenetic mechanism and could have a better visual prognosis than complete CRAO. We registered a visual recovery of two Snellen lines in a month and complete visual recovery in 3 months with the persistence of some scotomas mapped on microperimetry.

Declaration of patient consent

The authors certify that they have obtained all appropriate patient consent forms. In the form the patient(s) has/have given his/her/their consent for his/her/their images and other clinical information to be reported in the journal. The patients understand that their names and initials will not be published and due efforts will be made to conceal their identity, but anonymity cannot be guaranteed.

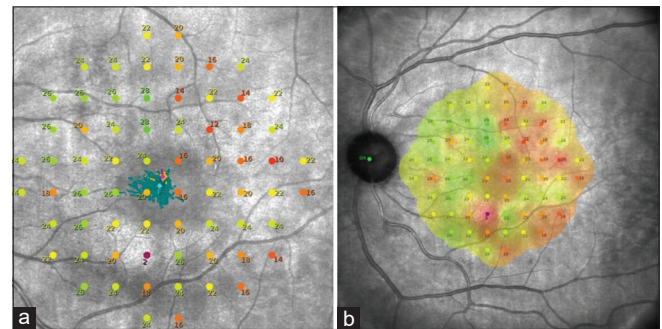


Figure 5: (a) sensitivity of LE; and (b) sensitivity and fundus image obtained with SLO

Financial support and sponsorship

Nil.

Conflicts of interest

There are no conflicts of interest.

References

1. Pellegrini M, Roda M, Lupardi E, Di Geronimo N, Giannaccare G, Schiavi C. The impact of COVID-19 pandemic on ophthalmological emergency department visits. *Acta Ophthalmol* 2020;98:e1058-9.
2. Perico L, Benigni A, Casiraghi F, Ng LFP, Renia L, Remuzzi G. Immunity, endothelial injury and complement-induced coagulopathy in COVID-19. *Nat Rev Nephrol* 2021;17:46-64.
3. Yahalomi T, Pikkil J, Arnon R, Pessach Y. Central retinal vein occlusion in a young healthy COVID-19 patient: A case report. *Am J Ophthalmol Case Rep* 2020;20:100992.
4. Varma DD, Cugati S, Lee AW, Chen CS. A review of central retinal artery occlusion: Clinical presentation and management. *Eye* 2013;27:688-97.
5. Kurimoto T, Okamoto N, Oku H, Kanbara Y, Etomi T, Tonari M, *et al.* Central retinal artery occlusion resembling Purtscher-like retinopathy. *Clin Ophthalmol* 2011;5:1083-8.
6. Agrawal A, McKibbin M. Purtscher's retinopathy: Epidemiology,

- clinical features and outcome. *Br J Ophthalmol* 2007;91:1456-9.
7. Lima LH, Vianello S, Pimentel S, Costa de Andrade G, Zett C, *et al.* Dengue fever presenting as Purtscher-like retinopathy. *Ocul Immunol Inflamm* 2018;26:660-5.
 8. Scharf J, Freund KB, Sadda SV, Sarraf D. Paracentral acute middle maculopathy and the organization of the retinal capillary plexuses. *Prog Retin Eye Res* 2020;81:100884.
 9. Kim HM, Park YJ, Park KH, Woo SJ. Visual field defects and changes in central retinal artery occlusion. *PLoS One* 2019;14:e0209118.
 10. Shi C, Wang C, Wang H, Yang C, Cai F, Zeng F, *et al.* The potential of low molecular weight heparin to mitigate cytokine storm in severe COVID-19 patients: A retrospective cohort study. *Clin Transl Sci* 2020;13:1087-95.
-