



Skeletal trauma in an Iron age context: new insight into the Etruscan population from Spina (Ferrara, Italy)

Vanessa S. Manzon¹ · Natascia Rinaldo¹ · Emanuela Gualdi-Russo¹

Received: 21 November 2023 / Accepted: 23 May 2024 / Published online: 4 June 2024
© The Author(s) 2024

Abstract

The analysis of traumatic injuries in human skeletal remains from archaeological contexts offers important challenges for the reconstruction of past populations' behaviors. In this study, a sample of 303 buried skeletons retrieved from the Etruscan necropolis of Spina (Ferrara, Italy) and dated back to the 5th to the 3rd century BC, were macroscopically analyzed for traumatic injuries. The sample consisted of 38% males, 22% females, and 40% undetermined individuals. Subadults represented 25% of the entire sample. The aim of this study was to collect and describe new data on antemortem and perimortem injuries in the Spina Etruscans, bringing a new perspective to the understanding of social behaviors in this population. In the sample of Etruscans examined 16 individuals showed evidence of one injury and two individuals of two injuries. The analysis revealed 18 cases of antemortem trauma and 2 cases of perimortem trauma. No traumatic injuries were detected among subadults, while men and women presented different types of traumas: women were more prone to stress fractures involving the spine, whereas men were affected by antemortem and perimortem inflicted traumas, suggesting a division of labor and a major exposition of the latter to interpersonal violence. The reduced presence of sharp force traumas found exclusively in males (3 cases, 1.3% of the adult sample) is basically consistent with archaeological and historical data that described this site as a free port without an explicit history of violence.

Keywords Antemortem trauma · Perimortem trauma · Interpersonal violence · Stress fractures · Paleopathology · Etruscans

Introduction

Trauma is one of the most common pathological conditions found in human skeletal remains (Roberts and Manchester 1995; Paine et al. 2007; Wedel and Galloway 2014). The term trauma refers to any wound or injury to the body caused by the application of an external force; it can involve bones (fracture), joints (dislocation), or soft tissues. In the last case, only traumas involving also periosteum, ligaments, and tendons that leave marks on the skeleton could be identifiable. From a causative point of view, trauma can be distinguished as accidental (deriving from hazards of day-to-day life), inflicted (linked to interpersonal violence and aggression), or caused by other pathological conditions

(e.g. osteoporosis) and senescence, or derived from repeated mechanical stress (Roberts and Manchester 1995; Lovell 1997; Ortner 2003; Rubini and Zaio 2011). Moreover, it is important to distinguish between antemortem and perimortem traumas, as they have different socio-cultural implications. Antemortem traumas occur during the life of an individual as shown by the presence of bone remodeling and healing (callus, osteoperiostitis, etc.) (Sauer 1998; Cohen et al. 2014; Scianò et al. 2020). These traumas did not result in immediate death and can inform on the level of social support and familial care, the presence and availability of treatment, the eventual occurrence of complications (Roberts and Manchester 1995; Judd and Redfern 2011; Mant et al. 2021; De Luca et al. 2023). Perimortem traumas occur at or near the moment of death and are characterized by the absence of evidence of healing and fracture margins having characteristics associated with breaks on fresh bone. This pattern also allows to distinguish perimortem from postmortem traumas occurring on dry bones (Jordana et al. 2013; Ribeiro et al. 2020; Smith 2021). Different types of

✉ Natascia Rinaldo
natascia.rinaldo@unife.it

¹ Department of Neuroscience and Rehabilitation, University of Ferrara, Corso Ercole I D'Este, 32, Ferrara 44121, Italy

behavior lead to characteristic patterns of skeletal injuries, and the analysis of these patterns in ancient populations can therefore inform on the historical, environmental, and cultural factors associated with these behaviors (Tremblay and Reedy 2020; Mant et al. 2021; Osterholtz et al. 2023). In particular, the study of traumatic injuries in human skeletal remains from archaeological contexts can thus inform about many aspects of past societies: their environment and living conditions, general health status, economy and subsistence base, level of physical and occupational activity, social organization and occupational roles, in addition to the eventual presence of interpersonal violence and aggressiveness (Judd and Redfern 2011; Martin and Harrod 2012; Redfern et al. 2017; Pasini et al. 2019). Indeed, injuries may have been caused by accidental agents related to lifestyle and work activity, or there may be intentional injuries caused by assault, fighting, execution, sacrifice, and surgery (Owens 2007). In particular, the investigation on inflicted traumas offers important challenges in the reconstruction of some aspects of past societies, as it often allows recognizing the weapons used and the manner of their employment, becoming thus a direct source for assessing violence and warfare in the past, often not obtainable by other means (Owens 2007).

In this study, we addressed the issue of skeletal trauma in an Etruscan population analyzing their occurrence with age, sex, and anatomical area affected. Despite the limitations resulting from the poor state of preservation of Etruscan remains, we are confident of making an original contribution to the knowledge of this population, reaching to highlight, through the analysis of skeletal traumas, aspects related to daily life and any violent episodes that occurred during the Iron Age in the Etruria Padana.

The site of Spina

The site of Spina was a flourishing commercial port, founded at the beginning of the 6th century BC by Etruscans at the Po River's delta to establish commercial trades with Greeks in the Upper Adriatic, and in use till the end of the 3rd century BC, when hydrological changes and political upheavals made it to lose its main function (Patitucci Uggeri and Uggeri 1993; Torelli 1993). The site is located on the Italian coast of the Upper Adriatic at the Po River's delta (Fig. 1). The Spina necropolis was discovered at the beginning of the last century and excavated in several phases from the 1920s to 1960s, returning to date more than 4000 graves, with a dual ritual involving both incinerations and inhumations. Most of the studies were focused on the analysis of extraordinary grave goods composed of fine Greek pottery, golden jewelry, and exotic ornaments such as glass paste and amber; human skeletal remains have only recently been the focus of some anthropological studies (Masotti et

al. 2013, 2020; Manzon et al. 2014; Manzon and Gualdi-Russo 2016; Gualdi-Russo et al. 2017, 2020; Manzon et al. 2017). The profile of the society that emerges from the study of the grave goods is that of a rich business class that pretended to represent itself in the afterlife as part of the Greek aristocracy: most graves are equipped with the so-called "symposium set", representing the last symposium that the deceased aristocrat offered to his/her peers (Malnati 1993; Torelli 1993). Still, human skeletal remains offer direct biological evidence of some aspects of this population's life and activities, not necessarily coinciding with those depicted by grave goods.

Materials and methods

In this study, human skeletal remains from the Etruscan necropolis of Spina (Ferrara, Italy) were anthropologically analyzed. The sample consists of 303 human skeletons unearthed during the 1920 and 1960 archaeological excavation campaigns of Spina necropolis. The preservation of skeletal material is quite poor because of the marshy habitat of the site and the poor archaeological methodologies at the time of excavation. Sex and age at death were determined using classical anthropological methods. Specifically, sex was determined using a visual assessment of sexually dimorphic traits of the skull (nuchal crest, mastoid process, supra-orbital margin, glabella, mental eminence), mandible, and pelvis (pubic bone shape, shape of the subpubic concavity, greater sciatic notch morphology, preauricular sulcus, medial aspect of the ischio-pubic ramus, ventral arc) (Acasadi and Nemeskeri 1974; Ferembach et al. 1980; Buikstra, J. E. Ubelaker 1994; Walker 2008) through a decision table approach (Ferembach, 1980). Moreover, a metric assessment using measurements of the post-cranial skeleton (Demoulin 1972; Krogman and İşcan 1986; MacLaughlin and Oldale 1992; Bass 1995; Cattaneo and Grandi 2004; Rühli et al. 2006; Gualdi-Russo 2007), and of the pelvis (ischium-pubic index; Schultz 1930). Age at death was estimated using standard anthropological methods taking into account ectocranial suture obliteration, dental attrition, and grade of remodeling of the pubic symphysis, the auricular surface of the ilium, and medial end of the 4th rib for adults (Ferembach et al. 1980; Lovejoy 1985; Meindl and Lovejoy 1985; Ubelaker 1989; İşcan et al., 1984, Brooks and Suchey 1990; Ríos and Cardoso 2009) For age at death estimation of subadults we considered the development and fusion of primary and secondary ossification centers, long bone lengths, and tooth development and eruption (Schaefer et al. 2009; Ubelaker 1989).

All complete or fragmented bones were examined. Assessment of traumatic injuries involved their identification and

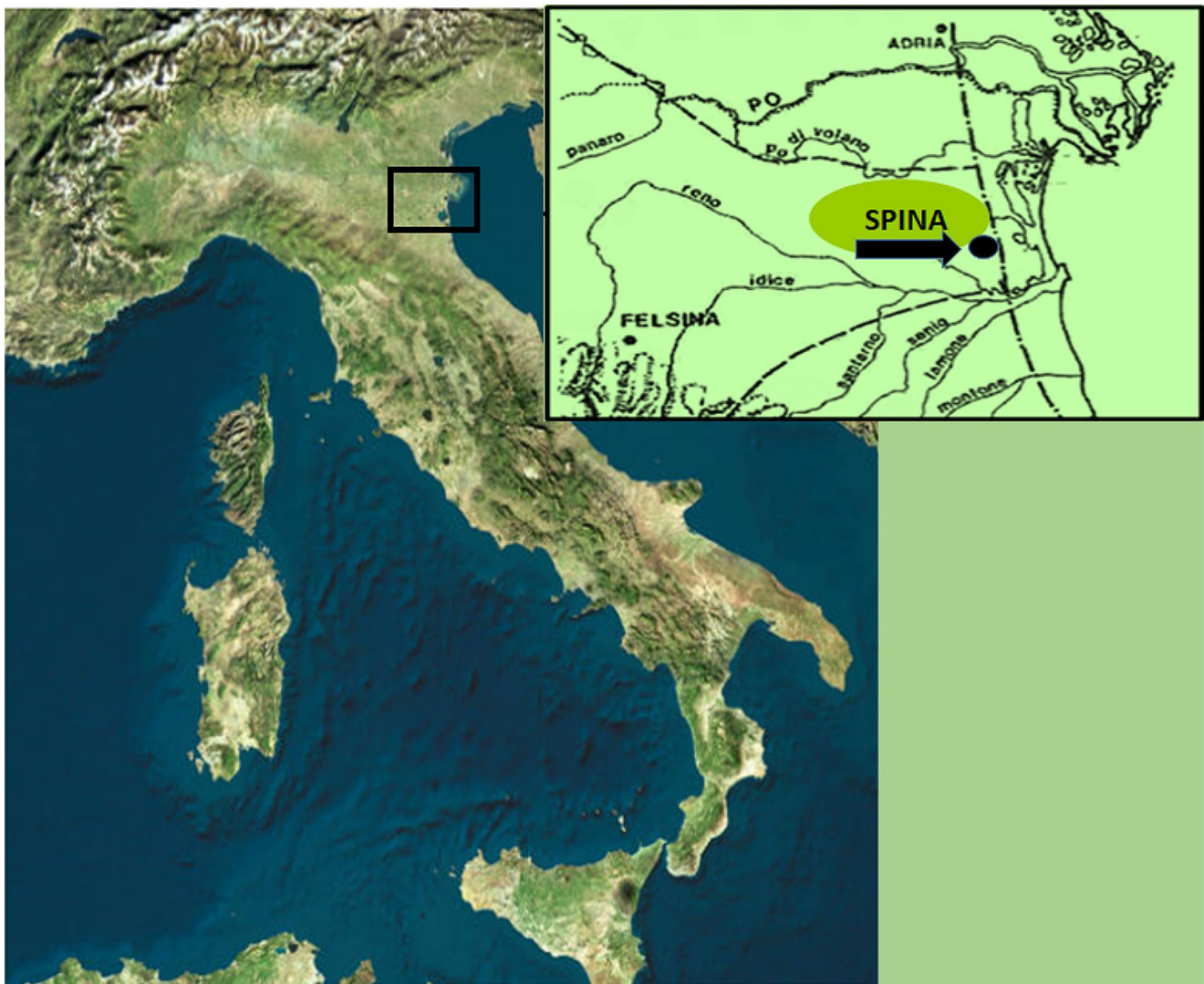

Fig. 1 Geographical localization of the site of Spina (Ferrara, Italy). The dashed line in the drawing at the top right indicates the coastline of Etruria Padana during the 5th century BC)

localization, defining the timing (antemortem, perimortem) and type of lesion (inflicted, accidental, degenerative, etc.) (Lovell 1997; Sauer 1998; Scianò et al. 2020). Postmortem traumas were excluded from the analysis. Each trauma was observed macroscopically under powerful illumination and through a magnifying glass. We distinguished between perimortem and postmortem trauma by color, fracture type, and edge shape according to Kimmerle & Baraybar (Kimmerle and Baraybar 2008), and several forensic studies (among others: (Sauer 1984, 1998; Pasini et al. 2018; Ribeiro et al. 2020; Scianò et al. 2020, 2021)). We performed fracture diagnoses based on the diagnostic elements established according to anatomopathological criteria (Aufderheide and Rodríguez-Martín; Roberts and Manchester 1995; Lovell 1997; Sauer 1998; Ortner 2003; Kremer et al. 2008; Lewis 2008; Siegel and Saukko 2012). For all antemortem

and perimortem trauma, the type and mechanism of injury were evaluated, and the proximate cause and dynamic of traumatic lesions were discussed to identify the ultimate cause of injury strictly linked to behavior (Lovell 1997). The state of preservation of the pathological individuals was evaluated and reported through the Anatomical Preservation Index (API) and the Bone Representation Index (BRI) (Bello et al. 2006).

Statistical analysis

Relative frequencies of the detected traumas were finally calculated on the total number of individuals for the total sample and in each sex group. The relative frequencies of antemortem and perimortem traumas were calculated based on the total number of individuals with trauma and divided

by sex. Frequencies of traumatic myositis ossificans (TMO) are calculated on skeletons having at least one bone of one limb preserved; frequencies of osteocondritis dissecans (OD) are calculated on skeletons having at least one major joint surface preserved.

In order to analyze the prevalence trend with age of the detected types of trauma, we grouped the subjects into the three following age categories according to Buikstra and Ubelaker's classification (Buikstra and Ubelaker 1994): subadults (<20 years old); young adults (20–35 years); middle/old adults (>35 years).

Statistical comparisons between adult age classes were also made within each sex, to test any sex-specific pathological trend with aging.

The differences in the frequencies of pathologies among age groups and between sexes were assessed with the chi-square test or Fisher's exact test, when appropriate.

The level of significance was set at $p < 0.05$.

The statistical analyses were performed using MedCalc Statistical Software version 14.8.1 (MedCalc Software bvba, Ostend, Belgium).

Results

Biological profiles

The distribution of the analyzed sample by sex and age is reported in Table 1.

Our analysis revealed that the majority of individuals examined were aged >35 years and of male sex. In particular, male individuals were almost twice as numerous as female individuals, although it is necessary to point out the high number of individuals for whom sex could not be evaluated, especially in subadults. The state of preservation was in general poor, with a BRI value of less than 50% in 77.8% of the pathological individuals (Table 1 SM).

Traumatic lesions

Table 2 presents the frequencies of the traumatic lesions by age and sex. Of the 303 individuals, 18 had at least one

lesion, thus indicating a low trauma prevalence (8.0%) in this sample. No evidence of trauma was found in subadults (age <20 years), therefore they are not included in the table. As regards sex differences, 6.1% of females and 12.8% of males presented at least one injury (first part of Table 2), but the comparison was not statistically significant. The majority of trauma was found in middle and old adults in both males and females, but the difference is not significant. Rates for each detected type of trauma according to timing were reported in Table 2 second part (*antemortem* and *perimortem* trauma). Soft-tissue traumas, such as TMO-OD, were considered antemortem traumas.

Out of 20 cases of trauma, 18 were ante-mortem (90.0%), and 2 were perimortem (18.2%). In particular, evidence of antemortem traumas was found in 8.0% of the adult sample, with a non-significant difference between females and males. Among the antemortem traumas, we found five cases of stress fractures at the spine, involving 1 male and 4 females, and three cases of antemortem inflicted trauma, involving exclusively males. The other antemortem trauma were five cases of TMO and five cases of OD. The five cases of TMO involved exclusively adult males (5.1% of the total male adult sample). Instead, the five cases of OD involved one female (2.2% of the total female adult sample with at least one major joint surface preserved) and four males (4.6% of the total male adult sample). Evidence of perimortem traumas was found in two adult males (1.8% of total adult males; 0.9% of the total adult sample). No cases of perimortem trauma were found in females. The recorded traumas are listed and described below according to the timing of injury (antemortem or perimortem traumas) and the mechanism of injury (accidental trauma, repeated stress, inflicted trauma, etc.) (Fig. 2).

Ante-mortem trauma and related mechanisms

The eight antemortem traumas found in the sample included 5 cases of spinal fractures (1 male and 4 female individuals), 2 cases of blunt-force trauma to the skull (both males), and 1 case of sharp force trauma on a right tibia (male). Of the 5 cases of spinal fractures detected, 2 involved cervical vertebrae, and 3 the lumbar spine (Fig. 3). The cervical fractures

Table 1 Sex and age distribution in the Etruscan sample

Age	Males		Females		ND sex		TOT.	
	N	%	N	%	N	%	N	%
<20	6	7.7	1	1.3	71	91.0	78	25.7
20–35	29	47.5	25	41.0	7	11.5	61	20.1
>35	54	62.7	28	32.5	4	4.7	86	28.4
ND adults	26	33.3	13	16.7	39	50.0	78	25.7
Tot. adults ¹	109	48.4	66	29.3	50	22.2	225	74.3
Total²	115	38.0	67	22.1	121	39.9	303	100

¹Tot. adults: total adult sample ("20–35" + ">35" years + Unknown age adults); ²Total: total sample (sub-adults + adults). ND: not determinable

Table 2 Frequencies of individuals with trauma from the Euruscan sample by sex and age

Trauma	Age class	Males		Females		P value ^a	ND sex		Tot					
		Tot	n	%	Tot		n	%	Tot	n	%			
General pattern	20–35	29	4	13.8	25	2	8.0	0	0	0	0	61	6	9.8
	>35	54	7	13.0	28	2	7.1	4	0	0	0	86	9	10.5
	ND adults	26	3	11.5	13	0	0	0	0	0	0	78	3	3.8
	Tot. adults	109	14	12.8	66	4	6.1	50	0	0	0	225	18	8.0
Trauma timing	20–35	4	4	100	2	2	100	0	-	-	-	6	6	100
	>35	7	6	75.0	2	2	100	0	-	-	-	9	9	100
	ND adults	3	3	100	0	-	-	0	-	-	-	3	0	0
	Tot. adults	14	13	92.9	4	4	100	0	-	-	-	18	15	83.0
peri-mortem	20–35	4	0	0	2	0	0	0	0	0	0	6	0	0
	>35	7	2	25.0	2	0	0	0	0	0	0	9	2	22.2
	ND adults	3	0	0	0	-	-	0	-	-	-	3	0	0
	Tot. adults	14	2	14.3	4	0	0	0	-	-	-	18	2	11.0

Note Tot: number of assessable individuals; n: number of affected individuals; dash: feature undetectable. ND: not determinable; ^aComparison between males and females performed through Fisher's exact test

affected 2 female individuals: the former, found in a 40–49 years old female (individual 11 A), had a complete vertical fracture at the middle of the left articular process of C2, with remodeling and osteoarthritis on the residual surface and on the odontoid process; the latter, found in a 25–30 years old female (individual 1287 VT), had a complete fracture at the left pedicle of C4, completely remodeled with the neo-formation of an accessory articular surface on it. In the same case, two Schmorl nodes and osteoarthritis on the upper endplate of the vertebral body and the right superior articular process were observed (Fig. 3C). Both lesions are cervical spondylolysis and are interpretable as fatigue fractures at the cervical column (Levy 1968; Ortner 2003; Puisto et al. 2008). The found evidence of lumbar injuries involved a male individual of >50 years of age (individual 94D), showing an incomplete vertical fracture on the right superior articular process of L3 (Fig. 3B); the lesion has healed, as shown by the callus on the posterior (non-articular) aspect of the facet, with a slight indentation of the broken edge of the articular process; the body of L3 was fractured postmortem, though evidence of a Schmorl node was appreciable on the residual part of the upper endplate. No other lumbar vertebra of Individual 94D was present but a lower thoracic vertebra and C7 were preserved, showing imprints of the tip of inferior articular processes of the missing C6 on the arch at *pars interarticularis*. These features, and the evidence of osteoarthritis on articular processes of the preserved vertebrae, suggest the presence of compressive forces acting on the spine (Yang and King 1984). The other two cases of lumbar fractures were found in 2 female individuals, one 20–35 years of age and the other 40–44 years of age, showing spondylolysis at L5. The former (individual 33 A) had complete asymmetrical spondylolysis at the right lamina of L5 (Fig. 3A). The defect consists of a complete separation between the vertebral body and the corresponding arch of the vertebra due to a fracture occurring at the *pars interarticularis* (Cunha and Pinheiro 2016). A functional remodeling involving also L4 was present: both vertebrae L5 and L4 had deviated spinous processes toward the left (laterolisthesis) and hypertrophy on the left side of the arch. This type of modification is a consequence of adaptation to reduce mechanical stress on the fractured side (the right), with the following hypertrophic growth of the opposite one (the left), now bearing the brunt of stresses generated in the arch after the unilateral separation, and is reported to be typical of complete asymmetrical spondylolisthesis (Merbs 1983; Jinkins 2004). This evidence and the fact that the broken edges of L5 showed considerable remodeling indicate that the break was long-standing (Ortner 2003). The latter female individual (1363 VT) with symmetrical spondylolysis, followed by spondylolisthesis at vertebra L5, was previously described (Manzon et al. 2014).

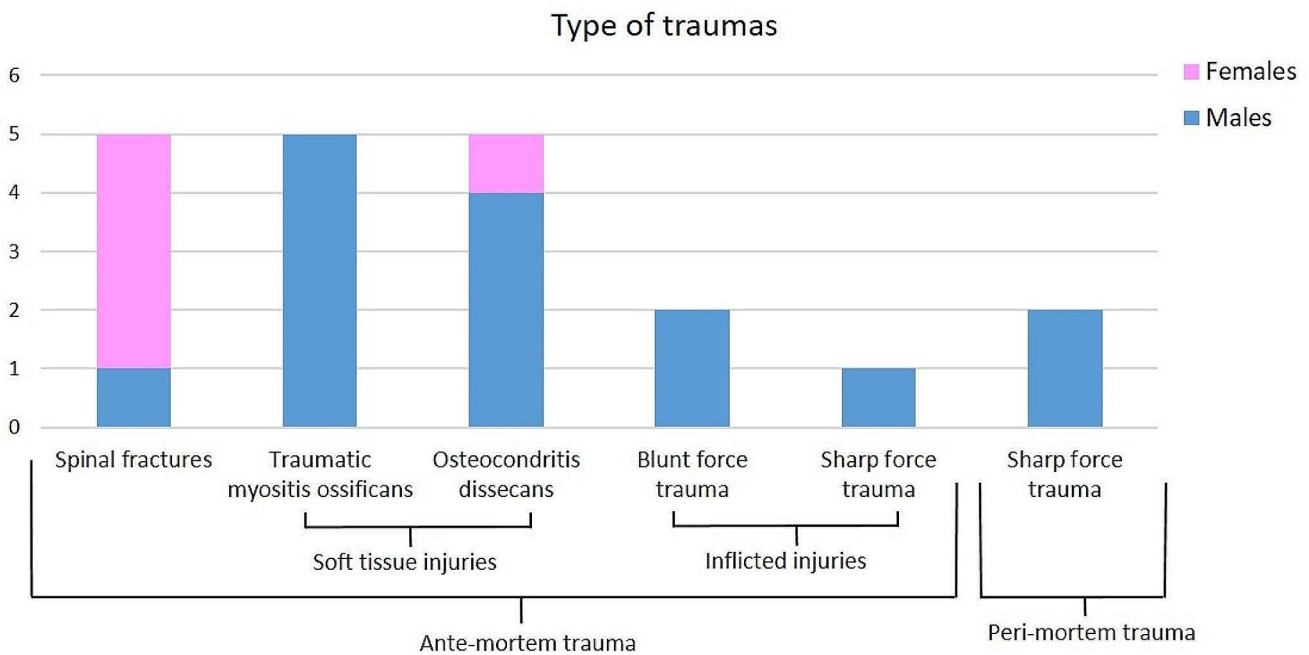


Fig. 2 histograms representing the trauma divided by type, timing, and sex

Regarding the 3 putative cases of antemortem inflicted trauma, 2 were depressed fractures on the skull (blunt force trauma) (Fig. 4). One of the observed blunt force traumas involved a 35–50 years old male (individual 1264a VT) showing an oval-shaped depression 14×16 mm wide 1–2 mm deep involving the left parietal bone with minor involvement of the right parietal in the obliterated sagittal suture. The fracture probably involved only the external cortex and the diploe, as no evidence of callus was present on the inner vault, and had completely healed without evidence of post-traumatic septic complication (Fig. 4A). The location and characteristics of the injury suggest that its cause was a blow from above (Roberts and Manchester 1995; Kremer et al. 2008; Kremer et al., 2009). The other case was 45–50 years-old male (92D), presenting a depression on the left parietal, near the obelion, 1 cm left to the level S3 line of the sagittal suture (Fig. 4B); also, in this case, the fracture probably did not penetrate the diploe and healed without any major complications, as suggested by the absence of traces of inflammatory processes (Aufderheide and Rodríguez-Martín; Orschiéd et al. 2003). The same individual was affected also by Legg-Calvé-Perthes disease on the left femoral head (Manzon et al. 2017).

An antemortem sharp force trauma was found on the anterior border of the right tibia of a 20–35 years man (1304a VT), showing a scarring cortical hollow 12 mm length and 1 mm width accompanied by a diffuse osteo-periostitis on the surrounding diaphysis of the bone, probably resulting from the periosteum reaction to injury (Fig. 4C). The characteristics of the lesion with a smooth V-shaped profile

suggest that the weapon used was a knife rather than a sword, as the last weapon usually leaves a mark displaying one smooth wall and one straighter and roughened (Lewis 2008).

Perimortem trauma and related mechanisms

The two perimortem inflicted traumas found in the sample are both sharp-force trauma, involving in one case the 2nd and 3rd lumbar vertebra of a middle adult male, and the other the right femur of a > 50 years-old male. The former (individual 135D) was probably the result of a stabbing wound inflicted to the abdomen probably by a dagger that completely pierced it reaching the spine. The absence of bone remodeling suggests that this trauma was probably the cause of death of the individual. More on this case has been reported previously (Gualdi-Russo et al. 2020) (Fig. 5B). The latter sharp wound involved the posteromedial aspect of the diaphysis of the right femur of an old adult male (individual 116Da), with an oblique direction from above downwards. The cut-mark had a V-shaped Section. 1.4 mm deep maximum and a deep bottom and jagged edges due to splintering of the cortical bone surface during the sliding of the blade (Fig. 5A). The characteristics of the cut marks, with one sharp edge (the upper) and one straighter and roughened due to detachment of bone flakes (the lower) indicate that it was made on the fresh bone and suggest that the weapon used was, also in this case, a sword or a dagger, handled by a right-handed opponent that stabbed the victim from the back in an oblique direction from top right to bottom left




Fig. 3 A: Example of antemortem trauma of the spine in the vertebra L5 in individual 33 A VP. In the left a view of the vertebra from above with the detail of the fracture on the right lamina (white and red arrows) with consequent spondylolisthesis toward the left and hypertrophy of the left side (triangle). in the right a detail of remodeling on the fracture point (white and red arrows) in the vertebra seen from the

backside. C: Case of incomplete vertical fractures in the right superior articular process of the vertebra L3 of the individual 94D (male, old adult). D: Case of ante-mortem trauma in a cervical vertebra (C4) of the individual 1287 VT (25–30 years old female) showing a complete fracture at the left pedicle (red arrows) and two Schmorl nodes on the upper side of the body (white arrows)

toward the inner thigh of the individual (Lewis 2008; Siegel and Saukko 2012). Moreover, another cut mark, very close to the other but with a different direction (from proximal to distal direction), leads to the assumption that the weapon was embedded into the thigh and then extracted. Using a knife in close combat is excluded, as this weapon leaves a cut mark having different characteristics (Lewis 2008; Cohen et al. 2014). Done its location on the postero-medial shaft of the femur the *arteria femoralis* may have

been involved, leading to the rapid death of the individual. However, even though no other trauma was found on the skeleton, we cannot exclude that the cause of death should have been another wound, or belt during the same episode of violence, possibly involving some vital organs.



Fig. 4 **A:** Case of blunt force trauma on the skull in a 35-50-year-old male (individual 1264a VT). **B:** Case of blunt force trauma on the left parietal of the skull in a 45-50-year-old male (individual 92 VT). **C:**

Case of sharp trauma on the left tibia, accompanied by reactive osteoperiostitis, in a 20-35-year-old male (individual 1304a VT)

Soft tissue trauma

Soft tissue injuries can be recognized on human skeletal remains from a new bone formation within the damaged soft tissue, as in the case of TMO. This condition was found in 3.5% of the adult sample, in particular 5 adult males (individuals 83 Ab, 90 D, 1256 VT, 1314 VT, 1396 VT). No sub-adult and no woman were affected (Table 2). Two individuals were OA, two indeterminate and one MA. Four out of five TMO were localized in the lower limbs (3 in the femur and one in the right tibia), whereas just in one individual the trauma was found in the right humerus (1256 VT). In almost all cases TMO is associated with periostitis and in one cases also with osteitis (90D).

The other condition recognized in Spina's findings was OD, due to fragmentation and disruption of articular cartilage and possibly the underlying subchondral bone.

This lesion was found on 5 individuals (1 female and 4 males), each at one different joint (Table 3; Fig. 1 SM). In

the case of individual 145Ab, the small sequestrum of bone 2 mm in diameter was still attached to the condyle surface of the left femur. This trauma was present in 3.5% of the adult sample preserving at least one major joint surface of the appendicular skeleton, with a more than twofold rate in males (4.6%) than females (2.2%) (Table 2). Among males, the prevalence was found higher in young adults (8.7%) than older adults (2.2%).

Discussion

This study aimed to analyze the prevalence of trauma in the Etruscan skeletal population of Spina, with particular attention to antemortem and perimortem trauma and type of trauma. In the analyzed sample, no subadult exhibited lesions referring to trauma, whereas a total of 20 adults were affected. Unlike other studies that have shown children's involvement in interpersonal violence (Fibiger 2013; Lewis

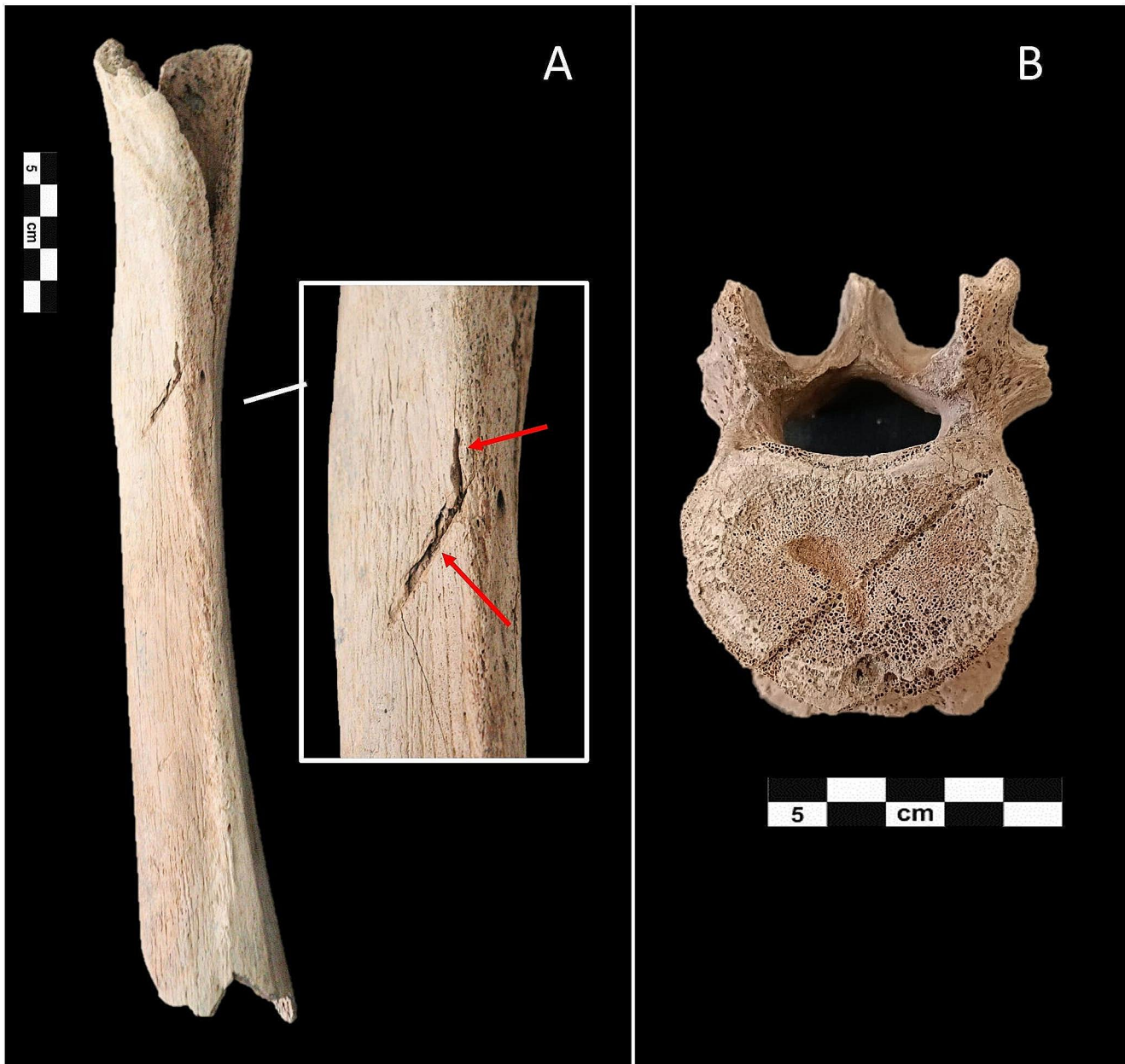


Fig. 5 **A:** Case of perimortem sharp force trauma in the right femur of an old adult male (individual 116 Da), from backward. The trauma involved the posteromedial aspect of the diaphysis. The red arrows

indicate the two cut marks. **B:** Case of a peri-mortem sharp force trauma in vertebra L3 with the evident cut mark in the superior side of the vertebra

Table 3 Individuals affected by Osteocondritis Dissecans (OD) and impaired joints

Ind. ID	Sex	Age	Joint surface
11 A	female	40–50	Right humerus –trochlea
31Aa	male	25–35	Left scapula – glenoid fossa
39 A	male	25–35	Right scapula –glenoid fossa
145 Ab	male	unknown	Left femur – lateral condyle
135 D	male	35–49	Left coxal – acetabulum Right coxal – acetabulum

2014; Osterholtz et al., 2017), we found an absence of traumatism in Spina subadults. This pattern is also confirmed in other studies on ancient populations (Djurić et al. 2006; Roksandic et al. 2006; Owens 2007; Jiménez-Brobeil et al. 2009, 2014), but may also be due to problems of preservation or complete obliteration of injuries by modeling and remodeling associated with normal growth (Ortner 2003). The percentage of trauma in the Etruscan population of Spina did not reach 10% of the population. However, we must consider that the number is probably underestimated

due to poor skeletal preservation. Higher frequencies of traumatic injuries have been reported in cases of violent conflicts (e.g., 30–44% in cranial remains from the late Neolithic in Ukraine)(Madden et al. 2018). The comparison of data from Spina with those from the coeval Etruscan necropolis of Pontecagnano, in Southern Italy, shows that trauma rates seem quite low, suggesting that inhabitants of Spina engaged in behaviors with no particular risk in everyday life. Robb (Robb 2014), analyzing a sample of 56 skeletons from Pontecagnano, found trauma rates, on average, at 16.7% (25.0% among males and 14.2% among females) for the period 7th -5th century BC, and 35.5% (51.9% among males and 6.7% among females), in the period 5th -3rd century BC, thus suggesting an increased number of traumatic lesions through times, especially in males.

In our sample, the detected types of traumas include 5 antemortem stress fractures on the vertebral column, 3 antemortem inflicted traumas (2 blunt traumas on the skull and one sharp force trauma on a tibia), 2 perimortem inflicted traumas due to sharp wounds (one involving the vertebral column and one a right femur). It should be noted that blunt force traumas are very complex to interpret as they are characterized by a large variety of fracture patterns, that often do not reflect the size and shape of the weapon used (usually a cudgel, a mace, a hammer, or a sling stone) (Cohen et al. 2014). Sharp-force trauma, on the other hand, indicates any injury produced by bladed instruments including penetrating wounds (stab or puncture wounds), cut marks or incised wounds, and chop wounds (cleft/notch), which involve both penetration and incision. In this case, the particular patterns of the cut marks allow for understanding the type of weapon and the direction of the trauma (Cohen et al. 2014; Lewis 2008; Strong and Fibiger 2023; Moreno-Ibàñez et al., 2024).

The only type of trauma found among females is a stress-induced fracture on the vertebral column (spondylolysis and spondylolisthesis) involving both the cervical vertebra and lumbar spine. For cervical injuries- especially those involving C1-C4 -, forces caused by the twisting of the neck while the head is immobilized – causing injury at the point of greatest rotational mobility- or pressing down on the head and cervical column can be suggested. These injuries are reported to be typical of people carrying loads on the head, such as grain porters, or as a consequence of compressive impact force on the top of the head (Capasso et al. 1999). On the other hand, spondylolysis in the lumbar spine is considered a consequence of habitual physical stress (Merbs 1983, 2002; Lovell 1997; Earl 2002; Mays 2006a, b; Jiménez-Brobeil et al. 2009; Cunha and Pinheiro 2016; Plomp et al. 2022). The prevalence of the condition among Spina females suggests that in the site women in particular were involved in strenuous occupational activities stressing the spine such as carrying and transporting heavy loads on the

back (causing lumbar stress fractures) or on the head (causing cervical stress fractures) (Merbs 1983, 2002; Earl 2002). The partial fracture at the superior articular process of L3 in a man could be interpreted as evidence of spondylolysis at an initial stage, and then healed (Merbs 2002). Given its location at L3 and its vertical direction, we suggest in fact for this atypical type of fracture the same etiology as for spondylolysis, with repetitive shearing stresses involving the lower spine in the vertical direction, not affecting the case under study the pedicle but the articular process (Mann et al. 1990; Magerl et al. 1994; Mann and Hunt 2013). We cannot however exclude a diagnosis of accidental trauma, for example, a fall from a great high or on the back, an injury caused by a heavy object falling on the bent back, or that the individual was thrown some distance (Magerl et al. 1994). Unfortunately, only L3, C7, and a lower thoracic vertebra are available for this individual, and the body of L3 is fractured postmortem; therefore, it is difficult to reconstruct the mechanism of fracture and the involved forces. However, the characteristics of the superior articular processes of C7, with imprints of the tip of inferior facets of C6 on the arch of C7 at *pars interarticularis*, and the presence of osteoarthritic modification on articular processes and a Schmorl node on the upper endplate of the vertebral body of L3, suggest the presence of compressive forces (Yang and King 1984). On the other hand, superior articular process degeneration and fracture can occur as a consequence of intervertebral disk collapse and collision of the apex of the superior articular facets and the undersurface of the *pars interarticularis* (Jenkins 2004).

In the analyzed sample, males were conversely more affected by inflicted traumas, both antemortem and perimortem, suggesting that they were involved in episodes of violence. The recorded antemortem inflicted injuries consist of 2 blunt force traumas on the skull and one sharp force trauma on the right tibia. Even if for the formers we cannot exclude an accidental etiology, the characteristics and location of the lesions make this unlikely: the presence of a blunt force trauma on the left side of the skulls is reported in fact to be typical of inflicted blows by a right-handed opponent in face-to-face conflict (Dawson et al. 2003; Djurić et al. 2006; Owens 2007; Siegel and Saukko 2012; Cohen et al. 2014; Serafin et al. 2014; Pasini et al. 2019). Moreover, for individual 92D, the involvement of the posterior part of parietal bones may suggest a backhanded inflicted blow while the victim was fleeing or the use of thrown objects (e.g. sling driven pellets/slingshot stones/projectiles) (Siegel and Saukko 2012; Cohen et al. 2014; Jiménez-Brobeil et al. 2014). In most cases of face-to-face combat, there is however considerable relative movement between the assailant and the victim, leading to irregular wound configuration (Siegel and Saukko 2012). Moreover, blunt force trauma is

variable in nature and often appears, especially in healed blows, as crushing and depression with little evidence of the weapon used, making it difficult to identify the dynamic of their formation (Cohen et al. 2014). Falls with the head striking on the ground are excluded because of their position above the hat brim line and the absence of large comminuted or linear fractures, expected in such cases (Kremer et al. 2008; Messina et al. 2013; Serafin et al. 2014). The absence of inflammatory reaction at the time of death, however, excludes for these individuals any major complications affecting the endocranium such as direct brain damage and/or infection (Aufderheide and Rodríguez-Martín 1998; Orschiedt et al. 2003).

The two perimortem inflicted traumas were sword injuries both affecting adult males > 35 years old, one at the lumbar spine and the other at the back diaphysis of the right femur. In both cases, the absence of healing testifies they were inflicted perimortem. In the first case, the characteristics and location of the wound and its direction running through the abdomen suggest it was the cause of death (Gualdi-Russo et al. 2020). Conversely, the blade wound on the femur of the other individual may have been inflicted shortly before death, which may have occurred because of this wound or other wounds inflicted during the same episode of interpersonal violence to vital organs. There is, moreover, no doubt that recognizable injuries on the skeleton represent only a small part of the total spectrum of injuries that may have affected a population, as most of them involve soft tissue and are therefore lost in the archaeological record (Roberts and Manchester 1995). These findings are particularly important as very few weapons were found in the grave goods of more than 4000 tombs: a javelin, a spear, the blade of a small dagger made of iron preserved in fragments, and two fragments of iron. Therefore, Spina was traditionally considered a free port generally without weapons (Malnati 1993; Patitucci Uggeri and Uggeri 1993). Then, the presence of sharp force trauma in several skeletons sheds light on some unknown aspects of the site's history as it suggests the presence of weapons such as swords, daggers, and knives in the site and a certain risk of exposure to violence for men. These findings seem to recall the historical data that mentioned people from Spina as "pirates of the Adriatic Sea" or "masters of the Adriatic Sea", implying their great dominium on commercial trades through the Adriatic, which allowed them to build their rich *thesaurus* at Delfi's sanctuary (Greece) (Braccisi and Coppola 1993; Sassatelli 1993; Torelli 1993). We would stress, however, that conclusions drawn on such a small number of cases showing signs of violence should be treated with great caution.

In considering the almost total absence of weapons in the grave goods, we cannot rule out the possibility that the attackers were not inhabitants of Spina. Also, we must keep

in mind the site's vocation as a free port, the ideology of the population that claimed to represent itself as Greek aristocracy beyond death, and the fact that lots of Spina graves have been the object of depredation from ancient to modern times (Gulletta 2005; Morpurgo 2020). Therefore, the funerary treatment did not automatically reflect the life of the inhabitants of Spina. Another important consideration is that the inflicted trauma (both antemortem and perimortem) involved exclusively males, who probably were more exposed to intentional violence, as found also for other coeval populations (Paine et al. 2007; Robb 2014). After all, the connection between masculinity and war is well-established in human history (Ferguson 2021). The low trauma rates found at Spina compared with the coeval Etruscan necropolis of Pontecagnano (Southern Italy) (Robb 2014) suggest that they were likely related to individual acts of interpersonal violence at Spina rather than warfare (Roksandic et al. 2006; Jiménez-Brobeil et al. 2014). However, we cannot exclude that some of them could be related to the Celtic invasion of the Po Plain at the end of the 3rd century BC, which also contributed to the site's decline. Although this possibility is merely hypothetical, the found blunt force trauma may be derived from sling-driven pellets, whose presence has been well documented by the settlement excavation and related to the Celt incursion (Desantis and Rinaldo 2020). Beyond this suggestive speculation, the location of both individuals' traumas on the left parietal suggests the possibility of a face-to-face confrontation with a right-handed opponent (Guyomarc'h et al. 2010; Kranioti 2015; Kremer et al. 2008). Also, the detected evidence of TMO and OD were almost exclusive of adult males, thus confirming that men were more exposed to muscular and articular traumas than women, probably due to the engagement in a more active daily life.

Conclusions

The main contribution of this study concerns the evidence of a low number of traumas in the Etruscan individuals examined and, at the same time, the presence of some inflicted traumas. For the first aspect, our study found that individuals buried in the Spina necropolis were exposed to a lower risk of injury compared to other Etruscans. In fact, traumas caused by single random events related to work activities were predominantly found. However, the presence of traumas that can be interpreted as due to interpersonal aggression that affected a few male individuals constitutes the second important aspect. These findings are important as accidental injuries can inform on the hazards of day-to-day life. Whereas inflicted traumas give information on violence and aggressiveness in the past, and on weapons used

in different times and populations. The Iron Age society that lived in Spina is well known from an archaeological point of view, given the great interest always aroused by the extraordinary grave goods equipping the burials and the recent excavation of the settlement. However, the anthropological analysis of human skeletal remains allowed obtaining some new information on this population, that could not be displayed from the material culture. In particular, the evidence of both antemortem and perimortem inflicted trauma found has discovered the employment of weapons such as swords not documented before by archaeological and historical research. The exclusive involvement of male individuals by inflicted trauma suggests that they were more prone than women to violence and aggressiveness, as well as to a more active lifestyle, as documented by their prevalence of TMO and OD. However, the finding of fatigue fractures at the spine in females suggests that women were also involved in strenuous activity such as carrying and transporting heavy loads on the head and/or on the back. The type and location of skeletal traumas detected appear consistent with traumas related to different occupations in males (with mainly limb involvement) and females (with primarily spine involvement). Although at the individual level, the observations drawn have some relevance, the low frequency of antemortem trauma prevents us from drawing with confidence general indications about the lifestyle of the Etruscan population of Spina.

Anyway, the present study provides new insights into the Spina Etruscans, further broadening the trauma literature for Northern Italy during the Iron Age.

Supplementary Information The online version contains supplementary material available at <https://doi.org/10.1007/s12520-024-02005-5>.

Acknowledgements The Authors would like to thank the Soprintendenza Archeologica, Belle Arti e Paesaggio per la città metropolitana di Bologna e le province di Modena, Reggio Emilia e Ferrara, and the National Archaeological Museum of Ferrara for permitting us to study a sample of Etruscan skeletal remains.

Author contributions All authors contributed to the study's conception and design. Material preparation, data collection and analysis were performed by VSM and NR. The first draft of the manuscript was written by VSM and EG-R, Fig. 1 was prepared by EG-R, Figs. 2, 3, 4 and 5 were prepared by NR and all authors commented on previous versions of the manuscript. All authors read and approved the final manuscript.

Funding No funds, grants, or other support was received. Open access funding provided by Università degli Studi di Ferrara within the CRUI-CARE Agreement.

Data availability No datasets were generated or analysed during the current study.

Declarations

Competing interests The authors declare no competing interests.

Open Access This article is licensed under a Creative Commons Attribution 4.0 International License, which permits use, sharing, adaptation, distribution and reproduction in any medium or format, as long as you give appropriate credit to the original author(s) and the source, provide a link to the Creative Commons licence, and indicate if changes were made. The images or other third party material in this article are included in the article's Creative Commons licence, unless indicated otherwise in a credit line to the material. If material is not included in the article's Creative Commons licence and your intended use is not permitted by statutory regulation or exceeds the permitted use, you will need to obtain permission directly from the copyright holder. To view a copy of this licence, visit <http://creativecommons.org/licenses/by/4.0/>.

References

- Acsadi G, Nemeskeri I (1974) History of Human Life Span and Mortality. *Curr Anthropol* 15:495–507. <https://doi.org/10.1086/201508>
- Aufderheide AC, Rodríguez-Martín C (1998) The Cambridge encyclopedia of human paleopathology
- Bass WM (1995) Human osteology: a laboratory and field manual. Missouri Archaeological Society
- Bello SM, Thomann A, Signoli M, Dutour O, Andrews P (2006) Age and sex bias in the reconstruction of past population structures. *Am J Phys Anthropol* 129:24–38
- Braccisi L, Coppola A (1993) I greci descrivono spina. In: Berti F, Guzzo PG (eds) Spina: storia di una città tra greci ed Etruschi. Comitato Ferrara Arte
- Brooks S, Suchey JM (1990) Skeletal age determination based on the os pubis: a comparison of the Acsádi-Nemeskéri and Suchey-Brooks methods. *Hum Evol* 5:227–238. <https://doi.org/10.1007/BF02437238>
- Buikstra JE, Ubelaker DH (1994) Standards for Data Collection from human skeletal remains. Arkansas Archaeological Survey Research Series 44
- Capasso L, Kennedy KAR, Wilczak CA (1999) Atlas of occupational markers on human remains. Enigrafitalia, Teramo
- Cattaneo C, Grandi M (2004) Antropologia E Odontologia forense: guida allo studio dei resti umani. Monduzzi, Milano
- Cohen H, Sarie I, Medlej B et al (2014) Trauma to the skull: a historical perspective from the southern Levant (4300BCE–1917CE). *Int J Osteoarchaeol* 24:722–736
- Cunha E, Pinheiro J (2016) Bone pathology and antemortem trauma. Academic Press Cambridge, MA, USA
- Dawson L, Levy TE, Smith P (2003) Evidence of interpersonal violence at the Chalcolithic village of Shiqmim (Israel). *Int J Osteoarchaeol* 13:115–119
- De Luca F, Pasini A, Scianò F et al (2023) Heal the sick: Health status and caregiving during the 17th–18th century in Northern Italy (St. Biagio Cemetery, Ravenna). *Am J Biol Anthropol*. <https://doi.org/10.1002/ajpa.24861>
- Demoulin F (1972) Importance de certaines mesures crâniennes (en particulier de la longueur sagittale de la mastoïde) dans la dénomination sexuelle des crânes. *Bull Mem Soc Anthropol Paris* 9:259–264. <https://doi.org/10.3406/bmsap.1972.2053>
- Desantis P, Rinaldo N (2020) Testimonianze celtiche a Spina alla luce dei nuovi studi sulle necropoli. In: Castiglioni MP, Curcio M, Dubbini R (eds) Incontrarsi Al Limite: ibridazioni

- mediterranea nell'Italia preromana. L'Erma di Bretschneider, Roma, pp 189–213
- Djurić MP, Roberts CA, Rakočević ZB et al (2006) Fractures in late medieval skeletal populations from Serbia. *Am J Phys Anthropology: Official Publication Am Association Phys Anthropologists* 130:167–178
- Earl JE (2002) Mechanical aetiology, recognition, and treatment of spondylolisthesis. *Phys Ther Sport* 3:79–87
- Ferembach D, Schwydeski I, Stloukal M (1980) Recommendations for age and sex diagnoses of skeletons. *J Hum Evol* 9:517–549. [https://doi.org/10.1016/0047-2484\(80\)90061-5](https://doi.org/10.1016/0047-2484(80)90061-5)
- Ferguson RB (2021) Masculinity and war. *Curr Anthropol* 62:S112–S124
- Fibiger L (2013) Mislplaced childhood? Interpersonal violence and children in Neolithic Europe. In: Knüsel C, Smith M (eds) *The Routledge Handbook of the Bioarchaeology of Human Conflict*. Routledge, pp 127–145
- Gualdi-Russo E (2007) Sex determination from the talus and calcaneus measurements. *Forensic Sci Int* 171:151–156. <https://doi.org/10.1016/j.forsciint.2006.10.014>
- Gualdi-Russo E, Zedda N, Esposito V, Masotti S (2017) More on molar incisor hypomineralisation (MIH) and linear enamel hypoplasia (LEH) in archaeological human remains. *Clin Oral Investig* 21:2153–2154
- Gualdi-Russo E, Manzon VS, Saguto I, Rinaldo N (2020) Life and death in Italian prehistory: the case of the sailor from Spina. *World Neurosurg* 139:106–110
- Gulletta MI (2005) Spina. *Bibliografia Topografica della colonizzazione greca in Italia. e Nelle Isole Tirre Niche* 19:526–617
- Guyomarc'h P, Campagna-Vaillancourt M, Kremer C, Sauvageau A (2010) Discrimination of falls and blows in blunt head trauma: a multi-criteria approach. *J Forensic Sci* 55:423–427. <https://doi.org/10.1111/j.1556-4029.2009.01310.x>
- İşcan M, Loth SR, Wright RK (1984) Age estimation from the rib by phase analysis: white males. *J Forensic Sci* 29:1094–1104
- Jiménez-Brobeil SA, Du Souich PH, Al Oumaoui I (2009) Possible relationship of cranial traumatic injuries with violence in the south-east Iberian Peninsula from the neolithic to the bronze age. *Am J Phys Anthropology: Official Publication Am Association Phys Anthropologists* 140:465–475
- Jiménez-Brobeil SA, Roca MG, Laffranchi Z et al (2014) Violence in the Central Iberian Peninsula during the bronze age: a possible prehistoric homicide. *Int J Osteoarchaeol* 24:649–659
- Jenkins JR (2004) Acquired degenerative changes of the intervertebral segments at and suprajacent to the lumbosacral junction: a radio-anatomic analysis of the nondiscal structures of the spinal column and perispinal soft tissues. *Eur J Radiol* 50:134–158
- Jordana F, Colat-Parros J, Bénézech M (2013) Diagnosis of skull fractures according to postmortem interval: an experimental approach in a porcine model. *J Forensic Sci* 58:S156–S162
- Judd MA, Redfern R (2011) Trauma. A companion to paleopathology 357–379
- Kimmerle EH, Baraybar JP (2008) Skeletal trauma: identification of injuries resulting from human rights abuse and armed conflict. CRC
- Kranioti E (2015) Forensic investigation of cranial injuries due to blunt force trauma: current best practice. *Res Rep Forensic Med Sci* 5:25–37
- Kremer C, Sauvageau A (2009) Discrimination of falls and blows in blunt head trauma: assessment of predictability through combined criteria. *J Forensic Sci* 54:923–926
- Kremer C, Racette S, Dionne C, Sauvageau A (2008) Discrimination of falls and blows in blunt head trauma: systematic study of the hat brim line rule in relation to skull fractures. *J Forensic Sci* 53:716–719
- Krogman WM, İşcan MY (1986) *The human skeleton in forensic medicine*. C.C. Thomas
- Levy LF (1968) Porter's neck. *Br Med J* 2:16
- Lewis JE (2008) Identifying sword marks on bone: criteria for distinguishing between cut marks made by different classes of bladed weapons. *J Archaeol Sci* 35:2001–2008. <https://doi.org/10.1016/j.jas.2008.01.016>
- Lewis ME (2014) Sticks and stones: exploring the nature and significance of child trauma in the past. In: Knüsel C, Smith M (eds) *The Routledge Handbook of the Bioarchaeology of Human Conflict*. Routledge, London, pp 39–63
- Lovejoy CO (1985) Dental wear in the Libben population: its functional pattern and role in the determination of adult skeletal age at death. *Am J Phys Anthropol* 68:47–56. <https://doi.org/10.1002/ajpa.1330680105>
- Lovell NC (1997) Trauma analysis in paleopathology. *Am J Phys Anthropology: Official Publication Am Association Phys Anthropologists* 104:139–170
- MacLaughlin SM, Oldale KNM (1992) Vertebral body diameters and sex prediction. *Ann Hum Biol* 19:285–292. <https://doi.org/10.1080/03014469200002152>
- Madden GD, Karsten JK, Ledogar SH et al (2018) Violence at Verteba Cave, Ukraine: new insights into the late neolithic intergroup conflict. *Int J Osteoarchaeol* 28:44–53
- Magerl F, Aebi M, Gertzbein SD et al (1994) A comprehensive classification of thoracic and lumbar injuries. *Eur Spine J* 3:184–201
- Malnati L (1993) Le Istituzioni Politiche E religiose a spina e nell'Etruria Padana. In: Berti F, Guzzo PG (eds) *Spina: Storia Di una città tra greci ed Etruschi*. Comitato Ferrara Arte
- Mann RW, Hunt DR (2013) *Photographic regional atlas of bone disease: a guide to pathologic and normal variation in the human skeleton*. Charles C Thomas, Springfield
- Mann WR, Murphy SP, Smith OC, Ortner DJ (1990) *Regional atlas of bone disease: a guide to pathologic and normal variation in the human skeleton*. Charles C Thomas Pub Ltd, Springfield
- Mant M, de la Cova C, Brickley MB (2021) Intersectionality and trauma analysis in bioarchaeology. *Am J Phys Anthropol* 174:583–594
- Manzon VS, Gualdi-Russo E (2016) Health patterns of the Etruscan Population (6th–3rd centuries bc) in Northern Italy: the case of Spina. *Int J Osteoarchaeol* 26:490–501. <https://doi.org/10.1002/oa.2438>
- Manzon VS, Onisto N, Gualdi-Russo E (2014) Spondylolisthesis in an etruscan woman from Spina (Ferrara, Italy): an iron age case report. *Coll Antropol* 38:745–748
- Manzon VS, Ferrante Z, Giganti M, Gualdi-Russo E (2017) On the antiquity of Legg–Calvé–Perthes disease: skeletal evidence in iron age Italy. *Homo* 68:10–17
- Martin DL, Harrod RP (2012) Body parts and parts of bodies: traces of violence in past cultures. *Int J Paleopathol* 2:49–52
- Masotti S, Onisto N, Marzi M, Gualdi-Russo E (2013) Dento-alveolar features and diet in an etruscan population (6th–3rd c. BC) from northeast Italy. *Arch Oral Biol* 58:416–426
- Masotti S, Mongillo J, Gualdi-Russo E (2020) Burned human remains: diachronic analysis of cremation rituals in necropolises of northern Italy. *Archaeol Anthropol Sci* 12:74
- Mays S (2006a) Spondylolysis, spondylolisthesis, and lumbo-sacral morphology in a medieval English skeletal population. *Am J Phys Anthropology: Official Publication Am Association Phys Anthropologists* 131:352–362
- Mays SA (2006b) A palaeopathological study of Colles' fracture. *Int J Osteoarchaeol* 16:415–428. <https://doi.org/10.1002/oa.845>
- Meindl RS, Lovejoy CO (1985) Ectocranial suture closure: a revised method for the determination of skeletal age at death based on the lateral-anterior sutures. *Am J Phys Anthropol* 68:57–66. <https://doi.org/10.1002/ajpa.1330680106>

- Merbs CF (1983) Patterns of activity-induced pathology in a Canadian Inuit population. National Museum of Man. Mercury series, Archaeological survey of Canada, Paper No.119. National Museums of Canada, Ottawa
- Merbs CF (2002) Asymmetrical spondylolysis. *Am J Phys Anthropol*: Official Publication Am Association Phys Anthropologists 119:156–174
- Messina AD, Carotenuto G, Micciché R, Sineo L (2013) Fatal cranial injury in an individual from Messina (Sicily) during the times of the Roman Empire. *J Forensic Leg Med* 20:1018–1023
- Moreno-Ibáñez MÁ, Saladié P, Ramírez-Pedraza I, Díez-Canseco C, Fernández-Marchena JL, Soriano E, Carbonell E, Tornero C (2024) Death in the high mountains: Evidence of interpersonal violence during Late Chalcolithic and Early Bronze Age at Roc de les Orenetes (Eastern Pyrenees, Spain). *American Journal of Biological Anthropology*: e24909
- Morpurgo G (2020) Il Vasellame in Bronzo Da banchetto nelle necropoli etrusche di bologna (560–350 ac): forme, uso e produzione. *Ocnus Quaderni della Scuola di Specializzazione in Beni Archeologici*
- Orschiedt J, Häußler A, Haidle MN et al (2003) Survival of a multiple skull trauma: the case of an early neolithic individual from the LBK enclosure at Herxheim (Southwest Germany). *Int J Osteoarchaeol* 13:375–383
- Ortner DJ (2003) Identification of pathological conditions in human skeletal remains. Academic, USA
- Osterholtz AJ, Martin DL (2017) The poetics of annihilation: on the Presence of women and children at Massacre sites in the Ancient Southwest. In: Martin D, Tegtmeier C (eds) *Bioarchaeology of women and children in Times of War*. *Bioarchaeology and Social Theory*. Springer, Cham. <https://doi.org/10.1007/978-3-319-48396-2>
- Osterholtz A, Martin D, Harrod R (2023) Bioarchaeology of violent death. In: Parra RC, Ubelaker DH (eds) *Anthropology of Violent Death: theoretical foundations for forensic humanitarian action*. John Wiley & Sons, Ltd, USA, pp 67–89
- Owens LS (2007) Craniofacial trauma in the prehispanic Canary Islands. *Int J Osteoarchaeol* 17:465–478. <https://doi.org/10.1002/oa.898>
- Paine RR, Mancinelli D, Ruggieri M, Coppa A (2007) Cranial trauma in Iron Age Samnite agriculturists, Alfedena, Italy: implications for biocultural and economic stress. *Am J Phys Anthropol* 132:48–58
- Pasini A, Gualdi-Russo E, Scianò F, Hohenstein UT (2018) Violence in the early bronze age. Diagnosis of skull lesions using anthropological, taphonomic and scanning electron microscopy techniques. *Forensic Sci Med Pathol* 1–5
- Pasini A, Gualdi-Russo E, Scianò F, Thun Hohenstein U (2019) Violence in the early bronze age. Diagnosis of skull lesions using anthropological, taphonomic and scanning electron microscopy techniques. *Forensic Sci Med Pathol* 15:324–328
- Patitucci Uggeri S, Uggeri G (1993) La Topografia della città. In: Berti F, Guzzo PG (eds) *Spina – Storia Di una città tra greci ed Etruschi*. Comitato Ferrara Arte, Ferrara
- Plomp KA, Been E, Collard M (2022) Acquired spinal conditions in humans: the roles of spinal curvature, the shape of the lumbar vertebrae, and evolutionary history. In: Plomp KA, Roberts CA, Elton S, Bentley GL (eds) *Palaeopathology and Evolutionary Medicine: an Integrated Approach*. Oxford University Press, Oxford
- Puisto V, Rissanen H, Heliövaara M et al (2008) Mortality in the Presence of a vertebral fracture, scoliosis, or Scheuermann's Disease in the thoracic spine. *Ann Epidemiol* 18:595–601. <https://doi.org/10.1016/j.annepidem.2008.04.009>
- Redfern RC, Judd MA, DeWitte SN (2017) Multiple injury and health in past societies: an analysis of concepts and approaches, and insights from a multi-period study. *Int J Osteoarchaeol* 27:418–429
- Ribeiro P, Jordana X, Scheirs S et al (2020) Distinction between perimortem and postmortem fractures in human cranial bone. *Int J Legal Med* 134:1765–1774
- Ríos L, Cardoso HFV (2009) Age estimation from stages of union of the vertebral epiphyses of the ribs. *Am J Phys Anthropol* 140:265–274. <https://doi.org/10.1002/ajpa.21065>
- Robb J (2014) *Violence and gender in early Italy*. Troubled Times. Routledge, pp 111–144
- Roberts C, Manchester K (1995) *The archaeology of disease*, 2nd edn. Sutton, Stroud
- Roksandic M, Djurić M, Rakočević Z, Seguin K (2006) Interpersonal violence at Lepenski Vir Mesolithic/Neolithic complex of the iron gates gorge (Serbia-Romania). *Am J Phys Anthropol* 129:339–348
- Rubini M, Zaio P (2011) Warriors from the East. Skeletal evidence of warfare from a Lombard-Avar cemetery in central Italy (Campochiaro, Molise, 6th–8th century AD). *J Archaeol Sci* 38:1551–1559
- Rühli FJ, Müntener M, Henneberg M (2006) Human osseous intervertebral foramen width. *Am J Phys Anthropol* 129:177–188. <https://doi.org/10.1002/ajpa.20263>
- Sassatelli G (1993) La Funzione Economica E produttiva: merci, scambi, artigianato. In: Berti F, Guzzo PG (eds) *Spina – Storia Di una città tra greci ed Etruschi*. Comitato Ferrara Arte, Ferrara
- Sauer N (1984) Manner of death: skeletal evidence of blunt and sharp instrument wounds. In: Rathbun T, Buikstra J (eds) *Human identification: case studies in forensic anthropology*. Charles C Thomas, Springfield, pp 177–184
- Sauer N (1998) The timing of injuries and manner of death: distinguishing among antemortem, perimortem and postmortem trauma. In: *Forensic Osteology Advances in the Identification of Human Remains*, 2nd edition. pp 321–332
- Schaefer M, Black SM, Schaefer MC, Scheuer L (2009) *Juvenile osteology*. Academic, London
- Schultz AH (1930) The skeleton of the trunk and limbs of higher primates. *Hum Biol* 2:303–438
- Scianò F, Bramanti B, Manzon VS, Gualdi-Russo E (2020) An investigative strategy for assessment of injuries in forensic anthropology. *Leg Med* 42:101632
- Scianò F, Zedda N, Mongillo J et al (2021) Autopsy or anatomical dissection: evidence of a craniotomy in a 17th–eighteenth century burial site (Ravenna, Italy). *Forensic Sci Med Pathol* 17:157–160
- Serafin S, Lope CP, Uc González E (2014) Bioarchaeological investigation of ancient Maya violence and warfare in inland northwest Yucatan, Mexico. *Am J Phys Anthropol* 154:140–151
- Siegel JA, Saukko PJ (2012) *Encyclopedia of forensic sciences*. Academic
- Smith A (2021) *Distinguishing Between Antemortem, Perimortem, and Postmortem Bone Trauma: A Short Primer*. *Academia Letters* 2
- Strong RLJ, Fibiger L (2023) An experimental investigation of cutmark analysis of sharp force trauma in the bronze age. *J Archaeol Science: Rep* 48:103843. <https://doi.org/10.1016/j.jasrep.2023.103843>
- Torelli M (1993) *Spina E La Sua Storia*. In: Berti F, Guzzo PG (eds) *Spina – Storia Di una città tra greci ed Etruschi*. Comitato Ferrara Arte
- Tremblay LA, Reedy S (2020) *The Bioarchaeology of Structural Violence*. Springer
- Ubelaker DH (1989) *Human skeletal remains: Excavation, Analysis, Interpretation*. Aldine De Gruyter
- Walker PL (2008) Sexing skulls using discriminant function analysis of visually assessed traits. *Am J Phys Anthropol* 136:39–50. <https://doi.org/10.1002/ajpa.20776>

- Wedel VL, Galloway A (2013) Broken bones: anthropological analysis of blunt force trauma. Charles C Thomas, Springfield, USA
- Yang KH, King AI (1984) Mechanism of facet load transmission as a hypothesis for low-back pain. *Spine (Phila Pa 1976)* 9:557–565

Publisher's Note Springer Nature remains neutral with regard to jurisdictional claims in published maps and institutional affiliations.