

Case report: Congenital extrahepatic portocaval shunt presenting as pulmonary arterial hypertension in a pregnant patient

Matevž Harlander^{1,2} | Maja Badovinac¹ | Frosina Markoska¹ |
Barbara Salobir^{1,2} | Tomaž Štupnik^{2,3} | Marija Iča Dolenšek⁴ | Izidor Kern⁵ |
Vojka Gorjup⁶ | Nazzareno Galiè⁷

¹Department of Pulmonary Diseases and Allergy, University Medical Centre Ljubljana, Ljubljana, Slovenia

²Faculty of Medicine Ljubljana, University of Ljubljana, Ljubljana, Slovenia

³Department of Thoracic Surgery, University Medical Centre Ljubljana, Ljubljana, Slovenia

⁴Institute of Radiology, University Medical Centre Ljubljana, Ljubljana, Slovenia

⁵Cytology and Pathology Laboratory, University Clinic of Respiratory and Allergic Diseases Golnik, Golnik, Slovenia

⁶Department of Intensive Internal Medicine, University Medical Centre Ljubljana, Ljubljana, Slovenia

⁷DIMES, S. Orsola University Hospital, University of Bologna and IRCCS, Bologna, Italy

Correspondence

Matevž Harlander, Department of Pulmonary Diseases and Allergy, University Medical Centre Ljubljana, Zaloška 7, Ljubljana 1000, Slovenia.
Email: matevz.harlander@kclj.si

Funding information

None

Abstract

Congenital extrahepatic portocaval shunt (CEPS) is a rare condition in which a rare congenital vascular anomaly of the portal system is present. CEPS may manifest as pulmonary arterial hypertension (PAH). When diagnosed and treated early, PAH can be reversible. We report a case of a previously asymptomatic woman, who manifested with severe pulmonary hypertension during pregnancy and was consequently diagnosed with CEPS. After unsuccessful medical treatment, urgent lung transplantation was done.

KEYWORDS

Abernethy syndrome, portopulmonary hypertension, pregnancy

INTRODUCTION

Congenital extrahepatic portocaval shunt (CEPS), also known as the Abernethy malformation, is a rare condition in which a congenital vascular anomaly of the portal system is present. Type I malformation is characterized by the absence of the intrahepatic portal vein and a complete shunt of portal

blood into the systemic circulation. It is usually diagnosed in childhood. In Type II malformation, the portal vein is hypoplastic and only a part of portal blood is shunted to the inferior vena cava through extrahepatic connection. The diagnosis is often delayed until adulthood.^{1,2} One of the possible manifestations of CEPS is pulmonary arterial hypertension (PAH).³

This is an open access article under the terms of the Creative Commons Attribution-NonCommercial License, which permits use, distribution and reproduction in any medium, provided the original work is properly cited and is not used for commercial purposes.

© 2021 The Authors. *Pulmonary Circulation* published by John Wiley & Sons Ltd on behalf of Pulmonary Vascular Research Institute.

CASE DESCRIPTION

A 31-year-old woman in the 33rd week of pregnancy was admitted to the hospital because of dyspnea and hemoptysis that started 5 days before admission. In the past few years before pregnancy, she reported having episodes of dry cough with occasional minimal hemoptysis which was attributed to gastroesophageal reflux. On admission, she had a respiratory failure (3 L O₂/min) and she was in functional Class NYHA IV. Cardiac ultrasound showed increased systolic pulmonary arterial pressure (sPAP) of 80 mmHg and severe enlargement and hypertrophy of the right ventricle. CTA of pulmonary arteries did not show pulmonary embolisms. Thyroid hormones and screening tests for connective tissue diseases, COVID-19, HIV, and hepatitis were negative. Hepatic enzymes and bilirubin levels were within normal values while ammonia level was not measured. Radiological characteristics suggested a diagnosis of pulmonary

veno-occlusive disease/pulmonary capillary hemangiomatosis (PVOD/PCH) rather than PAH (Figure 1a).

Epoprostenol was considered as a therapeutic option but was not tried due to its association with worsening of pulmonary edema and even fatal outcome in patients with PVOD/PCH.⁴ Two days after admission, a cesarean section in general anesthesia was performed after stabilization of the mother and the baby with supportive therapy including two doses of flosateron, furosemide, and inhaled NO.

After delivery, the baby was in good condition, while the mother remained dependent on mechanical ventilation—a trial of extubation 1 day after the operation was unsuccessful. Because the diagnosis of PVOD/PCH was still not firm macitentan was added to inhaled NO as a therapeutic trial. The clinical state did not improve, and a control computed tomography (CT) 2 days later showed significant deterioration of interlobular septal thickening (Figure 1b) further suggesting PVOD/PCH.⁵ Right heart

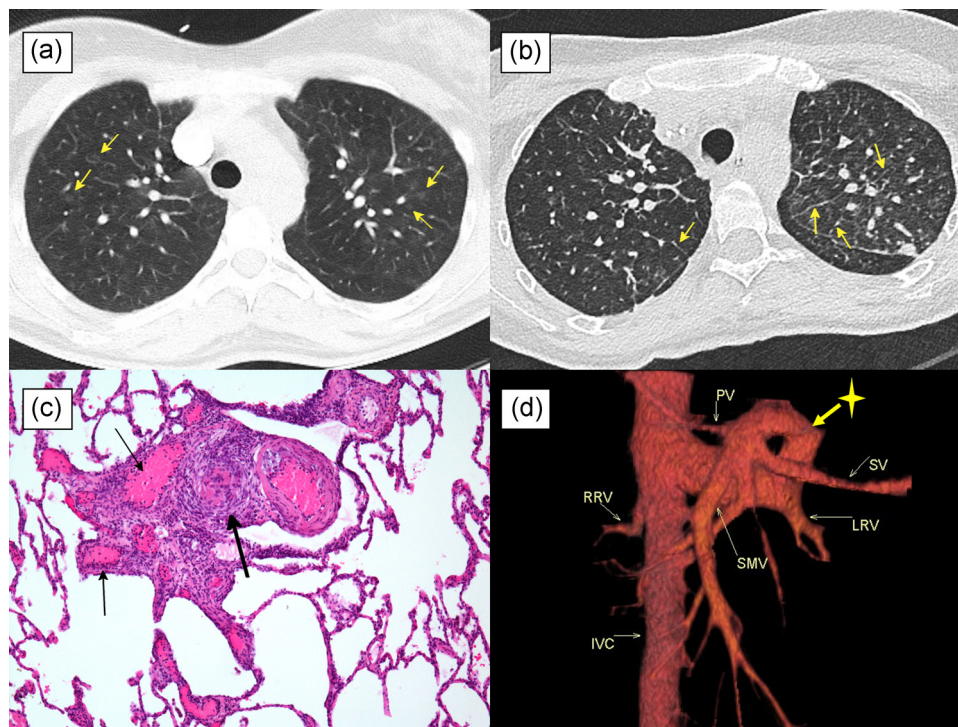


FIGURE 1 Severe pulmonary hypertension due to congenital extrahepatic portocaval shunt. (a) CT upon admission shows mildly to moderately expressed centrilobular ground-glass opacities in all lobes (arrows) and in places interlobular septal thickening suggesting PCH/POVD. (b) CT 2 days after macitentan in combination with NO shows worsening of interlobular septal thickening (arrows). (c) Histological examination of explanted lungs shows complex lesion characteristic of pulmonary arterial hypertension showing plexiform changes with a network of vascular channels lined with endothelial cells, surrounded by dilated thin-walled vein-like vessels (thin arrows) and thick-walled small pulmonary artery (thick arrow) due to a concentric intimal proliferation (hematoxylin-eosin, original magnification $\times 100$). (d) CT venography, volume rendering technique (VRT)—reconstruction shows anomalous drainage (marked with *) of a major part of superior mesenteric vein and splenic vein into inferior vena cava through the left renal vein and hypoplastic portal vein. (CT, computed tomography; IVC, inferior vena cava; LRV, left renal vein; PCH/POVD, pulmonary veno-occlusive disease/pulmonary capillary hemangiomatosis; PV, portal vein; RRV, right renal vein; SMV, superior mesenteric vein; SV, splenic vein)

catheterization confirmed increased pulmonary pressure without a decline in cardiac index (CI) (s-d/mPAP 107/45–66 mmHg, PCWP 12 mmHg, PVR 455 dyn·s/cm⁵, CI 4.4 L/min/m²). She needed support with noradrenaline and dobutamine but her clinical condition, kidney, and liver function had been deteriorating. An abdominal ultrasound showed anomalous venous structure around the right kidney, but at that point, this was not considered a clinically relevant finding.

Seven days after delivery, a cardiogenic shock developed due to a right ventricular failure, which was treated with veno-arterial extracorporeal membrane oxygenation (ECMO). Three days later, an urgent bilateral lung transplantation was performed. Unexpectedly, histological examination of the explanted lungs was consistent with changes due to PAH and not PVOD/PCH (Figure 1c). The postoperative course was complicated by kidney failure, intestinal failure, and severe myopathy. Due to postoperative complications, an abdominal CT scan was done. It finally revealed CEPS Type II as the underlying reason for severe pulmonary hypertension (Figure 1d).

A year later, the patient continues with rehabilitation but is in good clinical condition. No correction of CEPS Type II malformation was yet performed. Surgical closure of the shunt was taken into consideration, but the perceived risks of the procedure were estimated to be higher than potential benefits, so we opted for watchful waiting. Echocardiography showed normal sPAP (32 mmHg), with a normal size of the right heart. There was a mild increase of blood ammonia (34 μmol/L, normal values 11–32 μmol/L) and alkaline phosphatase (5.36 μkat/L, normal values 0.55–1.64 μkat/L) but there were no clinical signs of a portocaval shunt.

DISCUSSION

CEPS can be complicated by PAH in up to 15%.^{3,6,7} Pathogenesis of PAH in CEPS is likely similar to the pathogenesis of portopulmonary hypertension. Due to an extrahepatic shunt an excessive amount of vasoconstrictive and proliferative substances (such as endothelin-1), which would normally be metabolized by a liver, reaches pulmonary circulation. Consequently, progressive vascular remodeling develops. It may be further aggravated by hyperdynamic circulation that causes endothelial injury and dysfunction through shear stress.^{8,9} In our patient, PAH might have developed already before pregnancy which is consistent with the history of mild hemoptysis. During pregnancy, several physiological changes occur that have important effects on pulmonary hemodynamic. By the last trimester, blood volume

increases up to 40%–100% and cardiac output up to 30%–50%. This is accompanied by an increase of levels of sex hormones, such as progesterone, testosterone, and estrogens, which have a vasodilatory effect on pulmonary circulation and help pulmonary circulation to accommodate the increased blood flow. However, in patients with PAH, the response of pulmonary vasculature to vasodilatory substances is attenuated which worsens the effects of hyperdynamic circulation and increases the right ventricular strain. This may lead to right ventricular failure. Moreover, in our patient there might have been an increase of portocaval shunt, further worsening her condition. The climax of hemodynamic changes during pregnancy occurs between the 28th and 34th week which coincides with the presentation of our patient.⁹ A remarkable finding in our patient was a high cardiac output in the association with high pulmonary arterial pressure which we attributed to persisting postpartum hemodynamic changes. However, a small case series described PAH associated with high cardiac output in three male patients with CEPS suggesting the presence of additional pathophysiological mechanisms.¹⁰

We speculate that in our patient a combination of hyperdynamic circulation, hypervolemic state, and perhaps specific consequences of CEPS lead to the development of interstitial and alveolar edema mimicking the CT signs of PVOD/PCH.⁵ Intravenous prostacyclin therapy was thus not tried due to fear of the development of pulmonary edema, which was described in 44% of patients with PVOD/PCH.⁴ Albeit endothelin receptor antagonists were also associated with deterioration of PVOD/PCH,⁴ we decided for a trial with macitentan, which was unsuccessful.

PAH associated with CEPS can be reversible. Shunt closure should be considered in all patients with Type II malformation as it may significantly reduce complications, including the worsening of PAH.^{3,6,7,11} After the correction of the portocaval shunt, an overflow of vasoactive substances is stopped and PAH gradually resolves.^{6,7} In some patients, the treatment with pulmonary antihypertensives may stabilize the condition,³ but this was only demonstrated in a small study and needs further clinical investigation. In our patient, treatment with inhaled NO and macitentan did not result in clinical improvement. Retrospectively, we can thus speculate that lung transplantation in our patient could have been avoided, had the Abernethy malformation been diagnosed before the pregnancy and the development of right heart failure. The rarity of this condition caused a delayed diagnosis even after complications already developed. Moreover, a later literature search did not reveal any cases describing the presentation of CEPS during pregnancy.

In conclusion, to our best knowledge, this is the first report of Abernethy malformation manifesting as PAH during pregnancy. Although rare, it should be considered in the differential diagnoses of PAH diagnosed during pregnancy.

ACKNOWLEDGMENTS

We certify that the submission is original work and is not under review at any other publication.

CONFLICT OF INTERESTS

The authors declare that there are no conflict of interests.

ETHICS STATEMENT

Ethical approval was not provided; however, written, and informed consent of the patient was obtained for publication of patient information.

AUTHOR CONTRIBUTION

All co-authors have seen and agree with the contents of the manuscript.

REFERENCES

- Azad S, Arya A, Sitaraman R, Garg A. Abernethy malformation: our experience from a tertiary cardiac care center and review of literature. *Ann Pediatr Cardiol*. 2019;12:240–7.
- Kanamori Y, Hashizume K, Kitano Y, Sugiyama M, Motoi T, Tange T. Congenital extrahepatic portocaval shunt (Abernethy type 2), huge liver mass, and patent ductus arteriosus—a case report of its rare clinical presentation in a young girl. *J Pediatr Surg*. 2003;38:15–20.
- Baiges A, Turon F, Simón-Talero M, Tasayco S, Bueno J, Zekrini K, Plessier A, Franchi-Abella S, Guerin F, Mukund A, Eapen CE, Goel A, Shyamkumar NK, Coenen S, De Gottardi A, Majumdar A, Onali S, Shukla A, Carrilho FJ, Nacif L, Primignani M, Tosetti G, La Mura V, Nevens F, Witters P, Tripathi D, Tellez L, Martínez J, Álvarez-Navascués C, Fraile López ML, Procopet B, Piscaglia F, de Koning B, Llop E, Romero-Cristobal M, Tjwa E, Monescillo-Francia A, Senzolo M, Perez-LaFuente M, Segarra A, Sarin SK, Hernández-Gea V, Patch D, Laleman W, Hartog H, Valla D, Genescà J, García-Pagán JC, EHEVASC, VALDIG an EASL consortium, Abernethy Group. Congenital extrahepatic portosystemic shunts (Abernethy malformation): an international observational study. *Hepatology*. 2020;71:658–69.
- Montani D, Achouh L, Dorfmueller P, Le Pavec J, Sztymf B, Tchérakian C, Rabiller A, Haque R, Sitbon O, Jaïs X, Darteville P, Maître S, Capron F, Musset D, Simonneau G, Humbert M. Pulmonary veno-occlusive disease: clinical, functional, radiologic, and hemodynamic characteristics and outcome of 24 cases confirmed by histology. *Medicine (Baltimore)*. 2008;87:220–33.
- Grosse C, Grosse A. CT findings in diseases associated with pulmonary hypertension: a current review. *Radiographics*. 2010;30:1753–77.
- Peček J, Fister P, Homan M. Abernethy syndrome in Slovenian children: Five case reports and review of literature. *World J Gastroenterol*. 2020;26:5731–44.
- Sharma S, Bobhate PR, Sable S, Kumar S, Yadav K, Maheshwari S, Amin S, Chauhan A, Varma V, Kapoor S, Kumaran V. Abernethy malformation: single-center experience from India with review of literature. *Indian J Gastroenterol*. 2018;37:359–64.
- Raevens S, Geerts A, Van Steenkiste C, Verhelst X, Vlierberghe HV, Colle I. Hepatopulmonary syndrome and portopulmonary hypertension: recent knowledge in pathogenesis and overview of clinical assessment. *Liver Int*. 2015;35:1646–60.
- Hemnes AR, Kiely DG, Cockrill BA, Safdar Z, Wilson VJ, Al Haxmi M, Preston IR, MacLean MR, Lahm T. Statement on pregnancy in pulmonary hypertension from the pulmonary vascular research institute. *Pulm Circ*. 2015;5:435–65.
- Spruijt OA, Bogaard HJ, Vonk-Noordegraaf A. Pulmonary arterial hypertension combined with a high cardiac output state: three remarkable cases. *Pulm Circ*. 2013;3:440–3.
- Sahu MK, Bisoi AK, Chander NC, Agarwala S, Chauhan S. Abernethy syndrome, a rare cause of hypoxemia: a case report. *Ann Pediatr Cardiol*. 2015;8:64–6.

How to cite this article: Harlander M, Badovinac M, Markoska F, Salobir B, Štupnik T, Dolenšek MI, Kern I, Gorjup V, Galiè N. Case report: Congenital extrahepatic portocaval shunt presenting as pulmonary arterial hypertension in a pregnant patient. *Pulm Circ*. 2022;12:e12008. <https://doi.org/10.1002/pul2.12008>