



ALMA MATER STUDIORUM
UNIVERSITÀ DI BOLOGNA

ARCHIVIO ISTITUZIONALE
DELLA RICERCA

Alma Mater Studiorum Università di Bologna Archivio istituzionale della ricerca

Histological survey for oxalate nephrosis in Victorian koalas (*Phascolarctos cinereus*)

This is the final peer-reviewed author's accepted manuscript (postprint) of the following publication:

Published Version:

Speight N., Bacci B., Stent A., Whiteley P. (2020). Histological survey for oxalate nephrosis in Victorian koalas (*Phascolarctos cinereus*). AUSTRALIAN VETERINARY JOURNAL, 98(9), 467-470 [10.1111/avj.12986].

Availability:

This version is available at: <https://hdl.handle.net/11585/798107> since: 2021-02-11

Published:

DOI: <http://doi.org/10.1111/avj.12986>

Terms of use:

Some rights reserved. The terms and conditions for the reuse of this version of the manuscript are specified in the publishing policy. For all terms of use and more information see the publisher's website.

This item was downloaded from IRIS Università di Bologna (<https://cris.unibo.it/>).
When citing, please refer to the published version.

(Article begins on next page)

Histological survey for oxalate nephrosis in Victorian koalas (*Phascolarctos cinereus*)

N Speight^{a*}, B Bacci^b, A Stent^c and P Whiteley^{c,d}

^aSchool of Animal and Veterinary Sciences, Roseworthy campus, University of Adelaide, South Australia 5371, Australia

^bDepartment of Veterinary Medical Sciences, University of Bologna, via Tolara di Sopra 50, 40064 Bologna, Italy

^cMelbourne Veterinary School, Faculty of Veterinary and Agricultural Sciences, The University of Melbourne, 250 Princess Hwy, Werribee, Vic 3030 Australia

^dWildlife Health Victoria: Surveillance

*Corresponding author: Natasha Speight. School of Animal and Veterinary Sciences, Roseworthy campus, University of Adelaide, Roseworthy, South Australia 5371. Phone (+618) 8313 0655. Email: natasha.speight@adelaide.edu.au

Abstract

The Mount Lofty Ranges koala (*Phascolarctos cinereus*) population in South Australia has a high prevalence of the renal disease oxalate nephrosis, for which an underlying genetic cause is suspected. South Australian koalas primarily originate from those in French Island, Victoria,

however oxalate nephrosis has not previously been reported in Victorian koalas. Examination of kidney tissue sections from 63 koalas across Victoria found that nine koalas were affected by oxalate nephrosis (14.3%). These included 2/5 koalas from French Island (40%), 4/14 koalas from the western regions (29%), 2/11 Raymond Island koalas (18%), and 1/13 Cape Otway koalas (8%). There were no cases of oxalate nephrosis identified in the Strzelecki koalas (n=12). These findings suggest that oxalate nephrosis occurs in koalas from French Island and populations that have received significant influx of koalas from French Island, but not in the Strzelecki region, which has little to no French Island input. This lends support to the theory that an inherited abnormality of oxalate metabolism could underlie the high prevalence of oxalate nephrosis in the Mount Lofty Ranges koala population, and molecular investigations are currently underway to investigate a genetic cause.

Key words

Crystal, disease, kidney, koala, oxalate, nephrosis, Phascolarctidae.

Introduction

Koala (*Phascolarctos cinereus*) populations are declining in north-eastern Australia, and considered to be vulnerable under the *Environmental Protection and Biodiversity Act 1999* due to habitat loss, motor vehicle accidents and *Chlamydia*- associated disease. Southern koala populations in Victoria and South Australia are considered to be more robust, despite similar health threats.¹

A disease of great concern in South Australia, particularly in the Mount Lofty Ranges koala population near Adelaide, is oxalate nephrosis in which calcium oxalate is deposited in the kidneys.² Koalas with oxalate nephrosis show signs of progressive renal dysfunction,³ such as polydipsia and loss of body condition, often requiring euthanasia on welfare grounds. Oxalate nephrosis has been reported to occur in 32% (27/85) of rescued wild koalas necropsied from 2012 to 2013 affected,¹ and 55% (28/51) of those between 2008 and 2010.² Oxalate nephrosis is an uncommon finding in koalas elsewhere, with <2% prevalence of oxalate nephrosis found in necropsied New South Wales koalas.⁴ The primary cause of oxalate nephrosis in Mount Lofty Ranges koalas remains unknown, but dietary⁵ and gut microbiota⁶ causes have been investigated previously and are thought to play secondary, rather than primary, roles.

It is thought that an underlying metabolic abnormality with a genetic basis exists in this population of koalas,² similar to the inherited disease primary hyperoxaluria in humans.⁷ A disease similar to primary hyperoxaluria has recently been reported in a closely related colony of the Australian native marsupial Gilbert's potoroo (*Potorous gilbertii*).⁸ The Mount Lofty Ranges koalas may be more at risk of genetic disease due to their reduced diversity⁹ following several population bottlenecks in their history.¹⁰

Koalas in South Australia primarily originate from Victoria. In the 1920's, eighteen koalas were translocated from French Island in Victoria to Kangaroo Island in South Australia in a bid to rescue the species from extinction following severe population declines in south-eastern Australia after European settlement.¹⁰ Koalas thrived on Kangaroo Island and were translocated to various regions in South Australia in the mid 1960's, including six to the Mount

Lofty Ranges.¹⁰ A recent genetic study has shown that South Australian koalas are closely related to those in Victoria and have lower genetic diversity than undisturbed northeastern populations.⁹ Therefore, if an inherited disease similar to primary hyperoxaluria was the cause of oxalate nephrosis in Mount Lofty Ranges koalas, it would be expected that Victorian koalas, from which these koalas originated, would also be affected. However, oxalate nephrosis has not previously been reported in Victorian koalas. This project aims to determine if oxalate nephrosis occurs in koalas across various regions of Victoria, including French Island.

Methods

Wildlife Health Victoria: Surveillance at the Melbourne University Veterinary School undertook general wildlife health surveillance, including free-ranging koalas, since 2008. During pathological examination kidney samples were collected from koalas that were found dead or had been euthanased on welfare grounds and fixed in 10% neutral buffered formalin. Koala origin, sex, estimated age using upper premolar tooth wear¹¹ or classification as juvenile, adult or senior, gross renal abnormalities, and reason for euthanasia were recorded. Kidneys were processed routinely into paraffin wax blocks which were sectioned and stained with haematoxylin and eosin. For each koala a single kidney section, including cortex, medulla and papilla, was examined microscopically to identify cases of oxalate nephrosis. Renal tissue sections from a total of 63 koalas were examined, including 49 free-ranging koalas necropsied between 2010 and 2013 at University of Melbourne, and an additional 14 koalas sourced from Victorian veterinary clinics in 2017.

Koalas necropsied as part of ongoing work with Wildlife Health Victoria: Surveillance at the Faculty of Veterinary and Agricultural Sciences, Werribee campus, University of Melbourne were examined under Victoria Department of Sustainability and Environment Wildlife Act 1975 and National Parks Act 1975, Flora and Fauna Permit 10005681, and Research Permits 10004605 and 10006948; and additional kidney samples with University of Adelaide Animal Ethics permit S-2016-169 and Department of Environment, Land, Water and Planning permit 10007656.

Results

A total of 63 koalas were sampled across Victoria, originating from the western regions (n=14), Cape Otway (n=13), Strzelecki region (n=12), Raymond Island (n=11), Somers (n=6), French Island (n=5), and central regions (n=2) (Fig. 1). Koalas ranged in age from one to 15 years old, with the majority being adults, and only four juveniles between 12 and 24 months old recorded. There were 25 males, 34 females, and sex was not recorded for four koalas.

Microscopic examination found oxalate nephrosis to affect the kidneys of 9 of 63 Victorian koalas (14.3%). Crystal deposition ranged from mild to moderate with renal tubules containing variable numbers of clear to yellow-coloured crystals organised in rosettes that were birefringent under polarised light (Fig. 2), and/or crystal ghosts formed by protein residue around crystals lost during processing. Affected tubules were dilated throughout the cortex and medulla, and epithelium necrotic adjacent to crystals (Fig. 3). Mixed intratubular inflammation associated with crystals, and/or multifocal mononuclear interstitial inflammation was

common, and cortical interstitial fibrosis evident in some cases. The nine affected koalas were 2/5 koalas (40%) from French Island; 4/14 western regions koalas (29%); 2/11 Raymond Island koalas (18%); and 1 of the thirteen Cape Otway koalas examined (8%) (Fig. 4). Both male and female koalas were affected.

Review of gross post mortem findings in these nine affected kidneys included observations of surface pitting, mottled cortex, pale cortex, streaks in cortex, and white foci in the medulla. Where available, clinical history for the koalas with oxalate nephrosis included poor body condition, lethargy and polydipsia, with the latter being specific for koalas with oxalate nephrosis and not recorded in other koalas. Other renal pathology observed in the cohort was minimal and included active pyelonephritis in three koalas from the Strzelecki region, and three cases of unilateral chronic nephritis in koalas, one from each of the Somers region, western region and Raymond Island. The post mortem findings for the kidneys in these six koalas included surface pitting, mottled cortex and pale cortex, and clinical history of these koalas included the presence of 'wet bottom', a common clinical sign of chlamydiosis.

Discussion

This study identified oxalate nephrosis in 14.3% of 63 koalas from across Victoria, all from French Island or populations with French Island origins. The histopathological features in Victorian koalas were as described previously in Mount Lofty Ranges koalas,² suggesting a common aetiology. Causes of oxalate nephrosis in other mammalian species include high dietary intake of oxalate or its precursors or absence of oxalate degrading gastrointestinal

micro-organisms; these have previously been investigated in Mount Lofty Ranges koalas^{5,6} and not been considered to be primary causes. It is currently hypothesised that oxalate nephrosis in Mount Lofty Ranges koalas may in fact have a genetic basis, based on their bottlenecked history of translocation via Kangaroo Island from French Island,¹⁰ which itself was founded with as few as two to three individuals from South Gippsland, Victoria in the 1880s.¹²⁻¹⁴

French Island showed 40% prevalence, which is similar to that reported in the Mount Lofty Ranges, albeit in only five koalas. Two Raymond Island koalas of 11 examined were also found to be affected; this island population was established in 1953 from 42 koalas originally from Philip Island.¹⁵ Philip Island in turn was populated by several koala introductions starting in the 1870s, from Bass River, Flinders, Gippsland and finally in 1923, with 50 koalas from French Island.^{12,16} This link between French Island and Raymond Island may explain the finding of cases of oxalate nephrosis in both locations. Likewise the western regions and Cape Otway received translocated koalas from French Island,^{13,14} and this may be the reason that oxalate nephrosis was found in koalas from these regions. No koalas in Somers were identified with oxalate nephrosis, despite their likely origin being the French Island translocations to nearby Sandy Point in the early 1970's;¹³ and the two central region koalas examined were also free of oxalate nephrosis despite receiving French Island inputs.¹⁴

None of the 12 Strzelecki koalas were affected by oxalate nephrosis. If oxalate nephrosis were to have a genetic basis, this population of koalas could be less likely to be affected by oxalate nephrosis based on their history, as they are believed to be a remnant population, with a history of koala translocations from French and Phillip Islands only into the surrounding Gippsland Plains.^{13,14} Studies of koalas in South Gippsland, which includes those

in the Strzelecki region, have shown this population to be genetically unique with increased diversity compared with other koalas in Victoria that are largely derived from French and Phillip Island translocations.^{13,14}

In conclusion, this study provides supporting evidence for an underlying genetic cause for oxalate nephrosis in Mount Lofty Ranges koalas as the disease was present in French Island and French Island- derived koala populations in Victoria. An inherited condition such as primary hyperoxaluria, in which abnormal hepatic enzyme activity results in overproduction of endogenous oxalate, should therefore be investigated in affected koalas. Targeted molecular studies are currently underway to investigate several candidate genes. In addition, Kangaroo Island koalas should be investigated for occurrence of oxalate nephrosis, as French Island koalas were translocated via Kangaroo Island to the Mount Lofty Ranges.

Acknowledgements

Wildlife Health Victoria: Surveillance is very grateful for financial support from Wildlife Health Australia, the H&A Bruce Bequest, the MA Ingram and Youngman Trusts, the Vizard and Hermon Slade Foundations, and Donors. Wildlife Health Victoria: Surveillance is also very grateful for collaborations and partnerships with wildlife carers, veterinary practitioners, members of Field Naturalists Clubs, Birdlife Australia, Landcare and other members of the Victorian community, and to staff of the Victorian Departments of Environment and Agriculture and Parks Victoria. Thanks also to Tracey Wilson and Dr James Cowell for assistance with tissue sampling.

References

1. Speight KN, Hicks P, Graham C et al. Necropsy findings of koalas from the Mount Lofty Ranges population in South Australia. *Aust Vet J* 2018;96:188-192.
2. Speight KN, Boardman W, Breed WG et al. Pathological features of oxalate nephrosis in a population of koalas (*Phascolarctos cinereus*) in South Australia. *Vet Pathol* 2013;50:299-307.
3. Speight KN, Haynes JI, Boardman W et al. Plasma biochemistry and urinalysis variables of koalas (*Phascolarctos cinereus*) with and without oxalate nephrosis. *Vet Clin Pathol* 2014;43:244-254.
4. Canfield PJ. A survey of urinary tract disease in New South Wales koalas. *Aust Vet J* 1989;66:103-106.
5. Speight KN, Breed WG, Boardman W et al. Leaf oxalate content of *Eucalyptus* spp. and its implications for koalas (*Phascolarctos cinereus*) with oxalate nephrosis. *Aust J Zool* 2013;61:366-371.
6. Speight KN, Houston-Francis M, Ebrahimie E et al. Oxalate-degrading bacteria, including *Oxalobacter formigenes*, colonise the gastrointestinal tract of healthy koalas (*Phascolarctos cinereus*) and those with oxalate nephrosis *Aust Vet J* 2019;97:166-170.
7. Lorenzo V, Torres A, Salido E. Primary hyperoxaluria. *Nefrologia* 2014;34:398-412.
8. Forshaw D, Horwitz AM, Ellard K et al. Hyperoxaluria, hyperglycoluria and renal oxalosis in Gilbert's potoroos (*Potorous gilbertii*). *Aust Vet J* 2017;95:250-258.

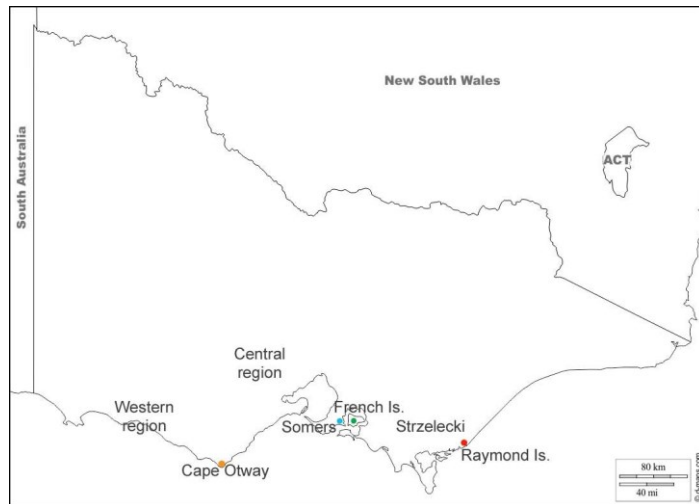
9. Kjeldsen SR, Raadsma HW, Leigh KA et al. Genomic comparisons reveal biogeographic and anthropogenic impacts in the koala (*Phascolarctos cinereus*): a dietary-specialist species distributed across heterogeneous environments. *Heredity* 2019;122:525-544.
10. Robinson AC. The koala in South Australia. In: Bergin TJ, editor. *The Koala: Proceedings of the Taronga symposium on koala biology, management and medicine, March 11-12, 1976*. Zoological Parks Board, Sydney, 1978:132-143.
11. Martin R, Handasyde K. *The koala: Natural history, conservation and management*. 2nd edn. University of New South Wales Press, Sydney, 1999.
12. Lewis F. The koala in Victoria. *Victorian Nat* 1934;51:73-76.
13. Wedrowicz F, Mosse J, Wright W, Hogan F. Genetic structure and diversity of the koala population in South Gippsland, Victoria: a remnant population of high conservation significance. *Conserv Genet* 2018;19:713-728.
14. Taylor AC, Graves JM, Murray ND et al. Conservation genetics of the koala (*Phascolarctos cinereus*): low mitochondrial DNA variation amongst southern Australian populations. *Genet Res* 1997;69:25-33.
15. Mitchell PJ, Bilney R, Martin RW. Population structure and reproductive status of koalas on Raymond Island, Victoria. *Aust Wildl Res* 1988;15:511-514.
16. Backhouse G, Crouch A. Koala management in the Western Port region, Victoria. In: Lee AK, Handasyde KA, Sanson GD, editors. *Biology of the Koala*. Surrey Beatty & Sons Pty Ltd, Chipping Norton, New South Wales, 1991:313-317.

Figure 1. Origins of koalas included in study of oxalate nephrosis in Victoria: Western region (n=14), Cape Otway (n=13) [orange], Strzelecki (n=12), Raymond Island (n=11) [red], Somers (n=6) [blue], French Island (n=5) [green], and central region (n=2).

Figure 2. French Island koala with oxalate nephrosis, showing a) oxalate crystals present in renal pelvis of kidney that are b) birefringent with polarised light.

Figure 3. French Island koala with oxalate nephrosis, showing severe tubule dilation in the medulla.

Figure 4. Number of koalas affected by oxalate nephrosis in various regions of Victoria.



AVJ_12986_Fig 1 regions.jpg

