



ALMA MATER STUDIORUM
UNIVERSITÀ DI BOLOGNA

ARCHIVIO ISTITUZIONALE DELLA RICERCA

Alma Mater Studiorum Università di Bologna Archivio istituzionale della ricerca

Video-polysomnography procedures for diagnosis of rapid eye movement sleep behavior disorder (RBD) and the identification of its prodromal stages: Guidelines from the International RBD Study Group

This is the final peer-reviewed author's accepted manuscript (postprint) of the following publication:

Published Version:

Cesari, M., Heidbreder, A., St Louis, E.K., Sixel-Döring, F., Bliwise, D.L., Baldelli, L., et al. (2022). Video-polysomnography procedures for diagnosis of rapid eye movement sleep behavior disorder (RBD) and the identification of its prodromal stages: Guidelines from the International RBD Study Group. *SLEEP*, 45(3), 1-20 [10.1093/sleep/zsab257].

Availability:

This version is available at: <https://hdl.handle.net/11585/900665> since: 2022-11-08

Published:

DOI: <http://doi.org/10.1093/sleep/zsab257>

Terms of use:

Some rights reserved. The terms and conditions for the reuse of this version of the manuscript are specified in the publishing policy. For all terms of use and more information see the publisher's website.

This item was downloaded from IRIS Università di Bologna (<https://cris.unibo.it/>).
When citing, please refer to the published version.

(Article begins on next page)

Video-polysomnography procedures for diagnosis of rapid eye movement sleep behavior disorder (RBD) and the identification of its prodromal stages: Guidelines from the International RBD Study Group

Matteo Cesari^{1, #}, Anna Heidebreder^{1, #}, Erik K. St. Louis^{2, 3}, Friederike Sixel-Döring^{4, 5}, Donald L. Bliwise⁶, Luca Baldelli⁷, Frederik Bes⁸, Maria Livia Fantini⁹, Alex Iranzo¹⁰, Stine Knudsen-Heier¹¹, Geert Mayer^{5, 12}, Stuart McCarter², Jiri Nepozitek¹³, Milena Pavlova¹⁴, Federica Provini^{7, 15}, Joan Santamaria¹⁰, Jun-Sang Sunwoo¹⁶, Aleksandar Videnovic¹⁷, Birgit Högl¹, Poul Jennum¹⁸, Julie A.E. Christensen^{18, 19, §}, Ambra Stefani^{1, §} for the International RBD Study Group

¹Department of Neurology, Medical University of Innsbruck, Austria

²Mayo Center for Sleep Medicine, Departments of Neurology and Medicine, Division of Pulmonary and Critical Care Medicine, Mayo Clinic College of Medicine and Science, Rochester, Minnesota, USA

³Department of Research, Mayo Clinic Health System Southwest Wisconsin, La Crosse, Wisconsin, USA

⁴Paracelsus Elena Klinik, Kassel, Germany

⁵Department of Neurology, Philipps-University, Marburg, Germany

⁶Sleep Center, Department of Neurology, Emory University School of Medicine, Atlanta, Georgia, USA

⁷Department of Biomedical and Neuromotor Sciences, University of Bologna, Bologna, Italy

⁸Clinic for Sleep- and Chronomedicine, St. Hedwig-Krankenhaus, Berlin, Germany

⁹NPsy-Sydo, Clermont-Ferrand University Hospital, Neurology Department, Université Clermont Auvergne, Clermont-Ferrand, France

¹⁰Sleep Disorders Center, Neurology Service, Hospital Clinic Barcelona, Universitat de Barcelona, IDIBAPS, Barcelona, Spain

¹¹Norwegian Center of Expertise for Neurodevelopmental Disorders and Hypersomnias (NevSom), Department of Rare disorders, Oslo University Hospital, Norway

¹²Hephata Klinik, Schwalmstadt, Germany

¹³Department of Neurology and Center of Clinical Neuroscience, First Faculty of Medicine, Charles University, General University Hospital, Prague, Czech Republic

¹⁴Department of Neurology, Brigham and Women's Hospital; Division of Sleep Medicine, Harvard Medical School, Boston, USA

¹⁵IRCCS, Istituto delle Scienze Neurologiche di Bologna, Bologna, Italy

¹⁶Department of Neurosurgery, Seoul National University Hospital, Seoul, South Korea

¹⁷Department of Neurology, Massachusetts General Hospital, Harvard Medical School, Boston, Massachusetts, USA

¹⁸Danish Center for Sleep Medicine, Department of Clinical Neurophysiology, Rigshospitalet Glostrup, Denmark

¹⁹Department of Health Technology, Technical University of Denmark, Lyngby, Denmark

#: shared first authorship

§: shared last authorship

Corresponding author:

Ambra Stefani

Medical University Innsbruck

Department of Neurology

Anichstrasse 35

6020 Innsbruck, Austria

ambra.stefani@i-med.ac.at

Tel: + 43 50 504 23811

Current word count: 6064

Abstract word count: 237 (max 250)

Statement of significance word count: 120 (max 120)

Number of tables: 4

Number of figures: 9

Number of references 96

ABSTRACT

Video-polysomnography (v-PSG) is essential for diagnosing rapid eye movement (REM) sleep behavior disorder (RBD). Although there are current American Academy of Sleep Medicine standards to diagnose RBD, several aspects need to be addressed to achieve harmonization across sleep centers. Prodromal RBD is a stage in which symptoms and signs of evolving RBD are present, but do not yet meet established diagnostic criteria for RBD. However, the boundary between prodromal and definite RBD is still unclear.

As a common effort of the Neurophysiology Working Group of the International RBD Study Group, this manuscript addresses the need for comprehensive and unambiguous v-PSG recommendations to diagnose RBD and identify prodromal RBD. These include: (1) standardized v-PSG technical settings; (2)

specific considerations for REM sleep scoring; (3) harmonized methods for scoring REM sleep without atonia; (4) consistent methods to analyze video and audio recorded during v-PSGs and to classify movements and vocalizations; (5) clear v-PSG guidelines to diagnose RBD and identify prodromal RBD.

Each section follows a common template: The current recommendations and methods are presented, their limitations are outlined, and new recommendations are described. Finally, future directions are presented.

These v-PSG recommendations are intended for both practicing clinicians and researchers. Classification and quantification of motor events, RBD episodes and vocalizations are however intended for research purposes only. These v-PSG guidelines will allow collection of homogeneous data, providing objective v-PSG measures and making future harmonized multicentric studies and clinical trials possible.

Keywords: IRBDSG, iRBD, RWA, iRWA, prodromal RBD, PSG.

STATEMENT OF SIGNIFICANCE

Rapid eye movement (REM) sleep behavior disorder (RBD) has gained increasingly relevance, as its isolated form (isolated RBD) is an early stage alpha-synucleinopathy. Moreover, a prodromal RBD phase has been described. A definite identification of these conditions requires video-polysomnography (v-PSG). Despite the existence of international v-PSG diagnostic standards for RBD, some particular aspects are not addressed or subject to interpretation. Additionally, prodromal RBD is still not clearly defined. For these reasons, different centers apply slightly different methods. To allow future harmonized multicentric studies and clinical trials, unambiguous v-PSG guidelines by the Neurophysiology Working Group of the International RBD Study Group are provided here. These guidelines will allow harmonization of diagnostic methods and enable a significant research advancement in the field of RBD and its prodromal phase.

1. INTRODUCTION

Rapid eye movement (REM) sleep behavior disorder (RBD) is characterized by motor behaviors, jerks and/or vocalizations during REM sleep, often associated with REM sleep-related dream content.¹ According to current knowledge, RBD can manifest as an isolated form (isolated RBD, iRBD, also called idiopathic RBD), which is recognized as an early stage of α -synucleinopathy,² or may also be associated with other diseases, including e.g. overt α -synucleinopathy (Parkinson's disease (PD), dementia with Lewy bodies (DLB), multiple system atrophy)^{3,4} and narcolepsy.⁵ Recent evidence suggests that RBD does not have a sudden onset, but is preceded by a prodromal stage.^{2,6}

Currently accepted standards to diagnose RBD are reported in the third edition of the International Classification of Sleep Disorders (ICSD-3, see Table S1 in Supplemental Material).⁷ Diagnostic criteria specify the need to document REM sleep without atonia (RWA, also known as RSWA), and the current internationally accepted rules for RWA quantification are presented in the American Academy of Sleep Medicine (AASM) Manual for Scoring of Sleep and Associated Events version 2.6.⁸ These however do not report cut-offs, so that RWA definition (i.e. which amount of EMG activity during REM sleep is considered "excessive") is not clear.

As RBD clinically manifests through complex motor behaviors and/or vocalizations, some studies have analyzed and classified them. Methods used have been reviewed elsewhere.⁹ However, no internationally recognized rules or recommendations are available for scoring and classifying movements and vocalizations in the context of RBD.

Prodromal RBD has been defined as a stage in which symptoms and signs of evolving RBD are present, but do not yet meet established diagnostic criteria for RBD.^{2,6} However, the boundary between prodromal and definite RBD is still unclear.

Therefore, several aspects/issues need to be addressed in order to harmonize diagnosis of RBD and identification of prodromal RBD. These include: (1) standardized video-polysomnography (v-PSG) technical settings; (2) specific considerations for REM sleep scoring in the context of RBD and prodromal RBD; (3) harmonized methods for scoring RWA; (4) consistent methods to analyze video and audio recorded during v-PSGs and to classify the types of movements and vocalizations; (5) clear v-PSG guidelines to diagnose RBD and identify prodromal RBD.

These guidelines are the result of a common effort of the Neurophysiology Working Group of the International RBD Study Group (IRBDSG) and address the outlined needs to propose comprehensive and unambiguous v-PSG recommendations to diagnose RBD and identify prodromal RBD. They are intended for both practicing clinicians and researchers (with the exception of classification and quantification of motor events, RBD episodes and vocalizations, which are intended for research purposes only). Different topics are addressed in each section following a common template: The current recommendations and methods are presented, their limitations are outlined, and new recommendations are described. Finally, future directions are presented in the last section.

2. TECHNICAL REQUIREMENTS FOR V-PSG RECORDING

Current recommendations: The AASM manual version 2.6 provides a list of technical v-PSG recommendations concerning recording of electrophysiological signals, which should be followed by sleep centers.⁸

Limitations of current recommendations: The AASM manual version 2.6 aims to provide comprehensive technical recommendations for recording of sleep and different sleep-associated events.⁸ However, specific considerations are necessary in the context of RBD and prodromal RBD. As RWA is a crucial aspect of both conditions, electromyography (EMG) signals are of fundamental importance. The required minimal sampling frequency of 200 Hz for EMG signals and filtering between 10 and 100 Hz does not include the full spectrum of surface EMG activity, as the surface EMG contains most of its power between 5 and 500 Hz¹⁰. Twitches and muscular activity with high frequency might therefore be missed when filtering at 100 Hz.

Furthermore, while the ICSD-3 refers to quantification of RWA based on the SINBAR (Sleep Innsbruck Barcelona) method (i.e. combining "any" activity in the chin and phasic activity in the bilateral flexor digitorum superficialis (FDS) muscles)⁷, the AASM manual version 2.6 indicates EMG recording of the upper extremities as optional, either in the FDS muscles or in the extensor digitorum communis (EDC),⁸ although there is no systematic data on the usefulness of EMG of the EDC muscle in the context of RBD diagnosis and identification of prodromal RBD.

Finally, there are no specific recommendations concerning video and audio recording, which plays a fundamental role in the evaluation of REM-sleep related behaviors.

Recommendations for technical requirements: In the context of RBD and prodromal RBD, we recommend the following technical requirements **in addition** to the ones recommended by the AASM manual version 2.6⁸:

- EMG recording:
 - Set EMG sampling rates at minimum 500 Hz (acceptable) and optimally 1000 Hz (recommended)¹¹;
 - Filtering between 5 and 500 Hz allows capturing the full spectrum of surface EMG activity. To avoid low-frequency artefacts, we recommend to have a high-pass cut-off of at least 10 Hz, as proposed by the AASM⁸. No specific low-pass cut-off is recommended, in order to capture most of the EMG spectrum.
 - Record EMG signals with a minimal digital resolution of 16 bits per sample¹¹;
 - EMG recording in the upper extremities is recommended and should be recorded as follows: Surface electrodes are placed longitudinally and symmetrically in the middle of the FDS muscle, so that they are 2-3 cm apart (Fig. 1a). Both arms are monitored with separate channels for each arm. To document appropriate position of surface EMG electrodes on the FDS muscle, the patient is asked to flex digits II to IV at the base, while avoiding bending the distal two joints, and keeping digit V extended (Fig. 1b).
- Video recording:
 - Recorded video must be synchronized with PSG, and whenever possible should have a frame rate of at least 25 frames per second;
 - The resolution should be high enough to allow off-line zooming without loss of quality (Fig. 2)¹²;
 - The camera must be sensitive to infrared (IR) lights¹²; the IR light is not directed towards the bed, but IR illumination is achieved indirectly;
 - The camera should have autofocus¹²;
 - The camera should have automatic and rapid adjustment of the lens iris to avoid loss of images when there is a sudden change of light in the room¹²;
 - The zoom and field of view can be remotely controlled¹²;
 - The camera must be mounted on the wall or on the ceiling and must frame the entire bed with a wide enough angle. The patient lying on the bed should be visualized from head to feet symmetrically (i.e. avoid body distortion). The recommended positions of the camera are shown in Fig. 3.
- Audio recording
 - Omnidirectional environmental microphone positioned optimally to record vocalizations.
 - Mono microphone should have a sampling frequency of at least 8 kHz and resolution of at least 16 bits.
- Room temperature
 - Individually adjustable, so that it is comfortable for the patient, and allows sleeping without heavy and thick blankets, to optimize recognition of movements.

[Insert here Figs. 1, 2 and 3]

3. REM SLEEP SCORING

Current recommendations and methods: According to the AASM manual version 2.6, REM sleep scoring in 30-second epochs is defined by three features: low amplitude, mixed frequency electroencephalographic (EEG) activity; low chin EMG tone for the majority of the epoch; and rapid eye movements⁸.

However, in RBD and overt synucleinopathies (with or without RBD), as well as in other conditions e.g. narcolepsy, muscle tone does not consistently decrease during REM sleep and may be intermittently or persistently elevated, constituting RWA. For this reason, the AASM manual version 2.6 (note 4

under RWA scoring) states: “Epochs containing RWA with sustained chin activity [...] may not meet criteria for stage R[EM] but in these cases, the epoch can still be scored as stage R[EM] if other criteria for stage R[EM] are met or if the epoch is contiguous with an epoch scored as stage R[EM]”⁸.

For quantification of RWA, some groups have proposed rules to select REM sleep periods to be analyzed within 30-s epochs of REM sleep. The most commonly used method for selection of REM sleep periods is based on 3-s mini-epochs. The onset of a REM sleep period is determined by the occurrence of a rapid eye movement. A REM sleep period ends either when K-complexes, sleep spindles or EEG signs of arousals are present, or when rapid eye movements are absent for 3 consecutive minutes from the last rapid eye movement^{13–15}.

Limitations of current recommendations and methods: The recommendations for scoring REM sleep in 30-s epochs described in the AASM manual version 2.6⁸ are comprehensive. However, it can be difficult to apply them in special cases, e.g. iRBD patients can present EEG slowing, similarly to patients with overt alpha-synucleinopathies^{16–23} or patients with Alzheimer’s disease.^{24,25} These electrophysiological changes can reduce inter-rater agreement^{26–28}. In these particular cases, so far there is no recommendation to use information from synchronized audiovisual recording, which might be of help to identify REM sleep, although this has been suggested previously.²⁹

Concerning the identification of discrete REM sleep periods (i.e., usually 3-s mini-epochs within 30-s REM sleep epochs used for quantification of RWA), different groups have applied the same rules^{13,14,30–32}, but unanimous recommendations are lacking.

Recommendations for REM sleep scoring: Score REM sleep according to the AASM recommendations⁸. When REM sleep cannot be scored by applying the AASM recommendations alone, we suggest the following:

- REM sleep should be scored based on characteristic findings on at least two of the following four parameters: EEG, EOG, EMG and synchronized audiovisual recordings.
- Presence of sawtooth waves in central EEG regions and absence of typical landmarks of non-REM (NREM) sleep such as spindles or K-complexes can be helpful.
- In some cases, EEG alpha activity can be present during REM sleep, even in such an amount that distinction with wakefulness might become difficult. In these cases, we suggest: 1. To compare this alpha activity with those of the same subject during baseline wakefulness; 2. To use additional information from audiovisual recording, as the behavioral pattern might be the clue to distinguish REM sleep from wakefulness.²⁹
- In the absence of clear patterns otherwise typical for REM sleep, the presence of excessive irregular phasic muscle activity may be of help to identify periods of REM sleep. Using the limbs together with the mental EMG is helpful.
- In the synchronized audiovisual recording, patients develop characteristic movements or vocalizations^{9,33} that might be the clue to identify REM sleep.

In order to score REM sleep periods (i.e. 3-s mini-epochs within 30-s REM sleep epochs) for RWA quantification, we recommend the following steps:

1. Score REM sleep in 30-s epochs according to AASM recommendations and, when necessary, according to the suggestions outlined above.
2. Score REM sleep periods:
 - Identify the start of a REM sleep period as the beginning of a 3-s mini-epoch where a rapid eye movement is present (Fig. 4). This rapid eye movement has to be included in a 30-s epoch scored as REM sleep or within the 15 seconds preceding a 30-s epoch scored as REM sleep.
 - Identify the end of a REM sleep period as I) the end of a 3-s mini-epoch before a 3-s mini-epoch including a K-complex, a sleep spindle, EEG signs of arousals; or II) after three consecutive minutes of scored REM sleep without rapid eye movements. A REM sleep period can end up to 15 seconds after the end of the last 30-s epoch scored as REM sleep (Fig. 5).

[Insert here Figs. 4 and 5]

4. RWA QUANTIFICATION

4.1 Manual quantification

Current recommendations and methods: The AASM manual version 2.6 reports the rules for manual scoring of RWA (see Table S2 in Supplemental Material)⁸. The ICSD-3 criteria⁷ refer to the SINBAR (i.e. “any” chin and/or bilateral phasic FDS muscular activity) cutoff for 30-s epochs.¹⁴

Different manual methods for scoring RWA have been described and validated utilizing various definitions of phasic, tonic, “any” and mixed muscle activity in the chin and/or limbs (Table 1).

Table 2 shows the cutoffs of the most commonly used validated RWA indices and their sensitivity and specificity. The SINBAR group reported that the best muscle combination for diagnosis of RWA is any EMG activity in the chin and/or phasic EMG activity in the FDS.¹⁴ The Mayo group showed that taking into account also phasic muscle burst duration increases diagnostic accuracy.^{30,31} Recently, the Prague group described mixed chin EMG activity as the presence of tonic or any EMG activity with superimposed phasic activity within the same 3-second mini-epoch.³²

Limitations of current recommendations and methods: Rules for scoring of RWA (chin tonic, phasic and any, and phasic EMG activity in the limbs) are defined in the AASM manual⁸, although single groups used slightly different rules (see Table 1). Cutoffs are not mentioned in the AASM manual⁸, whereas in

the ICSD-3 the SINBAR cutoffs for 30-s epochs are suggested⁷.

No consensus is available on the minimum amount of REM sleep that is needed for quantifying RWA. Furthermore, point 2c of the AASM criteria (Table S2 in Supplemental Material) allows scoring of RWA based exclusively on tibialis anterior (TA) EMG activity. However, it has been shown that phasic EMG activity in the TA is less specific for RWA, and the TA may contain other EMG activity (e.g. PLMS)^{14,31}.

Finally, it has been shown that the chin muscle may be affected by artefacts (including respiratory artefacts)³⁴, and most manual methods have been validated only in subjects with low apnea-hypopnea index (AHI)^{13,14,35-37}. However, there is no consensus on whether or how to evaluate RWA in subjects with high AHI. Moreover, most of the studies had inclusion and exclusion criteria based on AHI during total sleep time, not only during REM sleep.

Recommended methods for manual RWA quantification:

- Recommended (based on the evidence that upper extremities EMG increases sensitivity)^{14,38,39}:
 - REM sleep scoring in 3-s mini-epochs (i.e. REM sleep periods, see Section 3) followed by quantification of chin and FDS EMG activity (“any” chin and/or phasic FDS EMG activity according to SINBAR scoring method).
- Acceptable:
 - Quantification of chin EMG activity only:
 - REM sleep scoring in 30-s epochs or 3-s mini-epochs followed by quantification of chin tonic, phasic and “any” EMG activity (according to SINBAR¹⁴ or Mayo^{30,31} scoring methods^[a]).
 - Quantification of chin and FDS EMG activity in 30-s epochs:
 - REM sleep scoring in 30-s epochs followed by quantification of chin and FDS EMG activity (“any” chin and/or phasic FDS EMG activity according to SINBAR scoring method¹⁴)

Note: Depending on the scoring method used, the respective published cutoffs apply (methods and respective cutoffs are reported in Table 2).

- Further recommendations:
 - At least five minutes of REM sleep are required for RWA quantification, i.e. at least five minutes of REM sleep periods (if scoring in 3-s mini-epochs) or at least 10 REM sleep epochs (if scoring in 30-s epochs);
 - The TA channels should be included in the recording, but not be used for RWA quantification, as they present other EMG activity, e.g. periodic limb movements (PLMs)^{40,41} and fragmentary myoclonus⁴², partially overlapping with RWA. The TA is therefore less specific for RWA quantification^{14,31}.
 - In subjects with high AHI (>15/h)⁴³ during REM sleep, sufficient treatment of the sleep apnea may be necessary before scoring RWA^[b], as treatment with positive airway pressure does not induce artefact in the chin or impact RWA³⁰.

4.2 Automated quantification

Current recommendations and methods: AASM manual version 2.6 has not recommended any automated method to score RWA.⁸ Table 3 summarizes automatic methods that have been proposed in the literature. Among them, the REM atonia index (RAI) is the most validated.^{30,31,36,37,44} The only comparative study including some of these methods showed that RAI is the most sensitive for RBD identification when scoring EMG activity in the chin and/or TA.⁴⁵ Only one automatic method quantifies RWA combining chin and the upper limbs³⁴, and was not part of the previously cited comparative study.

Limitations of current methods: Despite description of current methods is available in scientific manuscripts, the originally developed software are included in commercial products or not freely available (i.e. the code cannot be downloaded). Furthermore, many of the methods require coding expertise to run the software routines. Only RAI and a machine-learning method have been validated in different cohorts.^{30,31,36,37,44,46,47} Validation across cohorts and centers is essential to document robustness to inter-clinical variability.

Recommendations for automated RWA quantification:

- Currently it is not possible to recommend any single method for automatic scoring of RWA.

In order to allow sharing of methods and ease validation across cohorts, we suggest that in the future software for automated RWA analysis should be made freely available and should be designed so that they follow these specifications:

- They can read inter-operable v-PSG files (e.g. EDF+/EDF) recorded according to the recommendations in Section 2;
- Users should be able to select the areas and channels to be analyzed;
- Software should have a simple inter-operable user interface and provide results clearly;
- An anonymized inter-operable file including a v-PSG recording should be provided together with the software to check whether it is correctly installed and executed.
- Manual correction should be possible.

4.3 Identification of artefacts and EMG activity not to be included in RWA quantification

Current recommendations and methods: Both AASM and ICSD-3 do not define artefacts on EMG signals which may bias RWA quantification. The AASM manual only recommends removing from the TA EMG signal limb movements (LMs) which are part of PLM series, but does not provide guidance on how to

discriminate RWA from PLMs during REM sleep.⁸

The different methods proposed for manual and automatic RWA quantification (Tables 1 and 3) usually contain brief and generic information about how to identify artefacts (e.g. due to respiratory events like snoring or apnea-induced arousals, or electrocardiogram (ECG)) and which EMG activity should be excluded from RWA quantification (like LMs in PLM series or bruxism). Some authors applied artefact correction when selecting 3-s mini-epochs of REM sleep (i.e. REM sleep periods) to be analyzed.^{13,14,30–32,35}

Limitations of current recommendations and methods: In the current AASM scoring recommendations, neither an artefact definition nor rules for artefacts removal are provided. In the literature, a clear definition of artefact is also lacking. Descriptions of methods to remove artefacts are inconsistent and instructions vary significantly and usually lack specific guidance. Currently used artefact removal methods have not been assessed in systematic studies nor have been evaluated in comparative analyses across different labs. Moreover, scoring of RWA is classically based on EMG signal alone, without taking into account concurrent analyses of video recording. If videographic interpretation of movements during REM sleep would be useful for artefact correction, has not been proposed nor evaluated so far.

Recommendations for identification of artefacts and EMG activity not to be included in RWA quantification:

In the context of RWA quantification, we recommend:

- To define artefacts as spurious observations resulting from preparatory or investigative procedures⁴⁸ (e.g. electrode artefact, Fig. 6) and bursts in the EMG channel due to intrusion of other physiological events (e.g. respiration, ECG, Figs. 7 and 8)^[c]. These should not be included in RWA quantification.
- To exclude from RWA quantification other motor events which are described in the current version of the AASM manual⁸ or in other internationally accepted criteria (e.g. LM in PLM series).

As comparative studies are lacking, recommendations for removal of artefacts and EMG activity not to be included in RWA quantification are based on expert opinion and might be modified in the future, once data on this topic will become available.

[Insert here Figs. 6, 7 and 8]

5. VIDEO AND AUDIO SCORING

Video and audio inspection is mandatory for diagnosing RBD (see Section 6). Classification and quantification of motor events, RBD episodes and vocalizations as described below are **not** required for diagnosing RBD, but recommended for research purposes.

Current recommendations and methods: ICSD-3 describes typical behaviors characterizing RBD as punching, kicking, jumping/falling out of bed, screaming, laughing, etc.⁷ In the earlier versions of the ICSD also “excessive limb or body jerking”,⁴⁹ as reported in the original description of RBD by Schenck et al⁵⁰, was listed among the diagnostic criteria to be documented during v-PSG,^{49,51} but this was later abandoned,^{7,52} although research shows that these limb and body jerks are a major hallmark and can be particularly useful to diagnose RBD.^{2,33}

First attempts to systematically classify REM sleep behaviors based on videographic analysis used categories of “simple” vs “complex” or “mild”, “moderate” and “severe” movements, or compared intra-individually RBD movement sequences to movements during wakefulness.^{53–57} Further studies^{33,58,59} introduced also the dimensions of frequency, duration and topographical distribution of REM-associated motor events, as well as intelligibility of vocalizations. This classification system is shown in Fig. 9. A modified version of this classification system, including also a composited measure of category and severity, has been recently used to measure the outcome of a double-blind randomized study with melatonin.⁶⁰ A further study used additional categories to classify movements, such as speed, self-orientation and use of the bed environment.⁶¹ Video analysis showed that minor limb jerks and elementary movements are by far the most common movements during REM sleep in RBD, whereas complex and violent behaviors are much less frequent.^{33,58} Another important finding was that minor jerks are a stable finding with low inter-night variability, while large inter-night variability was found for complex or violent events.^{33,62}

[Insert here Fig. 9]

The RBD severity scale (RBDSS)⁶² has been introduced for clinical purposes. It rates motor events recognized in the v-PSG on a scale from 0 to 3 according to movements' localization. Vocalizations are rated as absent or present (Table 4). The final RBD severity score is determined by the most severe episode observed during the night.

Most recent approaches for detection of movements during REM sleep employ automatic methods based on 3D images.⁶³

Limitations of current recommendations and methods: The current AASM recommendations and scoring criteria do not propose any method to describe and classify movements and vocalizations in REM sleep. A unanimous definition of motor events indicative of RBD does not exist, as ICSD-3 mentions REM sleep related vocalizations and/or complex behaviors, without defining criteria⁷. The simple, short, jerky, sometimes repetitive movements typical of RBD do not qualify for RBD diagnosis in the most recent ICSD versions^{7,52}. There is currently no consent on the duration of motor events and inter-event intervals. Comfort movements and arousal-associated movements are commonly excluded when analyzing movements during REM sleep, however no guidelines are

available. Moreover, there is no consent on how to deal with limb movements and movements associated with respiratory events. A common limitation of all the currently proposed visual methods is that they all depend on the scrutiny of the reviewer.

Recommendations for video and audio scoring: To harmonize video and audio scoring during REM sleep, we propose the following recommendations.

- General recommendations:
 - All video material recorded during REM sleep, independently from EMG activity, should be analyzed in detail. If only episodes with EMG activity are analyzed, motor activity involving muscles that are not recorded by surface EMG will be missed.
 - Epochs where the patient is not sufficiently visible should be registered as “videographically not scorable”. If during these epochs a movement is nevertheless visible, it should be scored but limited visibility should be reported.

- Definition of motor events and RBD episodes:

Motor events:

- A motor event is defined as any type of movement which is visible from the video.
- An inter-event interval of 3 seconds is proposed for separating motor events. Also, there should be no vocalization during these 3 seconds.

RBD episodes:

- One RBD episode consists of one or more motor events and/or vocalizations that can be interpreted as related to dream enactment. Thus, this includes jerky, sudden and complex movements with or without vocalizations.
- An inter-episode interval of 30 seconds with no motor events or vocalization is proposed for separating RBD episodes.

- Motor events and vocalizations to be excluded from scoring: comfort movements, movements or vocalizations related to respiratory events and typical periodic leg movements should be excluded from the video and audio analysis in the context of RBD and prodromal RBD.

- Description of motor events, RBD episodes and vocalization.

The following parameters should be reported:

- Duration
- Frequency (per 10 minutes of REM sleep)
- Topography (for motor events and RBD episodes):
 - body part involved, i.e. face/head, neck, upper extremities, trunk, lower extremities, whole body
 - body region: proximal, distal or axial
 - spatial distribution: focal, segmental, multifocal, generalized
 - laterality (unilateral, bilateral)

It is possible to state that topography is indeterminate, if the movement is not visible enough (due to e.g. position of the subject or covering with blankets).

- Visibility (visible or limited visibility)

- Classification of motor events and RBD episodes:

- Category:
 - Simple minor movements: small excursions that usually would not be noticed by a sleeping bed partner, e.g. small movements or stereotyped movements with low amplitude.
 - Simple major movements: simple movements with higher amplitude or intensity.
 - Complex movements: movements showing a complexity of action, involving more muscle groups simultaneously, e.g. apparent “acting out” of dream contents.
- Severity:
 - Mild: small movements without risk of injury.
 - Moderate: potential risk of mild injuries;.
 - Severe: forceful, vigorous or violent movements in which the patient could potentially hurt or severely injure himself and/or the bed partner (e.g., kicking or punching)

- Classification of vocalizations:

- Category:
 - Simple minor vocalizations: no comprehensible speech, no emotional component.
 - Simple major vocalizations: single comprehensible words, without an emotional component (e.g. single words, apparently neutral emotional state).
 - Complex vocalizations: comprehensible speech (e.g. talking), or vocalizations with an emotional component (e.g. crying, laughing, yelling, swearing, screaming, singing).
- Severity:
 - Mild: simple low-voiced vocalizations without an emotional component.
 - Moderate: normal-voiced vocalizations (e.g. talking); vocalization with some emotional component (e.g. laughing).

- Severe: loud-voiced vocalizations (e.g. shouting) or vocalizations with a clear emotional component (e.g., crying, yelling, swearing, screaming, singing).

If motor events/RBD episodes and vocalization occur simultaneously, classification of category and severity should be based on the most complex/severe one.

- Overall quantification of motor events, RBD episodes and vocalizations:
 - Recommended: A composite measure of motor events, RBD episodes and vocalization frequency and severity can be derived by weighting each of them by their severity, with mild ones receiving a weight of one, moderate ones a weight of 5, and severe ones a weight of 10. The composite score is the sum of products across all behaviors and scaled to a function of time to compute the severity-weighted RBD behaviors per 10 minutes of REM sleep. This comprehensive and thorough method is especially recommended for scientific and comparative purposes.
 - Acceptable: Modified RBDSS⁶², without taking into account the presence of RWA (i.e. “no visible motor activity” is scored as “0.-“ in “Motor Events” – Table 4, independently from the presence or not of RWA).

These guidelines are based on expert consensus. Utility of the proposed measures of severity need to be validated in future studies.

6. V-PSG RECOMMENDATIONS FOR REM SLEEP BEHAVIOR DISORDER DIAGNOSIS

Current recommendations and methods: Diagnosis of RBD requires repeated episodes of sleep related vocalization and/or complex motor behaviors occurring during REM sleep and the polysomnographic demonstration of RWA.⁷ Technical requirements as well as guidelines on scoring of REM sleep and RWA are listed in the AASM manual version 2.6.⁸ Several groups used different methods for RWA quantification (see Section 4).

Limitations of current recommendations and methods: As discussed in previous sections, technical requirements, methods for RWA quantification and for video and audio evaluation are heterogeneous and not harmonized (see Sections 2, 4 and 5). Scoring of REM sleep according to the AASM manual can be difficult in special cases (see Section 3).

V-PSG recommendations for RBD diagnosis (all following points are required)^{[d][e]}:

- V-PSG is mandatory to diagnose RBD, following technical requirements for sleep recording described in Section 2 and scoring REM sleep as described in Section 3 and in the AASM manual version 2.6.⁸
- RWA must be demonstrated, according to the quantification methods described in Section 4.1 and summarized below:
 - Recommended (based on the evidence that upper extremities EMG increases diagnostic accuracy)^{14,38,39}:
 - REM sleep scoring in 3-s mini-epochs (i.e. REM sleep periods, see Section 3) followed by quantification of chin and FDS EMG activity (“any” chin and/or phasic FDS EMG activity according to SINBAR scoring method).
 - Acceptable:
 - Quantification of chin EMG activity only:
 - REM sleep scoring in 30-s epochs or 3-s mini-epochs followed by quantification of chin tonic, phasic and “any” EMG activity (according to SINBAR¹⁴ and Mayo^{30,31} scoring methods^[f]).
 - Quantification of chin and FDS EMG activity:
 - REM sleep scoring in 30-s epochs followed by quantification of chin and FDS EMG activity (“any” chin and/or phasic FDS EMG activity according to SINBAR scoring method)

Depending on the scoring method used, the respective published cutoffs apply (methods and respective cutoffs are reported in Table 2).

- Video/audio recording during REM sleep captures at least one RBD episode, consisting of movements and/or vocalizations that can be interpreted as related to dream enactment (see Section 5).

Behavioral classification and quantification as described in Section 5 is **not** required for diagnosing RBD.

- To exclude RBD, at least 15 minutes of consecutive epochs scored as REM sleep (see Section 3) without any RBD episode is required (expert opinion).

7. V-PSG RECOMMENDATIONS FOR IDENTIFICATION OF PRODROMAL RBD

Identification of prodromal RBD as described below is recommended. As few data on prodromal RBD are available by now, these recommendations are based mainly on expert opinion and might be changed once more evidence will be available in the future. We recommend identification of prodromal RBD for both clinical and research purposes, both in its isolated form as well as when associated to overt alpha-synucleinopathies. In other contexts, e.g. narcolepsy, we suggest identification of prodromal RBD as well, although no data is available so far, as only through systematic recognition and follow-up of these subjects, more data can be gained and a better understanding of this finding can be achieved.

Current recommendations and methods: Prodromal RBD can be conceptually defined as a stage in which covert but quantifiably observable signs of evolving RBD are present during v-PSG, which do not yet meet established diagnostic criteria for RBD.^{2,6} Several studies support the concept and potential clinical relevance of prodromal RBD^{6,64–73}.

The signs of evolving RBD may be either neurophysiological, behavioral, or both², manifesting as: a) isolated RWA, i.e. quantitatively increased amounts of RWA without a clinical history or recorded dream enactments and/or b) REM sleep behavior events (RBEs), which are visible episodes with minor but seemingly purposeful motor behaviors during REM sleep or a clear excess of elementary motor events such as recurrent muscle twitches.

It has been suggested that isolated RWA could be defined by either the same RWA cut-offs used for the diagnosis of RBD (see Section 4), and/or RWA exceeding the 95th percentile threshold values of normative adult cohorts^{74,75}. The cut-off of two or more RBE has been used for defining prodromal RBD.⁶⁴ A recent study on automated 3D video analysis⁶³ used as cut-off the 90th percentile of published normative values of movements per hour during REM sleep in healthy subjects⁷⁶.

As prodromal RBD is a newly proposed concept, currently no methods for its identification have been thoroughly validated across clinics nor been defined in the AASM manual version 2.6⁸ and in the ICSD-3⁷ yet.

Limitations of current recommendations and methods: Currently, there is no clear definition how prodromal RBD can be identified. Video and audio scoring are not yet well standardized, and both video analysis and RWA quantification can be limited by differences in acquisition or interpretation,

Another potential issue is inter-night variability in prodromal RBD. In the context of RBD, studies of inter-night variability of RWA and movements/vocalizations remain limited^{62,77-80}, although RWA seems to be a stable finding over consecutive nights.⁷⁷⁻⁸⁰

V-PSG recommendations for identification of prodromal RBD:

- General recommendations:
 - V-PSG is mandatory to identify prodromal RBD.
 - V-PSG requirements for sleep recording: see Section 2.
 - REM sleep scoring: see Section 3.
 - RWA quantification: see Section 4.
 - Motor events description and classification: see Section 5.
- Prodromal RBD identification

Identify prodromal RBD if AT LEAST ONE of the following is present⁶¹:

- Isolated RWA (same cut-off as for RBD, see Section 4, and/or exceeding 95th percentile thresholds for normative cohorts^{74,75})
- Motor events exceeding the 90th percentile of normative values⁷⁶.

8. FUTURE DIRECTIONS

The evaluation of RBD and prodromal RBD is based on investigation and interpretation of electrophysiological signals and video/audio during REM sleep. With these guidelines we aim to harmonize v-PSG in this context. However, we recognize that: I) several issues are still open and need further research; II) currently, data deriving from v-PSG are not used at their full potential; III) development of new technologies may allow future different approaches to RBD and prodromal RBD.

Many issues including e.g. artefact correction, video and audio analysis, identification of prodromal RBD as the transition from physiological REM sleep to full-blown RBD still need to be clarified in future studies.

Despite electrophysiological signals and behavior manifestations in video or audio are different and complementary expressions of the same underlying process, no study has investigated so far how to integrate video and audio information in RWA quantification. As an example, RBD episodes might appear as arousals in the PSG and might therefore be excluded from RWA quantification. Similarly, in the context of RBD and prodromal RBD, the definition of arousal in REM sleep might be reconsidered. For example, an arousal might only be identified when there is a change in the EEG signal (as defined by the AASM⁸) but in association with a change from the RBD pattern of discontinuous EMG discharge to a continuous EMG period of at least 3 seconds and appearance of slow eye movements, particularly if associated with eye opening in the video. Future studies should investigate how to best deal with these issues and integrate *all* information recorded during v-PSG.

Artificial intelligence in sleep research⁸¹ could also significantly contribute to advancement in the field of RBD and prodromal RBD. These methods can easily combine multiple streams of electrophysiologic, video and auditory information from v-PSG in complex models and use them for predictions. Recent studies have already shown that the combination of different electrophysiological signals is helpful for both RBD diagnosis⁸² and identification of prodromal RBD⁷³. Future studies should investigate how to integrate video and electrophysiological signals using artificial intelligence methods.

V-PSG is the current gold standard for RBD diagnosis and identification of prodromal RBD. In the future, at-home technologies might help to identify these conditions in the general population, as well as to monitor their evolution over time. Actigraphy^{83,84}, motion activated video-recording, automatic analysis of 3-D videos⁶³, and light and practical devices to record sleep^{85,86} are promising tools that should be further investigated in the future and compared to gold standard v-PSG.

9. CONCLUSIONS

These v-PSG recommendations aim to standardize diagnosis of RBD and identification of prodromal RBD. This will allow collection of homogeneous data, providing objective v-PSG measures and making future harmonized multicentric studies and clinical trials possible⁸⁷.

APPENDIX

A1. METHODS

These guidelines are the result of a common effort of the Neurophysiology Working Group of the International RBD Study Group (IRBDSG). The coordinating authors of the manuscript proposed an outline with the topics to be addressed in the different sections. For each section, task-forces were created, depending on the main areas of expertise of each author. Task-forces had one coordinator, responsible for supervising the discussion. Literature on the topic was reviewed in each task force and consensus was reached based on literature and expert opinions. Task-force coordinators drafted the different sections, which were then collected and harmonized by the coordinating authors and a final draft was created. This underwent critical review and final approval by all co-authors. The IRBDSG board critically reviewed and approved the final version of the manuscript.

A2. USEFUL DEFINITIONS

Artefact: spurious observations resulting from preparatory or investigative procedures and bursts in the EMG channel due to intrusion of other physiological events (interference)

Motor event: any type of movement which is visible from the video. An inter-event interval of 3 seconds is proposed for separating motor events. Also, there should be no vocalization during these 3 seconds.

RBD episode: One RBD episode consists of one or more motor events and/or vocalizations that can be interpreted as related to dream enactment. Thus, this includes jerky and complex movements with or without vocalizations. An inter-episode interval of 30 seconds is proposed for separating RBD episodes.

REM sleep periods: usually 3-s mini-epochs within 30-s REM sleep epochs used for quantification of RWA.

ACKNOWLEDGEMENTS

We would like to thank Prof. Wolfgang Löscher and Dr. Abubaker Ibrahim from the Department of Neurology, Medical University of Innsbruck (Austria) for their help and inputs in Section 2 of the manuscript.

DISCLOSURE STATEMENT

Financial disclosures: none

Non-financial disclosures: none

REFERENCES

1. Schenck CH, Bundlie SR, Ettinger MG, Mahowald MW. Chronic behavioral disorders of human REM sleep: A new category of parasomnia. *Sleep*. 1986;9(2):293-308. doi:10.1093/sleep/9.2.293
2. Högl B, Stefani A, Videnovic A. Idiopathic REM sleep behaviour disorder and neurodegeneration - An update. *Nat Rev Neurol*. 2018;14(1):40-55. doi:10.1038/nrneuro.2017.157
3. Sixel-Döring F, Trenkwalder C. REM sleep behavior disorder associated with parkinson's disease and multiple system atrophy. In: *Rapid-Eye-Movement Sleep Behavior Disorder*. Springer International Publishing; 2018:53-65. doi:10.1007/978-3-319-90152-7_5
4. Boeve BF. REM sleep behavior disorder associated with dementia with lewy bodies. In: *Rapid-Eye-Movement Sleep Behavior Disorder*. Springer International Publishing; 2018:67-76. doi:10.1007/978-3-319-90152-7_6
5. Antelmi E, Pizzi F, Franceschini C, Ferri R, Plazzi G. REM sleep behavior disorder in narcolepsy: A secondary form or an intrinsic feature? *Sleep Med Rev*. 2020;50. doi:10.1016/j.smrv.2019.101254
6. Sixel-Döring F, Zimmermann J, Wegener A, Mollenhauer B, Trenkwalder C. The Evolution of REM Sleep Behavior Disorder in Early Parkinson Disease. *Sleep*. 2016;39(9):1737-1742. doi:10.5665/sleep.6102
7. American Academy of Sleep Medicine. *The International Classification of Sleep Disorders (ICSD-3)*. 3rd ed. (American Academy of Sleep Medicine, ed.). Darien, IL; 2014.
8. Berry RB, Brooks R, Gamaldo CE, et al. *The AASM Manual for the Scoring of Sleep and Associated Events: Rules, Terminology and Technical Specifications: Version 2.6*. Darien, IL: American Academy of Sleep Medicine; 2020.
9. De Cock VC. Video analysis of behaviors and movements in RBD. In: Schenck CH, Högl B, Videnovic A, eds. *Rapid-Eye-Movement Sleep Behavior Disorder*. Springer; 2018:281-290. doi:10.1007/978-3-319-90152-7_21
10. Merletti R. Standards for reporting EMG data. *J Electromyogr Kinesiol*. 2018;42:1-II. doi:10.1016/S1050-6411(18)30348-1
11. Hermens HJ, Frenkers B, Merletti R, et al. *European Recommendations for Surface ElectroMyoGraphy Results of the SENIAM Project*. Enschede, the Netherlands: Roessingh Research and Development; 1999.
12. Vandi S. Video-polysomnography of parasomnias. In: Thorpy M, Plazzi G, eds. *The Parasomnias and Other Sleep-Related Movement Disorders*. Cambridge University Press; 2010. doi:10.1017/CBO9780511711947.007
13. Lapierre O, Montplaisir J. Polysomnographic features of REM sleep behavior disorder: Development of a scoring method. *Neurology*. 1992;42(7):1371-1374. doi:10.1212/wnl.42.7.1371
14. Frauscher B, Iranzo A, Gaig C, et al. Normative EMG Values during REM Sleep for the Diagnosis of REM Sleep Behavior Disorder. *Sleep*. 2012;35(6):835-847. doi:10.5665/sleep.1886.

15. Frauscher B, Iranzo A, Högl B, et al. Quantification of electromyographic activity during REM sleep in multiple muscles in REM sleep behavior disorder. *Sleep*. 2008;31(5):724-731.
16. Fantini ML, Gagnon JF, Petit D, et al. Slowing of electroencephalogram in rapid eye movement sleep behavior disorder. *Ann Neurol*. 2003;53(6):774-780. doi:10.1002/ana.10547
17. Massicotte-Marquez J, Décary A, Gagnon JF, et al. Executive dysfunction and memory impairment in idiopathic REM sleep behavior disorder. *Neurology*. 2008;70(15):1250-1257. doi:10.1212/01.wnl.0000286943.79593.a6
18. Bang YR, Jeon HJ, Youn S, Yoon Iy. Alterations of awake EEG in idiopathic REM sleep behavior disorder without cognitive impairment. *Neurosci Lett*. 2017;637:64-69. doi:10.1016/j.neulet.2016.11.052
19. Sasai T, Matsuura M, Inoue Y. Electroencephalographic findings related with mild cognitive impairment in idiopathic rapid eye movement sleep behavior disorder. *Sleep*. 2013;36(12):1893-1899. doi:10.5665/sleep.3224
20. Iranzo A, Isetta V, Molinuevo JL, et al. Electroencephalographic slowing heralds mild cognitive impairment in idiopathic REM sleep behavior disorder. *Sleep Med*. 2010;11(6):534-539. doi:10.1016/j.sleep.2010.03.006
21. Gagnon JF, Fantini ML, Bédard MA, et al. Association between waking EEG slowing and REM sleep behavior disorder in PD without dementia. *Neurology*. 2004;62(3):401-406. doi:10.1212/01.WNL.0000106460.34682.E9
22. Petit D, Gagnon JF, Fantini ML, Ferini-Strambi L, Montplaisir J. Sleep and quantitative EEG in neurodegenerative disorders. *J Psychosom Res*. 2004;56(5):487-496. doi:10.1016/j.jpsychores.2004.02.001
23. Fernández-Arcos A, Morenas-Rodríguez E, Santamaria J, et al. Clinical and video-polysomnographic analysis of rapid eye movement sleep behavior disorder and other sleep disturbances in dementia with Lewy bodies. *Sleep*. 2019;42(7):zsz086. doi:10.1093/sleep/zsz086
24. Montplaisir J, Petit D, Gauthier S, Gaudreau H, Décary A. Sleep disturbances and EEG slowing in Alzheimer's disease. *Sleep Res Online*. 1998;1(4):147-151.
25. Petit D, Lorrain D, Gauthier S, Montplaisir J. Regional spectral analysis of the REM sleep EEG in mild to moderate Alzheimer's disease. *Neurobiol Aging*. 1993;14(2):141-145. doi:10.1016/0197-4580(93)90089-T
26. Bliwise DL, Williams ML, Irbe D, Ansari FP, Rye DB. Inter-rater reliability for identification of REM sleep in Parkinson's disease. *Sleep*. 2000;23(5):671-676. doi:10.1093/sleep/23.5.1j
27. Jensen PS, Sorensen HBD, Leonthin HL, Jennum P. Automatic sleep scoring in normals and in individuals with neurodegenerative disorders according to new international sleep scoring Criteria. *J Clin Neurophysiol*. 2010;27(4):296-302. doi:10.1097/WNP.0b013e3181eaad4b
28. Danker-Hopfe H, Anderer P, Zeitlhofer J, et al. Interrater reliability for sleep scoring according to the Rechtschaffen & Kales and the new AASM standard. *J Sleep Res*. 2009;18(1):74-84. doi:10.1111/j.1365-2869.2008.00700.x
29. Santamaria J, Högl B, Trenkwalder C, Bliwise D. Scoring Sleep in Neurological Patients: The Need for Specific Considerations. *Sleep*. 2011;34(10):1283-1284. doi:10.5665/sleep.1256
30. McCarter SJ, St. Louis EK, Duwell EJ, et al. Diagnostic Thresholds for Quantitative REM Sleep Phasic Burst Duration, Phasic and Tonic Muscle Activity, and REM Atonia Index in REM Sleep Behavior Disorder with and without Comorbid Obstructive Sleep Apnea. *Sleep*. 2014;37(10):1649-1662. doi:10.5665/sleep.4074
31. McCarter SJ, St. Louis EK, Sandness DJ, et al. Diagnostic REM sleep muscle activity thresholds in patients with idiopathic REM sleep behavior disorder with and without obstructive sleep apnea. *Sleep Med*. 2017;33:23-29. doi:10.1016/j.sleep.2016.03.013
32. Nepozitek J, Dostalova S, Dusek P, et al. Simultaneous tonic and phasic REM sleep without atonia best predicts early phenoconversion to neurodegenerative disease in idiopathic REM sleep behavior disorder. *Sleep*. 2019;42(9):zsz132. doi:10.1093/sleep/zsz132
33. Frauscher B, Gschliesser V, Brandauer E, et al. Video analysis of motor events in REM sleep behavior disorder. *Mov Disord*. 2007;22(10):1464-1470. doi:10.1002/mds.21561
34. Frauscher B, Gabelia D, Biermayr M, et al. Validation of an Integrated Software for the Detection of Rapid Eye Movement Sleep Behavior Disorder. *Sleep*. 2014;37(10):1663-1671. doi:10.5665/sleep.4076
35. Montplaisir J, Gagnon JF, Fantini ML, et al. Polysomnographic diagnosis of idiopathic REM sleep behavior disorder. *Mov Disord*. 2010;25(13):2044-2051. doi:10.1002/mds.23257
36. Figorilli M, Ferri R, Zibetti M, et al. Comparison between automatic and visual scorings of REM sleep without atonia for the diagnosis of REM sleep behavior disorder in Parkinson disease. *Sleep*. 2017;40(2):zsw060. doi:10.1093/sleep/zsw060
37. Ferri R, Gagnon JF, Postuma RB, Rundo F, Montplaisir JY. Comparison between an automatic and a visual scoring method of the chin muscle tone during rapid eye movement sleep. *Sleep Med*. 2014;15(6):661-665. doi:10.1016/j.sleep.2013.12.022
38. Iranzo A, Frauscher B, Santos H, et al. Usefulness of the SINBAR electromyographic montage to detect the motor and vocal manifestations occurring in REM sleep behavior disorder. *Sleep Med*. 2011;12(3):284-288. doi:10.1016/j.sleep.2010.04.021
39. Fernández-Arcos A, Iranzo A, Serradell M, et al. Diagnostic Value of Isolated Mentalis Versus Mentalis Plus Upper Limb Electromyography in Idiopathic REM Sleep Behavior Disorder Patients Eventually Developing a Neurodegenerative Syndrome. *Sleep*. 2017;40(4). doi:10.1093/sleep/zsx025
40. Fantini ML, Michaud M, Gosselin N, Lavigne G, Montplaisir J. Periodic leg movements in REM sleep behavior disorder and related autonomic and EEG activation. *Neurology*. 2002;59(12):1889-1894. doi:10.1212/01.wnl.0000038348.94399.f6
41. Gaig C, Iranzo A, Pujol M, Perez H, Santamaria J. Periodic limb movements during sleep mimicking REM sleep behavior disorder: A new form of periodic limb movement disorder. *Sleep*. 2017;40(3):zsw063. doi:10.1093/sleep/zsw063
42. Nepozitek J, Dostalova S, Kemlink D, et al. Fragmentary myoclonus in idiopathic rapid eye movement sleep behaviour disorder. *J Sleep Res*. 2019;28(4). doi:10.1111/jsr.12819
43. Cesari M, Heidbreder A, Bergmann M, Holzknacht E, Högl B, Stefani A. Flexor digitorum superficialis muscular activity is more reliable than mentalis muscular activity for rapid eye movement sleep without atonia quantification. *Sleep*. 2021:In press. doi:10.1093/sleep/zsab094
44. Ferri R, Rundo F, Manconi M, et al. Improved computation of the atonia index in normal controls and patients with REM sleep behavior disorder. *Sleep Med*. 2010;11:947-949. doi:10.1016/j.sleep.2010.06.003
45. Cesari M, Christensen JAEE, Kempfner L, et al. Comparison of computerized methods for rapid eye movement sleep without atonia detection. *Sleep*. 2018;41(10):zsy133. doi:10.1093/sleep/zsy133
46. Cesari M, Christensen JAE, Sixel-Döring F, et al. Validation of a new data-driven automated algorithm for muscular activity detection in REM sleep behavior disorder. *J Neurosci Methods*. 2019;312:53-64. doi:10.1016/j.jneumeth.2018.11.016
47. Cesari M, Christensen JAE, Sorensen HBD, et al. External validation of a data-driven algorithm for muscular activity identification during sleep. *J Sleep Res*. 2019;28(6):e12868. doi:10.1111/jsr.12868
48. Wordreference. Artefact definition. <https://www.wordreference.com/definition/artefact>. Accessed December 23, 2020.
49. Diagnostic Classification Steering Committee. *International Classification of Sleep Disorders: Diagnostic and Coding Manual*. Rochester: American Sleep Disorder Association; 1990.
50. Schenck CH, Bundlie SR, Patterson AL, Mahowald MW. Rapid Eye Movement Sleep Behavior Disorder: A Treatable Parasomnia Affecting Older Adults. *JAMA J Am Med Assoc*. 1987;257(13):1786-1789. doi:10.1001/jama.1987.03390130104038

51. American Academy of Sleep Medicine. *International Classification of Sleep Disorders: Diagnostic and Coding Manual, Revised*. Chicago: American Academy of Sleep Medicine; 2001.
52. American Academy of Sleep Medicine. *International Classification of Sleep Disorders: Diagnostic and Coding Manual*. 2nd ed. (American Academy of Sleep Medicine, ed.). Westchester; 2005.
53. Sforza E, Zucconi M, Petronelli R, Lugaresi E, Cirignotta F. REM sleep behavioral disorders. *Eur Neurol*. 1988;28(5):295-300. doi:10.1159/000116288
54. Fantini ML, Gagnon JF, Filipini D, Montplaisir J. The effects of pramipexole in REM sleep behavior disorder. *Neurology*. 2003;61(10):1418-1420. doi:10.1212/WNL.61.10.1418
55. Iranzo A, Santamaría J, Rye DB, et al. Characteristics of idiopathic REM sleep behavior disorder and that associated with MSA and PD. *Neurology*. 2005;65(2):247-252. doi:10.1212/01.wnl.0000168864.97813.e0
56. Gagnon JF, Bédard MA, Fantini ML, et al. REM sleep behavior disorder and REM sleep without atonia in Parkinson's disease. *Neurology*. 2002;59(4):585-589. doi:10.1212/WNL.59.4.585
57. Arnulf I. REM sleep behavior disorder: Motor manifestations and pathophysiology. *Mov Disord*. 2012;27(6):677-689. doi:10.1002/mds.24957
58. Frauscher B, Gschliesser V, Brandauer E, et al. Motor disturbances during non-REM and REM sleep in narcolepsy-cataplexy: A video-polysomnographic analysis. *J Sleep Res*. 2011;20(4):514-521. doi:10.1111/j.1365-2869.2011.00906.x
59. Nepozitek J, Unalp C, Dostalova S, et al. Systematic video-analysis of motor events during REM sleep in idiopathic REM sleep behavior disorder, follow-up and DAT-SPECT. *Sleep Med*. April 2021. doi:10.1016/j.sleep.2021.04.033
60. Stefani A, Santamaria J, Iranzo A, Hackner H, Schenck CH, Högl B. Nelotanserin as symptomatic treatment for rapid eye movement sleep behavior disorder: a double-blind randomized study using video analysis in patients with dementia with Lewy bodies or Parkinson's disease dementia. *Sleep Med*. 2021;81:180-187. doi:10.1016/j.sleep.2021.02.038
61. Oudiette D, Leu-Semenescu S, Roze E, et al. A motor signature of REM sleep behavior disorder. *Mov Disord*. 2012;27(3):428-431. doi:10.1002/mds.24044
62. Sixel-Döring F, Schweitzer M, Mollenhauer B, Trenkwalder C. Intraindividual variability of REM sleep behavior disorder in Parkinson's disease: A comparative assessment using a new REM sleep behavior disorder severity scale (RBDSS) for clinical routine. *J Clin Sleep Med*. 2011;7(1):75-80. doi:10.5664/jcsm.28044
63. Waser M, Stefani A, Holzknacht E, et al. Automated 3D video analysis of lower limb movements during REM sleep: a new diagnostic tool for isolated REM sleep behavior disorder. *Sleep*. 2020;43(11):zsaa100. doi:10.1093/sleep/zsaa100
64. Sixel-Döring F, Trautmann E, Mollenhauer B, Trenkwalder C. Rapid Eye Movement Sleep Behavioral Events: A New Marker for Neurodegeneration in Early Parkinson Disease? *Sleep*. 2014;37(3):431-438. doi:10.5665/sleep.3468
65. Swetlik C, Unger R, Bena J, Foldvary-Schaefer N, Rodriguez CL, Touse B. Neurodegenerative Outcomes Following Diagnosis of REM Sleep Behavior Disorder or Isolated REM Sleep Without Atonia (2746). *Neurology*. 2020;94(15 Supplement).
66. Stefani A, Gabelia D, Högl B, et al. Long-term follow-up investigation of isolated REM sleep without atonia without REM sleep behavior disorder: a pilot study. *J Clin Sleep Med*. 2015.
67. Dede HÖ, Benbir Senel G, Karadeniz D. Rapid eye movement sleep without atonia constitutes increased risk for neurodegenerative disorders. *Acta Neurol Scand*. 2019;140(6):399-404. doi:10.1111/ane.13156
68. Dijkstra F, Van den Bossche K, de Bruyn B, et al. REM sleep without atonia and the relation with Lewy body disease. *Park Relat Disord*. 2019;67:90-98. doi:10.1016/j.parkreldis.2019.07.007
69. Ferri R, Aricò D, Cosentino FII, Lanuzza B, Chiaro G, Manconi M. REM sleep without atonia with REM sleep-related motor events: Broadening the spectrum of REM sleep behavior disorder. *Sleep*. 2018;41(12). doi:10.1093/sleep/zsy187
70. Fujishiro H, Okuda M, Iwamoto K, et al. Clinical profiles of late-onset psychiatric patients exhibiting incidental REM sleep without atonia. *J Neural Transm*. 2019;126(8):1095-1104. doi:10.1007/s00702-019-02035-7
71. McCarter SJ, St. Louis EK, Boeve BF, Sandness DJ, Silber MH. Greatest rapid eye movement sleep atonia loss in men and older age. *Ann Clin Transl Neurol*. 2014;1(9):733-738. doi:10.1002/acn3.93
72. McCarter SJ, Tabatabai GM, Jong HY, et al. REM sleep atonia loss distinguishes synucleinopathy in older adults with cognitive impairment. *Neurology*. 2020;94(1):e15-e29. doi:10.1212/WNL.0000000000008694
73. Cesari M, Christensen JAE, Muntean ML, et al. A data-driven system to identify REM sleep behavior disorder and to predict its progression from the prodromal stage in Parkinson's disease. *Sleep Med*. 2021;77:238-248. doi:10.1016/j.sleep.2020.04.010
74. Frauscher B, Gabelia D, Mitterling T, et al. Motor Events during Healthy Sleep : A Quantitative Polysomnographic Study. *Sleep*. 2014;37(4):763-773. doi:10.5665/sleep.3586
75. Feemster JC, Jung Y, Timm PC, et al. Normative and isolated rapid eye movement sleep without atonia in adults without REM sleep behavior disorder. *Sleep*. 2019;42(10):zsz124. doi:10.1093/sleep/zsz124
76. Stefani A, Gabelia D, Mitterling T, Poewe W, Högl B, Frauscher B. A Prospective Video-Polysomnographic Analysis of Movements during Physiological Sleep in 100 Healthy Sleepers. *Sleep*. 2015;38(9):1479-1487. doi:10.5665/sleep.4994
77. Cygan F, Oudiette D, Leclair-Visonneau L, Leu-Semenescu S, Arnulf I. Night-to-night variability of muscle tone, movements, and vocalizations in patients with REM sleep behavior disorder. *J Clin Sleep Med*. 2010;6(6):551-555. doi:10.5664/jcsm.27988
78. Zhang J, Lam SP, Ho CKW, et al. Diagnosis of REM sleep behavior disorder by video-polysomnographic study: Is one night enough? *Sleep*. 2008;31(8):1179-1185. doi:10.5665/sleep/31.8.1179
79. Ferri R, Marelli S, Cosentino FIII, Rundo F, Ferini-Strambi L, Zucconi M. Night-to-night variability of automatic quantitative parameters of the chin EMG amplitude (atonia index) in REM sleep behavior disorder. *J Clin Sleep Med*. 2013;9(3):253-258. doi:10.5664/jcsm.2490
80. Bolitho SJ, Naismith SL, Terpening Z, et al. Investigating the night-to-night variability of REM without atonia in Parkinson's disease. *Sleep Med*. 2015;16(1):190-193. doi:10.1016/j.sleep.2014.08.007
81. Goldstein CA, Berry RB, Kent DT, et al. Artificial intelligence in sleep medicine: Background and implications for clinicians. *J Clin Sleep Med*. 2020;16(4):609-618. doi:10.5664/jcsm.8388
82. Cooray N, Andreotti F, Lo C, Symmonds M, Hu MTM, De Vos M. Detection of REM sleep behaviour disorder by automated polysomnography analysis. *Clin Neurophysiol*. 2019;130(4):505-514. doi:10.1016/j.clinph.2019.01.011
83. Stefani A, Heidebreder A, Brandauer E, et al. Screening for idiopathic REM sleep behavior disorder: usefulness of actigraphy. *Sleep*. 2018;41(6).
84. Filardi M, Stefani A, Holzknacht E, Pizza F, Plazzi G, Högl B. Objective rest-activity cycle analysis by actigraphy identifies isolated rapid eye movement sleep behavior disorder. *Eur J Neurol*. 2020. doi:10.1111/ene.14386
85. Shustak S, Inzelberg L, Steinberg S, et al. Home monitoring of sleep with a temporary-tattoo EEG, EOG and EMG electrode array: A feasibility study. *J Neural Eng*. 2019;16(2). doi:10.1088/1741-2552/aafa05

86. Mikkelsen KB, Tabar YR, Kappel SL, et al. Accurate whole-night sleep monitoring with dry-contact ear-EEG. *Sci Rep.* 2019;9(1). doi:10.1038/s41598-019-53115-3
87. Videnovic A, Ju Y-ES, Arnulf I, et al. Clinical trials in REM sleep behavioural disorder: challenges and opportunities. *J Neurol Neurosurg Psychiatry.* 2020;91(7):740-749. doi:10.1136/jnnp-2020-322875
88. Bliwise DL, He L, Ansari FP, Rye DB. Quantification of electromyographic activity during sleep: A phasic electromyographic metric. In: *Journal of Clinical Neurophysiology.* Vol 23. J Clin Neurophysiol; 2006:59-67. doi:10.1097/01.wnp.0000192303.14946.fc
89. Bliwise DL, Rye DB. Elevated PEM (phasic electromyographic metric) rates identify rapid eye movement behavior disorder patients on nights without behavioral abnormalities. *Sleep.* 2008;31(6):853-857. doi:10.1093/sleep/31.6.853
90. Figorilli M, Marques AR, Meloni M, et al. Diagnosing REM sleep behavior disorder in Parkinson's disease without a gold standard: a latent-class model study. *Sleep.* 2020;43(7). doi:10.1093/sleep/zsz323
91. Burns JW, Consens FB, Little RJ, Angell KJ, Gilman S, Chervin RD. EMG variance during polysomnography as an assessment for REM sleep behavior disorder. *Sleep.* 2007;30(12):1771-1778. doi:10.1093/sleep/30.12.1771
92. Mayer G, Kesper K, Ploch T, et al. Quantification of Tonic and Phasic Muscle Activity in REM Sleep Behavior Disorder. *J Clin Neurophysiol.* 2008;25(1):48-55. doi:10.1097/WNP.0b013e318162acd7
93. Guttowski D, Mayer G, Oertel WH, Kesper K, Rosenberg T. Validation of semiautomatic scoring of REM sleep without atonia in patients with RBD. *Sleep Med.* 2018;46:107-113. doi:10.1016/j.sleep.2018.03.010
94. Frandsen R, Nikolic M, Zoetmulder M, Kempfner L, Jennum P. Analysis of automated quantification of motor activity in REM sleep behaviour disorder. *J Sleep Res.* 2015;24(5):583-590. doi:10.1111/jsr.12304
95. Kempfner J, Sorensen GL, Nikolic M, Frandsen R, Sorensen HBD, Jennum P. Rapid Eye Movement Sleep Behavior Disorder as an Outlier Detection Problem. *J Clin Neurophysiol.* 2014;31:86-93.
96. Kempfner J, Sorensen HBD, Nikolic M, Jennum P. Early Automatic Detection of Parkinson's Disease Based on Sleep Recordings. *J Clin Neurophysiol.* 2014;31:409-415.

1

TABLES

Table 1: Definitions of types of EMG activity for scoring of RWA according to different validated methods.

Method	EMG activity	Definition	Muscles analysed	RWA scores	Additional notes
Montreal ^{13,35}	Phasic	Any burst of EMG activity lasting 0.1-5 s (later on modified to 0.1-10 s ³⁵) with an amplitude > 4 the background.	Chin	<ul style="list-style-type: none"> Chin phasic 2-s = % of 2-s mini-epochs in REM sleep periods with phasic chin activity Chin tonic 20-s = % of 20-s epochs included in REM sleep periods with tonic chin activity 	None
	Tonic	EMG activity with amplitude >2 the background or >10 μ V present for >50% of the 20/30-s epoch.	Chin	<ul style="list-style-type: none"> Chin phasic 3-s = % of 3-s mini-epochs in REM sleep periods with phasic chin activity Chin tonic 30-s = % of 30-s epochs included in REM sleep periods with tonic chin activity 	
Emory ^{88,89}	Phasic	Phasic EMG activity (PEM) defined as discrete bursts of EMG activity \geq 100 ms duration with an amplitude > 4 times the background activity as detected during the pre-sleep baseline.	Chin, Brachioradialis, TA	<ul style="list-style-type: none"> PEM rate chin: % of 2.5-s segments in REM sleep containing PEM in the chin; PEM rate left/right brachioradialis: % of 2.5-s segments in REM sleep containing PEM in the left/right brachioradialis muscle; PEM rate left/right TA: % of 2.5-s segments in REM sleep containing PEM 	<ul style="list-style-type: none"> PEM rates were calculated also in NREM sleep

				in the left/right TA muscle;	
SINBAR ^{14,15}	Phasic	Any burst of EMG activity lasting 0.1-5.0 s with an amplitude >2 times the background. End defined as a return to the baseline or an interburst interval of >250 ms. Phasic superimposed to tonic activity: the burst of phasic EMG has at least twice the amplitude of the background tonic EMG activity.	Chin, FDS, TA	<ul style="list-style-type: none"> • <i>Chin phasic 3-s</i> = % of 3-s mini-epochs in REM sleep periods with phasic chin activity. • <i>Chin tonic 3-s</i> = % full 30-s REM sleep epochs included in REM sleep periods scored as tonic. • <i>Chin any 3-s</i> = % of 3-s mini-epochs in REM sleep periods with any chin activity. • <i>SINBAR 3-s</i> = % of 3-s mini-epochs in REM sleep periods with any chin and/or bilateral FDS phasic EMG activity. 	<ul style="list-style-type: none"> • PLMS excluded from analysis. • Artifacts (e.g., snoring) and increases in EMG tone due to arousals from respiratory events excluded from the quantitative scoring of REM sleep related EMG activity.
	Tonic	Increased sustained EMG activity in >50% of a 30-s epoch, with an amplitude > times the background EMG muscle tone or >10µV	Chin	<ul style="list-style-type: none"> • <i>Chin phasic 30-s</i> = % of 30-s REM sleep epochs with at least five 3-s mini-epochs with phasic chin activity. • <i>Chin tonic 30-s</i> = % of 30-s tonic epochs in REM sleep. • <i>Chin any 30-s</i> = % of 30-s epochs included in REM sleep periods with at least five 3-s mini-epochs with any chin activity. • <i>SINBAR 30-s</i> = % of 30-s epochs included in REM sleep periods with at least five 3-s mini-epochs with any chin and/or bilateral FDS phasic EMG activity. 	
	Any	EMG activity, irrespective of whether tonic, phasic, a combination of both, or anything in between (i.e., with a duration 5-15 s).	Chin		
Mayo ^{30,31}	Phasic	EMG burst > 4 times the background amplitude, with a duration 0.1-14.9 s. End defined as a return to baseline for at least 200 ms. Phasic burst duration: Average duration of all phasic muscle activity. "Phasic-on-tonic": Bursts of phasic activity occurring simultaneously with tonic activity need to have an amplitude > 2 times the background tonic EMG	Chin, TA	<ul style="list-style-type: none"> • <i>Chin phasic 3-s</i> = % of 3-s mini-epochs in REM sleep periods with phasic chin activity. • <i>Chin any 3-s</i> = % of 3-s mini-epochs in REM sleep periods with any chin activity. • <i>Chin duration</i> = average duration of phasic EMG activity in the chin muscle. • <i>Chin tonic 30-s</i> = % of 30-s epochs included in REM sleep 	<ul style="list-style-type: none"> • PLM-like muscle activity included. • Any 3-s mini-epoch containing either a breathing-related event or an arousal was scored as "artefact" and excluded from analysis.

		activity to be scored separately as phasic.		periods with tonic chin activity.	
	Tonic	Any activity continuously greater than double the background EMG or $\geq 10 \mu V$ in $> 50\%$ of the epoch.	Chin, TA		
	Any	Either tonic, or phasic, or both.	Chin, TA (omitted in second validation study ³¹ due to rare TA tonic RWA)		
Prague ³²	Phasic	Any burst of EMG activity lasting 0.1- 5.0 s with amplitude exceeding twice the background. End defined by return to the baseline or by an interburst interval lasting >250 ms.	Chin, FDS	<ul style="list-style-type: none"> • <i>Chin phasic 3-s</i> = % of 3-s mini-epochs in REM sleep periods with phasic chin activity. • <i>Chin any 3-s</i> = % of 3-s mini-epochs in REM sleep periods with any chin activity. • <i>Chin mixed 3-s</i> = % of 3-s mini-epochs in REM sleep periods with mixed chin activity. • <i>Chin tonic 30-s</i> = % of 30-s epochs included in REM sleep periods with tonic chin activity. • <i>SINBAR 3-s</i> = % of 3-s mini-epochs in REM sleep periods with any chin and/or bilateral FDS phasic EMG activity. 	<ul style="list-style-type: none"> • All artifacts and increases in EMG tone due to arousals from respiratory events were excluded from the quantitative scoring before the analysis of EMG activity.
	Tonic	Sustained increase in EMG activity in $>50\%$ of the epoch with amplitude >2 times the background EMG muscle tone or $>10 \mu V$.	Chin		
	Any	Phasic, tonic, or mixed EMG activity.	Chin, FDS		
	Mixed	Burst of phasic EMG activity >2 times the amplitude of the background tonic EMG activity (including also EMG activity with a duration of 5–15 s).	Chin		

Legend: EMG, electromyography; FDS, flexor digitorum superficialis; PLMS, periodic leg movements during sleep; REM: rapid eye movement; SINBAR, Sleep Innsbruck Barcelona; TA, tibialis anterior.

Table 2. Cutoffs of the most commonly used validated RWA indices for manual RWA scoring methods and their performance.

Method	Studies	Patients / controls*	Cut-off and performances (sens/spec)
Montreal ^{13,35,36}	3	5/10 ¹³ 37 (PD+ RBD)/25 (PDnonRBD) ³⁶	<ul style="list-style-type: none"> • <u>30-s epochs</u>: <i>Chin tonic 30-s</i>: 30% (sens: 100% , spec: 88%)³⁶ • <u>3-s mini-epochs</u>: <i>Chin phasic 3-s</i>: 15% (sens: 37.8% , spec: 96%)³⁶
SINBAR ^{14,34,36,74,90}	5	30/30 ¹⁴ 37 (PD+ RBD)/25 (PDnonRBD) ³⁶ 69 PD+RBD/42 PDnonRBD + 25 controls ⁹⁰ 20/60 ³⁴ 0/100 ⁷⁴	<ul style="list-style-type: none"> • <u>30-s epochs</u>: <i>Chin tonic 30-s</i>: 8.7% (sens: 86.7%, spec:100%)¹⁴, 90th percentile 2.6%⁷⁴ <i>Chin phasic 30-s</i>: 10.6% (sens: 86.7%, spec:100%)¹⁴, 90th percentile 15.6%⁷⁴ <i>Chin any 30-s</i>: 14.5% (sens: 93.3%, spec:100%)¹⁴, 90th percentile 16.6%⁷⁴ <i>SINBAR 30-s</i>: 27.2% (sens 90.4%-100%, spec 88%-100%)^{14,34,36,90}, 90th percentile 26.1%⁷⁴

			<ul style="list-style-type: none"> 3-s mini-epochs: <i>Chin tonic</i> 3-s: 9.6% (sens 64-83.3%, spec 100%)^{14,90} <i>Chin phasic</i> 3-s: 16.3% (sens 27%-90%, spec 68%-100%)^{14,34,36,90}, 90th percentile 21.3%⁷⁴ <i>Chin any</i> 3-s: 18.2% (sens 85%-100%, spec 73%-100%)^{14,34,36,90}, 90th percentile 22.3%⁷⁴ <i>SINBAR</i> 3-s: 31.9% (sens 83%-94.6%, spec 87%-100%)^{14,34,36,90}, 90th percentile 31.2%⁷⁴
Mayo ^{30,31,75}	3	20 PD+RBD/40 OSA controls ³⁰ 15 iRBD/30 OSA controls ³¹ 118 controls ⁷⁵	<ul style="list-style-type: none"> 30-s epochs: <i>Chin tonic</i> 30-s: 0.7-1.2% (sens: 100%, spec: 97-100%)^{30,31}, 95th percentile 0.99%⁷⁵ <i>Chin phasic</i> 30-s: 8.7% (sens: 87%, spec: 100%)³¹ 3-s mini-epochs: <i>Chin any</i> 3-s: 19.7-21.6% (sens: 85-87%, spec: 97-100%)^{30,31}, 95th percentile 9.1%⁷⁵ <i>Chin phasic</i> 3-s: 15.5-15.8% (sens: 85-87%, spec: 97-100%)^{30,31}, 95th percentile 8.6%⁷⁵ <i>Chin duration</i>: 0.65-0.66 seconds (sens: 90-93%, spec: 82-83%)^{30,31}, 85th percentile 1.07s⁷⁵
Prague ³²	1	77/47	<ul style="list-style-type: none"> 30-s epochs: <i>Chin tonic</i> 30-s: 2.5% (sens: 77.7-92.8%, spec: 85.8-99.2%) 3-s mini-epochs: <i>Chin phasic</i>: 8.7% (sens: 84.0-96.4%, spec: 88.9-99.9%) <i>SINBAR</i> 3-s: 10.7% (sens: 89.2-98.9%, spec: 85.8-99.2%) <i>Chin mixed</i>: 1.1% (sens: 82.4-95.5%, spec: 85.8-99.2%)

Legend: FDS, flexor digitorum superficialis; OSA, obstructive sleep apnea; PD, Parkinson's disease; RBD, REM sleep behavior disorder; REM: rapid eye movement; PD+RBD: Parkinson's disease with RBD; PDnonRBD: Parkinson's disease without RBD; sens: sensitivity; spec: specificity; SINBAR, Sleep Innsbruck Barcelona; TA, tibialis anterior.

*: when not specified, patients are isolated RBD patients and controls are healthy controls.

* For the Prague method, cut-offs have not been published in the original manuscript as mixed RWA was evaluated as a prognostic (not a diagnostic) tool. Cut-offs reported derive from the original data by courtesy of the authors.

Table 3: Overview of the currently available automated methods for RWA quantification.

Method	Brief description	Muscles investigated	Filters	Studies	Cohorts	Exclusion criteria	Artefact correction	Cut-offs and performances (sens/spec)
Supra-threshold REM activity metric (STREAM)	% 3-s REM mini-epochs with average variance above the 5 th percentile of the variances in NREM sleep.	Chin	Notch (60 Hz) and bandpass 10-70 Hz	Burns et al. ⁹¹	- 17 with NDD (9 with probable RBD) - 6 controls	None defined	No artefact removed	Cut-off 15% (sens: 100%; spec: 71% for differentiating probable RBD from other subjects)
Short and Long Muscle Activity Index (SMI, LMI)	Short (<0.5 s) and long (≥0.5 s) muscle activities identified automatically in REM sleep with smoothing and thresholding. SMI and LMI calculated as number of activities per hour of REM sleep (hREM).	Chin	Not specified	Mayer et al. ⁹²	- 34 narcolepsy type 1 with RBD - 28 iRBD - 25 controls	- REM sleep at least 5 consecutive minutes - False calibration	No artefact removed	No cut-off defined, no sensitivity and specificity provided in study
				Guttowski et	- 20 RBD)	None defined	No artefact	- Cut-off for SMI:

				al. ⁹³	- 10 somnambulism / night terror - 10 RLS - 10 OSAS		removed	90.1/hREM (sens: 85%; spec: 83.3%) - Cut-off for LMI: 43.1/hREM (sens: 75%; spec: 80%) - Cut-off for SMI+LMI not specified (sens: 72.5%; spec: 86.7%) All performance refer to the differentiation of RBD from the other groups.	
REM atonia index (RAI)	EMG signal rectified and divided into 1-s mini-epochs. For each mini-epoch <i>amp</i> = average amplitude – minimum EMG amplitude in surrounding ± 30 s moving window. RAI = % $[amp \leq 1 \mu V] / (100 - \% [1 \mu V < amp \leq 2 \mu V])$	Chin	Notch at 50 or 60 Hz and bandpass 10-100 Hz	Ferri et al. ⁴⁴	- 25 young controls - 10 aged controls - 31 untreated iRBD - 8 treated iRBD - 10 MSA (with RBD) - 5 OSAS	AHI≥5	Epochs with technical artifacts or extremely high muscle activity removed	- Cut-off 0.8 (sens: 38.5%; spec: 100%) - Cut-off 0.9 (sens: 74.3%; spec 91.4%) The performance refer to the differentiation of (iRBD +MSA) from other groups)	
				Figorilli et al. ³⁶	- 37 PD+RBD - 25 PDnonRBD	REM time <5 min		-Cut-off 0.8 (sens: 94.6%; spec 72% for differentiating patients with and without RBD)	
				Ferri et al. ³⁷	- 74 RBD patients - 75 controls	AHI>15		- Cut-off 0.8 (sens: 84%; spec: 81%) - Cut-off 0.9 (sens: 96%; spec: 51%) Performances refer to the differentiation of RBD from controls	
				McCarter et al. ³⁰	- 20 PD with RBD - 20 primary snorers - 20 OSAS	- AHI in REM>30 - REM time <5 min		In addition to the ones above, 30-s epochs with arousals, snoring or breathing events excluded	- Cut-off 0.88 (sensitivity: 95%; specificity: 92% for differentiating patients with RBD from the other groups)
				McCarter et al. ³¹	- 15 iRBD - 30 controls	- AHI>25 - REM time <5 min			- Cutoff 0.86 (sensitivity: 87%; specificity: 96% for differentiating iRBD from controls)
SINBAR	Manual identification of REM sleep periods and automatic identification of phasic, “any” and tonic muscular activity according to SINBAR definitions ¹⁴ . Calculation of RWA scores for 3-s mini-epochs as in Table 3.	Chin and bilateral FDS	Bandpass 50-300 Hz	Frauscher et al. ³⁴	- 10 iRBD - 10 RBD secondary to NDD - 60 controls	- AHI>10	Snoring artifacts, ECG artifacts and EMG activity in the context of arousals manually removed.	- Cutoff 16.3% for chin phasic 3-s (sens: 90%; spec: 68%) - Cutoff 18.2% for any chin 3-s (sens: 90%; spec: 67%) - Cutoff 9.6% for tonic chin 3-s (sens: 75%; spec: 98%) - Cutoff 32% for SINBAR 3-s (sens: 89%; spec: 83%)	

								All performances refer to the differentiation of (iRBD, RBD) from controls.
Frandsen	% of 3-s mini-epochs of REM sleep with muscle activity, defined as exceeding four times the baseline calculated in a moving window of 60 mins, minimum length of 0.3 s and inter-event interval of at least 0.5 s.	Chin	Notch 50 Hz and bandpass 10-70 Hz	Frandsen et al. ⁹⁴	- 29 iRBD - 29 controls - 44 PD patients	AHI>15	No artefact removed	- Cutoff 30% (sens: 52%; spec: 100%) - Cutoff 20% (sens: 62%; spec: 82.8%) - Cutoff 10% (sens: 65%; spec: 75.8%) All performances refer to the differentiation of iRBD from controls and PD patients.
Kempfner	The EMG signals are divided in 3-s mini-epochs and features are extracted from each mini-epoch. A one-class support vector machine classifies each mini-epoch as normal or abnormal and the score S is calculated as the percentage of 3-s mini-epochs in REM sleep with abnormal muscular activity.	Chin and bilateral TA	Notch at 50 Hz and bandpass 30-65 Hz	Kempfner et al. ^{95,96}	- 16 iRBD - 16 PLMD - 16 controls	Patients with OSAS excluded	No artefact removed	Cutoff on S not clearly specified (sens: 100%; spec: 100% for differentiating iRBD from controls and PLMD patients)
Cesari	A data-driven model of muscular activity is used to calculate the percentage of muscular activity in 1-s mini-epochs and the average distance between muscular activities in REM and NREM sleep in the three muscles. These features are the input of a machine learning classifier that gives the probability having RBD (pRBD) as output.	Chin and bilateral TA	Notch 50 Hz and bandpass 10-70 Hz	Cesari et al. ⁴⁶	- 29 RBD - 27 healthy controls - 36 PLMD	None	No artefact removed	Cutoff on p(RBD) at 0.34 (sens: 73.4%; spec: 84% for differentiating RBD from controls and PLMD patients)
				Cesari et al. ⁴⁷	- 94 controls - 31 iRBD - 85 PDnonRBD - 30 PD+RBD			- Cutoff on p(RBD) at 0.34 (sens: 51.6%; spec: 96.8% for differentiating iRBD from controls; sens: 66.67%; spec: 88.24% for differentiating PD+RBD from PDnonRBD)

Legend: AHI: apnea-hypopnea index; iRBD: isolated RBD; MSA: multiple system atrophy; NDD: neurodegenerative disease; OSAS: obstructive sleep apnea; PDnonRBD: Parkinson's disease without RBD; PD+RBD: Parkinson's disease with RBD; PLMD: periodic limb movement disorder; RBD: REM sleep behavior disorder; RLS: restless leg syndrome; sens: sensitivity; spec: specificity; TA: tibialis anterior.

Table 4: REM sleep behavior disorder severity scale (RBDSS)⁶²

Motor events	Vocalizations
<p>0. = no visible motor activity, RWA present</p> <p>only definition criteria of RWA according to ICSD are fulfilled, no other phasic muscle activity in the limbs or face is visible or obvious on recording</p> <p>1. = distal or short movements</p> <p>isolated, single hand or foot movements or facial jerks visible, restricted to the distal extremities and/or face</p> <p>2. = proximal movements</p> <p>single movements or series of movements including proximal extremities, no change of position</p> <p>3. = axial movements</p>	<p>.0 = no vocalization</p> <p>snoring with some sound may be present and should be differentiated from REM associated vocalization</p> <p>.1 all sleep associated sounds other than respiratory noises</p> <p>talking, shouting, murmuring, laughing or screaming, either tonic or phasic are present during at least one REM episode</p>

Legend: ICSD: International Classification of Sleep Disorders; REM: rapid eye movement; RWA: REM sleep without atonia.

1

FIGURES

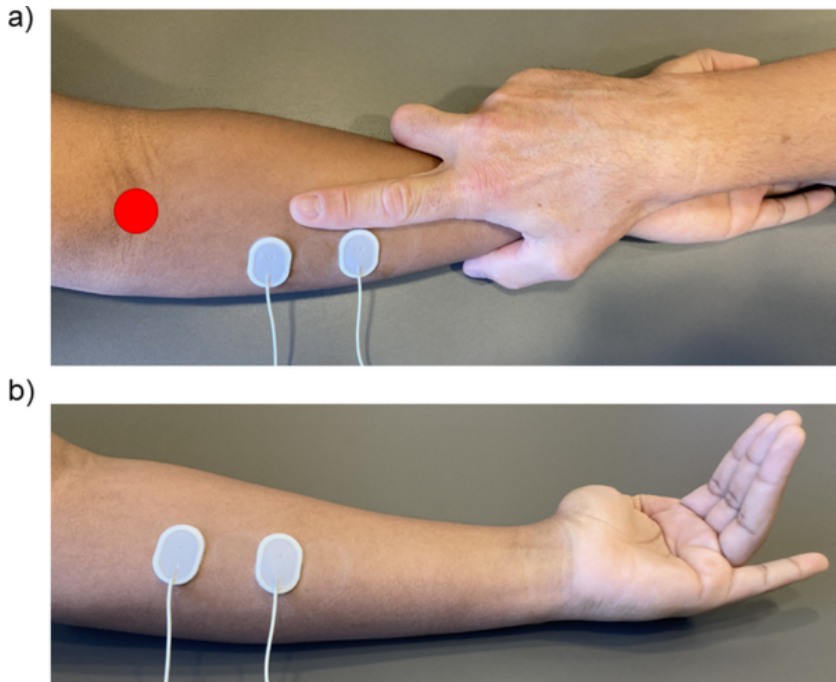


Figure 1: Techniques for placement and to document appropriate activation of surface EMG electrodes on the FDS muscle. a) To place the surface EMG electrodes on the FDS muscle, the technician's palm of the hand is placed over the patient's wrist, with index finger directed towards the biceps brachii tendon (red dot). The electrodes are placed on the medial side of the forearm, so that they are 2-3 cm apart. b) Appropriate position of the electrodes is checked by asking the patient to flex digits II to IV at the base while avoiding bending the distal two joint and keeping digit V extended.

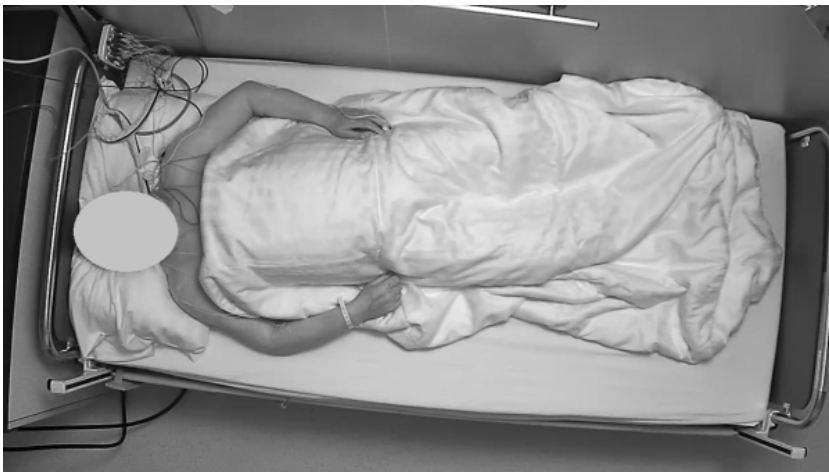

Figure 2: Example of image of a high-density camera. Note that the resolution of the camera is high enough to allow zooming without loss of quality.

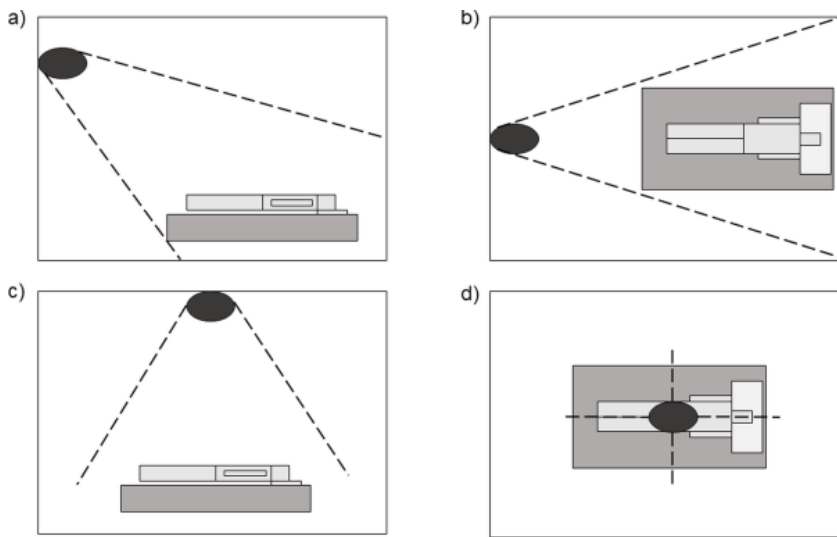


Figure 3: Recommended positions of the camera for video-polysomnography recording in the context of RBD and prodromal RBD. The camera can be mounted on the wall in front of the patient (a: view from the side, b: view from above) or the ceiling on top of the bed (c: view from the side, d: from above). Modified from Vandi¹².

1

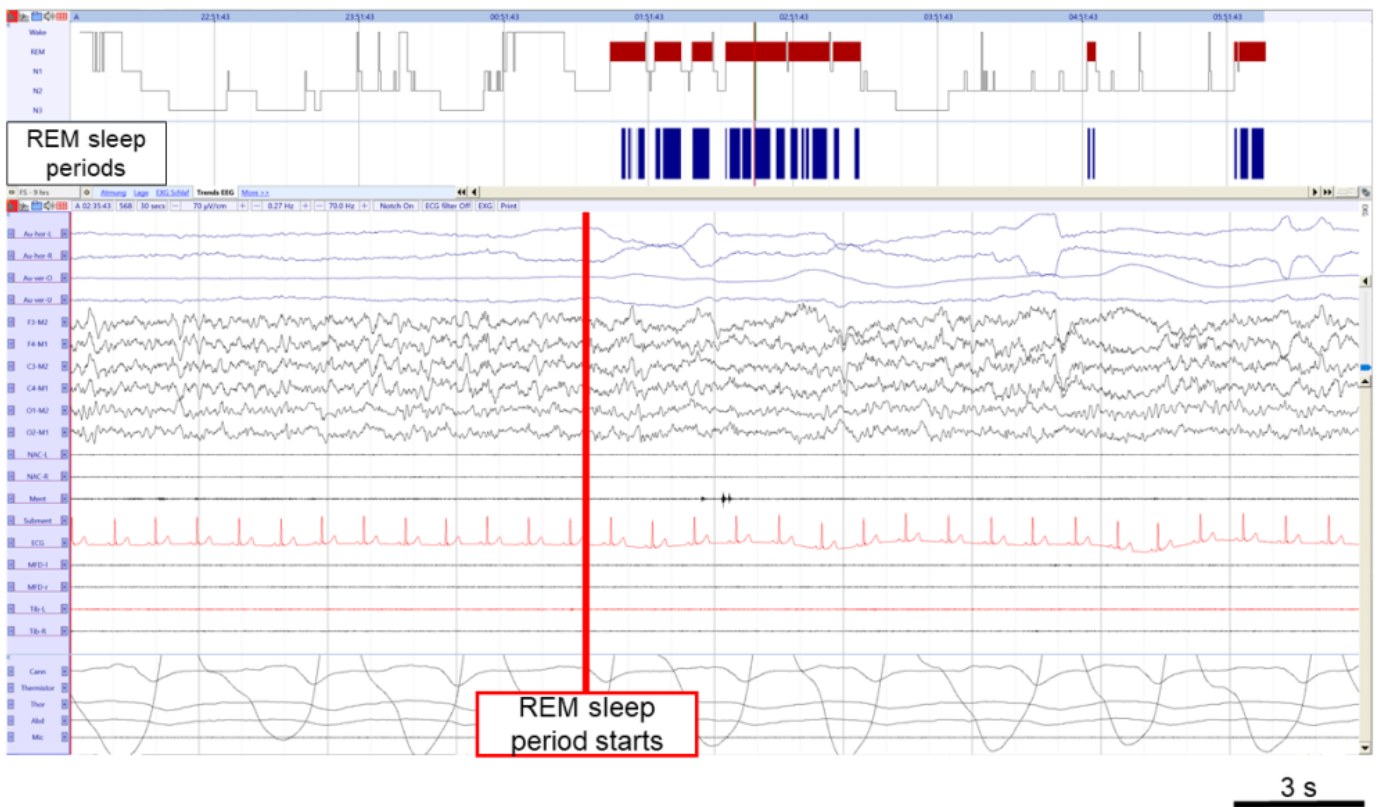


Figure 4: Example of start of a REM sleep period. The REM sleep periods selected for quantification of RWA are shown in blue and it can be seen that they are included in REM sleep epochs. The start of a REM sleep period is set at the beginning of a 3-s mini-epoch where a rapid eye movement is present. Legend: Au-hor-L: left horizontal electrooculogram (EOG); Au-hor-R: right horizontal EOG; Au-ver-O: vertical upper EOG; Au-ver-U: vertical lower EOG; NAC-L: splenius capitis muscle left; NAC-R: splenius capitis muscle right; Ment: mentalis muscle; Subment: submental EMG; ECG: electrocardiogram; MDF-l: left flexor digitorum superficialis (FDS) muscle; MDF-r: right flexor digitorum superficialis muscle; Tib-L: left anterior tibialis muscle; Tib-R: right anterior tibialis muscle; Cann: cannula; Thor: thorax; Abd: abdomen; Mic: microphone; EMG: electromyogram; REM: rapid eye movement; RWA: REM sleep without atonia.

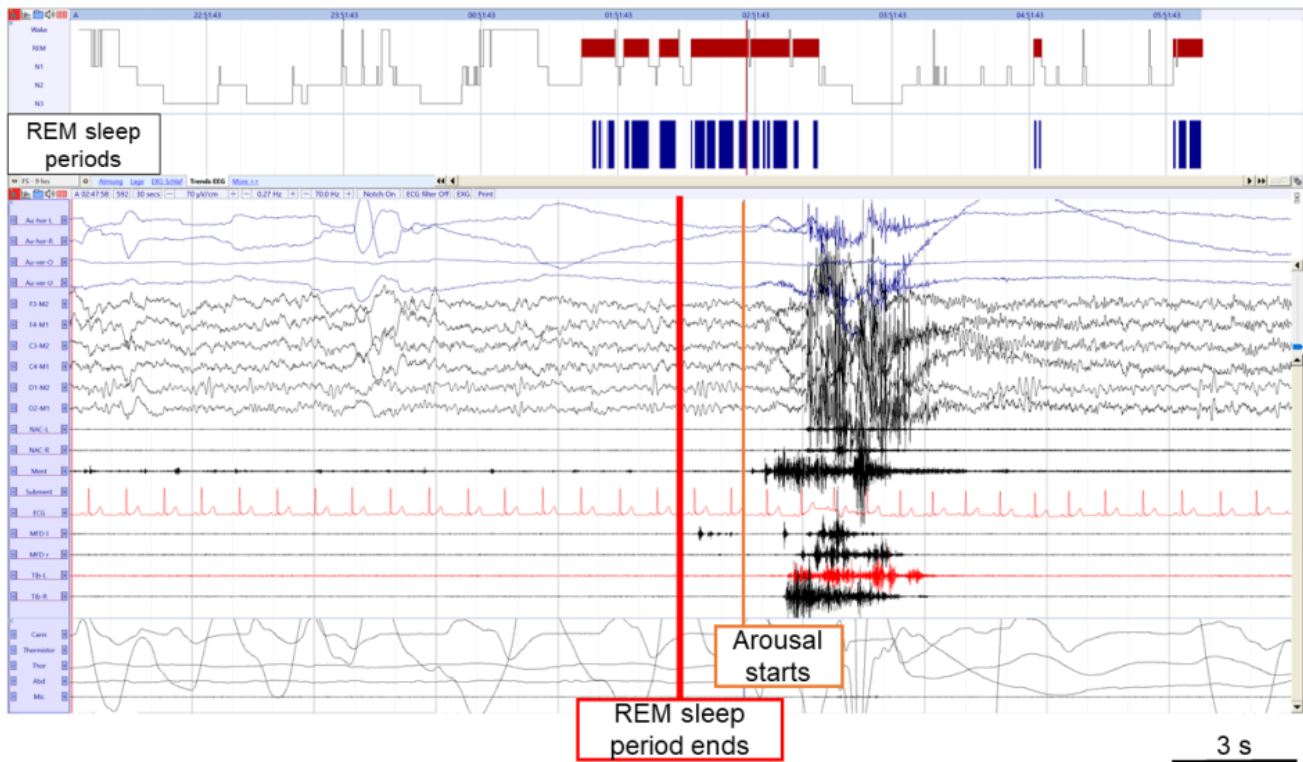


Figure 5: Example of end of a REM sleep period. The REM sleep periods selected for quantification of RWA are shown in blue and it can be seen that they are included in REM sleep epochs. The end of a REM sleep period is set at the end of a 3-s mini-epoch before a 3-s mini-epoch an arousals. *Legend:* Au-hor-L: left horizontal electrooculogram (EOG); Au-hor-R: right horizontal EOG; Au-ver-O: vertical upper EOG; Au-ver-U: vertical lower EOG; NAC-L: splenius capitis muscle left; NAC-R: splenius capitis muscle right; Ment: mentalis muscle; Submen: submental EMG; ECG: electrocardiogram; MDF-l: left flexor digitorum superficialis (FDS) muscle; MDF-r: right flexor digitorum superficialis muscle; Tib-L: left anterior tibialis muscle; Tib-R: right anterior tibialis muscle; Cann: cannula; Thor: thorax; Abd: abdomen; Mic: microphone; EMG: electromyogram; REM: rapid eye movement; RWA: REM sleep without atonia.

1

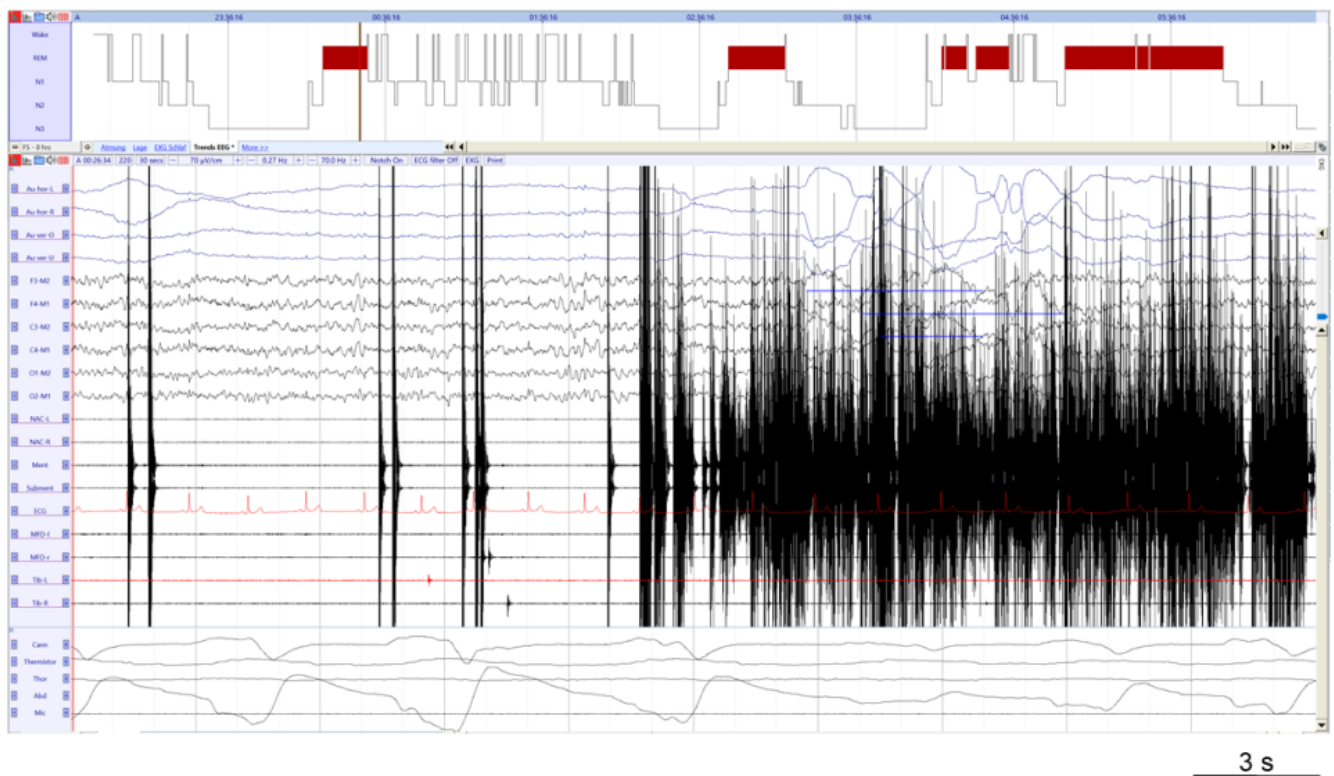


Figure 6: Example of electrode artefacts in the mentalis and submental EMG channels. *Legend:* Au-hor-L: left horizontal electrooculogram (EOG); Au-hor-R: right horizontal EOG; Au-ver-O: vertical upper EOG; Au-ver-U: vertical lower EOG; NAC-L: splenius capitis muscle left; NAC-R: splenius capitis muscle right; Ment: mentalis muscle; Subment: submental EMG; ECG: electrocardiogram; MDF-l: left flexor digitorum superficialis (FDS) muscle; MDF-r: right flexor digitorum superficialis muscle; Tib-L: left anterior tibialis muscle; Tib-R: right anterior tibialis muscle; Cann: cannula; Thor: thorax; Abd: abdomen; Mic: microphone; EMG: electromyogram.

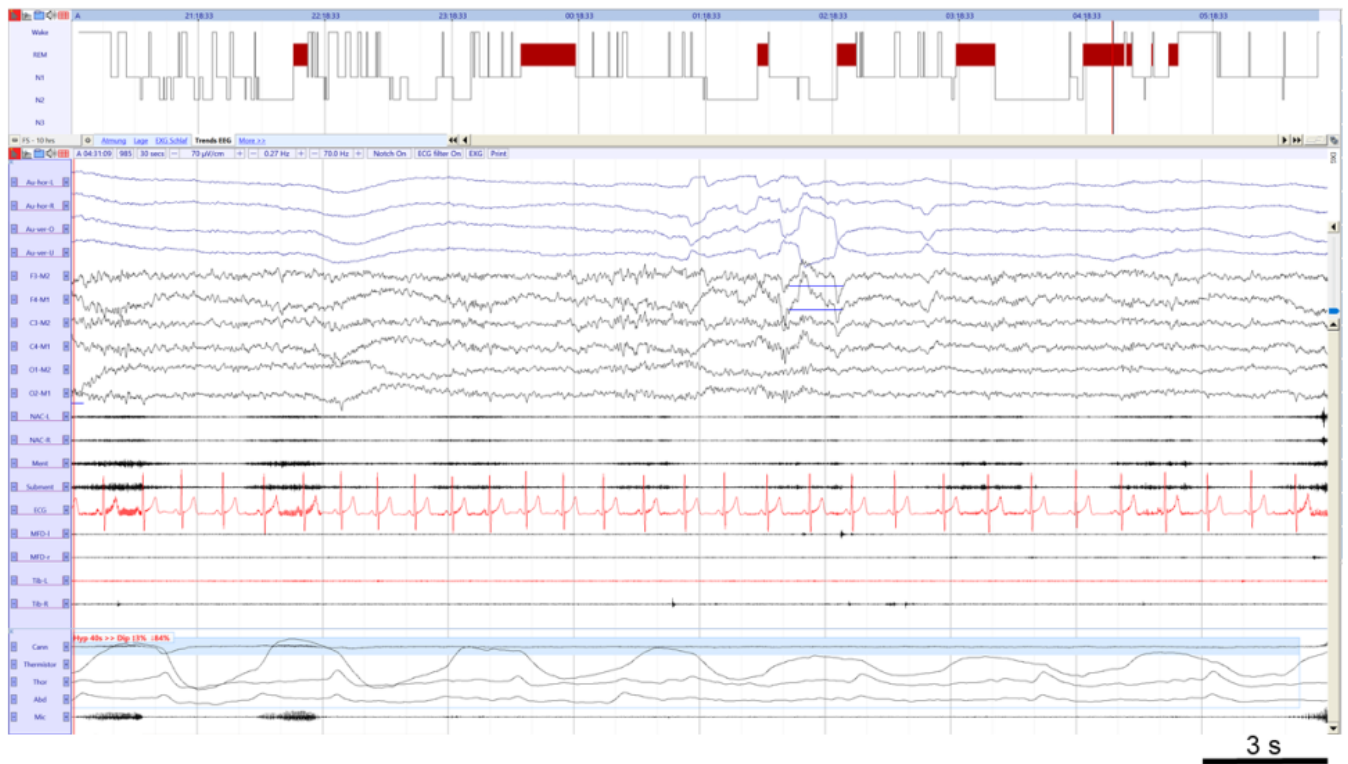


Figure 7: Example of respiration artefacts in the mentalis and submental EMG channels. It can be noted that respiration effort during the hypopnea (Hyp, highlighted in blue) is seen in the mentalis and submental EMG channels. *Abbreviations:* Au-hor-L: left horizontal electrooculogram (EOG); Au-hor-R: right horizontal EOG; Au-ver-O: vertical upper EOG; Au-ver-U: vertical lower EOG; NAC-L: splenius capitis muscle left; NAC-R: splenius capitis muscle right; Ment: mentalis muscle; Subment: submental EMG; ECG: electrocardiogram; MDF-l: left flexor digitorum superficialis (FDS) muscle; MDF-r: right flexor digitorum superficialis muscle; Tib-L: left anterior tibialis muscle; Tib-R: right anterior tibialis muscle; Cann: cannula; Thor: thorax; Abd: abdomen; Mic: microphone; EMG: electromyogram.

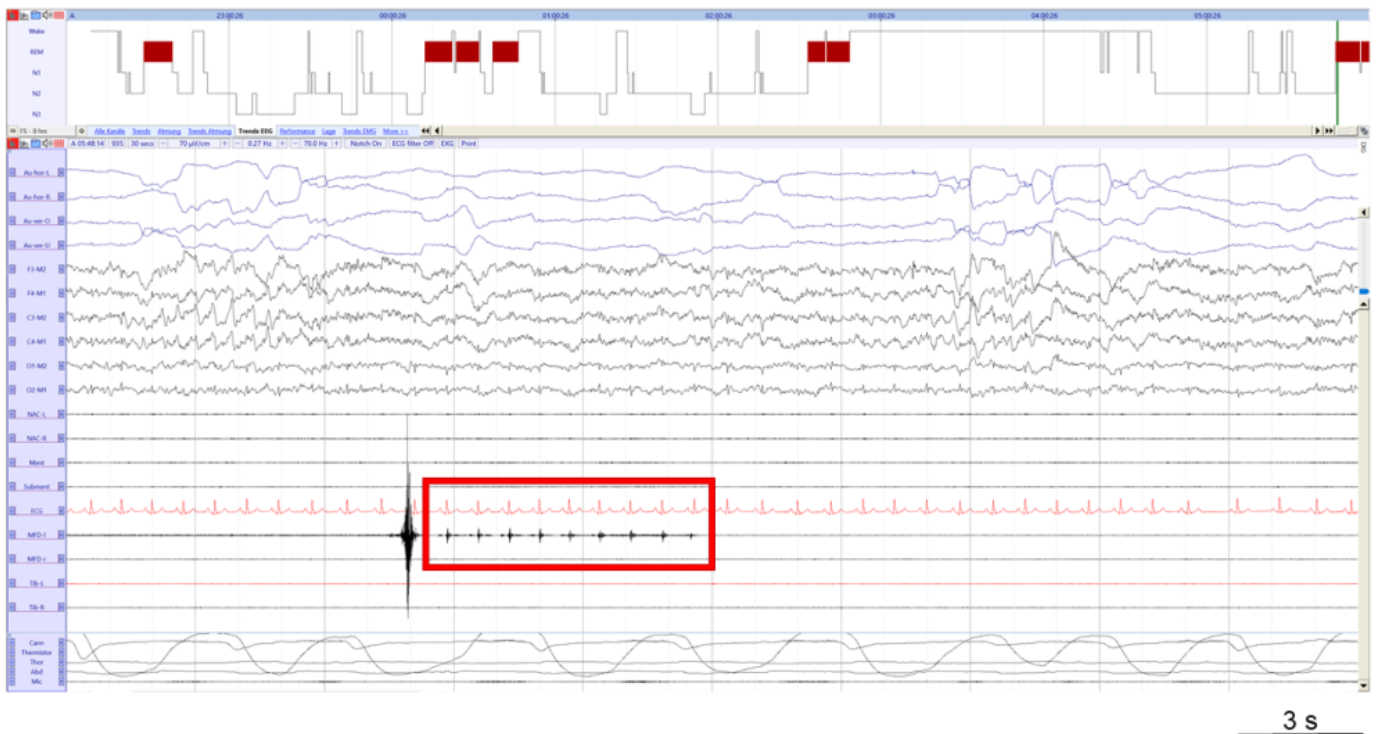


Figure 8: Example of ECG artefact on FDS left muscle. The ECG artefact is highlighted by the red box. *Abbreviations:* Au-hor-L: left horizontal electrooculogram (EOG); Au-hor-R: right horizontal EOG; Au-ver-O: vertical upper EOG; Au-ver-U: vertical lower EOG; NAC-L: splenius capitis muscle left; NAC-R: splenius capitis muscle right; Ment: mentalis muscle; Subment: submental EMG; ECG: electrocardiogram; MDF-l: left flexor digitorum superficialis (FDS) muscle; MDF-r: right flexor digitorum superficialis muscle; Tib-L: left anterior tibialis muscle; Tib-R: right anterior tibialis muscle; Cann: cannula; Thor: thorax; Abd: abdomen; Mic: microphone; EMG: electromyogram.

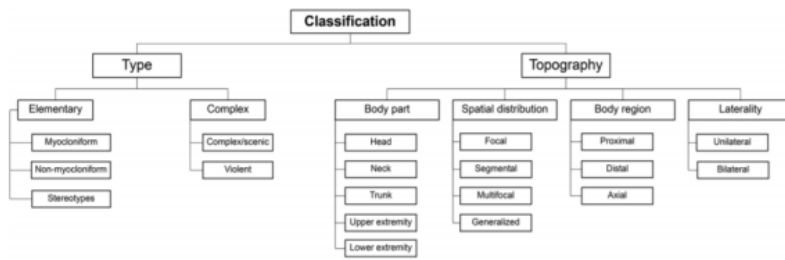


Figure 9: Classification method for visible movements proposed by the Innsbruck group^{33,58}.

^[a] Quantification of chin tonic EMG activity for 3-s mini-epochs is included only in the SINBAR scoring method

^[b] Based on sparse literature and expert opinion. Cutoff for AHI during REM sleep to allow correct quantification of RWA might be modified once more evidence from future studies is available.

^[c] Such bursts are by definition interference, but in the context of RWA quantification have been referred to as artefacts^{14,30–32}.

^[d] In subjects exhibiting at least one RBD episode during v-PSG, but without RWA, RBD may be provisionally diagnosed. In these subjects, subsequent v-PSGs will confirm or exclude the diagnosis of RBD.

^[e] In subjects without any RBD episode during v-PSG, but with RWA and a clear history of dream enactment, RBD may be provisionally diagnosed. In these subjects, subsequent v-PSGs will confirm or exclude the diagnosis of RBD.

^[f] Quantification of chin tonic EMG activity for 3-s mini-epochs is included only in the SINBAR scoring method

^[g] Two or more than 2 RBEs have been proposed to identify prodromal RBD. For simplification and harmonization, we suggest to use motor events as defined in section 5 for the identification of prodromal RBD, as these include also RBE. In the context of prodromal RBD, vocalizations have not been systematically evaluated, and are therefore not included here.