



Forensic applications of micro-computed tomography: a systematic review

Giorgia Franchetti¹ · Guido Viel¹ · Paolo Fais² · Giulia Fichera³ · Diego Cecchin⁴ · Giovanni Cecchetto¹ · Chiara Girauda⁵ 

Received: 29 April 2022 / Accepted: 4 July 2022 / Published online: 26 July 2022
© The Author(s) 2022

Abstract

Purpose The aim of this systematic review was to provide a comprehensive overview of micro-CT current applications in forensic pathology, anthropology, odontology, and neonatology.

Methods A bibliographic research on the electronic databases Pubmed and Scopus was conducted in the time frame 01/01/2001–31/12/2021 without any language restrictions and applying the following free-text search strategy: “(micro-computed tomography OR micro-CT) AND (forensic OR legal)”. The following inclusion criteria were used: (A) English language; (B) Application of micro-CT to biological and/or non-biological materials to address at least one forensic issue (e.g., age estimation, identification of post-mortem interval). The papers selected by three independent investigators have been then classified according to the investigated materials.

Results The bibliographic search provided 651 records, duplicates excluded. After screening for title and/or abstracts, according to criteria A and B, 157 full-text papers were evaluated for eligibility. Ninety-three papers, mostly (64) published between 2017 and 2021, were included; considering that two papers investigated several materials, an overall amount of 99 classifiable items was counted when referring to the materials investigated. It emerged that bones and cartilages (54.55%), followed by teeth (13.13%), were the most frequently analyzed materials. Moreover, micro-CT allowed the collection of structural, qualitative and/or quantitative information also for soft tissues, fetuses, insects, and foreign materials.

Conclusion Forensic applications of micro-CT progressively increased in the last 5 years with very promising results. According to this evidence, we might expect in the near future a shift of its use from research purposes to clinical forensic cases.

Keywords Micro-radiology · Microcomputed tomography · Forensic pathology · Forensic anthropology · Medico-legal sciences

Introduction

Microcomputed tomography (micro-CT) is a non-destructive technique allowing the acquisition of high-resolution cross-sectional images with pixel size in the micrometer range. Since the development of the first micro-CT scanner by Lee Feldkamp to assess defects of ceramic automotive [1], the technical and informatic progress led to a broader and faster use of this type of pre-clinical devices. Indeed, the most recent scanners enable the acquisition of large datasets and very accurate three dimensional (3D) reconstructions in a few minutes. Over time, micro-CT has been successfully used in various research areas including electronics, archeology, food industry, geology, and most of all in the biomedical field [1–6]. Within the biomedical area, in addition to cardiovascular, orthopedic, and pulmonary analyses [7, 8],

✉ Chiara Girauda
chiara.girauda@unipd.it

¹ Department of Cardiac, Thoracic, Vascular Sciences and Public Health, University of Padova, Padua, Italy

² Department of Medical and Surgical Sciences, Institute of Legal Medicine, University of Bologna, Bologna, Italy

³ Pediatric Radiology Unit, University Hospital of Padova, Padua, Italy

⁴ Unit of Nuclear Medicine, Department of Medicine–DIMED, University of Padova, Padua, Italy

⁵ Unit of Advanced Clinical and Translational Imaging, Department of Medicine–DIMED, University of Padova, Via Giustiniani 2, 35100 Padua, Italy

in the last decade, forensic applications have progressively increased [9]. In fact, for instance, the knowledge acquired performing skeletal analyses for orthopedic purposes has been transposed to the forensic field to investigate bone characteristics and lesions in different contexts. In particular, the possibility to collect qualitative and quantitative information has been applied to characterize and estimate, among others, bone saw marks and gunshot residues (GSR). It should not be overlooked that in forensics, also anthropology benefited of the advantages carried by the use of micro-CT.

Given the growing interest into the use of micro-CT in the forensic field, the aim of this systematic review was to provide a comprehensive overview of the current main applications of this tool in forensic pathology, anthropology, odontology, and neonatology to further promote its use in medico-legal cases.

Materials and methods

Bibliographic search strategy

A bibliographic research on the electronic databases PubMed and Scopus was conducted applying the following time frame 01/01/2001–31/12/2021, without any restrictions to language, and using the following free-text protocols search strategy: “(micro-computed tomography OR micro-CT) AND (forensic OR legal)”.

Duplicates were removed using Zotero.

Paper selection

The following inclusion criteria have been applied:

- A. English language;
- B. Application of micro-CT to biological and/or non-biological materials to address at least one specific forensic issue (e.g., age estimation, identification of post-mortem interval, wound chronology, tool marks, gunshot wounds, injuries, firing distance).

A team composed of two forensic pathologists and one radiologist with expertise in forensic pathology selected records by title and abstracts, according to the above-mentioned criteria.

The retrieved articles were then analyzed in full-text and selected according to the above-mentioned A and B criteria and the following exclusion criteria:

- C. Application of micro-CT on archeological material because beyond the scope of the review;
- D. Editorials, letters to the Editor, opinion papers, commentaries, congress papers, narrative reviews without novel data (i.e., without statistics).

For each step of the selection, discrepancies among the raters were solved by a consensus process until unanimous agreement was reached.

Data extraction and paper classification

Three independent blinded investigators collected study characteristics and classified each selected paper according to one or more of the following subcategories, coinciding with the biological/non-biological materials under investigation: (i) Bones and cartilages; (ii) Teeth; (iii) Soft tissues; (iv) Blood; (v) Fetuses; (vi) Insects; (vii) Foreign materials.

The results are presented and discussed in the results and discussion section, which is divided into paragraphs pertaining to the material under investigation and/or to the aim of the micro-CT analysis.

Results and discussion

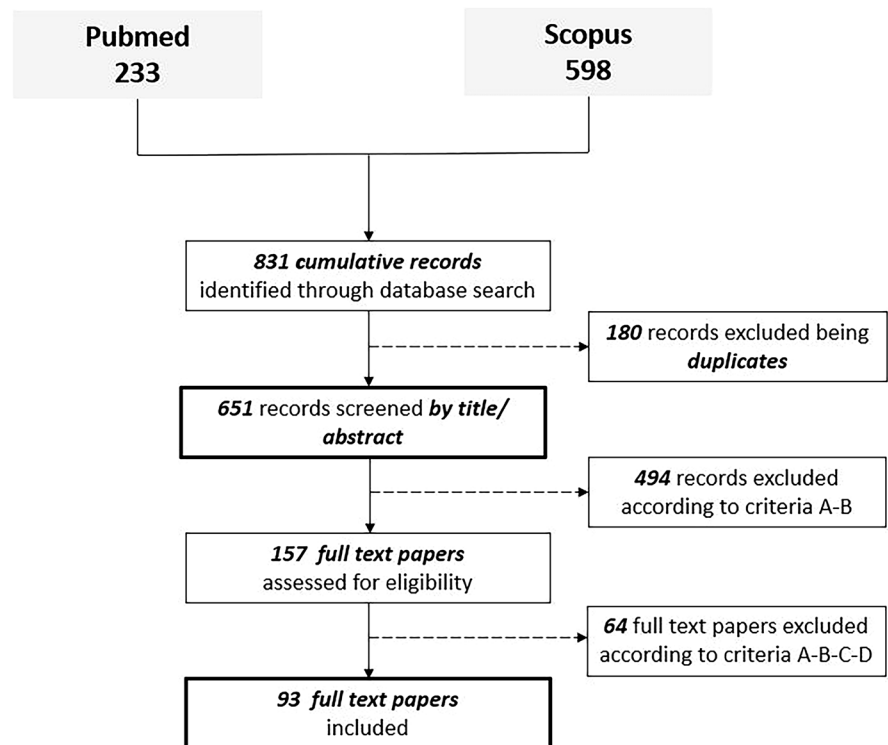
Paper selection and classification

The bibliographic search provided an overall amount of 651 records, duplicates excluded. After screening for title and/or abstracts, according to criteria A and B, 157 full-text papers were evaluated for eligibility. According to criteria A, B, C and D, 93 papers (14.28% of the total records, duplicates excluded) were included (Fig. 1).

As depicted in Fig. 2A, most of the papers (64) were published between 2017 and 2021, highlighting an increasing interest for forensic micro-CT applications in the last five years.

Assessing the full-text of each included article according to the above-mentioned list of materials, it emerged that two papers investigated multiple materials [19, 28]. In particular one study was focused on two (bones and foreign objects) [28] and the other one on six materials (i.e., bones, teeth, soft tissues, embryos, foreign objects, and insects) [19]. Aiming to do not introduce any bias related to a potential selection/exclusion of investigated materials, we considered each material assessed in the two above-mentioned papers [19, 28] as an independent classifiable item. Thus, as follows, for all calculations regarding the investigated materials, absolute numbers and percentages refer to 99 classifiable items (see Supplemental material for classification data). Bones and cartilages were the most frequent materials investigated by micro-CT (i.e., 54 out of 99, 54.55%), followed by teeth (i.e., 13 out of 99, 13.13%), embryos and fetuses (i.e., 12 out of 99, 12.12%), foreign materials (i.e., 11 out of 99, 11.11%), soft tissues (i.e., 4 out of 99, 4.04%), insects (i.e., 3 out of 99, 3.03%) and blood (i.e., 2 out of 99, 2.02%) (Fig. 2B).

Fig. 1 Prisma flow chart



Bones and cartilages

Regarding bone and cartilage, micro-CT has been used for evaluating morphometric features and to obtain detailed information about tissue micro-architecture and composition.

Fracture

Micro-CT is a non-destructive and highly sensitive technique for detecting and characterizing skeletal injuries (Fig. 3A). One of the main advantages for this type of evaluations is represented by the chance to obtain multi-planar and volumetric images (Fig. 3B). For example, it has been used to identify pediatric rib fractures in cases of child abuse [10, 11] or to evaluate full-thickness fractures of the skull in cases involving blunt force trauma [12]. Recently, the application of 3D printing technology for court use has been proposed, creating models of fragmented skeletal remains or bone injuries based on micro-CT scans, to replicate the bone surface geometry with a sub-millimeter accuracy [13–15].

Moreover, high-definition 3D reconstructions of micro-CT images of the larynx allowed the detection of thin fracture lines of the superior horn of the thyroid cartilage and of the hyoid bone (Fig. 3C) in cases of strangulation [11, 16], also when advanced decomposition precluded the detection of soft tissues injuries [17]. Moreover, micro-CT

has been proved useful to identify morphological features observable in the normal population which might have been misinterpreted as real fractures (i.e., discontinuity on the inferior thyroid margin) [18].

Last, but not least, the identification of chronic osteomyelitis, syphilis, hyperostosis frontalis interna, hyperparathyroidism, and osteomyelosclerosis by micro-CT demonstrated to be useful in predicting the risk of fractures or clarifying the effects of blunt/sharp force traumas [19].

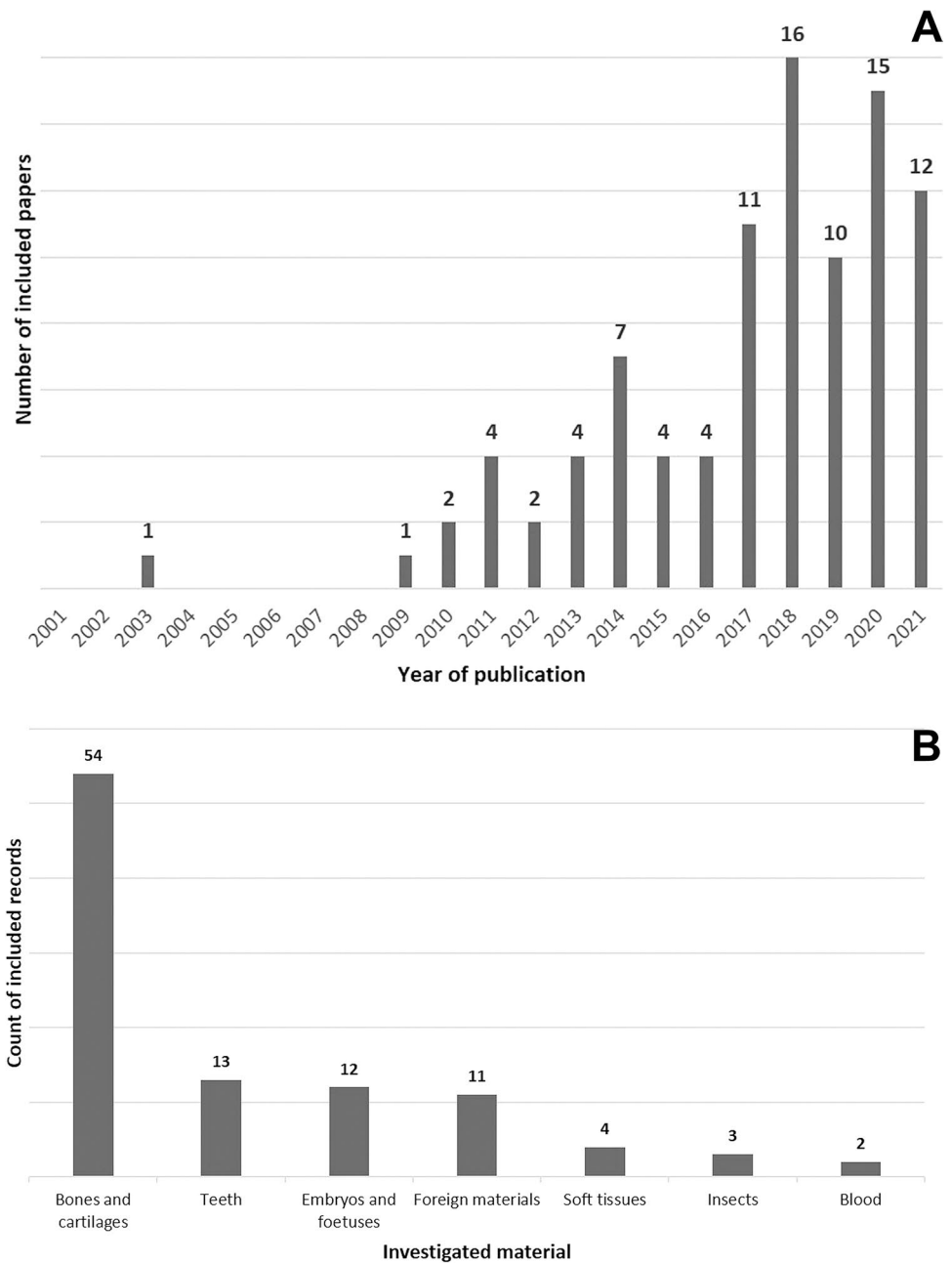
Gunshot wound

Micro-CT has been applied to evaluate the features of gunshot wounds on different bones (i.e., skull, scapulae, ribs, femurs, tibiae, fibulae and vertebrae) [20–24].

Concerning gunshot wounds produced on “sandwich bones” by projectiles with different velocities, it has been demonstrated that at lower velocity, circular depressed fractures of the outer cortex exhibiting angulated cortical fracture edges occurred, whereas at higher velocity, translaminar fractures were produced. Finally, at the highest velocities, conoids were fragmented [25, 26].

Moreover, micro-CT allowed the characterization of the keyhole pattern of cranial gunshot wounds as well as the identification of secondary and tertiary fractures, demonstrating perpendicular or tangential gunshot paths [27].

Fig. 2 In **A**, histogram showing the distribution of the included papers which have been published in the selected time interval (i.e., from 2001 to 2021) and demonstrating the increasing interest in the topic in the last five years; in **B** types of biological or non-biological materials investigated by micro-CT in the 93 included papers (i.e., in two of the included studies more than one biological or non-biological material was investigated; therefore, a total 99 classifiable items was considered. See Supplemental material for detailed classification data)



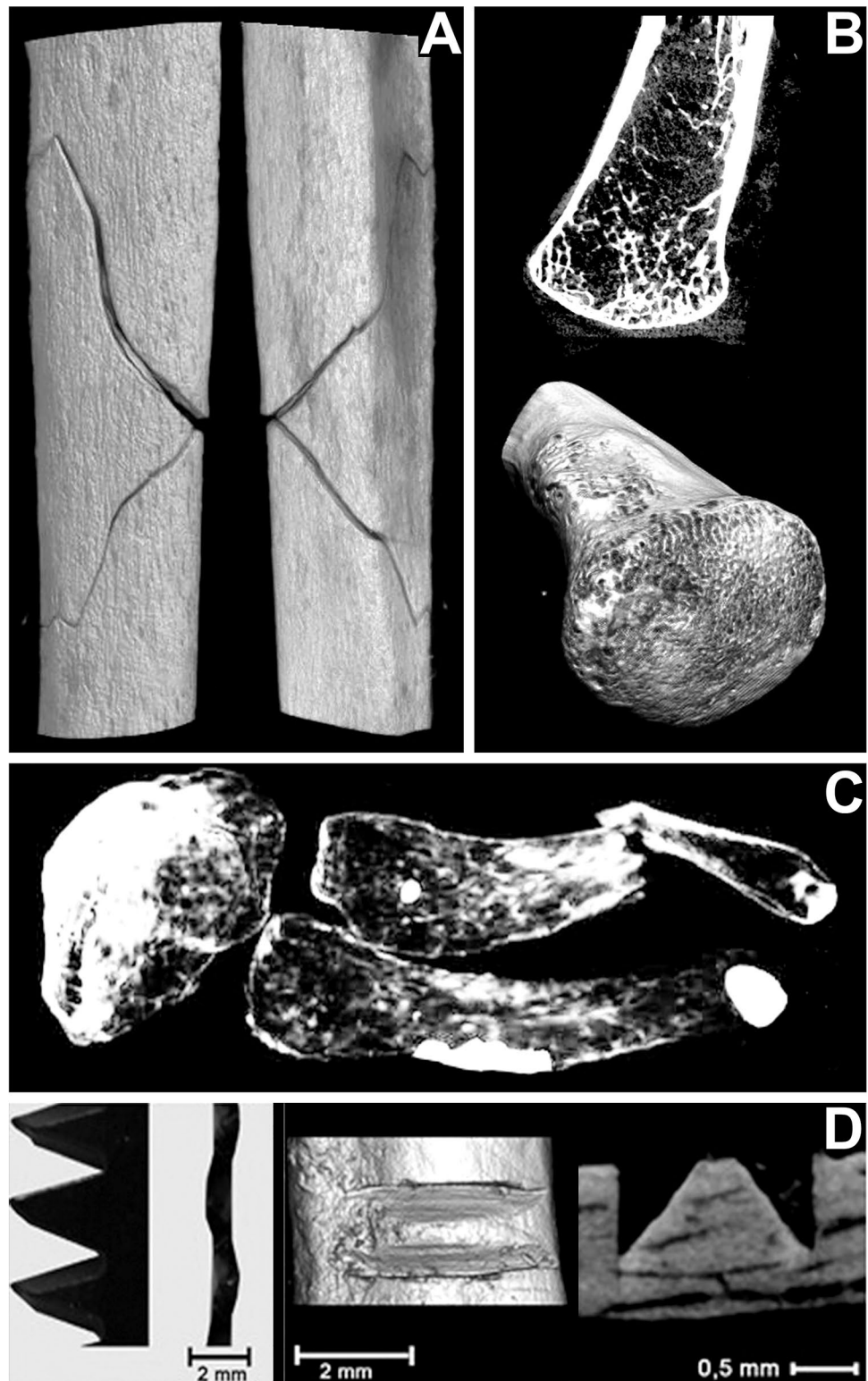
Tool mark

The analysis of the size and shape of tool marks on human bones is crucial for the identification of the type of tool which caused the injuries, such as hatchets, knives, and saws.

Micro-CT was first applied by Thali et al. [28] to examine bone marks produced by knives. Also the skeleton of King Richard III has been investigated by micro-CT to characterize the injuries and establish the most probable cause of death. The analyses revealed several peri-mortem wounds in the skull, ribs, and pelvis, consistent with those created by weapons from the later medieval period [29].

Afterward, several experimental studies have demonstrated that micro-CT is useful to document the morphology (i.e., shape, walls, floor, angles) of stab wounds on cartilage and bones (i.e., without maceration) being even more accurate than macrophotography and scanning electron microscopy [30]. A proposed qualitative tool mark classification allowed the distinction between the weapon causing the injury (i.e., hatchet, knife) as well as the estimation of the trajectory used at tool impact [31, 32]. Moreover, performing quantitative analysis morphometric information of stabbed bones (i.e., width, wall angle, floor radius) was collected with an inter-observer agreement higher than with

Fig. 3 Bones forensic analysis by Micro-CT. In **A**, butterfly fracture of a human fibula; in **B**, high-resolution MPR and 3D surface reconstructions of the medial extremity of a human clavicle; in **C**, fracture of the greater horn of the hyoid bone; in **D**, saw marks on bone samples (i.e., all unpublished data belonging to authors' casework)



light microscopy [33, 34]. Together, the results of several experimental studies demonstrated the value of this technique for measuring saw mark features (i.e., top and bottom kerf width, depth, angles degrees, and floor width) validating its use for this type of injuries. Particularly, micro-CT

analysis of false starts (Fig. 3D) produced by different hand saws on human bones allowed the correct coupling of tool marks and classes of saws [35, 36] and also the differentiation of false starts produced by saws belonging to the same class [37], with a high level of accuracy and precision [38].

Moreover, a random forest statistical regression model was proposed to enable prediction of saw blade thickness from empirical data [39] and 3D printed models deriving from micro-CT scans were used in forensic cases of dismemberment to detect several cut marks and false starts and identify the tools used by the murderer [40].

Last, in cases of blunt force trauma, such as aggression or road accident, micro-CT has been used to scan bone injuries (e.g., depressed fractures or superficial marks) and collect quantitative data (i.e., measures of the wounds), to identify the means of production and consequently to reconstruct the exact dynamics of the event [12, 41].

Post-traumatic survival time estimation

The first study concerning this topic on a piglet model is dated 2013 [42]; desiccated (post-mortem) and fresh (peri-mortem) rib fractures, produced by compression, were analyzed discovering that on fresh sample the injury did not affect the cortical bone but caused only periosteal tearings [42, 43]. Moreover, the analysis of skull fractures allowed the evaluation of the contours of the fracture and the assessment of the internal micro-architecture of the callus characterizing early signs of bone healing [44–46]. Recently, micro-CT has been used to test if bone mineral density could be useful for differentiating vital from post-mortem mandibular fractures, showing that bone mineral density decreased after a natural putrefaction period of 12 weeks maintaining a statistically significant difference between ante- and post-mortem fractures [47].

In conclusion, although histology remains the gold standard for analyzing fractures occurred in the ante-mortem, peri-mortem or post-mortem periods, the above-mentioned preliminary studies indicate that also micro-CT analysis can provide detailed information on the bone and cartilages potentially useful to estimate the time frame between injury production and death (i.e., the so-called “post-traumatic survival time”).

Anthropological investigations

Micro-radiological analysis of nutrient foramina in long bone shafts has been performed to measure the shape of the canal entrance and its angle with the cortical bone, allowing the distinction between human and non-human highly fragmented or incomplete bones [48, 49].

By micro-CT scans of skulls, the measurement of three referring lines (i.e., asterion–porion, mastoideale–porion, asterion–mastoideale) and the area of the deriving triangle have been proposed, showing that morphometric variables of the mastoid process reflect sexual dimorphism in the Brazilian population [50]. The examination of the internal acoustic meatus has revealed that in adults the angle at

the level of the transverse crest of the fundus is significantly greater in females than in males [51]. Therefore, currently, micro-radiology can be used as a preliminary screening tool for sex identification also in cases of fragmented skulls.

Regarding the age-at-death estimation, morphometric properties of the trabecular micro-architecture of bones belonging to several different anatomical districts have been investigated demonstrating that several quantitative parameters change with age. In fact, for instance, the thickness of the trabeculae in the iliac and pubic bone [52, 53] and bone volume, mineral density, and the number of trabeculae of the medial clavicle [54] increased with age while the trabecular bone volume in the posterior part of the auricular surface decreased with age [55] (Fig. 3B). On the contrary, the degree of closure of the sagittal suture seems to not be related to aging [56].

Post-mortem interval (PMI) estimation

PMI estimation of human skeletons is very important in forensic medicine. Firstly, micro-CT has been used to assess the role of bone density in estimating PMI [57]. It emerged that after 1 month, bone samples extracted from a fresh human vault showed a decrease of mean bone volume, bone surface, and trabecular number, whereas the mean trabecular separation and trabecular thickness increased [58, 59]. Moreover, during the first 2 weeks of post-mortem, a significant decrease of the ratio between bone surface and bone volume and of the average distance between the trabeculae was observed [60].

Cremation temperature estimation

The use of micro-CT provided crucial information for the estimation of the cremation temperature of burned human remains. Indeed, it is well known that skeletal hard tissues exposed to heat are subjected to shrinkage and a recent study on experimentally burned ribs showed an increase of the average heat-induced volumetric shrinkage with the increase of the temperature [61]. Mckinnon and colleague using incinerated bovine long bones samples demonstrated that the changes in porosity are non-exponential [62]. In fact, they observed an initial decrease of porosity at lower temperatures (100–200°) which might be due to the loss of organic materials and an increase of porosity at around 500° that could be caused by hydroxyapatite re-crystallization [62].

Furthermore, the analysis of injured ribs exposed to heat showed that the burning process and the related bone shrinkage did not significantly influence cut marks [63].

Teeth

Micro-CT enables accurate analyses of the micro-structure of the enamel, dentine, and pulp cavity which can be useful for anthropological evaluations and in forensic cases, especially when other skeletal elements are fragmented or unavailable [64]. It has been shown that this type of examination can be even applied for the identification of fire victims since teeth morphology is well preserved even after exposure at high temperatures [65].

Anthropological investigations

Given the high degree of sexual dimorphism, permanent dentition has been extensively studied in the forensic field for sex determination. Indeed, it has been shown that volumetric measurements of different components of mandibular canines (e.g., enamel cap, coronal dentine and pulp, enamel-dentine junction surface) may indicate the correct gender [66, 67]. Nevertheless, such parameters are still considered additional [66, 67].

Two-dimensional measurements of mandibular molars demonstrated that in male there is a higher content of dentine while female dental elements are characterized by greater relative enamel thickness [68].

Moreover, several authors investigated the relationship between age and age-related changes in the pulp/tooth volume ratio and secondary dentin pulp deposition in mandibular central incisors and maxillary premolars even using broken teeth [69–72]. In particular, the analysis of a single small fragment of a tooth allowed age estimation with an accuracy of seven–eight years, which is within the typical acceptable range, for forensic investigations, of ten years.

PMI estimation

The results of a recent preliminary study showed that values of enamel abrasion combined with the identification of decreased enamel mineral densities could be useful for determining PMI [73].

Cremation temperature estimation

The investigation of ultrastructural heat-induced changes on burned human dental tissue provided useful information about the cremation temperature. In fact, in a preliminary study, micro-CT analysis of human molars burned under controlled temperatures showed a temperature-dependent increase of heat-induced cracks [74]. In a further study [75], the combined use of small- and wide-angle X-ray scattering not only detected an increase in the mean crystal thickness of burned dentine and enamel but also showed a decreased degree of alignment and changes in the crystalline shape.

Soft tissues

Neuropathology

In forensic neuropathology, although the primary method for the assessment of high-resolution 3D brain cyto-architecture is confocal light microscopy, micro-CT has become a valid tool. Indeed, it provides non-destructive volumetric images of the internal brain structures with details comparable to a light microscope allowing the detection of small brain components, amyloid plaques, micro-hemorrhages and age-associated rearrangement of hippocampal subfields, cranial trauma or degenerative diseases. Furthermore, by micro-CT, it is possible to investigate nervous circuits of any part of the brain, to select sites of interest for subsequent histological analysis [19].

Cardiovascular pathology

Post-mortem micro-CT can provide highly accurate images of cardiac architecture as well as coronary (Fig. 4A–D) and valvular morphology even comparable to histological analysis [76]. Moreover, this technique can be successfully applied for vascular imaging allowing the collection of the volumetric data of blood vessels as well as a characterization of fibrous plaques, calcified lesions, fibroatheroma, and lipid rich lesions [19]. Although, currently, to the best of our knowledge, there are no forensic micro-CT applications about the timing of myocardial infarction, we can assume that in the near future the combination of micro-imaging with computational modeling could enable the analysis of the myocardial structure and the quantification of morphometric parameters potentially useful for dating ischemic lesions in humans [77]. Moreover, similar applications are expected for pulmonary embolism.

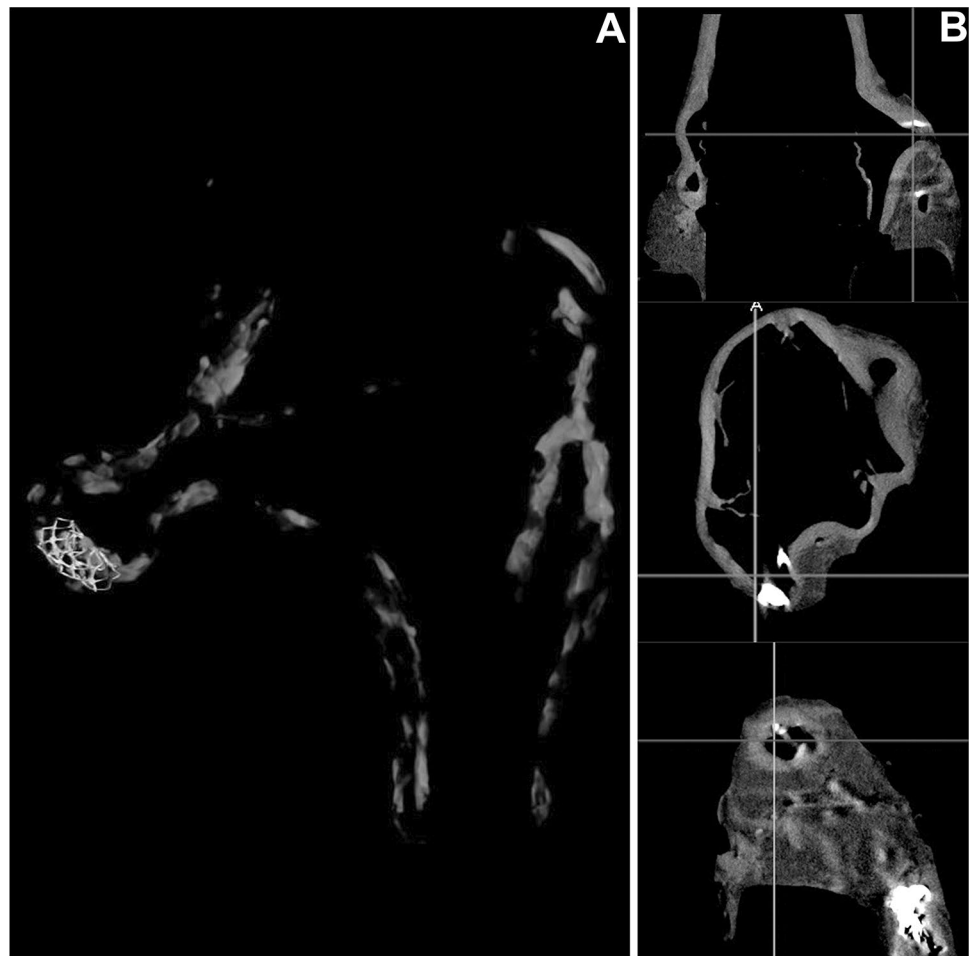
Lung pathology

Micro-CT can provide information about the micro-architectural structure of the tracheobronchial tree and lungs. For instance, it demonstrated to be useful to score the extent of emphysema in cases of asphyxial deaths and, by 3D images and quantitative measurements, it allowed the assessment of pathological changes of small airways and the quantification of tissue proliferation and fibrotic or emphysematous alterations in respiratory work-related diseases [19].

Identification of soft tissues

Human identification has traditionally focused on DNA sampling from cortical bone tissues, typically from the femora or tibiae. However, recent research suggested that skeletal elements with a greater proportion of cancellous bone yielded

Fig. 4 Cardiovascular pathology. Volumetric reconstruction of the coronary tree of a cadaver well demonstrating the coronary stent (A). Multi-planar reconstructions nicely showing arterial wall calcifications (B–D) (i.e., all unpublished data belonging to authors' casework)



nuclear DNA at the highest rates. In this context, micro-CT has been used for identifying the bone tissue type most likely to yield nuclear DNA from skeletal material. Indeed, 3D micro-CT reconstructions revealed soft tissues, otherwise non-visible to the naked eye, within the marrow spaces of skeletal elements with high cancellous content, suggesting that these residual soft tissues contributed to the higher DNA yields from cancellous bone [78]. Even cementum could be a source of DNA in challenging forensic cases. Micro-CT analysis of teeth of decomposed bodies revealed that cementum thickness as well as cellular density of cementum varies significantly in the same individual between different types of teeth and different tooth regions [79].

Blood

Bloodstain pattern analysis

Micro-CT analysis enabled the assessment of size, shape, and internal structure of bloodstains as well as a better understanding of the interaction between blood and fabrics.

According to the recent literature, bloodstain forms a diamond shaped figure within the textile with the maximum cross-sectional area of the stain occurring below the surface of the fabric [80, 81].

Embryos and fetuses

Even if conventional autopsy followed by histology remains the gold standard for diagnosing fetal pathologies, there is a clinical and forensic need for alternative post-mortem investigations of early gestational fetuses and several authors already proposed the use of micro-CT [82–87].

Certainly this type of analyses require an adequate preparation of the samples and one of the proposed protocols requires four main stages: formalin fixation, addition of contrast agent (potassium trichloride, iodine, or phosphotungstic acid solution in ethanol), tight vertical positioning of the sample, and high-definition micro-CT scan [83, 84].

In a first study published in 2014, micro-CT and autoptic findings of seven fetuses (i.e., gestational age between seven

and 17 weeks) have been compared [85]. It emerged that micro-CT identified all anatomical structures and abnormalities documented during the macroscopic dissection and in two cases even showed additional details.

A further similar study published in 2018 based on 20 fetuses in the same gestational interval demonstrated that micro-CT has a sensitivity of 93.8% and a specificity of 100% [86].

This technique has been used also on macerated fetuses (gestational age between 11 and 24 weeks), showing a sufficient image quality score, higher for the head than the chest [87].

Isolated organs examination

Micro-CT has also been applied on single organs. For example, it was successfully used to demonstrate complex congenital heart diseases [88] and adding contrast medium further details were collected improving diagnostic accuracy [85, 89]. This tool turned out to be especially useful in cases in which conventional autopsy or dissection was precluded due to size restrictions. Despite the encouraging evidence regarding the potential use of virtual fetal cardiac dissection [90], the results of a recent study suggest that micro-CT seems to modify the cyto-architecture, highlighting the need of further studies [91].

Not only cardiac imaging benefited of the advantages carried by micro-CT imaging, in fact, it has been used for fetal renal cystic disease, obtaining microscopical details comparable to low-power histological analyses, as well as for cerebral anatomical evaluations suggesting potential applications for congenital malformations of the central nervous system [92].

Placental examination

The micro-radiological examination of the placenta after perfusion of contrast agents demonstrated for instance that a decreased blood flow is associated with a reduced fetal weight while the enlargement of the arterial tree is mainly associated with an increase of the caliber of the vessels rather than with a greater number of arteries [19].

Insects

Micro-CT has been used to investigate the anatomy of insects for forensic purposes with a resolution comparable to that of more invasive and time-consuming traditional microscopic techniques [93, 94].

PMI estimation

Assessing the metamorphosis of insects is one of the most reliable methods for PMI estimation, especially when death has occurred since more than 72 h and insects are involved at the death scene. Indeed, the combined investigation of the development of external (i.e., wings, legs, eyes, and outer mouthparts) and internal (i.e., brain, flight muscles, fat cells, and alimentary tract) microstructural features of the *Calliphora vicina* pupae stained with iodine during metamorphosis, provided reliable parameters for age estimation of forensically relevant blowfly species, and, therefore, an accurate estimation of the PMI [93, 94].

Furthermore, the measurement of volumetric changes of selected organs (i.e., flight muscles, pre-helicoidal region of the midgut, and rectal pouch) could be used, in combination with qualitative markers, to estimate the age of blow flies during the intra-pupal period.

Foreign materials

GSR analysis

Micro-CT analysis of gunshot wounds experimentally produced on human skin has been used for the examination of GSR particles to detect and localize the gunshot wound, differentiate the entrance from the exit wound, and presume the firing distance [95].

Currently, it is well known that micro-CT allows the detection and quantification of radiopaque micro-particles, and consequently, reconstructs the spatial distribution of the GSR particles due to a gunshot wound (Fig. 5A, B). Moreover, not only it allows the distinction between gunshot wounds and other traumatic wounds as well as between the entrance from the exit hole, even if covered by textiles, but also among samples altered by putrefaction, fire or water [96–99].

Further, in an experimental model based on intermediate-range gunshot wounds produced on human skin, the amount of GSR resulting from the discharge of the firearm decreased in a non-linear fashion by increasing the firing distance. Thus, given a known percentage of GSR deposits, it was possible to estimate the firing distance at least between 5 and 30 cm [100].

Additional experiments assessing gunshot holes on cotton fabric, demonstrated that micro-CT allows the simultaneous visualization of the 3D distribution of the inorganic GSR and the alterations of the textile. Furthermore, in contact shots, a regular ring of GSR around the edges of the hole and fibers along the direction of the bullet were detected, while for intermediate distances (10–70 cm), the distribution of GSR and fibers was irregular [101].

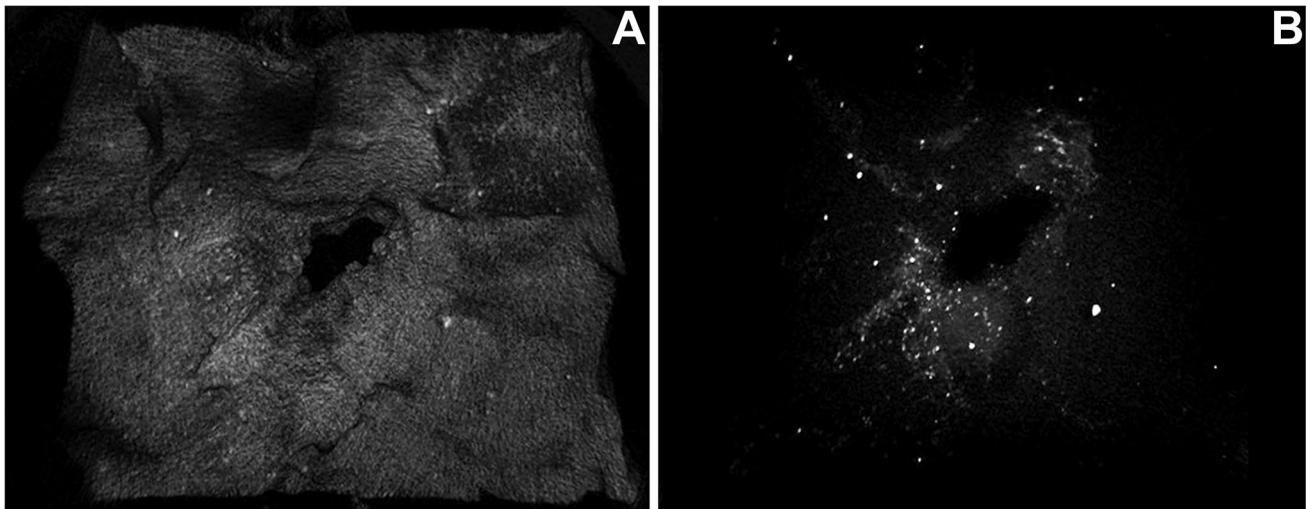


Fig. 5 Foreign materials. 3D reconstruction of an intermediate entrance gunshot wound nicely showing the hyper-dense gunshot residues (unpublished data belonging to authors' casework)

Cartridge cases

In forensic ballistics, the analysis of cartridge cases is essential for identifying the weapon. This type of analysis is based on the specific impressions left by the firearm on the cartridge case during the loading, discharge, and ejection phases. It has been demonstrated that micro-CT is an effective tool for the 3D examination of both the external and internal features of the cartridge cases, and thus for the identification of the weapon used to fire [102].

3D reconstruction of metal objects

Micro-CT allows the reconstruction of the size and shape of broken metal tools (e.g., tips of knife or saw tooth), which can be referred to a potential weapon [28]. It is also possible to produce 3D images of intravascular stents, detecting dislocations or fractures in cases of suspected medical malpractice [103].

Conclusion

In conclusion, the current literature demonstrates that micro-CT is a tool with a great variety of applications in the forensic field, ranging from forensic pathology, anthropology, odontology to neonatal forensic medicine, and entomology.

Even if its leading use remains the structural investigation of calcified tissues or teeth to identify and characterize traumatic lesions or architectural changes, and very promising results were obtained for retained metallic materials (e.g.,

knife tip, saw tooth) or GSR, it should not be overlooked that also the assessment of soft tissues, including fetuses and single organs, can provide reliable information.

This evidence suggests that in the near future micro-CT will not only be applied for research purposes but will become a companion tool for clinical forensic cases considering also that, similarly to CT images, micro-CT data can be stored, being accessible after burial or cremation of corpses, and retrieved, if needed, in Court. Certainly, to realize this shift, the availability of such device should increase. In fact, up to now, micro-CT scanners are mainly available in academic centers [104].

Last, it should be considered that in the era of artificial intelligence and radiomics [105], this type of complex analyses could be performed on micro-CT datasets to fill the gap of knowledge regarding some forensic issues, such as chronology reconstruction and estimation of the post-mortem interval.

Supplementary Information The online version contains supplementary material available at <https://doi.org/10.1007/s40336-022-00510-y>.

Author contributions Conceptualization: CG, GC; Methodology: GF, GV; Paper selection: PF, GC, GF; Data extraction: GF, GV; Writing Original draft: GF; Writing Review and Editing: CG, GV, DC, PF; Supervision: CG, DC, GC.

Funding Open access funding provided by Università degli Studi di Padova within the CRUI-CARE Agreement. The authors did not receive support from any organization for the submitted work.

Declarations

Conflict of interest The authors have no conflicts of interest to declare that are relevant to the content of this article.

Ethical approval All procedures performed in studies involving human participants were in accordance with the ethical standards of the institutional and/or national research committee and with the 1964 Helsinki Declaration and its later amendments or comparable ethical standards.

Open Access This article is licensed under a Creative Commons Attribution 4.0 International License, which permits use, sharing, adaptation, distribution and reproduction in any medium or format, as long as you give appropriate credit to the original author(s) and the source, provide a link to the Creative Commons licence, and indicate if changes were made. The images or other third party material in this article are included in the article's Creative Commons licence, unless indicated otherwise in a credit line to the material. If material is not included in the article's Creative Commons licence and your intended use is not permitted by statutory regulation or exceeds the permitted use, you will need to obtain permission directly from the copyright holder. To view a copy of this licence, visit <http://creativecommons.org/licenses/by/4.0/>.

References

- Boerckel JD, Mason DE, McDermott AM, Alsberg E (2014) Microcomputed tomography: approaches and applications in bioengineering. *Stem Cell Res Ther* 5(6):144. <https://doi.org/10.1186/scrt534>
- Lekhov VA, Pozdniakov SP, Nešetřil K (2021) Lab-scale and pore-scale study of low-permeability soil diffusional tortuosity. *J Contam Hydrol* 242:103858. <https://doi.org/10.1016/j.jconhyd.2021.103858>
- Guillermic RM, Aksoy EC, Aritan S, Erkinbaev C, Paliwal J, Koksel F (2021) X-Ray microtomography imaging of red lentil puffed snacks: processing conditions, microstructure and texture. *Food Res Int* 140:109996. <https://doi.org/10.1016/j.foodres.2020.109996>
- Dal Sasso E, Menabò R, Agrillo D, Arrigoni G, Franchin C, Giraudo C et al (2020) RegenHeart: a time-effective, low-concentration, detergent-based method aiming for conservative decellularization of the whole heart organ. *ACS Biomater Sci Eng* 6(10):5493–5506. <https://doi.org/10.1021/acsbomaterials.0c00540>
- Scanu A, Giraudo C, Galuppini F, Lazzarin V, Pennelli G, Sivolella S et al (2019) Periodontal Injection of lipopolysaccharide promotes arthritis development in mice. *Inflammation* 42(3):1117–1128. <https://doi.org/10.1007/s10753-019-00975-6>
- Bellesso S, Salvalaio M, Lualdi S, Tognon E, Costa R, Braghetta P et al (2018) FGF signaling deregulation is associated with early developmental skeletal defects in animal models for mucopolysaccharidosis type II (MPSII). *Hum Mol Genet* 27(13):2262–2275. <https://doi.org/10.1093/hmg/ddy131>
- Porzionato A, Macchi V, Da Broi U, Giraudo C, Miotto D, Rodriguez D et al (2015) Diffuse pulmonary ossification in permanent vegetative state. *Pathol Int* 65(1):27–32. <https://doi.org/10.1111/pin.12228>
- Di Liddo R, Paganin P, Lora S, Dalzoppo D, Giraudo C, Miotto D et al (2014) Poly- ϵ -caprolactone composite scaffolds for bone repair. *Int J Mol Med* 34(6):1537–1546. <https://doi.org/10.3892/ijmm.2014.1954>
- Rutty GN, Brough A, Biggs MJ, Robinson C, Lawes SDA, Hainsworth SV (2013) The role of micro-computed tomography in forensic investigations. *Forensic Sci Int* 225(1–3):60–66. <https://doi.org/10.1016/j.forsciint.2012.10.030>
- Baier W, Norman DG, Williams MA (2021) Micro-CT for the examination of paediatric rib injuries: a case series. *Forensic Sci Int* 325:110789. <https://doi.org/10.1016/j.forsciint.2021.110789>
- Baier W, Mangham C, Warnett JM, Payne M, Painter M, Williams MA (2019) Using histology to evaluate micro-CT findings of trauma in three post-mortem samples—First steps towards method validation. *Forensic Sci Int* 297:27–34. <https://doi.org/10.1016/j.forsciint.2019.01.027>
- Brown KR, Silver IA, Musgrave JH, Roberts AM (2011) The use of μ CT technology to identify skull fracture in a case involving blunt force trauma. *Forensic Sci Int* 206(1–3):e8–11. <https://doi.org/10.1016/j.forsciint.2010.06.013>
- Baier W, Norman DG, Donnelly MJ, Williams MA (2021) Forensic 3D printing from micro-CT for court use- process validation. *Forensic Sci Int* 318:110560. <https://doi.org/10.1016/j.forsciint.2020.110560>
- Baier W, Warnett JM, Payne M, Williams MA (2018) Introducing 3D printed models as demonstrative evidence at criminal trials. *J Forensic Sci* 63(4):1298–1302. <https://doi.org/10.1111/1556-4029.13700>
- Collings AJ, Brown K (2020) Reconstruction and physical fit analysis of fragmented skeletal remains using 3D imaging and printing. *Forensic Sci Int Rep*. <https://doi.org/10.1016/j.fsir.2020.100114>
- Fais P, Giraudo C, Viero A, Miotto D, Bortolotti F, Tagliaro F, Montisci M, Cecchetto G (2016) Micro computed tomography features of laryngeal fractures in a case of fatal strangulation. *Leg Med* 18:85–89. <https://doi.org/10.1016/j.legalmed.2016.01.001>
- Kettner M, Potente S, Schulz B, Knauff P, Schmidt PH, Ramsthaler F (2014) Analysis of laryngeal fractures in decomposed bodies using microfocus computed tomography (mfCT). *Forensic Sci Med Pathol* 10(4):607–612. <https://doi.org/10.1007/s12024-014-9584-1>
- Baier W, Burnett BA, Payne M, Warnett JM, Williams MA (2020) Using micro-computed tomography to examine the larynx in cases of suspected strangulation—a comparison of case findings and control images. *Int J Legal Med* 134(4):1441–1450. <https://doi.org/10.1007/s00414-019-02194-y>
- Cecchetto G (2018) Micro-imaging in forensic medicine. In: Ferrara SD (ed) *P5 Medicine and Justice: Innovation, Unitariness and Evidence*. Springer, Cham, pp 560–575. <https://doi.org/10.1007/978-3-319-67092-8>
- Jennings RM, Malbon C, Brock F, Harrison S, Carr DJ (2018) A preliminary study into injuries due to non-perforating ballistic impacts into soft body armour over the spine. *Injury* 49(7):1251–1257. <https://doi.org/10.1016/j.injury.2018.05.015>
- Kováčová V, Urbanová P (2021) Hierarchical micro-ct top-down examination of cranial gunshot injuries. *Romanian J Leg Med* 29(2):172–178
- Newton J, Savage A, Coupar N, Fraser J (2020) Preliminary investigation into the use of Micro-CT scanning on impact damage to fabric, tissue and bone caused by both round and flat nosed bullets. *Sci Justice* 60(2):151–159. <https://doi.org/10.1016/j.scijus.2019.09.006>
- Jennings RM, Malbon C, Brock F, Harrison SE, Carr DJ (2018) Preliminary study into the skeletal injuries sustained to the spine from posterior non-perforating ballistic impacts into body armour. *J R Army Med Corps* 164(3):186–190
- Caister AJ, Carr DJ, Campbell PD, Brock F, Breeze J (2020) The ballistic performance of bone when impacted by fragments. *Int J Legal Med* 134(4):1387–1393. <https://doi.org/10.1007/s00414-020-02299-9>
- Rickman JM, Shackel J (2019) A novel hypothesis for the formation of conoidal projectile wounds in sandwich bones. *Int J Legal Med* 133(2):501–519. <https://doi.org/10.1007/s00414-018-1946-x>

26. Rickman JM, Shackel J (2019) Crack propagation through sandwich bones due to low-velocity projectile impact. *Int J Legal Med* 133(5):1443–1459. <https://doi.org/10.1007/s00414-019-02086-1>
27. Delannoy Y, Colard T, Le Garff E, Humez S, Gosset D, Hedouin V (2016) The mechanism of the keyhole lesion reassessed: an experimental approach. *J Forensic Leg Med* 37:1–7. <https://doi.org/10.1016/j.jflm.2015.09.020>
28. Thali MJ, Taubenreuther U, Karolczak M, Braun M, Brueschweiler W, Kalender WA et al (2003) Forensic microradiology: micro-computed tomography (Micro-CT) and analysis of patterned injuries inside of bone. *J Forensic Sci* 48(6):1336–1342
29. Appleby J, Ruttly GN, Hainsworth SV, Woosnam-Savage RC, Morgan B, Brough A et al (2015) Perimortem trauma in King Richard III: a skeletal analysis. *Lancet* 385(9964):253–259. [https://doi.org/10.1016/S0140-6736\(14\)60804-7](https://doi.org/10.1016/S0140-6736(14)60804-7)
30. Stanley SA, Hainsworth SV, Ruttly GN (2018) How taphonomic alteration affects the detection and imaging of striations in stab wounds. *Int J Legal Med* 132(2):463–475. <https://doi.org/10.1007/s00414-017-1715-2>
31. Capuani C, Rouquette J, Payré B, Moscovici J, Delisle MB, Telmon N et al (2013) Deciphering the elusive nature of sharp bone trauma using epifluorescence macroscopy: a comparison study multiplexing classical imaging approaches. *Int J Legal Med* 127(1):169–176. <https://doi.org/10.1007/s00414-012-0678-6>
32. Pounder DJ, Sim LJ (2011) Virtual casting of stab wounds in cartilage using micro-computed tomography. *Am J Forensic Med Pathol* 32(2):97–99. <https://doi.org/10.1097/PAF.0b013e3182186f37>
33. Komo L, Grassberger M (2018) Experimental sharp force injuries to ribs: multimodal morphological and geometric morphometric analyses using micro-CT, macro photography and SEM. *Forensic Sci Int* 288:189–200. <https://doi.org/10.1016/j.forsciint.2018.04.048>
34. Norman DG, Watson DG, Burnett B, Fenne PM, Williams MA (2018) The cutting edge-micro-CT for quantitative toolmark analysis of sharp force trauma to bone. *Forensic Sci Int* 283:156–172. <https://doi.org/10.1016/j.forsciint.2017.12.039>
35. Pelletti G, Viel G, Fais P, Viero A, Visentin S, Miotto D et al (2017) Micro-computed tomography of false starts produced on bone by different hand-saws. *Leg Med* 26:1–5. <https://doi.org/10.1016/j.legalmed.2017.01.009>
36. Norman DG, Baier W, Watson DG, Burnett B, Painter M, Williams MA (2018) Micro-CT for saw mark analysis on human bone. *Forensic Sci Int* 293:91–100. <https://doi.org/10.1016/j.forsciint.2018.10.027>
37. Giraudo C, Montisci M, Giorgetti A, Martinuzzo L, Bisceglia M, Moschi S et al (2020) Intra-class and inter-class tool discrimination through micro-CT analysis of false starts on bone. *Int J Legal Med* 134(3):1023–1032. <https://doi.org/10.1007/s00414-019-02157-3>
38. Pelletti G, Cecchetto G, Viero A, Fais P, Weber M, Miotto D et al (2017) Accuracy, precision and inter-rater reliability of micro-CT analysis of false starts on bones. *Prelim Valid Study Leg Med* 29:38–43. <https://doi.org/10.1016/j.legalmed.2017.10.003>
39. Alsop K, Baier W, Norman D, Burnett B, Williams MA (2021) Accurate prediction of saw blade thicknesses from false start measurements. *Forensic Sci Int* 318:110602. <https://doi.org/10.1016/j.forsciint.2020.110602>
40. Baier W, Norman DG, Warnett JM, Payne M, Harrison NP, Hunt NCA et al (2017) Novel application of three-dimensional technologies in a case of dismemberment. *Forensic Sci Int* 270:139–145. <https://doi.org/10.1016/j.forsciint.2016.11.040>
41. Baier W, Donnelly MJ, Payne M, Williams MA (2020) A holistic multi-scale approach to using 3D scanning technology in accident reconstruction. *J Forensic Sci* 65(5):1774–1778. <https://doi.org/10.1111/1556-4029.14405>
42. Kieser JA, Weller S, Swain MV, Neil Waddell J, Das R (2013) Compressive rib fracture: peri-mortem and post-mortem trauma patterns in a pig model. *Leg Med* 15(4):193–201. <https://doi.org/10.1016/j.legalmed.2013.01.001>
43. Bradley AL, Swain MV, Neil Waddell J, Das R, Athens J, Kieser JA (2014) A comparison between rib fracture patterns in peri and post-mortem compressive injury in a piglet model. *J Mech Behav Biomed Mater* 33:67–75. <https://doi.org/10.1016/j.jmbbm.2013.06.004>
44. Steyn M, De Boer HH, Van der Merwe AE (2014) Cranial trauma and the assessment of posttraumatic survival time. *Forensic Sci Int* 244:e25–e29. <https://doi.org/10.1016/j.forsciint.2014.08.021>
45. Delabarde T, Reynolds M, Decourcelle M, Pascaretti-Grizon F, Ludes B (2020) Skull fractures in forensic putrefied/skeletonised cases: the challenge of estimating the post-traumatic interval. *Morphologie* 104(344):27–37. <https://doi.org/10.1016/j.morpho.2020.01.002>
46. Viero A, Biehler-Gomez L, Cappella A, Messina C, Montisci M, Cattaneo C (2021) The potential of micro-CT for dating post-cranial bone fractures: a macroscopic, radiographic, and microtomography study of fractures of known post-traumatic ages. *Int J Legal Med* 135(5):1913–1921. <https://doi.org/10.1007/s00414-021-02582-3>
47. Akbulut N, Çetin S, Bilecenoğlu B, Altan A, Ocak M, Şen E et al (2021) Evaluation of the detectability of early mandible fracture healing findings in terms of vitality aspect by using micro-CT technology in postmortem interval. *Leg Med* 52:101914. <https://doi.org/10.1016/j.legalmed.2021.101914>
48. Johnson V, Beckett S, Márquez-Grant N (2017) Differentiating human versus non-human bone by exploring the nutrient foramen: implications for forensic anthropology. *Int J Legal Med* 131(6):1757–1763. <https://doi.org/10.1007/s00414-017-1662-y>
49. Corrieri B, Márquez-Grant N (2019) Using nutrient foramina to differentiate human from non-human long bone fragments in bioarchaeology and forensic anthropology. *Homo* 70(4):255–268. <https://doi.org/10.1127/homo/2019/1113>
50. Kramer NA, Lopez-Capp TT, Michel-Crosato E, Biazevic MGH (2018) Sex estimation from the mastoid process using Micro-CT among Brazilians: discriminant analysis and ROC curve analysis. *J Forensic Radiol Imaging* 14:1–7. <https://doi.org/10.1016/j.jofri.2018.05.003>
51. Kozerska M, Szczepanek A, Tarasiuk J, Wroński S (2020) Micro-CT analysis of the internal acoustic meatus angles as a method of sex estimation in skeletal remains. *Homo* 71(2):121–128
52. Wade A, Nelson A, Garvin G, Holdsworth DW (2011) Preliminary Radiological Assessment of Age-related Change in the Trabecular Structure of the Human Os Pubis*. *J Forensic Sci* 56(2):312–319. <https://doi.org/10.1111/j.1556-4029.2010.01643.x>
53. Deguette C, Ramond-Roquin A, Rougé-Maillart C (2017) Relationships between age and microarchitectural descriptors of iliac trabecular bone determined by microCT. *Morphologie* 101(333):64–70. <https://doi.org/10.1016/j.morpho.2017.03.008>
54. McGivern H, Greenwood C, Márquez-Grant N, Kranjoti EF, Xhemali B, Zioupos P (2020) Age-related trends in the trabecular micro-architecture of the medial clavicle: is it of use in forensic science? *Front Bioeng Biotechnol* 7:467. <https://doi.org/10.3389/fbioe.2019.00467>
55. Deguette C, Chappard D, Libouban H, Airagnes G, Rouge-Maillart C, Telmon N (2018) The contribution of Micro-CT to the evaluation of trabecular bone at the posterior part of the auricular surface in men. *Int J Legal Med* 132(4):1231–1239. <https://doi.org/10.1007/s00414-014-1139-1>
56. Nikolova S, Toneva D, Georgiev I, Lazarov N (2019) Sagittal suture maturation: morphological reorganization, relation to

- aging, and reliability as an age-at-death indicator. *Am J Phys Anthropol* 169(1):78–92. <https://doi.org/10.1002/ajpa.23810>
57. Longato S, Wöss C, Hatzler-Grubwieser P, Bauer C, Parson W, Unterberger SH et al (2015) Post-mortem interval estimation of human skeletal remains by micro-computed tomography, mid-infrared microscopic imaging and energy dispersive X-ray mapping. *Anal Methods* 7(7):2917–2927. <https://doi.org/10.1039/c4ay02943g>
 58. Le Garff E, Mesli V, Delannoy Y, Colard T, Demondion X, Becart A et al (2017) Technical note: early post-mortem changes of human bone in taphonomy with μ CT. *Int J Legal Med* 131(3):761–770. <https://doi.org/10.1007/s00414-016-1509-y>
 59. Le Garff E, Mesli V, Delannoy Y, Colard T, De Jonckheere J, Demondion X et al (2017) The precision of micro-tomography in bone taphonomic experiments and the importance of registration. *Forensic Sci Int* 273:161–167. <https://doi.org/10.1016/j.foresciint.2017.02.005>
 60. Le Garff E, Mesli V, Marchand E, Behal H, Demondion X, Becart A et al (2018) Is bone analysis with μ CT useful for short postmortem interval estimation? *Int J Legal Med* 132(1):269–277. <https://doi.org/10.1007/s00414-017-1696-1>
 61. Ellingham S, Sandholzer MA (2020) Determining volumetric shrinkage trends of burnt bone using micro-CT. *J Forensic Sci* 65(1):196–199. <https://doi.org/10.1111/1556-4029.14150>
 62. Mckinnon M, Henneberg M, Simpson E, Higgins D (2021) Effects of thermal insult on bone tissue as observed by micro computed tomography. *Forensic Imaging*. <https://doi.org/10.1016/j.fri.2021.200437>
 63. Waltenberger L, Schutkowski H (2017) Effects of heat on cut mark characteristics. *Forensic Sci Int* 271:49–58. <https://doi.org/10.1016/j.foresciint.2016.12.018>
 64. Aktuna Belgin C, Serindere G, Orhan K (2019) Accuracy and reliability of enamel and dentin thickness measurements on micro-computed tomography and digital periapical radiographs. *J Forensic Radiol Imaging* 18:32–36. <https://doi.org/10.1016/j.jofri.2019.05.006>
 65. Sandholzer MA, Walmsley AD, Lumley PJ, Landini G (2013) Radiologic evaluation of heat-induced shrinkage and shape preservation of human teeth using micro-CT. *J Forensic Radiol Imaging* 1(3):107–111
 66. García-Campos C, Martínón-Torres M, Martín-Francés L, Martínez de Pinillos M, Modesto-Mata M, Perea-Pérez B et al (2018) Contribution of dental tissues to sex determination in modern human populations. *Am J Phys Anthropol* 166(2):459–472. <https://doi.org/10.1002/ajpa.23447>
 67. García-Campos C, Martínón-Torres M, Martínez de Pinillos M, Modesto-Mata M, Martín-Francés L, Perea-Pérez B et al (2018) Modern humans sex estimation through dental tissue patterns of maxillary canines. *Am J Phys Anthropol* 167(4):914–923. <https://doi.org/10.1002/ajpa.23715>
 68. Sorenti M, Martínón-Torres M, Martín-Francés L, Perea-Pérez B (2019) Sexual dimorphism of dental tissues in modern human mandibular molars. *Am J Phys Anthropol* 169(2):332–340. <https://doi.org/10.1002/ajpa.23822>
 69. Asami R, Aboshi H, Iwawaki A, Ohtaka Y, Odaka K, Abe S et al (2019) Age estimation based on the volume change in the maxillary premolar crown using micro CT. *Leg Med* 37:18–24. <https://doi.org/10.1016/j.legalmed.2018.12.001>
 70. Someda H, Saka H, Matsunaga S, Ide Y, Nakahara K, Hirata S et al (2009) Age estimation based on three-dimensional measurement of mandibular central incisors in Japanese. *Forensic Sci Int* 185(1–3):110–114. <https://doi.org/10.1016/j.foresciint.2009.01.001>
 71. Nudel I, Pokhojaev A, Hausman BS, Bitterman Y, Shpack N, May H et al (2020) Age estimation of fragmented human dental remains by secondary dentin virtual analysis. *Int J Legal Med* 134(5):1853–1860. <https://doi.org/10.1007/s00414-020-02366-1>
 72. Aboshi H, Takahashi T, Komuro T (2010) Age estimation using microfocus X-ray computed tomography of lower premolars. *Forensic Sci Int* 200(1–3):35–40. <https://doi.org/10.1016/j.foresciint.2010.03.024>
 73. Akbulut N, Çetin S, Bilecenoğlu B, Altan A, Akbulut S, Ocak M et al (2020) The micro-CT evaluation of enamel-cement thickness, abrasion, and mineral density in teeth in the postmortem interval (PMI): new parameters for the determination of PMI. *Int J Legal Med* 134(2):645–653. <https://doi.org/10.1007/s00414-019-02104-2>
 74. Sandholzer MA, Baron K, Heimel P, Metscher BD (2014) Volume analysis of heat-induced cracks in human molars: a preliminary study. *J Forensic Dent Sci* 6(2):139. <https://doi.org/10.4103/0975-1475.132545>
 75. Sandholzer MA, Sui T, Korsunsky AM, Damien Walmsley A, Lumley PJ, Landini G (2014) X-ray scattering evaluation of ultrastructural changes in human dental tissues with thermal treatment. *J Forensic Sci* 59(3):769–774. <https://doi.org/10.1111/1556-4029.12400>
 76. De Marco E, Vacchiano G, Frati P, La Russa R, Santurro A, Scopetti M et al (2018) Evolution of post-mortem coronary imaging: from selective coronary arteriography to post-mortem CT-angiography and beyond. *Radiol med* 123(5):351–358. <https://doi.org/10.1007/s11547-018-0855-x>
 77. Papazoglou AS, Karagiannidis E, Moysidis DV, Sofidis G, Bompoti A, Stalikas N et al (2021) Current clinical applications and potential perspective of micro-computed tomography in cardiovascular imaging: a systematic scoping review. *Hellenic J Cardiol* 62(6):399–407. <https://doi.org/10.1016/j.hjc.2021.04.006>
 78. Andronowski JM, Mundorff AZ, Pratt IV, Davoren JM, Cooper DML (2017) Evaluating differential nuclear DNA yield rates and osteocyte numbers among human bone tissue types: a synchrotron radiation micro-CT approach. *Forensic Sci Int Genet* 28:211–218. <https://doi.org/10.1016/j.fsigen.2017.03.002>
 79. Mansour H, Krebs O, Sperhake JP, Augustin C, Koehne T, Amling M et al (2018) Cementum as a source of DNA in challenging forensic cases. *J Forensic Leg Med* 54:76–81. <https://doi.org/10.1016/j.jflm.2017.12.015>
 80. Dicken L, Knock C, Carr DJ, Beckett S (2019) The effect of fabric mass per unit area and blood impact velocity on bloodstain morphology. *Forensic Sci Int* 301:12–27. <https://doi.org/10.1016/j.foresciint.2019.05.001>
 81. Dicken L, Knock C, Beckett S, de Castro TC, Nickson T, Carr DJ (2015) The use of micro computed tomography to ascertain the morphology of bloodstains on fabric. *Forensic Sci Int* 257:369–375. <https://doi.org/10.1016/j.foresciint.2015.10.006>
 82. Dawood Y, Strijkers GJ, Limpens J, Oostra RJ, de Bakker BS (2020) Novel imaging techniques to study postmortem human fetal anatomy: a systematic review on microfocus-CT and ultra-high-field MRI. *Eur Radiol* 30(4):2280–2292. <https://doi.org/10.1007/s00330-019-06543-8>
 83. Simcock IC, Shelmerdine SC, Hutchinson JC, Sebire NJ, Arthurs OJ (2021) Human fetal whole-body postmortem microfocus computed tomographic imaging. *Nat Protoc* 16(5):2594–2614. <https://doi.org/10.1038/s41596-021-00512-6>
 84. Vymazalová K, Vargová L, Zikmund T, Kaiser J (2017) The possibilities of studying human embryos and fetuses using micro-CT: a technical note. *Anat Sci Int* 92(2):299–303. <https://doi.org/10.1007/s12565-016-0377-3>
 85. Lombardi CM, Zambelli V, Botta G, Moltrasio F, Cattoretti G, Lucchini V et al (2014) Postmortem microcomputed tomography (micro-CT) of small fetuses and hearts. *Ultrasound Obstet Gynecol* 44(5):600–609. <https://doi.org/10.1002/uo.13330>

86. Hutchinson JC, Kang X, Shelmerdine SC, Segers V, Lombardi CM, Cannie MM et al (2018) Postmortem microfocus computed tomography for early gestation fetuses: a validation study against conventional autopsy. *Am J Obstet Gynecol* 218(4):445.e1–445.e12. <https://doi.org/10.1016/j.ajog.2018.01.040>
87. Simcock IC, Shelmerdine SC, Langan D, Anna G, Sebire NJ, Arthurs OJ (2021) Micro-CT yields high image quality in human fetal post-mortem imaging despite maceration. *BMC Med Imaging* 21(1):128. <https://doi.org/10.1186/s12880-021-00658-5>
88. Hutchinson JC, Arthurs OJ, Ashworth MT, Ramsey AT, Mifsud W, Lombardi CM et al (2016) Clinical utility of postmortem microcomputed tomography of the fetal heart: diagnostic imaging vs macroscopic dissection: Micro-CT of the fetal heart. *Ultrasound Obstet Gynecol* 47(1):58–64. <https://doi.org/10.1002/uo.15764>
89. Sandaite I, Lombardi C, Cook AC, Fabietti I, Deprest J, Boito S (2020) Micro-computed tomography of isolated fetal hearts following termination of pregnancy: a feasibility study at 8 to 12 weeks' gestation. *Prenat Diagn* 40(8):984–990. <https://doi.org/10.1002/pd.5719>
90. Sandrini C, Boito S, Lombardi CM, Lombardi S (2021) Post-mortem micro-CT of human fetal heart—A systematic literature review. *J Clin Med* 10(20):4726. <https://doi.org/10.3390/jcm10204726>
91. Lupariello F, Genova T, Mussano F, Di Vella G, Botta G (2021) Micro-CT processing's effects on microscopic appearance of human fetal cardiac samples. *Leg Med* 53:101934. <https://doi.org/10.1016/j.legalmed.2021.101934>
92. Lombardi S, Scola E, Ippolito D, Zambelli V, Botta G, Cuttin S et al (2019) Micro-computed tomography: a new diagnostic tool in postmortem assessment of brain anatomy in small fetuses. *Neuroradiology* 61(7):737–746. <https://doi.org/10.1007/s00234-019-02168-2>
93. Richards CS, Simonsen TJ, Abel RL, Hall MJR, Schwyn DA, Wicklein M (2012) Virtual forensic entomology: Improving estimates of minimum post-mortem interval with 3D micro-computed tomography. *Forensic Sci Int* 220(1–3):251–264. <https://doi.org/10.1016/j.forsciint.2012.03.012>
94. Martín-Vega D, Simonsen TJ, Wicklein M, Hall MJR (2017) Age estimation during the blow fly intra-puparial period: a qualitative and quantitative approach using micro-computed tomography. *Int J Legal Med* 131(5):1429–1448. <https://doi.org/10.1007/s00414-017-1598-2>
95. Viero A, Giraudo C, Cecchetto G, Muscovich C, Favretto D, Puglisi M et al (2014) An unusual case of “dyadic-death” with a single gunshot. *Forensic Sci Int* 244:e1–5. <https://doi.org/10.1016/j.forsciint.2014.08.001>
96. Fais P, Giraudo C, Viero A, Amagliani A, Viel G, Montisci M et al (2015) Identification of bullet entrance in different type of intermediate firearm wounds through micro-computed tomography analysis. *J Forensic Radiol Imaging* 3(3):147–152. <https://doi.org/10.1016/j.jofri.2015.07.004>
97. Giraudo C, Fais P, Pelletti G, Viero A, Miotto D, Boscolo-Berto R et al (2016) Micro-CT features of intermediate gunshot wounds covered by textiles. *Int J Legal Med* 130(5):1257–1264. <https://doi.org/10.1007/s00414-016-1403-7>
98. Fais P, Giraudo C, Boscolo-Berto R, Amagliani A, Miotto D, Feltrin G et al (2013) Micro-CT features of intermediate gunshot wounds severely damaged by fire. *Int J Legal Med* 127(2):419–425. <https://doi.org/10.1007/s00414-012-0775-6>
99. Cecchetto G, Amagliani A, Giraudo C, Fais P, Cavarzeran F, Montisci M et al (2012) MicroCT detection of gunshot residue in fresh and decomposed firearm wounds. *Int J Legal Med* 126(3):377–383. <https://doi.org/10.1007/s00414-011-0648-4>
100. Cecchetto G, Giraudo C, Amagliani A, Viel G, Fais P, Cavarzeran F et al (2011) Estimation of the firing distance through micro-CT analysis of gunshot wounds. *Int J Legal Med* 125(2):245–251. <https://doi.org/10.1007/s00414-010-0533-6>
101. Brożek-Mucha Z, Borowska P, Tarasiuk J, Wroński S (2020) Application of electron microscopy, X-ray spectrometry and computed micro-tomography for characterisation of gunshot residue deposition in textile at close range. *Z Zagadnien Nauk Sadowych* 124:211–236
102. Alsop K, Norman D, Remy G, Wilson P, Williams MA (2021) Quantitative characterisation of ballistic cartridge cases from micro-CT. *Forensic Sci Int* 326:110913. <https://doi.org/10.1016/j.forsciint.2021.110913>
103. Foerst J, Ball T, Kaplan AV (2010) Postmortem in situ micro-ct evaluation of coronary stent fracture. *Catheter Cardiovasc Interv* 76(4):527–531. <https://doi.org/10.1002/ccd.22498>
104. Cecchetto G, Bajanowski T, Cecchi R, Favretto D, Grabherr S et al (2017) Back to the future-part 1. The medico-legal autopsy from ancient civilization to the post-genomic era. *Int J Legal Med* 131(4):1069–1083. <https://doi.org/10.1007/s00414-017-1584-8>
105. Ferrara SD, Cecchetto G, Cecchi R, Favretto D, Grabherr S et al (2017) Back to the future-part 2. Post-mortem assessment and evolutionary role of the bio-medico-legal sciences. *Int J Legal Med* 131(4):1085–1101. <https://doi.org/10.1007/s00414-017-1585-7>

Publisher's Note Springer Nature remains neutral with regard to jurisdictional claims in published maps and institutional affiliations.