


# Myocarditis and coronary aneurysms in a child with acute respiratory syndrome coronavirus 2

Cristina Ciuca<sup>1</sup>, Marianna Fabi<sup>2\*</sup> , Daniela Di Luca<sup>3</sup>, Fabio Niro<sup>4</sup>, Chiara Ghizzi<sup>5</sup>, Andrea Dotti<sup>1</sup>, Anna Balducci<sup>1</sup>, Alessandro Rocca<sup>2</sup>, Chiara Zarbo<sup>2</sup>, Gaetano Domenico Gargiulo<sup>1</sup> and Marcello Lanari<sup>2</sup>

<sup>1</sup>Pediatric Cardiology and Cardiac Surgery Unit, University of Bologna, S. Orsola Hospital, Bologna, Italy; <sup>2</sup>Department of Pediatrics, University of Bologna, S. Orsola Hospital, Bologna, Italy; <sup>3</sup>Department of Anesthesiology, University of Bologna, S. Orsola Hospital, Bologna, Italy; <sup>4</sup>Department of Radiology, University of Bologna, S. Orsola Hospital, Bologna, Italy; <sup>5</sup>Department of Pediatrics, Maggiore Hospital, Bologna, Italy

## Abstract

A 6-year-old African boy with multi-viral infection including parvovirus B19 and severe acute respiratory syndrome coronavirus 2 was admitted for persistent fever associated with respiratory distress and myocarditis complicated by cardiogenic shock needing ventilatory and inotropic support. Coronary aneurysms were also documented in the acute phase. Blood tests were suggestive of macrophage activation syndrome. He was treated with intravenous immunoglobulins, aspirin, diuretics, dexamethasone, hydroxychloroquine, and prophylactic low molecular weight heparin. Normalization of cardiac performance and coronary diameters was noticed within the first days. Cardiac magnetic resonance imaging, performed 20 days after the hospitalization, evidenced mild myocardial interstitial oedema with no focal necrosis, suggesting a mechanism of cardiac stunning related to cytokines storm rather than direct viral injury of cardiomyocytes.

**Keywords** Coronary aneurysms; Myocarditis; Shock; COVID-19; Children

Received: 4 July 2020; Revised: 4 September 2020; Accepted: 17 September 2020

\*Correspondence to: Marianna Fabi, Department of Pediatrics, University of Bologna, S. Orsola Hospital, Bologna, Italy.

Email: marianna.fabi@aosp.bo.it

## Introduction

Coronavirus disease 2019 (COVID-19), also known as severe acute respiratory syndrome coronavirus 2 (SARS-CoV-2), is a major world health issue. Approximately 1% of COVID-19-affected patients are less than 18 years old.<sup>1,2</sup> Major concerns have recently been raised about severe manifestations in the paediatric age group.<sup>3,4</sup> A multisystem inflammatory syndrome (MIS), potentially needing intensive care support, has been described as well as a wide spectrum of cardiovascular anomalies, particularly a Kawasaki-like disease (KD).<sup>5</sup>

## Case report

A 6-year-old African boy, with an uneventful clinical history, was hospitalized for persistent fever. A contact with a SARS-CoV-2-positive subject (mother) was referred. At admission, he was febrile (39.9°C) and eupneic with normal oxygen saturation and had no signs of mucocutaneous inflammation.

The nasopharyngeal swab for SARS-CoV-2 was negative. Blood tests showed increased C-reactive protein and procalcitonin and hyponatraemia (*Table 1*). A wide-spectrum antibiotic therapy was started.

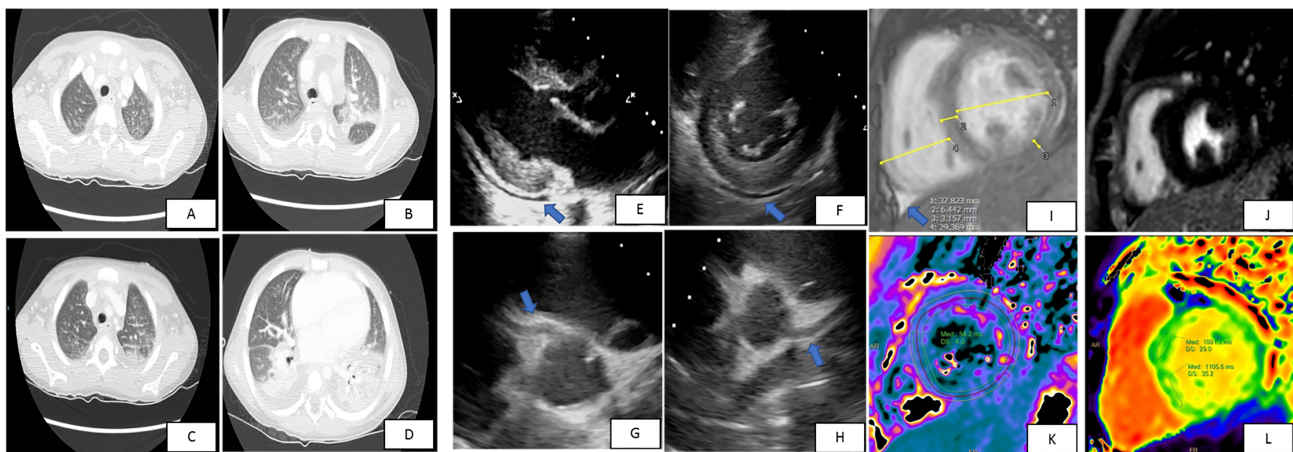
Five days after the onset of fever, he showed worsening of clinical conditions with shock, marked tachypnoea, desaturation, fever persistence, and hepatosplenomegaly. The laboratory tests (*Table 1*) were suggestive of macrophage activation syndrome (MAS)<sup>6</sup> with pancytopenia, hypertriglyceridaemia, hyperferritinaemia, hypocalcaemia, and increased values of aspartate aminotransferase, alanine aminotransferase, interleukin 6, D-dimer, C-reactive protein, procalcitonin, and cardiac biomarkers (*Table 1*). The nasopharyngeal swab for SARS-CoV-2 was repeated and resulted positive. A coinfection with parvovirus B19 was documented. A thoracic high-resolution computed tomography showed bilateral consolidations and pleural effusion (*Figure 1A–1D*). The electrocardiogram showed low voltage in the limb leads and minimal ST-segment depression with T-wave inversion in the anterior leads.

**Table 1** Laboratory findings from the time of the admission to the following days

	24 April, admission	29 April	2 May	6 May
WBC ( $\times 10^9/L$ )	9.18	4.21	7.23	23.7
Neutrophils (%)	76	69.6	50	46
Lymphocytes (%)	18	22.3	14.4	46.1
Hb (g/dL)	10.5	7.5	10.7	10.5
PLT ( $\times 10^9/L$ )	183	101	353	982
D-Dimer (mg/L FEU)		3.75	2	1
CRP (mg/dL)	14.8	23.5	9	0.8
Procalcitonin (ng/mL)	13	17.2	1	0.2
Ferritin	358	1515	357	321
Fibrinogen (mg/dL)		368	289	
Triglycerides (mg/dL)		295	200	149
ALT (U/L)		371	93	98
AST (U/L)		492	78	64
Creatinine (mg/dL)	0.26	0.32	0.31	0.26
Blood urea nitrogen (mg/dL)	40	38	34	39
Na (mmol/L)	129	132	136	140
IL-6 (pg/mL)		398	30.8	<2
IL-10 (pg/mL)				10.3
IL-1 (pg/mL)				<2
TNF- $\alpha$ (pg/mL)				<2
High-sensitivity troponin (ng/L)		98	65	16
BNP (pg/mL)		1170		18
CPK (U/L)		552	537	189
Parvovirus B19 (copies/mL)		14 298		<600

ALT, alanine aminotransferase; AST, aspartate aminotransferase; BNP, B-type natriuretic peptide; CPK, creatine phosphokinase; CRP, C-reactive protein; FEU, fibrinogen equivalent units; Hb, haemoglobin; IL-1, interleukin 1; IL-6, interleukin 6; IL-10, interleukin 10; Na, sodium; PLT, platelets; TNF- $\alpha$ , tumour necrosis factor- $\alpha$ ; WBC, white blood cells.

**Figure 1** (A–D) Thoracic high-resolution computed tomography showing bilateral multiple consolidations and basal bilateral pleural effusion. Parasternal long-axis (E) and short-axis (F) view showing normal left ventricular dimensions, mild septal hypertrophy, and mild pericardial effusion (arrows). Parasternal short-axis view showing a global dilation of right coronary artery (G, arrow) and left anterior descending artery (H, arrow) without focal aneurysms. (I) Cardiac magnetic resonance (CMR) short-axis image normal diameters and wall thickness, and trivial pericardial effusion (arrow). (J) Phase-sensitive inversion recovery sequences showed absence of late gadolinium enhancement. (K) CMR T2 mapping: abnormal values greater than 50 ms (54 ms) suggestive of myocardial oedema (internal normal values  $48 \pm 2$ ). (L) CMR T1 mapping; abnormal values 1091–1105 ms confirming the presence of oedema (internal normal values  $983 \pm 26$ ).



Echocardiography showed normal left ventricular dimensions, trivial increased septal thickness (interventricular septal thickness at end-diastole 8 mm, Z score +2.0; *Figure 1E*), an impaired left ventricular systolic function (left ventricular ejection fraction 48%), and a mild circumferential pericardial

effusion (10 mm: *Figure 1E* and *1F*). Multi-coronary aneurysms were detected: left main coronary artery was 3.9 mm, Z score +2; left anterior descending artery was 3.8 mm, Z score +3.9 (*Figure 1G*); left circumflex coronary artery was 3.6 mm, Z score +3.0; and right coronary artery was

4.3/3.3 mm, respectively, Z score +3.8/+2.4, in the proximal/medial segment (Figure 1H).

A non-invasive ventilatory support and inotropic therapy were started. Intravenous immunoglobulins (IVIGs, 2 g/kg), aspirin (5 mg/kg), diuretics, dexamethasone, hydroxychloroquine, and prophylactic low molecular weight heparin were added as target therapy. A rapid recovery was observed with a complete normalization of left ventricular function and weaning of ventilatory and inotropic support in less than 72 h. Seven days after IVIG inflammation marker and plasmatic interleukin levels normalized, DNA polymerase chain reaction parvovirus B19 couples significantly reduced (Table 1).

Ten days after onset, chest radiography, lung echography, abdominal echography, and echocardiography did not show any abnormalities. Twenty days after onset, a cardiac magnetic resonance imaging (CMRI) showed normal biventricular diameters, volumes, and systolic function (Figure 1I). Phase-sensitive inversion recovery sequences showed absence of late gadolinium enhancement (Figure 1J). T2-mapping sequences showed mild myocardial interstitial oedema (Figure 1K). Moreover, T1 mapping showed increased values, which confirmed the presence of oedema (Figure 1L).

The patient was discharged on aspirin therapy. The 1 month echocardiographic follow-up was normal.

## Discussion

Herein, we describe the case of a 6-year-old boy admitted for persistent fever who rapidly progressed to respiratory distress, ventricular dysfunction, and shock. Coronary aneurysms were documented in the acute phase. He tested positive for multi-viral infection including SARS-CoV-2. His blood tests were suggestive of MAS.<sup>6</sup>

SARS-CoV-2-associated myocardial dysfunction has been described in adults and children<sup>3–5,7–9</sup>: the combination of the direct viral insult to cardiomyocytes and myocardial dysfunction due to hyperinflammation with cytokine release is thought to be the mechanism leading to cardiac dysfunction.<sup>7,9</sup> SARS-CoV-2 uses angiotensin-converting enzyme 2 (ACE2) as its entry receptor: in addition to the heart and lung, ACE2 is localized in the vascular endothelium.<sup>10</sup> More than 7.5% of myocardial cells have positive ACE2 expression, which could mediate SARS-CoV-2 entry into cardiomyocytes and cause direct cardiotoxicity.<sup>11</sup> Based on post-mortem biopsies, the pathological features of SARS-CoV-2 in the cardiac tissue vary from minimal change to interstitial inflammatory infiltration and myocyte necrosis. Moreover, microthrombosis and vascular inflammation were found.<sup>12</sup> The increased values of troponin may be caused by the myocardial injury either viral or due to the cytokine-driven myocardial damage or by the presence of

vasculitis.<sup>13</sup> While elevated troponin levels in adults with COVID-19 are associated with a poorer outcome, in children, the prognostic value in COVID-19 setting has to be investigated; however, as in our case, a normalization of cardiac biomarkers is associated with a good prognosis, and serial testing could be useful in detecting patients at risk.<sup>3–5</sup> IVIGs are known to modulate immune and inflammatory response by a variety of mechanisms and are used in several systemic autoimmune diseases with no major side effects,<sup>14,15</sup> and they are the standard treatment for KD and also the standard local protocol for myocarditis.<sup>3,5,14–16</sup> Therefore, the patient was treated using the IVIGs, and corticosteroids were added for MAS with subsequent clinical, laboratory, and instrumental improvement.

An important increase of KD incidence was noticed in the regions severely affected by the SARS-CoV-2 epidemic,<sup>5</sup> mostly the patients with Kawasaki disease shock syndrome and MAS.<sup>6</sup> Because both KD and MIS are systemic inflammatory syndromes, they share clinical, laboratory features and pathological pathways with consequences such as cardiac involvement, elevation of inflammatory markers, and coagulopathy in the absence of other microbial causes.

Notably, despite a rapidly evolving critical clinical presentation with high inflammatory markers, multisystem dysfunction, polyserositis with pleural and pericardial effusion, myocardial dysfunction, and coronary aneurysms, treatment with IVIG and steroid therapy were remarkable, as in most cases of KD. Moreover, aspirin was started given the presence of coronary lesions and according to previous studies that described endothelial dysfunction, microthrombosis, and vascular inflammation.<sup>7</sup> To date, no recommendations for the duration of anti-aggregating therapy have yet been published, but it seems reasonable to follow the same suggested for KD.

Coinfections in children with COVID-19 are described: our patient had a coinfection with parvovirus B19.<sup>14</sup> Positive viral serology does not imply myocardial infection but rather indicates the interaction of the peripheral immune system with an infectious agent, which we believe happened in our case; the presence of MIS was associated with transitory myocardial injury. In addition, the interaction between parvovirus B19 and SARS-CoV-2 might maintain myocardial (low-grade) inflammation and consequently the myocardial depression. Furthermore, the optimal response to treatment and the evidence of isolated septal oedema more than necrosis at the CMRI make cardiac stunning more conceivable.

A relatively recent review showed no difference in parvovirus B19 prevalence between myocarditis/dilated cardiomyopathy and healthy control hearts.<sup>17</sup> However, findings suggest that parvovirus B19 can be aetiologically relevant either in the presence of other cardiotropic viruses or when parvovirus B19 load is high and/or actively replicating, which both may maintain myocardial (low-grade) inflammation. If it was true,

combination of COVID/parvovirus B19 also could be a possible aetiological factor in developing myocardial depression.

In addition, in line with the previous series,<sup>3</sup> cardiac, pulmonary, and laboratory manifestations of our patient completely regressed without sequelae.

Because hydroxychloroquine can inhibit replication of SARS-CoV-2 in vitro, its use has been promoted for treatment and prevention of COVID-19 despite conflictual data have been published about its efficacy<sup>18</sup> and its side effects on QT prolongation.<sup>19,20</sup> At the time of patient's hospitalization, the hydroxychloroquine was recommended empirically by the local/national guidelines in patients with SARS-CoV-2 infection and pulmonary involvement and was administered under regular electrocardiogram and blood test monitoring without adverse reactions.

In conclusion, our case underlines the presence of MIS in paediatric patients with SARS-CoV-2 infection with a

multi-organ involvement and a rapidly progressive clinical impairment. As previously described, shock might complicate the clinical presentation, and cardiac involvement is not exceptional. Our findings evidenced a reversible myocardial injury probably related with cytokine storm rather than direct viral damage considering the rapid recovery and the absence of myocardial necrosis at CMRI. Moreover, IVIG results were remarkable and safe in the acute stage. There are also other unanswered questions such as the long-term therapy, especially when coronaries are involved, and the timing of the follow-up.

## Conflict of interest

None declared.

## References

- Wu Z, McGoogan JM. Characteristics of and important lessons from the coronavirus disease 2019 (COVID-19) outbreak in China: summary of a report of 72 314 cases from the Chinese Center for Disease Control and Prevention. *JAMA* 2020; **323**: 1239–1242.
- Tagarro A, Epalza C, Santos M, Sanz-Santaufemia FJ, Otheo E, Moraleda C, Calvo C. Screening and severity of coronavirus disease 2019 (COVID-19) in children in Madrid, Spain. *JAMA Pediatr* 2020; e201346.
- Belhadjer Z, Meot M, Bajolle F, Khraiche D, Legendre A, Abakka S, Auriiau J, Grimaud M, Oualha M, Beghetti M, Wacker J. Acute heart failure in multi-system inflammatory syndrome in children (MIS-C) in the context of global SARS-CoV-2 pandemic. *Circulation* 2020; **142**: 429–436.
- Whittaker E, Bamford A, Kenny J, Kaforou M, Jones CE, Shah P, Ramnarayan P, Fraise A, Miller O, Davies P, Kucera F, Brierley J, McDougall M, Carter M, Tremoulet A, Shimizu C, Herberg J, Burns JC, Lyall H, Levin M, for the PIMS-TS Study Group and EUCLIDS and PERFORM Consortia. Clinical characteristics of 58 children with a pediatric inflammatory multisystem syndrome temporally associated with SARS-CoV-2. *JAMA* 2020; **324**: 259–269.
- Verdoni L, Mazza A, Gervasoni A, Martelli L, Ruggeri M, Ciuffreda M, Bonanomi E, D'Antiga L. An outbreak of severe Kawasaki-like disease at the Italian epicentre of the SARS-CoV-2 epidemic: an observational cohort study. *Lancet* 2020; **395**: 1771–1778.
- Ravelli A, Minoia F, Davi S, Horne A, Bovis F, Pistorio A, Arico M, Avcin T, Behrens EM, De Benedetti F, Filipovic L, Grom AA, Henter J-I, Ilowite NT, Jordan MB, Khubchandani R, Kitoh T, Lehmberg K, Lovell DJ, Miettunen P, Nichols KE, Ozen S, Schmid JP, Ramanan AV, Russo R, Schneider R, Sterba G, Uziel Y, Wallace C, Wouters C, Wulffraat N, Demirkaya E, Brunner HI, Martini A, Ruperto N, Cron RQ, Paediatric Rheumatology International Trials Organisation, Childhood Arthritis and Rheumatology Research Alliance; Pediatric Rheumatology Collaborative Study Group, Histiocyte Society. 2016 classification criteria for macrophage activation syndrome complicating systemic juvenile idiopathic arthritis: a European League Against Rheumatism/American College of Rheumatology/Paediatric Rheumatology International Trials Organisation Collaborative Initiative. *Ann Rheum Dis* 2016; **75**: 481–489.
- Kang Y, Chen T, Mui D, Ferrari V, Jagasia D, Scherrer-Crosbie M, Chen Y, Han Y. Cardiovascular manifestations and treatment considerations in covid-19. *Heart* 2020; **106**: 1132–1141.
- Shekerdemian LS, Mahmood NR, Wolfe KK, Riggs BJ, Ross CE, McKiernan CA, Heidemann SM, Kleinman LC, Sen AI, Hall MW, Priestley MA, McGuire JK, Boukas K, Sharron MP, Burns JP, for the International COVID-19 PICU Collaborative. Characteristics and outcomes of children with coronavirus disease 2019 (COVID-19) infection admitted to US and Canadian pediatric intensive care units. *JAMA Pediatr* 2020; **174**: 868.
- Siripanthong B, Nazarian S, Muser D, Deo R, Santangeli P, Khanji MY, Cooper LT Jr, Chahal CAA. Recognizing COVID-19-related myocarditis: the possible pathophysiology and proposed guideline for diagnosis and management. *Heart Rhythm* 2020; **17**: 1463–1471.
- Hoffmann M, Kleine-Weber H, Schroeder S, Kruger N, Herrler T, Erichsen S, Schiergens TS, Herrler G, Wu NH, Nitsche A, Müller MA, Drosten C, Pöhlmann S. SARS-CoV-2 cell entry depends on ACE2 and TMPRSS2 and is blocked by a clinically proven protease inhibitor. *Cell* 2020; **181**: 271–280 e278.
- Zou X, Chen K, Zou J, Han P, Hao J, Han Z. Single-cell RNA-seq data analysis on the receptor ACE2 expression reveals the potential risk of different human organs vulnerable to 2019-nCoV infection. *Front Med* 2020; **14**: 185–192.
- Zhou F, Yu T, Du R, Fan G, Liu Y, Liu Z, Xiang J, Wang Y, Song B, Gu X, Guan L, Wei Y, Li H, Wu X, Xu J, Tu S, Zhang Y, Chen H, Cao B. Clinical course and risk factors for mortality of adult inpatients with COVID-19 in Wuhan, China: a retrospective cohort study. *Lancet* 2020; **395**: 1054–1062.
- Tersalvi G, Vicenzi M, Calabretta D, Biasco L, Pedrazzini G, Winterton D. Elevated troponin in patients with coronavirus disease 2019: possible mechanisms. *J Card Fail* 2020; **26**: 470–475.
- Caforio AL, Pankuweit S, Arbustini E, Basso C, Gimeno-Blanes J, Felix SB, Fu M, Helio T, Heymans S, Jahns R, Klingel K, Linhart A, Maisch B, McKenna W, Mogensen J, Pinto YM, Ristic A, Schultheiss H-P, Seggewiss H, Tavazzi L, Thiene G, Yilmaz A, Charron P, Elliott PM, European Society of Cardiology Working Group on Myocardial and Pericardial Diseases. Current state of knowledge on aetiology, diagnosis,

- management, and therapy of myocarditis: a position statement of the European Society of Cardiology Working Group on Myocardial and Pericardial Diseases. *Eur Heart J* 2013; **34**: 2636–2648, 2648a–2648d.
15. Li Y, Yu Y, Chen S, Liao Y, Du J. Corticosteroids and intravenous immunoglobulin in pediatric myocarditis: a meta-analysis. *Front Pediatr* 2019; **7**: 342.
  16. McCrindle BW, Rowley AH, Newburger JW, Burns JC, Bolger AF, Gewitz M, Baker AL, Jackson MA, Takahashi M, Shah PB, Kobayashi T, Wu M-H, Saji TT, Pahl E, American Heart Association Rheumatic Fever, Endocarditis, and Kawasaki Disease Committee of the Council on Cardiovascular Disease in the Young, Council on Cardiovascular and Stroke Nursing; Council on Cardiovascular Surgery and Anesthesia, Council on Epidemiology and Prevention. Diagnosis, treatment, and long-term management of Kawasaki disease: a scientific statement for health professionals from the American Heart Association. *Circulation* 2017; **135**: e 927–e999.
  17. Verdonshot J, Hazebroek M, Merken J, Debing Y, Dennert R, Brunner-La Rocca HP, Heymans S. Relevance of cardiac parvovirus B19 in myocarditis and dilated cardiomyopathy: review of the literature. *Eur J Heart Fail* 2016; **18**: 1430–1441.
  18. Cohen MS. Hydroxychloroquine for the prevention of Covid-19—searching for evidence. *N Engl J Med* 2020; **383**: 585–586.
  19. O'Connell TF, Bradley CJ, Abbas AR, Williamson BD, Rusia A, Tawney AM, Gaines R, Schott J, Dmitrienko A, Haines DE. Hydroxychloroquine/azithromycin therapy and QT prolongation in hospitalized patients with COVID-19. *JACC Clin Electrophysiol* August 2020.
  20. Tuncer T, Karaci M, Boga A, Durmaz H, Guven S. QT interval evaluation associated with the use of hydroxychloroquine with combined use of azithromycin among hospitalised children positive for coronavirus disease 2019. *Cardiol Young* 2020; **20**: 1–4.