

Available online at www.sciencedirect.com

ScienceDirect

journal homepage: www.elsevier.com/locate/radcr

Case Report

Bone echinococcosis with hip localization: A case report with evaluation of imaging features [☆]

Giuseppe Martinese, M.D.^{a,*}, Vincenzo Lucidi, M.D.^a, Paola Di Masi, M.D.^a,
 Francesco Adduci, M.D.^a, Alberta Cappelli, M.D.^a, Matteo Renzulli, M.D.^a, Massimiliano De
 Paolis, M.D.^b, Michele Fiore, M.D.^b, Rita Golfieri, M.D.^a

^a Department of Radiology, IRCSS Azienda Ospedaliero-Universitaria di Bologna, Via Albertoni 15, 40138 Bologna, Italy

^b Department of Orthopedics and Traumatology, IRCSS Azienda Ospedaliero-Universitaria di Bologna, Via Albertoni 15, 40138 Bologna, Italy

ARTICLE INFO

Article history:

Received 6 June 2022

Revised 13 June 2022

Accepted 21 June 2022

Available online 19 July 2022

Keywords:

Pelvis

Echinococcosis

Computed tomography

Magnetic resonance imaging

X-ray computed

Management

ABSTRACT

Hydatid disease (HD) is a zoonotic parasitic disease caused by the larvae of *Echinococcus*. Bone echinococcosis is rare, accounting for 0.5% to 4% of all echinococcosis. We describe a particular case of pelvic echinococcosis. A 29-year-old man initially presents with pain in his left hip for several years. After an accidental fall from a tree, he suffered a fracture of the left acetabulum. X-rays and CT scans showed an osteolytic area of the acetabulum with bony cortical interruption. MR imaging demonstrated extensive area of osteostructural alteration of the iliac wing and the left acetabulum due to multiple cysts with enhancement of the walls after administration of Gadolinium-based contrast agents. A CT-guided biopsy of an osteolytic area was performed with diagnosis of echinococcus cyst. He underwent albendazole therapy and subsequently echinococcus cyst exeresis, bone curettage, and left hip arthroplasty. Twenty-two months after surgery, CT scan showed recurrence of disease. After 4 years and 6 months of chronic therapy CT scan showed an increase in size of the cyst at the site of the disease recurrence. Five years and 4 months after the first operation, a new cyst exeresis and pelvic bone curettage with implant retention was performed. This case report demonstrates that hydatid cysts should be considered as a possible cause for non-specific pelvic pain, especially in endemic locations.

© 2022 The Authors. Published by Elsevier Inc. on behalf of University of Washington.

This is an open access article under the CC BY-NC-ND license (<http://creativecommons.org/licenses/by-nc-nd/4.0/>)

Introduction

Human echinococcosis is a zoonotic infection. Cystic echinococcosis may affect all organs, but mostly settles

in the liver and lungs. Primary *Echinococcus* infection of bone is rare, with reported rates of 0.5%-4% of the total cases of *hydatid disease* [1]. The spine is the most common osseous location of infection, followed by the long bones (femur, tibia, and humerus), skull, and ribs. Pelvic involvement is extremely

[☆] Competing Interests: All authors declare no conflict of interest.

* Corresponding author.

E-mail address: giuseppe.martinese@studio.unibo.it (G. Martinese).
<https://doi.org/10.1016/j.radcr.2022.06.065>

1930-0433/© 2022 The Authors. Published by Elsevier Inc. on behalf of University of Washington. This is an open access article under the CC BY-NC-ND license (<http://creativecommons.org/licenses/by-nc-nd/4.0/>)

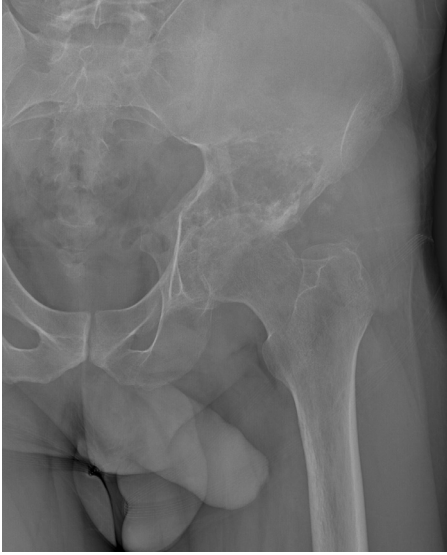

Fig. 1 – X-rays demonstrates an expansile lytic process involving the acetabular region of the left hip.

rare, with few cases reported in the literature. We describe a particular case of pelvic echinococcosis, which required a total hip replacement and clearly describes the clinical challenges related to this pathology, focusing on radiological features.

Case report

A 29-year-old man initially presents with pain in his left hip for several years. After an accidental fall from a tree, he suffered a fracture of the left acetabulum treated with traction for 30 days. He underwent X-rays and CT scans that showed an osteolytic area of the acetabulum with bony cortical interruption in a pathological acetabular fracture. A CT-guided biopsy of an osteolytic area was performed with diagnosis of echinococcus cyst.

He underwent albendazole therapy for 5 months and subsequently echinococcus cyst exeresis, bone curettage, and left hip arthroplasty with cemented Burch-Schneider ring via Smith-Petersen approach were performed, continuing albendazole for 4 weeks after surgery.

Twenty-two months after surgery, CT scan with contrast medium showed the appearance of fluid-like formation starting from osteolysis of the posterior column of the acetabulum suggesting recurrence of disease, therefore, albendazole therapy was resumed with subsequent reduction of the cystic area.

After 4 years and 6 months of chronic therapy an additional control CT scan was performed showing an increase in size of the cyst at the site of the disease recurrence.

Five years and 4 months after the first operation, a new cyst exeresis and pelvic bone curettage with implant retention via xiphopubic approach was performed, considering the exclu-

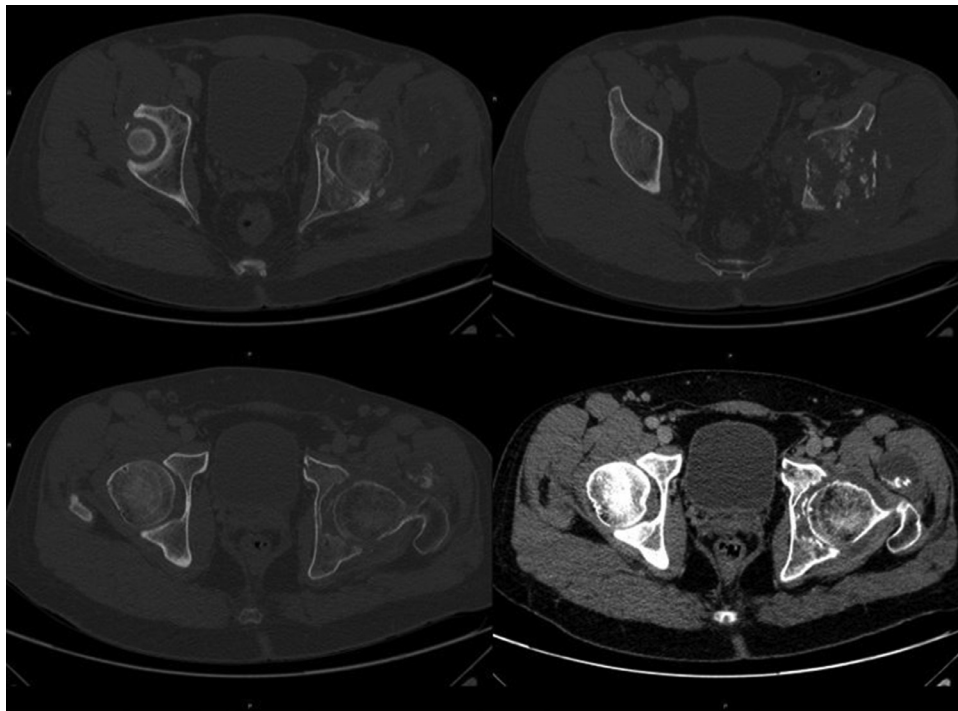


Fig. 2 – CT scan demonstrates a lytic process involving the acetabular region of the left hip and also shows extraosseous fluid/overfluid component with multiple contextual calcifications involving the gluteus minimus muscle and the ipsilateral internal obturator muscle.

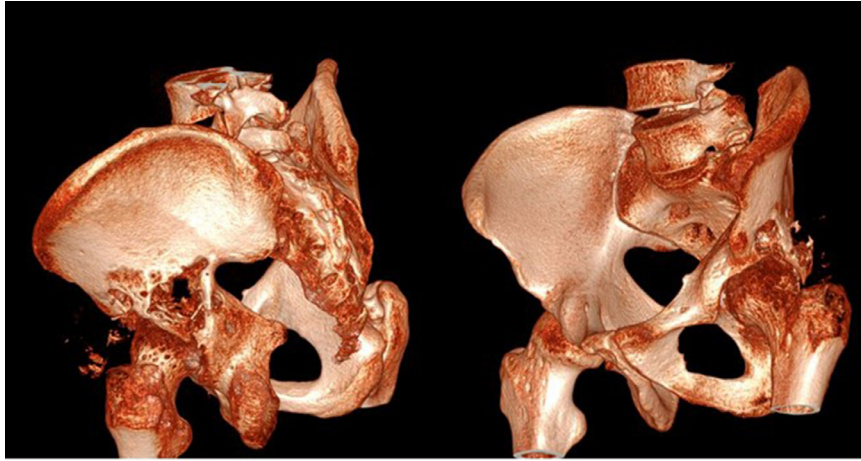


Fig. 3 – CT 3D reconstruction of lytic acetabular process.

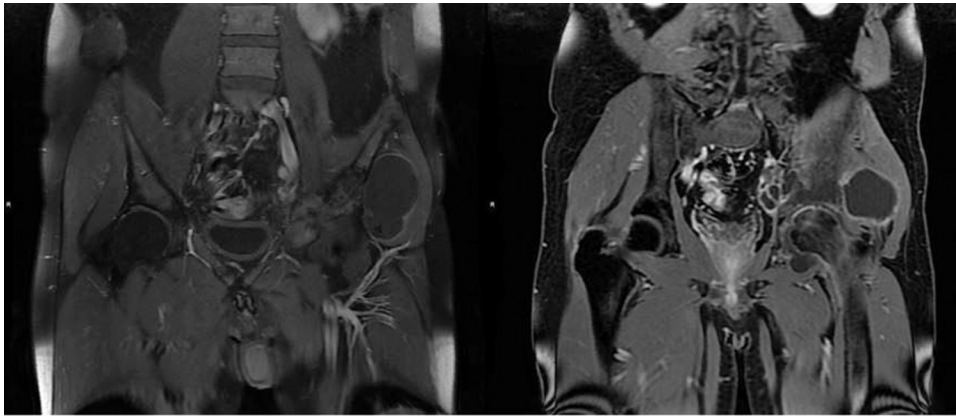


Fig. 4 – MR with T1-weighted image demonstrates extensive area of osteostructural alteration of the iliac wing and the left acetabular roof for the presence of multiple cystic formations with enhancement of the walls after administration of Gadolinium-based contrast agents.

sively endopelvic extension of the recurrence with involvement of the obturator fossa.

From a radiological point of view, radiographs demonstrated an expansile lytic process involving the acetabular region of the left hip (Fig. 1).

CT scan confirmed the lytic process that also shows extraosseous fluid/overfluid component with multiple contextual calcifications involving the gluteus minimus muscle and the ipsilateral internal obturator muscle; the intramedullary margins of the process were not well defined (Figs. 2 and 3).

MR imaging demonstrated extensive area of osteostructural alteration of the iliac wing and the left acetabulum due to multiple cysts with enhancement of the walls after administration of Gadolinium-based contrast agents (Fig. 4), apparently communicating with the joint. Within the larger cysts, a few millimetric oval images with a void signal in the joint cavity are appreciated. This formation extended medially into the pelvis – with slight dislocation of the iliac vessels – and laterally to the gluteal region, contained below the fascial planes where the largest cysts (max. 68 × 50 × 76 mm) are appreciated. Associated medullary edema of the femoral head and, to a lesser extent, of the left iliac wing adjacent to the

sacroiliac synchondrosis was found, correlating with reactive-phlogistic phenomena. STIR-sequences were also performed that demonstrated hyperintensity of the iliac muscle and the gluteus medius muscle at their bony insertion (Fig. 5). Radiographs performed after surgery showed the results of curettage and prosthetic implantation (Fig. 6). A CT scan performed 22 months after first surgery showed the recurrence of the disease starting from the posterior acetabular wall and involving soft tissues medial to the coxofemoral joint (Fig. 7). After the second surgery no residual disease was detectable on CT scan (Fig. 8).

Discussion

Bone hydatidosis is uncommon and, in contrast to other organs, the hydatid cysts in bone do not develop a pericyst, which is a dense fibrous protective layer of modified host cells [2]. The rigid structure of bone limits uniform enlargement and leads to the slow and insidious, yet extensive, spread of

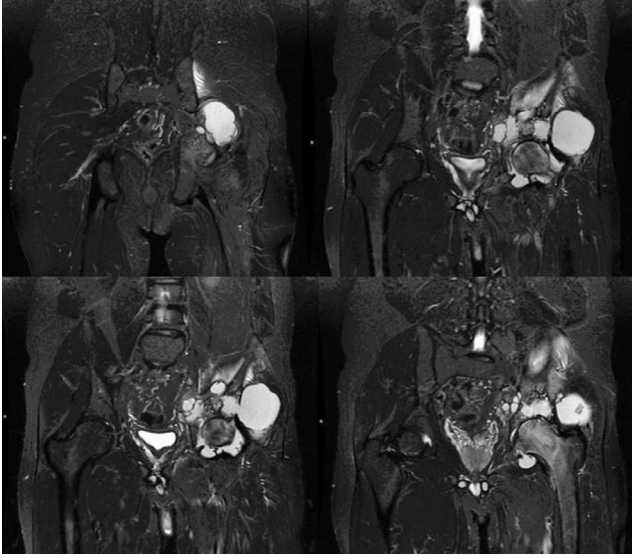


Fig. 5 – MRI with STIR sequences demonstrates multiple cystic areas at the site of the left acetabular region, the largest of which was 68 x 50 x 76 mm, with some parietal calcifications. There is associated medullary edema of the femoral head and, to a lesser extent, on the left iliac wing adjacent to the sacroiliac synchondrosis, in relation to reactive-phlogistic phenomena. In addition hyperintensity of the iliac muscle and the gluteus medius muscle at their bony insertion.

the organism in an irregular branching pattern along the path of least resistance through the osseous canals [3].

Due to the slow growth of the cyst, years to decades may pass before clinical symptoms occur. The cysts may also be identified incidentally at radiologic evaluation. In cases of primary hydatid disease of bone, patients usually present with vague pain. As in this case, patients may present with a pathologic fracture related to osseous destruction [2–4].

Pelvic bone disease is particularly difficult to diagnose, given the vague symptomatology facilitated by the possibil-

ity for the lesion to occupy a large space in the pelvic cavity before becoming manifest. To date, to the best of our knowledge, only 3 small series of patients [5] and few case reports collected in previous studies [6] are reported in the literature concerning pelvic involvement. Clinical presentations may be different. Lesions may penetrate through the bony cortex and invade the surrounding soft tissue to form a mass. When they infiltrate the skin, chronic suppurative osteomyelitis may develop with the formation of long-term unhealed fistulas and the discharge of hydatid debris and pus. If the joint is involved, it can cause pathological dislocation. However, when clinical symptoms such as pain, swelling, abnormal walking, incontinence due to nerve compression, paraplegia due to compressive neuropathies of the femoral or sciatic nerves, and other related symptoms appear, the lesion is already extensive.

There are various surgical treatment options when the hip joint is involved with destructive effect. Belzunegui et al have shown good functional outcome after Girdlestone arthroplasty [7]. Siwach et al reported a case of extensive hydatid disease of pelvis and femur for which a hindquarter amputation was performed [8]. However, the justifiable need for limb-sparing surgery which also preserves limb function makes arthroplasty the first choice in cases of a disrupted joint, although the high risk of secondary bacterial infection cannot be neglected [9]. With this report we have presented a rare case of successful treatment with hip arthroplasty, although burdened by recurrence.

At radiography and computed tomography, the collapsed and folded membrane layers surrounding the fluid-filled lumen appear as closely spaced lacunar lesions with osseous expansion and cortical disruption is seen, without periosteal reaction. Typically, no clear boundary is depicted between normal and abnormal bone [10,11]. At MR imaging, the membranes are seen as the T1- and T2-hypointense layers interspersed with the fluid-signal-intensity cystic areas [12]. MR imaging is useful for detection of soft-tissue and nerve involvement, as well as early recurrence after resection [13].

The differential diagnosis for hydatid disease varies on the basis of location and appearance but often includes neoplasm and infection. In particular, aneurysmal bone cyst, giant cell tumor, and bone tuberculosis can be considered in differential

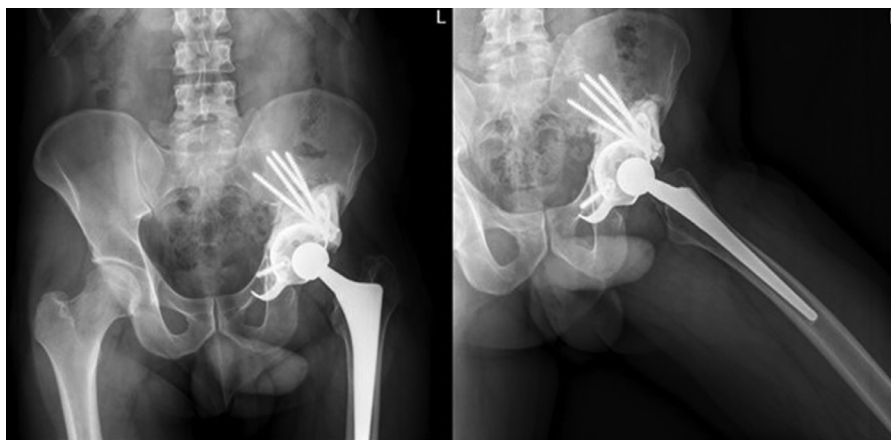


Fig. 6 – X-rays after cyst exeresis with implantation of left total hip prosthesis.

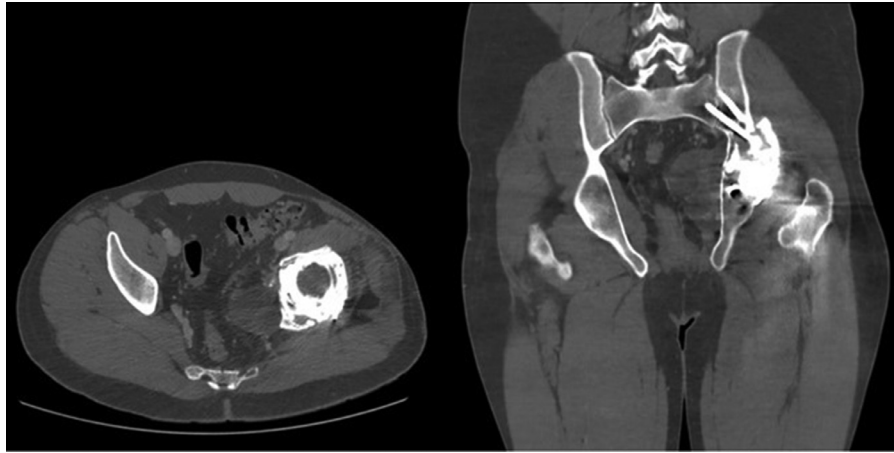


Fig. 7 – CT axial and coronal reconstruction demonstrates recurrence of echinococcus disease starting from the posterior acetabular wall and involving soft tissues medial to the coxo-femoral joint.

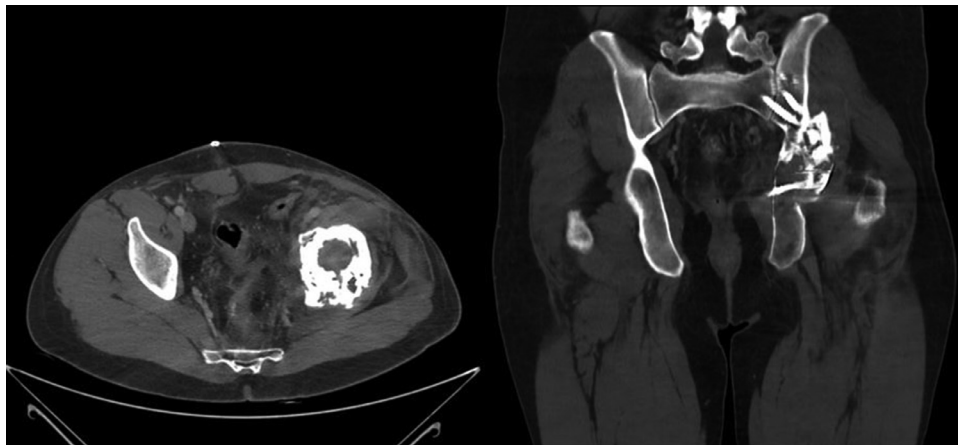


Fig. 8 – CT scan post-excision of the disease recurrence with implant retention.

diagnosis of bone echinococcosis. Definitive diagnosis can be made with biopsy or aspiration, but the latter has classically not been recommended because of the risk of further dissemination or anaphylaxis. Antibody analysis, which was done in this patient, may also be helpful.

The primary treatment option, regardless of the location of the infection, is usually surgery. Other treatment options include aspiration with instillation of alcohol, physiologic saline, or antiparasitic medication. Systemic pharmacotherapy is also usually administered. The most commonly administered drug is albendazole, with praziquantel being an alternative choice. Pharmacotherapy is started before surgery and can be continued afterward, in some cases indefinitely [2,4].

Recurrence is frequent, as it happened in this case, and it reaches rates of 30%-100% [14]. This is particularly true in bones. As mentioned above, unlike other viscera, there is no adventitia formation in skeletal hydatidosis (due to the rigid structure of the bone). This allows for microvesicular invasion of the daughter cysts into the bony tissue [12]. As a result,

due to this issue and lack of clear-cut demarcation between normal and pathological tissues, complete eradication of the parasite is often unsuccessful despite extensive surgery. Presentation within an anatomically complex district such as the pelvis can only further decrease the chances of obtaining radical surgery. Unfortunately, due to its high rate of recurrence prognosis is poor. Long-term radiologic follow-up is recommended at least once a year to identify recurrence at the site that needs to be excised.

This report has tried to emphasise how this disease requires awareness and up-to-date knowledge on the part of physicians, especially in endemic areas when patients present with generalized musculoskeletal disorders.

Patient consent statement

Patient was informed of the publication of a case report regarding his clinical case and provided written consent for pub-

lication. Furthermore, the patient is aware that his name will not appear in the text of the article.

REFERENCES

- [1] Torricelli P, Martinelli C, Biagini R, Ruggieri P, De Cristofaro R. Radiographic and computed tomographic findings in hydatid disease of bone. *Skeletal Radiol* 1990;19:435–9. doi:10.1007/BF00241799.
- [2] Pedrosa I, Saíz A, Arrazola J, Ferreirós J, Pedrosa CS. Hydatid disease: radiologic and pathologic features and complications. *Radiographics* 2000;20(3):795–817 PMID: 10835129. doi:10.1148/radiographics.20.3.g00ma06795.
- [3] Abramson, A D. and Barger, R L. and O’Hora, K T. and Dulai, M S. AIRP best cases in radiologic-pathologic correlation: primary echinococcus infection of the femur. *RadioGraphics*. doi:10.1148/rg.334125197.
- [4] Pawlowski Z, Eckert J, Vuitton DA, Ammann RW, Kern P, Craig PS. Echinococcosis in humans: clinical aspects, diagnosis and treatment. In: WHO/OIE Manual on Echinococcosis in humans and animals. Paris: Office International des Epizooties; 2001. p. 20–71.
- [5] Chen YW, Aikebaier A, Zhao Y. Evaluation of imaging features of pelvic echinococcosis based on multimodal images. *J Orthop Surg Res*. 2020 Oct 26;15(1):493. doi:10.1186/s13018-020-01912-2. PMID: 33106164; PMCID: PMC7590711 + Inayat F, Azam S, Baig AS, et al. Presentation patterns, diagnostic modalities, management strategies, and clinical outcomes in patients with hydatid disease of the pelvic bone: a comparative review of 31 cases [J]. *Cureus*. 2019;11(3):e4178. + Merkle EM, Schulte M, Vogel J, et al. Musculoskeletal involvement in cystic echinococcosis: report of eight cases and review of the literature. *AJR Am J Roentgenol*. 1997;168:1531–4.
- [6] Bhatnagar N, Kishan H, Sura S, Lingaiah P, Jaikumar K. Pelvic hydatid disease: a case report and review of literature. *J Orthop Case Rep*. 2017;7(4):25–28. doi:10.13107/jocr.2250-0685.834 + Banerjee S, Gupta A, Choudhary R, Singh Rathore K, Khera S. Pelvic echinococcosis presenting as a mass in the gluteal region: a case report. *Infez Med*. 2019;27(4):456–460. PMID: 31847000.
- [7] Belzunegui J, Maíz O, López L, Plazaola I, González C, Figueroa M. Hydatid disease of bone with adjacent joint involvement. A radiological follow-up of 12 years. *Br J Rheumatol* 1997;36(1):133–5.
- [8] Siwach R, Singh R, Kadian VK, Singh Z, Jain M, Madan H, et al. Extensive hydatidosis of the femur and pelvis with pathological fracture: a case report. *Int J Infect Dis* 2009;13(6):e480–2.
- [9] Steinmetz S, Racloz G, Stern R, Dominguez D, Al-Mayahi M, Schibler M, et al. Treatment challenges associated with bone echinococcosis. *J Antimicrob Chemother* 2014;69(3):821–6.
- [10] Kural C, Ugras AA, Sungur I, Ozturk H, Erturk AH, Unsaldi T. Hydatid bone disease of the femur. *Orthopedics* 2008;31(7):712 PMID: 19292369.
- [11] Zlitni M, Ezzaouia K, Lebib H, Karray M, Kooli M, Mestiri M. Hydatid cyst of bone: diagnosis and treatment. *World J Surg* 2001;25(1):75–82.
- [12] Papanikolaou A. Osseous hydatid disease. *Trans. R. Soc. Trop. Med. Hyg*. 102, 3, 233–238, 2008. + Zlitni M., Ezzaouia K., Lebib H., Karray M., Kooli M., Mestiri M. Hydatid cyst of bone: diagnosis and treatment. *World. J. Surg*. 2001;25(1):75–82.
- [13] Goodier M, Rubin G. Echinococcal disease of the bone: an unusual cause of a pathological fracture. *S Afr J Radiol* 2010;14(4):116–17.
- [14] Schnepfer GD, Johnson WD. Recurrent spinal hydatidosis in North America. *Neurosurg Focus* 2004;17(6):1–6. doi:10.3171/foc.2004.17.6.