

## Positive Anagen Pull Test Predicting Lichen Planopilaris Activity

Raíssa Rodriguez Melo<sup>1</sup>, Rita Fernanda Cortez de Almeida<sup>1</sup>,  
Michela Valeria Rita Starace<sup>2,3</sup>, Daniel Fernandes Melo<sup>1</sup>

1 Department of Dermatology, State University of Rio de Janeiro (UERJ), Rio de Janeiro, Brazil

2 Dermatology, IRCCS Azienda Ospedaliero-Universitaria di Bologna, Bologna, Italy

3 Department of Medical and Surgical Sciences, Alma Mater Studiorum, University of Bologna, Bologna, Italy

**Citation:** Rodriguez Melo R, Cortez de Almeida RF, Starace MVR, Melo DF. Positive Anagen Pull Test Predicting Lichen Planopilaris Activity. *Dermatol Pract Concept*. 2023;13(3):e2023140. DOI: <https://doi.org/10.5826/dpc.1303a140>

**Accepted:** December 2, 2022; **Published:** July 2023

**Copyright:** ©2023 Rodriguez Melo et al. This is an open-access article distributed under the terms of the Creative Commons Attribution-NonCommercial License (BY-NC-4.0), <https://creativecommons.org/licenses/by-nc/4.0/>, which permits unrestricted noncommercial use, distribution, and reproduction in any medium, provided the original authors and source are credited.

**Funding:** None.

**Competing interests:** None.

**Authorship:** All authors have contributed significantly to this publication.

**Corresponding author:** Raíssa Rodriguez Melo, Department of Dermatology, State University of Rio de Janeiro (UERJ), Boulevard 28 de Setembro, 77, Rio de Janeiro, Rio de Janeiro, 20551-030, Brazil. Tel: +55 21 28688478; E-mail: [rodriguezraissaa@gmail.com](mailto:rodriguezraissaa@gmail.com)

### Case Presentation

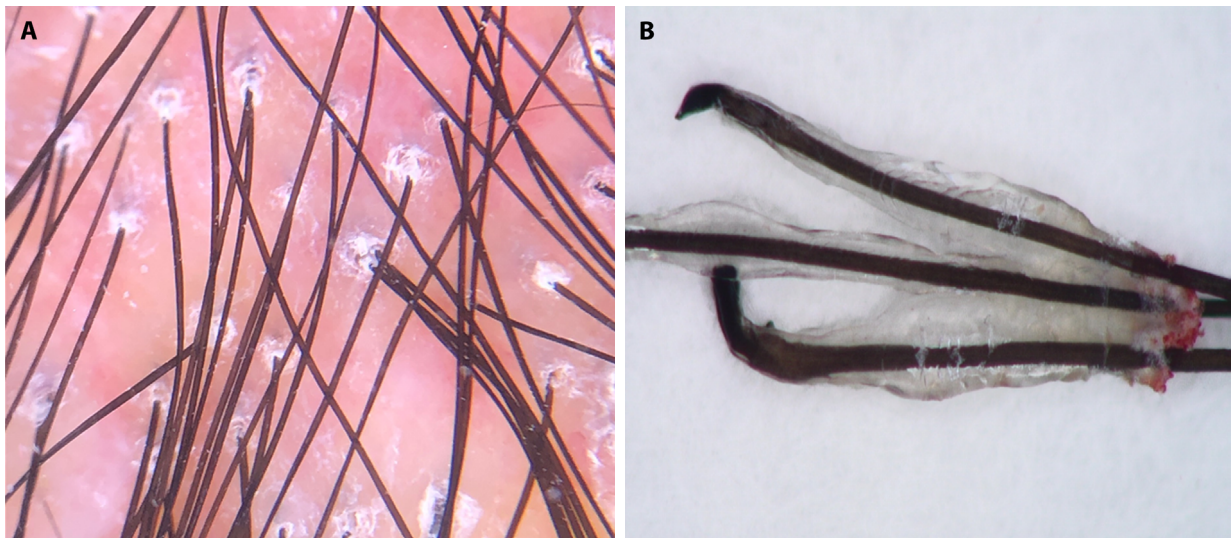
A healthy 32-year-old Caucasian male complained of patches of alopecia on the right temple and mid-scalp that started three months before. Physical examination showed two irregular patches of scarring alopecia of approximately 5 cm associated with trichodynia. The patches trichoscopic features were consistent with lichen planopilaris (LPP) in the acute phase (Figure 1A).

The pull test was positive and revealed golf club-shaped, pigmented hair roots on trichoscopy, typical of anagen bulbs, surrounded by a translucent root sheath and bleeding area (Figure 1B). A trichoscopy-guided biopsy followed by histopathological examination confirmed the suspicion of LPP.

Treatment with topical clobetasol propionate, oral prednisolone 0,5mg/kg/day, and hydroxychloroquine 5mg/kg/day was started. After 3 months, the patient had improved and presented a negative pull test.

### Teaching Point

LPP is a primary scarring alopecia that usually presents with hair loss at the vertex or parietal scalp, and may be associated with pain, itchiness, burning, or tenderness. The histopathology is characterized by perifollicular lymphocytic infiltrate at the follicular isthmus and infundibulum. On trichoscopy, perifollicular hyperkeratosis and erythema are typical signs of active LPP [1,2]. A positive anagen pull test consists of anagen bulbs with attached inner and outer root sheaths [1-3]. Extraction of anagen hair with thickened roots is uncommon and strongly suggests cicatricial alopecia in the acute phase [1,2], as the inflammatory infiltrate may prematurely release anagen hairs. It has been previously described predicting disease activity in discoid lupus erythematosus and Brocq's pseudopelade, since it is compatible with active interface dermatitis on histopathology [2,3]. In the reported case, it was associated with LPP activity, supported by clinical, trichoscopic, and histopathological findings.



**Figure 1.** (A) Trichoscopy shows erythema and perifollicular hyperkeratosis in lichen planopilaris. (B) Golf club-shaped pigmented anagen bulbs surrounded by the root sheath and a bleeding area.

## References

1. Harries MJ, Trueb RM, Tosti A, et al. How not to get scared: pointers to the correct diagnosis in patients with suspected primary cicatricial alopecia. *Br J Dermatol.* 2009;160(3):482-501. DOI:10.1111/j.1365-2133.2008.09008.x PMID: 19183169.
2. Lajevardi V, Mahmoudi H, Moghanlou S, Ansari M, Teimourpour A, Daneshpazhooh M. Assessing the correlation between trichoscopic features in lichen planopilaris and lichen planopilaris activity index. *Australas J Dermatol.* 2019;60(3): 214-218. DOI:10.1111/ajd.13022 PMID: 30957880.
3. Azulay L, Hanauer L, Leal F, Azulay DR. Alopecias cicatriciais. In: *Atlas de Dermatologia da semiologia ao diagnóstico.* 3rd edition. Rio de Janeiro: Guanabara Koogan; 2020: p156.