



Safety of boneless reconstruction of the mandible with a CAD/CAM designed titanium device: The replica cohort study / Bedogni A., Bettini G.; Bedogni B., Merlappo G., Sandi A., Micheloni F., Di Carlo R.; Franco P.; Saia G. - In: ORAL ONCOLOGY, ISSN 1368-8375, - STAMPA - 112:(2021), pp. 105073.1-105073.8. [10.1016/j.oraloncology.2020.105073]

ARCHIVIO ISTITUZIONALE
DELLA RICERCA

Alma Mater Studiorum Università di Bologna Archivio istituzionale della ricerca

Safety of boneless reconstruction of the mandible with a CAD/CAM designed titanium device: The replica cohort study

This is the final peer-reviewed author's accepted manuscript (postprint) of the following publication:

Published Version:

Availability:

This version is available at: <https://hdl.handle.net/11585/959556> since: 2024-02-20

Published:

DOI: <http://doi.org/10.1016/j.oraloncology.2020.105073>

Terms of use:

Some rights reserved. The terms and conditions for the reuse of this version of the manuscript are specified in the publishing policy. For all terms of use and more information see the publisher's website.

This item was downloaded from IRIS Università di Bologna (<https://cris.unibo.it/>).
When citing, please refer to the published version.

(Article begins on next page)

SAFETY OF BONELESS RECONSTRUCTION OF THE MANDIBLE WITH A CAD/CAM DESIGNED TITANIUM DEVICE: THE REPLICA COHORT STUDY

Alberto Bedogni a,b,*, Giordana Bettini a,b, Giorgio Bedogni c, Giorgia Menapace a, 1, Andrea Sandi d, Fabio Michelon d, Roberto Di Carlo e, Piero Franco a, Giorgia Saia a

a Unit of Maxillofacial Surgery, Department of Neuroscience, University of Padova, Padova, Italy

b Regional Center for the Prevention, Diagnosis and Treatment of Medication and Radiation-related Bone Diseases of the Head and Neck, Azienda Ospedale-Universit` a Padova, Padova, Italy

c Department of Medicine, University of Padova, Via Giustiniani 2, 35128 Padova, Italy

d Sintac S.r.l., Biomedical Engineering, via Ragazzi del '99, 13, 38123 Trento, Italy

e Unit of Otolaryngology, Department of Neuroscience, University of Padova, Via Giustiniani 2, 35128 Padova, Italy

KEYWORDS

Mandibular reconstruction

Computer-assisted surgery

Computer-aided design

Prosthesis implantation

Titanium device

Head and neck cancer

Osteonecrosis of the jaw

Osteoradionecrosis

Quality of life

ABSTRACT

Objective: We evaluated the safety of REPLICA, a CAD/CAM-designed patient-specific titanium mandible, in patients with mandibular defects not suitable for reconstruction with traditional techniques.

Patients and methods: We performed a cohort study with a composite primary outcome assigned at the end of a 1-year follow-up. The outcome was assigned in the presence of all the following: 1) absence of intraoral or skin extrusion of REPLICA; 2) decrease or cessation of oral pain; 3) stability or increase in mouth opening; 4) resumption of oral feeding without the need of nasogastric tube; 5) absence of fracture at multidetector computer tomography (MDCT); 6) absence of displacement (MDCT); 7) absence of screw loosening (MDCT). The secondary outcome was the patient-reported QOL at 6 months of follow-up as detected by the EORTC QLQ-C30 and QLQ-H&N35 questionnaires.

Results: Between March 2012 and June 2017, 18 consecutive patients, with a median (IQR) age of 67 (65;74) underwent reconstruction of mandibular defects with REPLICA at our Unit. The primary outcome was reached by 14 of the 18 patients. QOL data were available for 15 patients at the 6-month follow-up, showing a good profile of general and disease-specific QOL.

Conclusion: REPLICA offered a safe solution at 1-year for the treatment of mandibular defects not suitable for reconstruction with traditional techniques, and was associated with subjective well-being and satisfaction. Further studies are needed to assess the full range of indications of REPLICA.

Introduction

The loss of form and function associated with ablative surgery of the mandible affects social functioning and well-being substantially [1,2]. The restoration of mandibular bone continuity is central to give structural support to the inferior third of the face. The accuracy of the reconstruction is another crucial factor, which cannot be achieved without detailed preoperative planning. The available reconstruction techniques satisfy well-established criteria based on defect type and size and patient features [3].

Vascularized bone reconstruction is the present reference method [4,5], but it is unfeasible in some patients, because of frequent local and systemic contraindications [6]. Until recently, reconstruction plates were the only available alternative to vascularized bone flaps for such patients. Reconstruction plates are useful for defects involving the lateral mandible and not including the condylar unit, but not for complex defects involving the anterior mandible [7,8]. It must be added that the relatively high failure rate associated with the use of standard reconstruction plates, which is due mostly to mechanical overload, has progressively discouraged their use among reconstructive surgeons [9].

Standard mandibular reconstruction plates are made of titanium and require bending to resemble mandibular shape. Independently of when bending is performed, i.e. preoperatively using a stereolithographic model or intraoperatively, overbent plates are at an increased risk of fracture after surgery [10,11]. Locking reconstruction systems were recently introduced to reduce the risk of plate fracture by distributing the maximum masticatory load to the bone-screw interface. Unfortunately, these systems have been shown to produce plate dislocation [12]. Such complication happens because the screw-bone interface is mechanically overloaded, with ensuing screw-head fracture or mandibular bone resorption. Lastly, cutaneous and mucosal extrusion of the plate, due to the instability of surrounding soft-tissues, is a well-known and feared complication, and radiation-treated patients are at greater risk of it [9,13]. The use of standard reconstruction plates is therefore limited to selected patients [8].

Computer-aided design (CAD)/manufacturing (CAM) has a great potential for mandibular reconstruction [14–16], where it was first applied by printing customized titanium plates to support vascularized bone flaps [17]. CAD/CAM reconstruction of the mandible is highly effective and reliable [18–20]. There is, however, little experience on the application of CAD/CAM to the development of patient-specific substitutes of the mandible for individuals who are not candidate to treatment with vascularized bone flaps [21–25].

Few years ago, we reported on the first use of CAD/CAM to produce a titanium mandible (REPLICA, from the latin replicare, to copy) for a fragile patient with many previous unsuccessful mandibular reconstructions [26]. Although the titanium device offered a valid solution for one-stage rehabilitation of mastication, deglutition, speech, and aesthetics in that patient, its overall safety had to be determined by cohort studies of multiple patients. The present study was aimed at evaluating the safety of REPLICA in a

cohort of patients with different mandibular defects contraindicating the use of traditional surgical techniques.

Patients and methods

Study design

The REPLICA cohort study was performed at the Unit of Maxillofacial Surgery of Padova University (Italy) between March 2012 and June 2017. The study was approved by the local Ethical Committee of the University Hospital of Padova (protocol number 24435-AOP 1814, April 2019) and all patients gave their written informed consent.

Patients

The inclusion criteria were: 1) age \geq 18 years; 2) need of primary or secondary reconstruction of mandibular continuity defects (all sizes, all sites); 3) presence of local or systemic contraindications to mandibular reconstruction with vascularized bone or standard reconstruction plates, including local anatomical conditions precluding the use of bridging reconstruction plates (mandible defect involving the condylar unit and/or exceeding the midline), donor-site contraindications to the harvest of microvascular bone flaps (i.e. peripheral arterial occlusive disease or vascular anomalies) and medical conditions that could adversely affect postoperative morbidity and mortality (Appendix 1); 4) score \leq 3 at the physical status classification system of the American Society of Anesthesiologists; 5) expected survival rate \geq 1 year according to the Karnofsky Performance Scale (corresponding to a score \geq 60).

Data collection and variables

The following variables were collected using a case report form: 1) age; 2) sex; 3) diagnosis; 4) side, size, and type of mandibular defect [27]; 5) history of previous mandibular surgery; 6) history of previous radiation therapy of the head and neck; 7) Karnofsky score; 8) oral pain as detected by a visual analogue scale (VAS) ranging from 0 (none) to 10 (unbearable) by steps of 1; 9) findings at visual inspection of oral mucosa and cervico-facial skin; 11) mouth opening (mm); 12) lip competence; 13) symmetry of

facial contour; 14) need of adjunctive surgical procedures involving soft tissues. Digital photographs (EOS 5D Mark IV, Canon, US) were performed to record lip competence and appearance. All patients underwent fine-cut (1-mm) multidetector-computed tomography (MDCT) scans of the head and neck (Lightspeed VCT LS Advantage 64 slices, General Electric, US) to reach a conclusive diagnosis of the type and size of the mandibular defect [27].

Virtual surgical planning and computer-aided mandibular design and fabrication

We developed a workflow together with engineers proficient in CAD/CAM design of personalized implantable devices (Sintac S.r.l. Biomedical Engineering, Trento, Italy). Digital imaging and communications in medicine protocol (DICOM) data obtained from preoperative MDCT scans were imported into the Mimics Innovation Suite software (version 19 and updates, Materialise, Belgium), which provided a virtual 3D model of the facial skeleton. The planning of mandibular resection was started by the surgeon on a web conference, with the selection of safe bone margins on the basis of the underlying disease and the quantity and quality of bone at the remaining mandibular stumps. The design of REPLICA was performed considering the original shape of the mandible whenever possible, using Geomagic Freeform Plus software with Phantom Desktop Haptic device version 2016 (3D Systems Inc., US). REPLICA was designed to resemble the outer surface of the mandibular defect and to be symmetric to the contralateral side. When mandibular anatomy was grossly altered by disease (H and L defects) [27], we used mirroring of the contralateral healthy side to simulate the reconstruction of the defect. For any defect involving the anterior mandible (LC or HC) and for any bilateral mandibular defect (LCL or HCL), the size and shape of the mandibular implant were chosen from a digital image library, in accordance with the facial proportions of the patient. When secondary reconstruction was needed, MDCT scans of the native mandible were used to virtually plan the surgical intervention. The standard maximum height of the anatomical area of each REPLICA was devised using digital data to minimize the risk of extrusion (25 mm for the symphysis, 20 mm for the body, and 25 mm for the bisector of the mandibular angle). REPLICA was fabricated with 2.2-mm thick titanium, smooth borders, and with the minimum thickness at the level of the bone-implant contact. For H defects, the condylar unit was designed and fabricated with a 10% reduction of its original volume. This was done for both natural and mirrored condyles to prevent temporomandibular dysfunction. The coronoid process was never included in the device. Retention titanium structures were positioned on each end-plate surface to increase the stability of the system. At least three screw-holes were designed for each REPLICA to allow stable bicortical screw-fixation at the remaining bone stumps. The final position of each screw-hole was selected on the basis of the quality

and quantity of bone at each stump, irrespective of the geometry of the end-plate. Screw-holes were kept at a minimum distance of 5 mm from each other, from the inferior/lateral cortical rim, and from the resection margins. The length of each screw-hole was recorded. The system was fully bridging, with the titanium device responsible for the entire masticatory load [12]. In detail, REPLICA was designed with separate grids to allow the attachment of muscles and tendons. Lateral grids were positioned at the level of the original insertion of the mylo-hyoid muscle and anterior grids at the level of the mentalis muscle and of the anterior belly of the digastric muscle. A 3D construct resembling the original shape and volume of the mental spine was added to allow the reinsertion of the genioglossus and geniohyoid muscles. At the level of the mandibular body, the device had a rough surface to promote the adhesion of soft-tissues (Figs. 1, 2, 3, 4, Supplementary figure 1 and Supplementary figure 2).

The components of REPLICA were built up additively in fine-powder layers of titanium alloy (EOS Titanium Ti6AlV4) using a M280 EOS DMLS laser-sintering machine (Electro Optical Systems GmbH, Germany). The cutting guides were also printed in polyamide using the SLS FORMIGA P110 system (Electro-Optical Systems GmbH, Germany). The implants and the cutting guides were provided in labeled packages together with the made-to-order conformity certificate. Autoclave sterilization at 132°-135 °C for 60 min was used, as recommended by the producer (Sintac srl) for both implantable titanium device (Replica) and non-implantable parts (surgical guides).

Surgery

All interventions were performed under general anesthesia. For primary reconstruction, segmental resection of the mandible was performed using a combined cervical and intraoral approach. Press-fit cutting guides were inserted without the need of screw stabilization. A single screw was added in the presence of difficult anatomical conditions. The holes for screw stabilization were produced first and osteotomies thereafter (Fig. 2).

Careful dissection of the suprahyoid and mentalis muscles was performed to allow their positioning onto REPLICA, except for malignancies, where radical resection included the surrounding soft-tissue. REPLICA was then inserted to cover the bone gap and fixed to the remaining bone stumps with standard non-locking bicortical screws using the previously produced holes (MatrixMANDIBLE Recon Screw, Synthes GmbH, Switzerland) (Fig. 3).

Additional surgical procedures were performed depending on the patient and disease. A stable tension-free coverage of REPLICA was obtained with local or distant soft-tissue flaps, as determined preoperatively. Mouth opening, mandibular range of movements, and occlusion stability were evaluated before the closure of soft tissues and the insertion of drainage.

Perioperative follow-up

All patients were given a 10-day cycle of intravenous Sulbactam-Amoxicillin 1.5 g t.i.d. and Metronidazole 500 mg t.i.d starting from the day of surgery. Patients with known allergy to penicillin were given ciprofloxacin 500 mg b.i.d. for 10 days. Temporary tracheotomy and intensive care surveillance were given to patients undergoing major ablative surgery, as per standard practice at our Unit. Patients undergoing mandibular resection alone were fed a soft diet starting from the first postoperative day. In cancer patients requiring additional reconstructive procedures, oral feeding was delayed until soft-tissue closure.

Postoperative follow-up

Patients were seen at 1-month and then at 3-month intervals up to 1 year. We recorded the following variables during hospital stay and at each follow-up visit: 1) need of enteral feeding (nasogastric tube); 2) time to resumption of oral feeding; 3) oral pain (VAS scale); 4) mouth opening (mm); 5) presence of occlusion; 6) mandibular range of motion; 7) symmetry of facial contour; 8) lip competence; 9) postoperative complications; 10) length of stay (LOS). Soft tissues were inspected for signs of infection (sinus track, abscess, purulent discharge) and extrusion of REPLICA. A fine-cut MDCT was performed postoperatively and every 3 months up to 1 year. At the 6-month follow-up, all patients completed the EORTC QLQ-C30 and the H&N35 questionnaires. EORTC QLQ-C30 comprises 30 questions assessing global quality of life (QOL) [28] and QLQ-H&N35 comprises 35 QOL questions specific for head and neck patients [29].

Primary outcome

The primary outcome of the study was composite and was intended to quantify the 1-year safety of REPLICA. The primary outcome was assigned if all the following conditions were met: 1) absence of intraoral or skin extrusion of REPLICA; 2) decrease or cessation of oral pain as compared to baseline; 3) stability or increase in mouth opening (mm); 4) resumption of oral feeding without the need of nasogastric tube; 5) absence of fracture at MDCT; 6) absence of displacement at MDCT; 7) absence of screw loosening at MDCT.

Secondary outcome

The secondary outcome was the patient-reported QOL at 6 months from the surgical intervention as detected by the EORTC QLQ-C30 and QLQ-H&N35 questionnaires.

EORTC QLQ-C30 measures comprise a substantial number of scales with scores being calculated from a single item or multiple items. All scales are scored on a metric from 0 to 100 by adding the individual items and transforming them linearly. Within the EORTC framework, there is a distinction between functioning scales and symptom scales. The core instrument was used in tandem with the head and neck module (QLQ-H&N35), a 35-item questionnaire that assesses symptoms encountered specifically by patients with head and neck cancer. This measure generates 7 multiple-item scales (Pain, Swallowing, Senses, Speech, Social eating, Social contact, and Sexuality), in addition to 11 single items (eg, Opening mouth, Sticky saliva, Dry mouth, etc). All EORTC scales and single items are scored and linearly transformed to scales of 0 to 100. The functional scales are reversed scored, so that higher scores indicate better functioning. Conversely, higher scores on the symptom scales and individual items indicate greater impairment.

Statistical analysis

Descriptive statistics were calculated on a per-patient basis. Continuous variables are reported as median (50th percentile) and interquartile range (IQR, 25th and 75th percentile). Categorical variables are given as the number or percentage of patients with the characteristic of interest. Statistical analysis was performed using Stata 16.1 (Stata Corporation, College Station, TX, USA).

Results

Preoperative features of the patients

Between March 2012 and June 2017, 18 consecutive patients underwent reconstruction of mandibular defects with REPLICA at our Unit. Their baseline features are given in Table 1.

The patients were 9 men and 9 women with a median (IQR) age of 67 (65;74) years. Medication-related osteonecrosis of the jaw was the most frequent diagnosis (n = 10), followed by squamous cell carcinoma of the oral cavity (n = 2) and osteoradionecrosis (n = 2).

Surgery

REPLICA was applied to all patients in accordance with the virtual surgical plan. Condylar unit alloplastic substitution was performed in 14 patients, 4 of whom had a continuity bone defect involving the anterior mandible (HC), while the defect involved the lateral mandible (H) in the remaining 10 patients. The remaining 4 REPLICA were inserted to repair lateral mandibular defects (L), which extended to the central area in 2 cases (LC, LCL). Temporary tracheotomy was performed in 4 patients, 3 of whom underwent ablative surgery for cancer-related disease. 4 patients required immediate soft-tissue coverage of REPLICA with a soft-tissue free-flap, and 6 needed cancer-related adjunctive surgery. The median (IQR) operative time was 308 (230;400) minutes, with the shortest value of 141 min for a case of isolated mandibular reconstruction (Table 2).

Perioperative follow-up

The median (IQR) time to the resumption of oral feeding was 2 (1;8) days and the median (IQR) LOS was 10 (5;20) days. 2 patients had perioperative systemic complications (Table 2). The first patient died 4 days after surgery because of acute respiratory distress due to bilateral pneumothorax; the second patient developed acute limb ischemia and partial flap necrosis with oral extrusion of the REPLICA two days after surgery and underwent surgical repair with a temporal flap.

Postoperative follow-up

2 patients had mucosal wound dehiscence successfully treated with direct soft-tissue closure under local anesthesia. Extrusion of REPLICA occurred in 2 patients. The first patient was a 65-year-old woman with metastatic breast cancer who developed mucosal exposure of the device, which did not heal after two subsequent salvage surgeries; the second patient was a 75-year-old man who had a grade III chin burn with progressive skin loss. Both patients underwent implant removal and direct soft-tissue closure (at 4 and 6 months). Lastly, 1 patient with oral cancer died 11 months after surgery because of chemotherapy-induced acute myeloid leukemia.

Primary outcome

The primary outcome was reached by 14 of the 18 patients. All patients showed better profiles of oral pain over time and all but one had no pain at the 1-yr follow-up. Among the patients with follow-up data, mouth opening improved in 10 and remained stable in 4 patients (Fig. 4).

No signs of device fracture or displacement and screw loosening were detected at MDCT at the 1-yr follow-up. (Appendix 2: panel A, panel B)

Secondary outcome

EORTC QLQ-C30 and H&N35 data were available for 15 out of 18 patients at the 6-month follow-up (Table 3). These data show a good profile of QOL for the treated patients.

Discussion

In the present study, performed in a cohort of patients in whom standard reconstructive procedures could not be employed, we assessed the safety and the patient-reported QOL of REPLICA, a patient-specific implant designed with CAD/CAM. REPLICA offered a

safe solution for the treatment of mandibular defects and the rehabilitation of masticatory function at 1 year, and was associated with subjective well-being and satisfaction.

The main limitation of the present study is the lack of a control group treated with standard reconstruction techniques, i.e. microvascular bone transfers or reconstruction plates. This is, however, largely due to the fact that we studied patients with worst-case scenario disease not suitable for standard reconstructions.

A second limitation is the unavailability of QOL data, except at the 6-month follow-up. We are currently performing QOL assessments preoperatively and at 6-month follow-up in all patients treated with REPLICA and we plan to report on these data extensively in the near future. A third limitation is that REPLICA is presently lacking the ability to allow dental rehabilitation, contrarily to bone-flap transfers. On the other hand, REPLICA was devised mostly for patients who cannot achieve dental rehabilitation in one time because of the current lack of alternatives to repeated and challenging interventions.

REPLICA was designed with four aims in mind: 1) to restore mandibular continuity and give structural support to the face; 2) to support oral soft tissues for functional and esthetic issues; 3) to distribute mass and constraints using known reconstruction principles for bridging defects; 4) to connect muscles supporting the oral floor and the lower lip on the basis of the patient's chewing, speech, and swallowing needs. The customization of REPLICA allowed to adapt it precisely to the remaining bone stumps and extended its applicability as compared to traditional reconstruction plates. The precise fitting of REPLICA allowed an immediate and stable fixation to the remaining condylar stumps with an optimal bone-implant contact. This is especially important when ablative surgery leaves an insufficient bone surface at the condylar neck for the 3-screw fixation, which impedes the use of traditional plates without the loss of the condylar unit and the recourse to immediate alloplastic reconstruction. The customization of REPLICA allowed also the optimization of the maximum bone surface and of the number of screw-holes for fixation. The stability of the system was further increased by including bone-anchoring titanium structures at each device-bone interface.

REPLICA was designed to restore any type and size of segmental mandibular bone defect. Its form and dimensions were planned to replicate those of the native mandible, providing support to the over-lying soft tissues. This is especially important for mandibular defects extending to the anterior area of the mandible, where support of the

lower lip is crucial to avoid lip incompetence and drooling, conditions common with traditional reconstruction plates. As expected, the fact that REPLICA provided soft-tissue support, contributed to a good esthetic outcome. Also mirroring, i.e. the digital imposition of the healthy site during CAD/CAM to provide a symmetrical projection of the reconstructed side, was central to reach such outcome.

Contrarily to what happens with standard reconstruction plates [11], we did not observe fractures or dislocations of REPLICA during 1 year of follow-up. It was indeed expected that a personalized mandible-like device, filling properly the bone gap, would ensure a lower failure rate as compared to standard reconstructive plates, which frequently undergo overbending and dislocation [10]. Despite the low number of extrusions observed in our study, it is likely that infection will remain the most critical variable influencing the long-term outcome. The risk of infection and extrusion was, however, minimized by the choice of specific requirements for REPLICA. First, the height of the posterior and central aspects of REPLICA was adjusted with empirical reduction to achieve tension-free soft-tissue coverage. Second, REPLICA was designed with blunt borders to reduce the traumatism of the overlying oral mucosa. Third, the reinsertion of the muscles of the tongue and mouth floor to the prefabricated grids of REPLICA prevented dead-space formation after tissue dissection, which predisposes to infection and soft-tissue dehiscence. Lastly, REPLICA was manufactured in titanium, because of its bio-compatibility, resistance to corrosion, low specific weight, and well-known biomechanical properties [31].

The operative time was influenced mostly by the need to perform surgical procedures in addition to mandibular reconstruction. As exclusive bone reconstruction is concerned, the CAD-CAM technique has an operative time similar to that required for the insertion of standard plates and lower than that reported for microvascular bone [15]. The suspension of the suprahyoid muscles was expected to prevent the backward protrusion of the tongue, making temporary tracheotomy unnecessary in the presence of an isolated bone defect. In fact, most of the patients requiring temporary tracheotomy were undergoing cancer-related surgical procedures in addition to mandibular reconstruction. Most patients had a recovery of mastication and deglutition in the first postoperative day, irrespective of the site and size of the original defect. LOS was associated mainly with the number and difficulty of surgical procedures and its median value is comparable to that of traditional reconstructive techniques.

In this study, cancer patients who underwent adjuvant chemo and RT treatments after Replica surgery did well at 1-year. Yet, we cannot conclude whether Replica can be

safely exposed to RT treatment after Head and Neck cancer surgery owing to the limited number of patients studied.

At present, we believe that patients previously exposed to radiation treatment, and osteoradionecrosis patients in particular, are poor candidates to mandible reconstruction with REPLICA because radiation-induced soft-tissue damage can put the device at risk of infection and extrusion.

REPLICA provided pain relief over time and improved mouth opening. High QOL scores were observed for the functional, physical, and emotional domains of QLQ-C30. In most patients, the health status was not influenced by surgery and only minimal complaints were re-reported at the reconstructed site. These results are comparable to those obtained with fibula flaps, except for the higher social functioning of patients undergoing final dental rehabilitation with the latter [2,32,33].

We also observed high QOL scores for speech, chewing and swallowing at H&N35, which is important owing to the fact that they are the most important determinants of QOL after mandible reconstruction [16,34].

Conclusion

In conclusion, REPLICA, a patient-specific CAD/CAM designed titanium device, offers a safe and well-tolerated alternative to traditional microsurgical techniques and plating systems for mandibular reconstruction in patients with critical mandibular anatomy. Further studies are needed to assess the full range of indications of REPLICA as well as to test whether an upgraded version of it can provide the restoration of dental functioning.

Funding source

The authors The authors received no specific funding for this work.

Declaration of Competing Interest

Alberto Bedogni was supported by a research grant from Sintac s.r.l.
(BEDO_COMM17_01: December 2017 - December 2019).

The remaining authors have nothing to disclose.

Acknowledgements

We dedicate the present paper to the memory of Professor Giuseppe Ferronato, M.D., D.M.D., expert maxillofacial surgeon and great teacher, who passed away before the end of the study.

References

- [1] Murphy BA, Ridner S, Wells N, Dietrich M. Quality of life research in head and neck cancer: A review of the current state of the science. *Crit Rev Oncol/Hematol* 2007; 62(3):251–67.
- [2] Yang W, Zhao S, Liu F, Sun M. Health-related quality of life after mandibular resection for oral cancer: Reconstruction with free fibula flap. *Med Oral* 2014: e414–8. <https://doi.org/10.4317/medoral.19399>.
- [3] Cannon TY, Strub GM, Yawn RJ, Day TA. Oromandibular reconstruction. *Clin Anat* 2012;25:108–19.
- [4] Brown JS, Lowe D, Kanatas A, Schache A. Mandibular reconstruction with vascularised bone flaps: a systematic review over 25 years. *Br J Oral Maxillofac Surg* 2017;55(2):113–26.
- [5] Kakarala K, Shnayder Y, Tsue TT, Girod DA. Mandibular reconstruction. *Oral Oncol* 2018;77:111–7.
- [6] Barry CP, Brown J, Hanlon R, Shaw R. Tailored approach to oromandibular reconstruction in patients with compromised lower limb vessels: Tailored approach to oromandibular reconstruction. *Head Neck* 2017;39(5):916–20.
- [7] Cordeiro PG. Classification System for Mandibulectomy Defects Atlas of Mandibular and Maxillary Reconstruction with the Fibula Flap: A step-by-step approach. In: De Santis G, Cordeiro PG, Chiarini L, editors. *Atlas of Mandibular and Maxillary*

Reconstruction with the Fibula Flap: A step-by-step approach. Cham: Springer International Publishing; 2019. p. 3–5. https://doi.org/10.1007/978-3-030-10684-3_1.

[8] Pare´ A, Bossard A, Laure B, Weiss P, Gauthier O, Corre P. Reconstruction of segmental mandibular defects: Current procedures and perspectives. *Laryngoscope Invest Otolaryngol* 2019;4(6):587–96.

[9] Maurer P, Eckert AW, Kriwalsky MS, Schubert J. Scope and limitations of methods of mandibular reconstruction: a long-term follow-up. *Br J Oral Maxillofac Surg* 2010;48(2):100–4.

[10] Martola M, Lindqvist C, Ha¨nninen H, Al-Sukhun J. Fracture of titanium plates used for mandibular reconstruction following ablative tumor surgery. *J Biomed Mater Res* 2007;80B(2):345–52.

[11] Shibahara T, Noma H, Furuya Y, Takaki R. Fracture of mandibular reconstruction plates used after tumor resection. *J Oral Maxillofac Surg* 2002;60(2):182–5.

[12] Schupp W, Arzdorf M, Linke B, Gutwald R. Biomechanical Testing of Different Osteosynthesis Systems for Segmental Resection of the Mandible. *J Oral Maxillofac Surg* 2007;65(5):924–30.

[13] Probst FA, Mast G, Ermer M, Gutwald R, Schmelzeisen R, Pautke C, Otto S, Schiel S, Ehrenfeld M, Cornelius C-P, Metzger MC. MatrixMANDIBLE Preformed Reconstruction Plates—A Two-Year Two-Institution Experience in 71 Patients. *J Oral Maxillofac Surg* 2012;70(11):e657–66.

[14] Rodby KA, Turin S, Jacobs RJ, Cruz JF, Hassid VJ, Kolokythas A, Antony AK. Advances in oncologic head and neck reconstruction: Systematic review and future considerations of virtual surgical planning and computer aided design/computer aided modeling. *J Plastic, Reconstruct Aesthet Surg* 2014;67(9):1171–85.

[15] Toto JM, Chang EI, Agag R, Devarajan K, Patel SA, Topham NS. Improved operative efficiency of free fibula flap mandible reconstruction with patient-specific, computer-guided preoperative planning: Preoperative modeling for free fibula flaps. *Head Neck* 2015;37(11):1660–4.

[16] Wang YY, Zhang HQ, Fan S, Zhang DM, Huang ZQ, Chen WL, Ye JT, Li JS. Mandibular reconstruction with the vascularized fibula flap: comparison of virtual planning surgery and conventional surgery. *Int J Oral Maxillofac Surg* 2016;45 (11):1400–5.

[17] Ciocca L, Mazzoni S, Fantini M, Marchetti C, Scotti R. The Design and Rapid Prototyping of Surgical Guides and Bone Plates to Support Iliac Free Flaps for Mandible Reconstruction: *Plast Reconstr Surg* 2012;129(5):859e–61e.

- [18] Foley BD, Thayer WP, Honeybrook A, McKenna S, Press S. Mandibular Reconstruction Using Computer-Aided Design and Computer-Aided Manufacturing: An Analysis of Surgical Results. *J Oral Maxillofac Surg* 2013;71(2): e111–9.
- [19] Mascha F, Winter K, Pietzka S, Heufelder M, Schramm A, Wilde F. Accuracy of computer-assisted mandibular reconstructions using patient-specific implants in combination with CAD/CAM fabricated transfer keys. *J Cranio-Maxillofac Surg* 2017;45(11):1884–97.
- [20] Tarsitano A, Battaglia S, Ricotta F, Bortolani B, Cercenelli L, Marcelli E, Cipriani R, Marchetti C. Accuracy of CAD/CAM mandibular reconstruction: A three-dimensional, fully virtual outcome evaluation method. *J Cranio-Maxillofac Surg* 2018;46(7):1121–5.
- [21] Lee Y-W, You H-J, Jung J-A, Kim D-W. Mandibular reconstruction using customized three-dimensional titanium implant. *Arch Craniofac Surg* 2018;19(2): 152–6.
- [22] Jo Y-Y, Kim S-G, Kim M-K, Shin S-H, Ahn J, Seok H. Mandibular Reconstruction Using a Customized Three-Dimensional Titanium Implant Applied on the Lingual Surface of the Mandible. *J Craniofac Surg* 2018;29(2):415–9.
- [23] Fernandes N, van den Heever J, Hoek K, Booyesen G. Customized reconstruction of an extensive mandibular defect: A clinical report. *J Prosthet Dent* 2016;116(6): 928–31.
- [24] Qassemayr Q, Assouly N, Temam S, Kolb F. Use of a three-dimensional custom-made porous titanium prosthesis for mandibular body reconstruction. *Int J Oral Maxillofac Surg* 2017;46(10):1248–51.
- [25] U V, Mehrotra D, Howlader D, Singh PK, Gupta S. Patient Specific Three-Dimensional Implant for Reconstruction of Complex Mandibular Defect. *J Craniofac Surg* 2019;30(4):e308–11.
- [26] Bedogni A, Bettini G, Ferronato G, Fusetti S, Saia G. Replacement of fractured reconstruction plate with customized mandible implant: A novel technique: Customized Plate for Mandible Reconstruction. *The Laryngoscope* 2014;124(2): 401–4.
- [27] Boyd JB, Gullane PJ, Rotstein LE, Brown DH, Irish JC. Classification of mandibular defects. *Plast Reconstr Surg* 1993;92:1266–75.
- [28] Fayers P, Aaronson N, Bjordal K, Groenvold M, Curran D, Bottomley A. EORTC QLQ-C30 Scoring Manual (ed 3). Brussels: Belgium; 2001.
- [29] Heutte N, Plisson L, Lange M, Prevost V, Babin E. Quality of life tools in head and neck oncology. *Eur Ann Otorhinolaryngol, Head Neck Dis* 2014;131(1):33–47.

- [31] Trevisan F, Calignano F, Aversa A, Marchese G, Lombardi M, Biamino S, Ugues D, Manfredi D. Additive manufacturing of titanium alloys in the biomedical field: processes, properties and applications. *J Appl Biomater Funct Mater* 2018;16(2): 57–67.
- [32] Li X, Zhu K, Liu F, Li H. Assessment of quality of life in giant ameloblastoma adolescent patients who have had mandible defects reconstructed with a free fibula flap. *World J Surg Onc* 2014;12(1):201. <https://doi.org/10.1186/1477-7819-12-201>.
- [33] Hundepool AC, Dumans AG, Hofer SOP, Fokkens NJW, Rayat SS, van der Meij EH, Schepman KP. Rehabilitation after mandibular reconstruction with fibula free-flap: clinical outcome and quality of life assessment. *Int J Oral Maxillofac Surg* 2008;37(11):1009–13.
- [34] Rogers SN, Devine J, Lowe D, Shokar P, Brown JS, Vaugman ED. Longitudinal health-related quality of life after mandibular resection for oral cancer: a comparison between rim and segment. *Head Neck* 2004;26(1):54–62.

FIGURE LEGENDS

Fig. 1. Computer-aided design of REPLICA.

Panel A: 3D virtual model of the native mandible with the titanium patient-specific device designed to bridge a right HC bone defect after the simulation of bone resection. REPLICA is designed to resemble the outer surface of the native mandible with blunt borders (white arrows) and a tailored reduction in height at the level of the retromolar area and symphysis to allow stable soft-tissue coverage. The rough outer surface (black arrow) promotes soft tissue adhesion. Multiple linear grids are designed for the connection of the mylohyoid muscles laterally (white arrowhead), the mentalis (black arrowhead) and digastric muscles anteriorly (black arrow right). The inferior grid on the lateral aspect of REPLICA provides soft-tissue free flap suspension for reconstructive purpose (white arrow up). Three to four screw-holes are designed at a minimum distance of 5-mm each other to allow bicortical screw-fixation to the remaining mandibular stumps (asterisk).

Panel B: Bottom-up view of REPLICA CAD design shows the titanium construct resembling the volume and shape of the original mental spine (white arrowhead) for the attachment of the genioglossus and geniohyoid muscles. Retention structures are outlined, which increase mechanical stability of Replica at the titanium-bone interface (black arrow left).

Fig. 2. Mandibular reconstruction. Panel A: Intraoperative view of the bone cutting guide placed at the planned margin of resection in a left HC defect. Panel B: Insertion of REPLICA in the bone gap with placement of the condylar unit in the glenoid fossa.

Fig. 3. Oral floor reconstruction and mentalis muscle reinsertion.

Panel A: Dissection of the genioglossus (black arrows), geniohyoid (white arrows) and of the anterior belly of the digastric muscle (black arrowheads) after right mandibulectomy extending over the central area and before the insertion of REPLICA.

Panel B: Screw fixation of REPLICA and muscle reinsertion with non-absorbable 2/0 sutures to the inner side of the device (anterior belly of digastric muscles, black arrowheads).

Panel C: Suspension sutures of two-sided mentalis muscle after dissection for their reinsertion on the implant (inner side).

<i>Baseline features</i>	
Sex	
Women	9 (50%)
Men	9 (50%)
Age (years)	67 (65; 74)
Main disease	
Ameloblastoma	1 (6%)
Ameloblastoma - recurrence	1 (6%)
Medication-related osteonecrosis of the jaw	10 (56%)
None	1 (6%)
Ossifying Fibroma (previous)	1 (6%)
Osteoradionecrosis	2 (11%)
Squamous cell cancer of oral cavity	2 (11%)
Secondary disease	
Chronic osteomyelitis	1 (6%)
Chronic radiodermatitis	2 (11%)
Mandible fracture	4 (22%)
None	7 (39%)
Plate failure	3 (17%)
Plate failure and mandible fracture	1 (6%)
Underlying disease	
Breast Cancer	5 (28%)
Multiple myeloma	3 (17%)
None	7 (39%)
Prostate Cancer	1 (6%)
Rheumatoid Arthritis	1 (6%)
Tongue cancer (previous)	1 (6%)
Mandibular defect (Boyd)	
HC left	2 (11%)
HC right	1 (6%)
HCL right	1 (6%)
H left	7 (39%)
H right	3 (17%)
L left	1 (6%)
L right	1 (6%)
L.C right	1 (6%)
LCL	1 (6%)
ASA score	
1	1 (6%)
2	4 (22%)
3	13 (72%)
Karnofsky score \geq 60	18 (100%)
Previous surgery	9 (50%)
Previous radiotherapy	3 (17%)
VAS	3 (0; 6)
<i>Preoperative features</i>	
Bone exposure	9 (50%)
Infection	10 (56%)
Mucosal involvement	13 (72%)
Extra-oral fistula	7 (39%)
Mouth opening (mm)	30 (25; 35)
Facial symmetry	4 (22%)
Lip competence	16 (89%)
<i>Comorbidities</i>	
Type 2 diabetes mellitus	2 (11%)
Hypertension	11 (61%)
Coronary artery disease	2 (11%)
Dyslipidemia	1 (6%)
HBV infection	2 (11%)
HCV infection	1 (6%)
Cardiac rhythm disorder	2 (11%)
Hashimoto thyroiditis	1 (6%)
Psoriatic arthritis	1 (6%)
Peripheral artery occlusive disease	2 (11%)
Sinusitis	1 (6%)
Valve prolapse	1 (6%)
Obesity	1 (6%)
Chronic kidney disease	1 (6%)

Continuous variables are reported as median and interquartile range (IQR) and discrete variables are reported as the number and proportion of patients with the characteristic of interest.

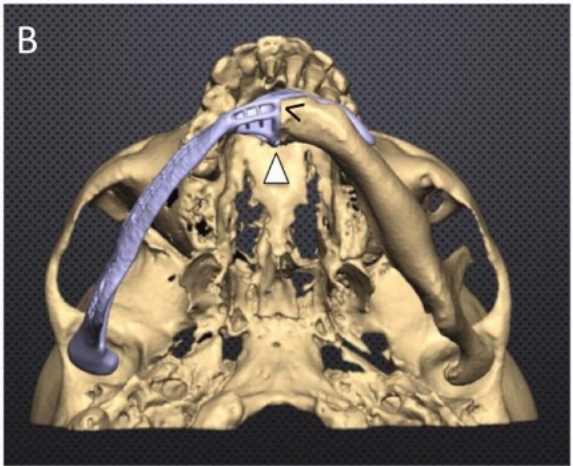
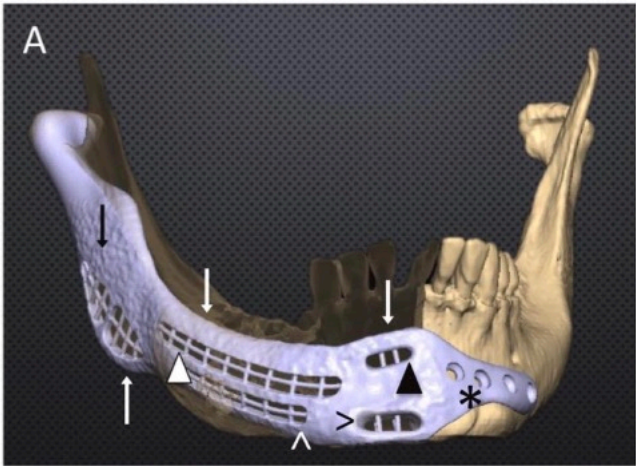
Duration of surgery (minutes)	308 (230; 400)
Tracheotomy	4 (22%)
<i>Adjunctive surgery</i>	
Bilateral deep inferior epigastric perforator flap for cheek and neck reconstruction	1 (6%)
None	8 (44%)
Plate removal, left mandibular resection, and condylar disarticulation	1 (6%)
Right radial free forearm flap for soft-tissue reconstruction	1 (6%)
Tooth extraction	4 (22%)
Tumor resection	1 (6%)
Tumor resection and lateral circumflex femoral artery perforator flap for cheek reconstruction	1 (6%)
Tumor resection, neck dissection, and lateral circumflex femoral artery perforator flap for cheek reconstruction	1 (6%)
Nasogastric tube	6 (33%)
Resumption of oral feeding (days)	2 (1; 8)
Length of stay (days)	10 (5; 20)
<i>Systemic complications</i>	
Acute respiratory distress syndrome (with death on 4th post-op day)	1 (6%)
Acute limb ischemia	1 (6%)
None	16 (89%)
<i>Local complications</i>	
Mucosal dehiscence (surgery performed again)	1 (6%)
Mucosal dehiscence and seroma (surgery performed again)	1 (6%)
None	13 (72%)
Partial flap necrosis (salvage surgery with temporalis muscle flap)	1 (6%)
Postoperative edema	1 (6%)
Submental skin burns (9 post-op day)	1 (6%)
<i>Adjuvant treatments</i>	
Radiotherapy	2 (11%)
Chemotherapy	2 (11%)

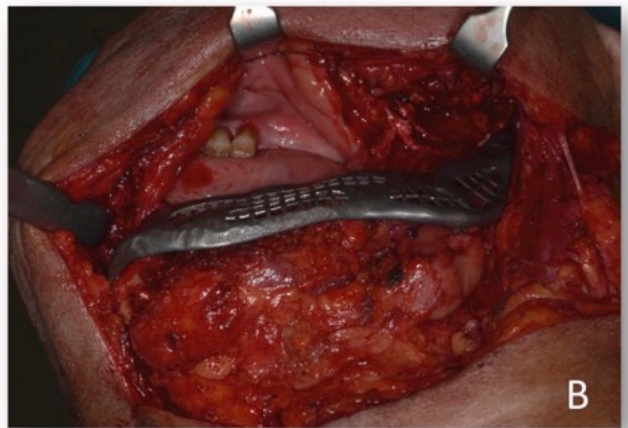
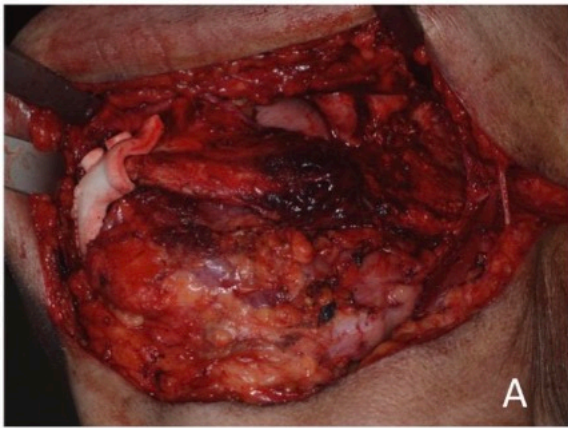
Continuous variables are reported as median and interquartile range (IQR) and discrete variables are reported as the number and proportion of patients with the characteristic of interest.

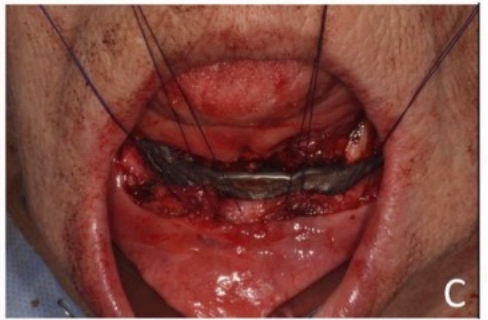
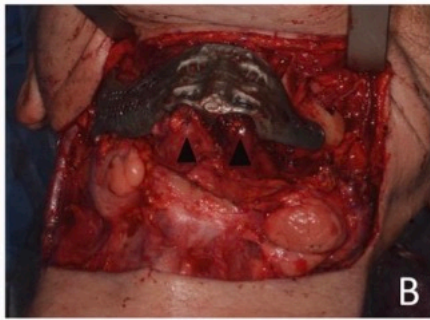
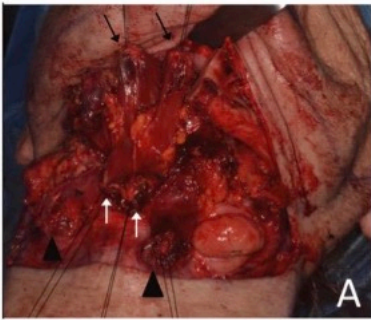
	N = 15
Global health status/QOL	75 (42; 83)
PF2 - Physical functioning	93 (73; 100)
RF2 - Role functioning	100 (67; 100)
EF - Emotional functioning	92 (75; 92)
CF - Cognitive functioning	100 (83; 100)
SF - Social functioning	83 (83; 100)
FA - Fatigue	0 (0; 44)
NV - Nausea and vomiting	0 (0; 0)
PA - Pain	0 (0; 33)
DY - Dyspnea	0 (0; 33)
SL - Insomnia	0 (0; 33)
AP - appetite loss	0 (0; 0)
CO - Constipation	0 (0; 33)
DI - Diarrhea	0 (0; 0)
FI - Financial difficulties	0 (0; 33)
HNSA - Pain	8 (0; 17)
HNSW - Swallowing	8 (0; 17)
HNSE - Senses problems	0 (0; 17)
HNSP - Speech problems	11 (0; 22)
HNSO - Trouble with social eating	17 (0; 33)
HNSC - Trouble with social contact	13 (0; 27)
HNSX - Less sexuality	0 (0; 33)
HNTE - Teeth	0 (0; 33)
HNOM - Opening mouth	33 (0; 33)
HNDR - Dry mouth	0 (0; 33)
HNSS - Sticky saliva	0 (0; 33)
HNCO - Coughing	0 (0; 0)
HNFI - Felt ill	0 (0; 0)
HNPB - Pain killers	0 (0; 100)
HNNU - Nutritional supplements	0 (0; 100)
HNFE - Feeding tube	0 (0; 0)
HNWL - Weight loss	0 (0; 0)
HNWG - Weight gain	0 (0; 0)

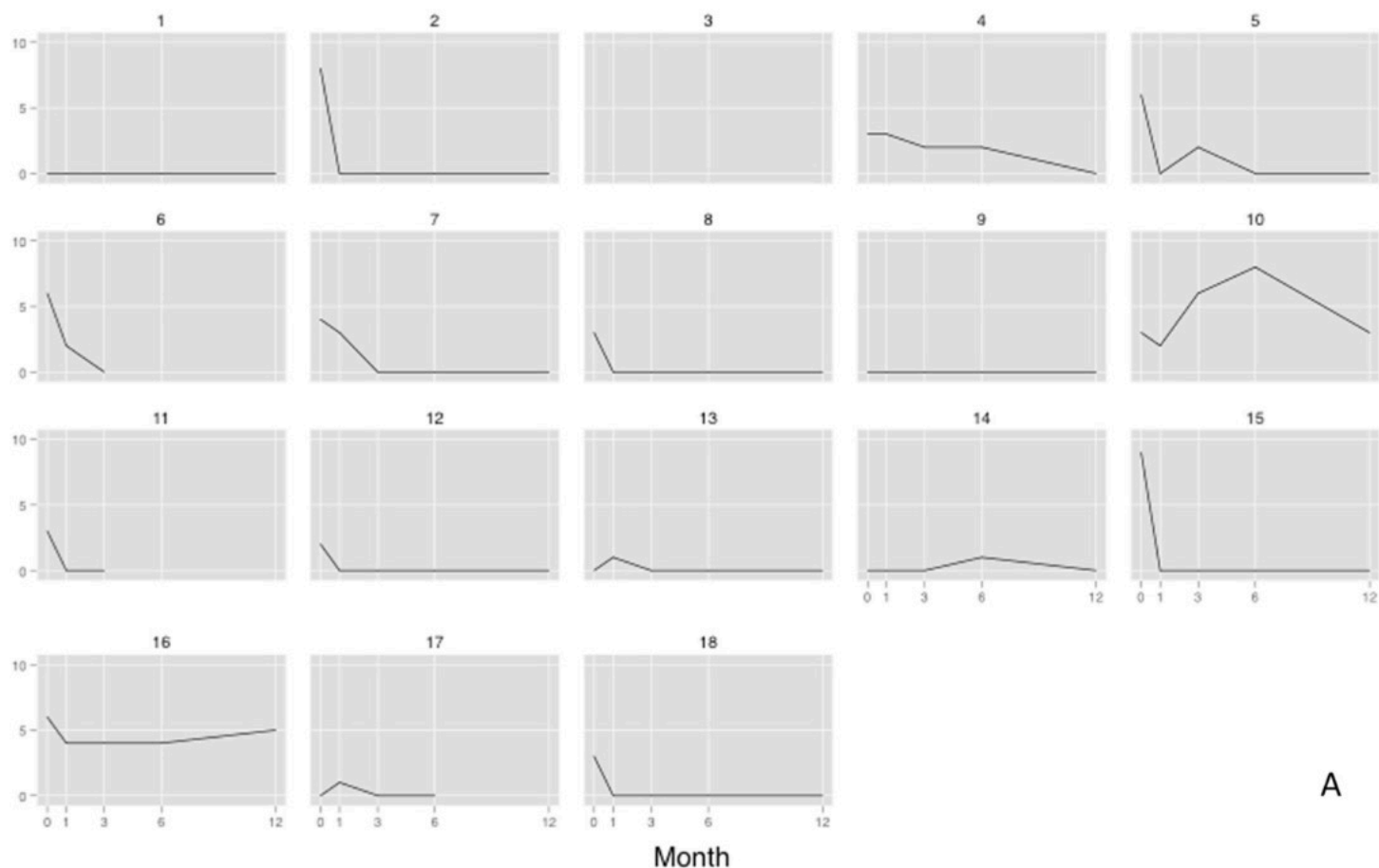
Values of the entire patient cohort are reported as median and IQR.

All of the scales range in score from 0 to 100. A high score for a functional scale represents a high/healthy level of functioning, whereas a high score for a symptom scale or single item represents a high level of symptomatology or problems.



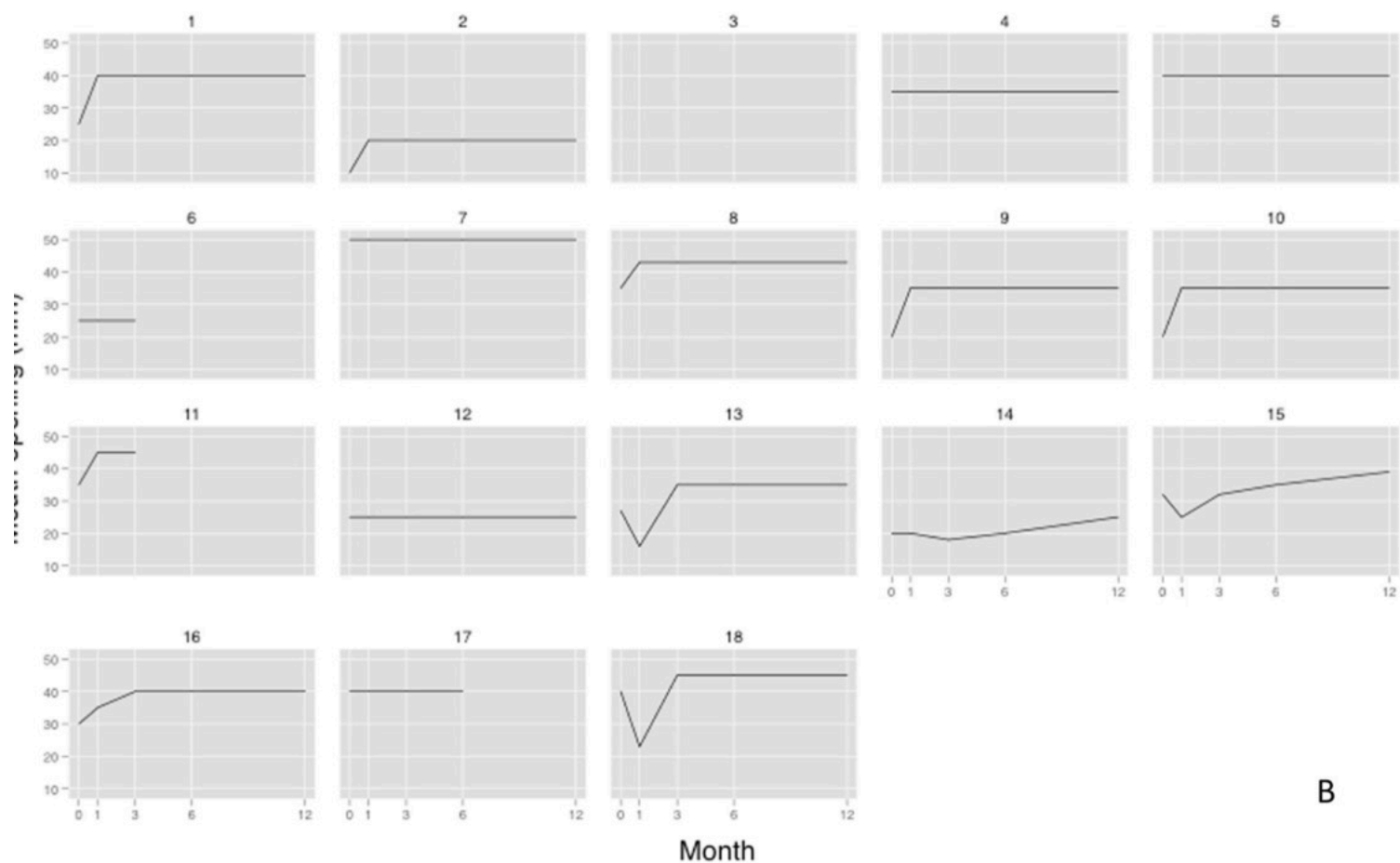






A

Patients with ID = 3, 6, 11 and 17 could not be assigned the main outcome at 1-yr follow-up.



B