

# Structurally compromised teeth. Part I: Clinical considerations and novel classification proposal

Guido Fichera DMD, MSc<sup>1</sup> | Claudia Mazzitelli DMD, MSc, PhD<sup>2</sup> |  
 Vincenzo Picciariello DMD<sup>3</sup> | Tatjana Maravic DMD, PhD<sup>2</sup> |  
 Uros Josic DMD, PhD<sup>2</sup> | Annalisa Mazzoni DMD, PhD<sup>2</sup> | Lorenzo Breschi DMD, PhD<sup>2</sup> 

<sup>1</sup>Dr. Guido Fichera Private Practice, Monza, Italy

<sup>2</sup>Department of Biomedical and Neuromotor Science (DIBINEM), Alma Mater Studiorum, University of Bologna, Bologna, Italy

<sup>3</sup>Dr. Vincenzo Picciariello Private Practice, Bitonto, Italy

## Correspondence

Lorenzo Breschi, Department of Biomedical and Neuromotor Science (DIBINEM), University of Bologna – Alma Mater Studiorum, Via San Vitale 59, 40125 Bologna, Italy.

Email: [lorenzo.breschi@unibo.it](mailto:lorenzo.breschi@unibo.it)

## Abstract

**Objective:** A comprehensive classification of structurally compromised teeth (SCT) was introduced.

**Clinical Considerations:** Dental injuries or operative mismanagement undermine the structural integrity of the tooth abutment, reducing its biomechanical strength and rendering restorative procedures challenging. To standardize the overall pre-operative evaluations and determine the biological and mechanical features, a classification of the coronal and cervical tooth defects, as well as an attentive analysis of the most apical location of the residual cervical tooth structure along the whole perimeter and the most coronal location of the bucco/lingual residual structure was presented. Considering the residual cervical structure, five possible clinical scenarios were individuated with respect to the gingival margin, gingival sulcus, supracrestal tissue attachment and bone crest (BC). The latter prevents the isolation procedures rendering the adhesive restorations unfeasible. Instead, the location of the most apical portion of residual cervical structure within subgingival/intrasulcular depth (>1.5 mm above BC) can be considered restorable.

**Conclusions:** This classification is threefold: to enclose all the possible clinically encountered tooth defects, to identify the apical problems of SCT to appropriately manage the perio-restorative interfaces, and to evaluate the tooth resistance capacity of SCT, as to plan and perform the most adequate biomechanical restorative approach.

**Clinical Significance:** The present classification is proposed to provide a complete perspective of structurally compromised teeth to standardize the biologic and biomechanical evaluations during planning of restorative procedures.

## KEYWORDS

bone crest, cervical structure, classification, ferrule, resistance form, structurally compromised teeth, supracrestal tissue attachment

This is an open access article under the terms of the [Creative Commons Attribution](https://creativecommons.org/licenses/by/4.0/) License, which permits use, distribution and reproduction in any medium, provided the original work is properly cited.

© 2023 The Authors. *Journal of Esthetic and Restorative Dentistry* published by Wiley Periodicals LLC.

## 1 | INTRODUCTION

Tooth integrity can be undermined by fractures and/or rampant caries demanding for attentive preoperative analyses to decide whether the dental element can be restoratively treated, requires surgical and/or orthodontic interventions, or it is chanceless and indicated for extraction. In certain clinical situations, the loss of coronal tooth structure can be very extensive, but with some residual coronal structure, or massive, with a complete absence of coronal structure. The defective tooth is mechanically weaker compared to its sound counterpart and depending on the location of the residual tooth structure with respect to the periodontal tissues, the restorative/prosthetic procedures could be very challenging and mostly dependent on the operator's individual skills, therefore limiting the treatment choice.<sup>1</sup>

This is particularly evident in case of defective restorations of previously prosthetically rehabilitated teeth which require re-interventions due to technical (e.g., loss of prosthetic crown retention, post and/or root fractures) and/or biological (e.g., loss of marginal seal and/or recurrent caries) complications.<sup>2</sup> In these cases, after the removal of the obsolete full-crown restoration, the teeth abutments may present biological (violation of the supracrestal tissue attachment [STA]) and structural (e.g., altered geometry) defects that can negatively affect periodontal health, complicate operative procedures and reduce the mechanical resistance of the tooth.<sup>3</sup>

Several clinical recommendations have been proposed over time to increase the resistance and retention form of compromised teeth abutments, such as vertical grooves, slots and tapered walls paralleling.<sup>4–6</sup> However, these subtractive procedures would further weaken the pathologically reduced tooth structure, impairing its mechanical properties and additionally exposing it to risk of fractures, failures and overall poor prognosis over time.<sup>3,7</sup>

The preservation of as much as possible intact coronal and radicular tooth structure and the maintenance of cervical tissue to create a ferrule effect are considered crucial to optimize the biomechanical behavior of a restored tooth.<sup>8,9</sup> In very demanding clinical cases, crown lengthening and/or orthodontic extrusion have been advocated as the techniques to refer to in case of impediment to intervene with more conservative approaches.<sup>10–13</sup> However, borderline clinical situations between structurally preserved teeth and those requiring surgical/orthodontic interventions, are encountered often in the daily clinical practice.<sup>9</sup> Indeed, such tooth abutments still present some valid residual tooth structure to be restored, but it may be limited to just one or more walls or partial ferrules without all the geometrical and physical requirements (taper  $>15^\circ$ , thickness range between 0.5 and 1 mm), making it difficult to formulate a restorative therapeutic solution where a balance between biological, biomechanical and operative needs are achieved.<sup>14</sup>

The common clinical problem in these structurally compromised teeth is the management of the restorative adhesive procedures of the proximal cervical area, especially in deep cervical lesions.<sup>15</sup> In these clinical situations, where the proximal residual tooth structure is adjacent to, but not impinging the periodontal connective attachment, the isolation with rubber dam and adequate proximal contour reconstruction

can be really challenging, often jeopardizing the quality of the marginal seal and the realization of correct proximal walls. It is also worth mentioning that clinicians can be confused on when and how to restore a structurally compromised tooth before prosthetic preparation.<sup>16,17</sup>

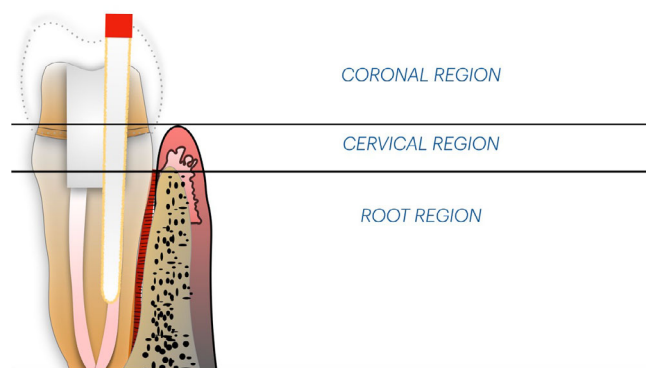
Even though the topic related to the ferrule effect has been extensively covered (in terms of height, thickness, taper and number of walls of residual dentin as well as the evaluation of load-bearing vectors on the tooth) in the last decades,<sup>2,6,8,9,18–20</sup> surprisingly, when this concept is translated into modern dentistry, it essentially remains unconcluded and demand for standardized codifications given the complex biomechanical and biological considerations.<sup>2,18</sup> Indeed, based on the advancement of knowledge and technical possibilities, the authors of this article feel confident that a more exhaustive classification is demanding.

Hence, the objective of this study is to introduce a comprehensive, clinically relevant novel classification of structurally compromised teeth (SCT) based on the status of the residual coronal structure and the location of the residual cervical structure with respect to periodontal tissues. The likelihood of restoring a tooth with margins below the gingival margin outline was thoroughly revisited, thus favoring the preservation of the compromised tooth, facilitating the orthodontic or periodontal procedure when necessary, and postponing the possibility to resort to surgery or implant placement.

## 2 | MATERIALS AND METHODS

### 2.1 | Considerations about residual tooth structure

A detailed classification of SCT cannot be made without an in-depth evaluation of the residual dental structure. To facilitate the clinical analysis, the residual substance of SCT can be distinguished into three different tooth regions (Figure 1):



**FIGURE 1** Schematic representation of the three different tooth regions useful for the interpretation of the location of the residual tooth structure. In particular: the coronal region refers to the supragingival area; the cervical region ranges between the gingival margin and the tip of the proximal papilla up to the bone crest; the root region extends underneath the bone crest. This initial differentiation is essential to focus the operatory range.

- Coronal, intended as the clinically visible residual tooth structure coronal to gingival margin and papilla;
- Cervical, considered as the residual tooth structure ranging between the gingival margin and the bone crest (that is the tooth structure corresponding to the STA and gingival sulcus);
- Root, related to the residual tooth structure underneath the bone crest.

In presence of a foundation restoration, the forces created during oral functions are likely to be concentrated in the regions coronal and apical to the bone crest in a manner that may favor the dislodgement of the bonded restoration and expose the residual tooth structure to fracture.<sup>21,22</sup> This risk seems further increased in case of surgical crown lengthening owing to the unfavorable crown/root ratio.<sup>23</sup> This concept clinically underlines the relevant support exerted by the cervical tooth structure in the resistance capability of the tooth against non-axial forces,<sup>21,22,24</sup> thus enhancing or diminishing the lifespan of the restoration over time.<sup>25</sup> During restorative procedures, the most apical geometry and location of the sound cervical tooth structure of the target tooth are among the most relevant factors conditioning the isolation procedures.<sup>26</sup> Based on the aforementioned considerations, the cervical structure deserves particular interest in the formulation of a schematic but comprehensive classification that could offer the clinician a standardized method for the evaluation of the biological and mechanical problems, facilitating decision-making processes in the management of SCT.

Even though the evaluation of SCT is independent on whether the dental abutment is vital or endodontically treated, it should be considered that the latter presents higher central structure loss compared to the vital counterparts. Indeed, literature identifies the endodontically treated teeth as more likely to undergo structural failure, and the challenge of restoring non-vital teeth has been described to be directly associated with the extensive loss of natural tooth structure.<sup>28,29</sup>

The residual coronal tooth structure is usually examined to evaluate the presence or absence of the ferrule, taking into considerations

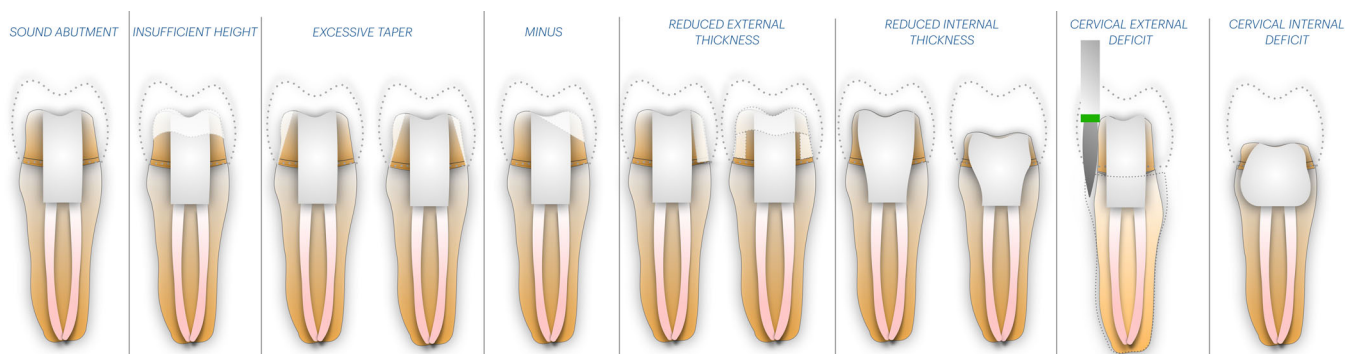
the supragingival position and the number of dentinal walls.<sup>30,31</sup> The presence of the ferrule has been claimed mandatory to consider a tooth restorable.<sup>8,9</sup> Instead, when dealing with molars, the clinical relevance of the ferrule effect is questionable while the pulp chamber is taken into consideration since it contributes to increase the resistance and retention of the coronal restoration.<sup>32,33</sup> Ferrule has been generally identified as the 1.5 mm height collar of at least 1 mm-thick residual dentin after tooth preparation, with 10–15° tapered walls above the prosthetic margin necessary to enhance the biomechanical prognosis of the restored endodontically treated abutments teeth.<sup>6,18,34</sup> Although it is clear that a full 360° ferrule is desirable,<sup>23</sup> there are clinical circumstances where adopting a partial ferrule is still better than the alternative surgical or more aggressive treatment options.<sup>2,20,35</sup> In general, the more ferrule walls present, the better the fracture resistance, but sometimes it is not the number of walls that should be the focus of consideration, but rather the location of these walls.<sup>36</sup> Indeed, depending on the clinical situation,<sup>37</sup> if on the one hand the presence of the ferrule has the function of increasing the mechanical resistance of the tooth/abutment,<sup>31</sup> on the other hand, the location of the residual dental structure with respect to the periodontal tissues is of fundamental importance for asserting its biological response in the medium/long term.

### 2.1.1 | Geometrical defects classification

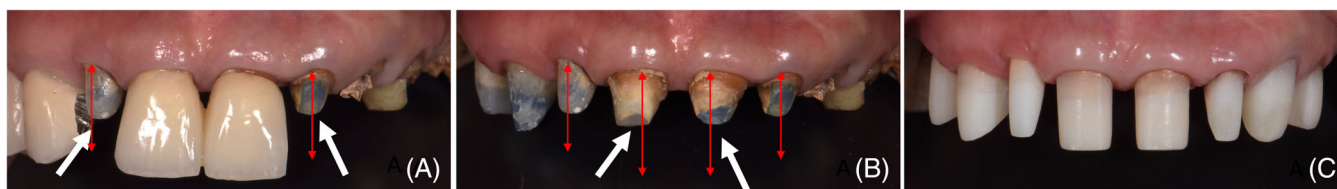
After the removal of an obsolete prosthetic crown, the coronal/cervical region of the tooth abutment can assume different defective geometries as a consequence of flawed foundation restorations, dental injuries (caries, fracture, wear, and resorption) or incorrect tooth preparation.

Considering an ideal abutment formed by retentive and resistant geometry (Figure 2A), the defects can involve the coronal or the cervical regions and can be summarized as follows (Figure 2B–E):

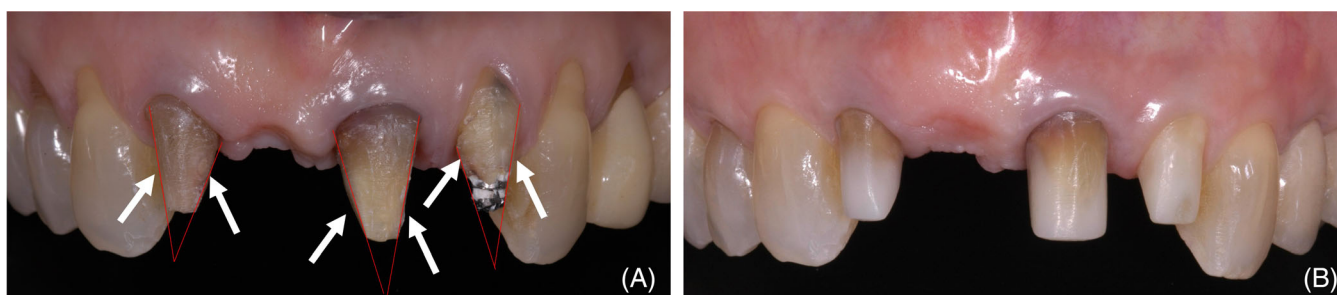- insufficient height of the abutment (due to tooth lesion or excessive occlusal reduction) (Figures 2B and 3);



**FIGURE 2** Classification of the defects clinically encountered at the removal of defective full-crown prostheses. A. Geometrical characteristics of an ideal abutment (the presence of at least 1.5 mm height collar with 1 mm thickness and 10–12° tapered walls); B. Abutment with insufficient height. C. Abutment with excessive taper in 1 or 2 walls. D. Presence of minus in the abutment structure. E. Reduced external thickness of tooth walls or ferrule. F. Reduced internal thickness of the abutment. G. Cervical external deficit. H. Cervical internal deficit.



**FIGURE 3** Illustration of representative abutments with reduced height at the removal of defective full-crown ceramic restorations. A. Maxillary lateral incisors with insufficient height; B. Situation of the maxillary central incisors at the complete removal of the defective restorations. In this situation, the discrepancy (red arrows) between the height of the abutment (white arrows) and the restoration immediately attracts the attention. C. Replacement of the correct anatomy of the abutment after additive foundation restoration according to the peripheral build-up technique (PBUt).



**FIGURE 4** At the removal of the fixed prosthesis, the abutments (white arrows) presented excessive taper (red lines) that can jeopardize the load-bearing ability of the final restorations (A). B. The image shows the restored abutment by the PBUt with the adequate geometrical features in terms of height and taper.

- excessive taper (consequent to tooth lesion or excessively conical preparation) (Figures 2C and 4);
- presence of a minus, for example, structural deficit without specific geometrical feature (due to tooth lesion or incorrect preparation) (Figures 2D and 5);
- reduced external thickness of residual walls and ferrule (in presence of tooth lesion, excessive axial reduction and cervical preparation) (Figures 2E and 6);
- reduced internal thickness of residual wall and ferrule (due to tooth lesion or excessive loss of central core structure) (Figures 2F and 7);
- cervical external deficit (in case of prosthetic preparation with extensive root reshaping) (Figures 2G and 8); and
- cervical internal deficit (loss of internal tooth structure, e.g., caries) (Figures 2H and 9).

From a mechanical point of view, these defects should be resolved to increase the resistance capability of the tooth/abutment.<sup>38</sup> However, it seems there is no codified strategy to manage these situations with mechanically and biologically therapeutic considerations, leaving the clinicians without well-defined and rational indications on how to treat SCT. Hence, a standardization of the operative procedures is clinically desirable. In this term, the authors believe that the restorable solution of the aforementioned biomechanical and biological problems (Figures 3–9) is the peripheral build-up technique (PBUt) that will be treated in detail in the Part II.

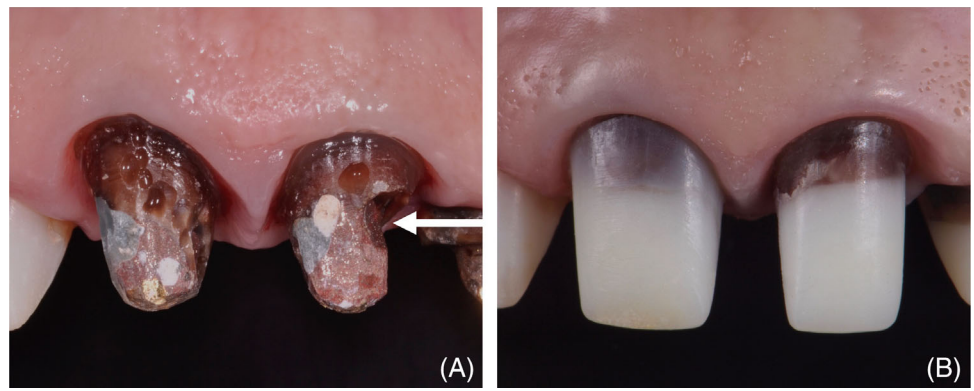
## 2.2 | Evaluation of the cervical tooth structure

The examination of the residual cervical structure and periodontal tissues of the affected dental element and adjacent teeth, when they are present, should be carried out by a careful clinical examination, evaluation of periapical and/or bitewing radiographs, and periodontal probing. The clinical complexity of restoring a SCT can be related to the following factors:

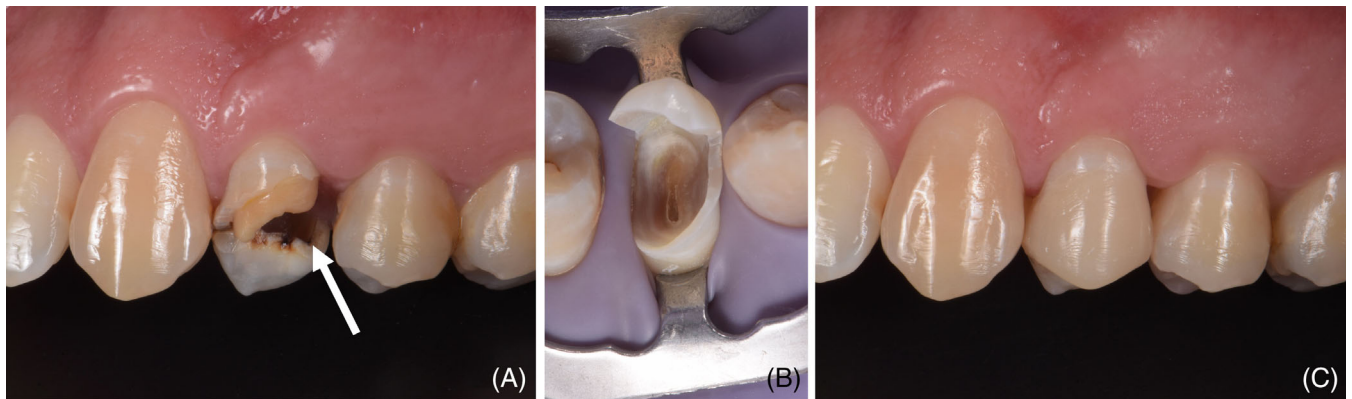
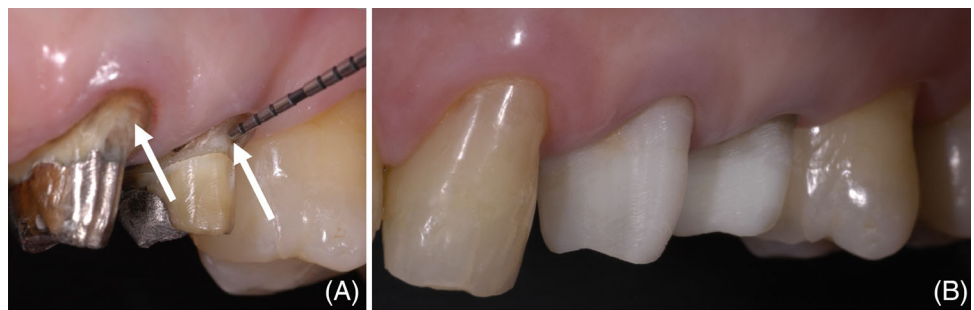
- geometry of tooth surface border to be restored (margin vs inclined plane);
- subgingival depth of the tooth margin or lesion (in presence of caries, fracture, or resorption), taking into consideration the relationship with the STA;
- status of periodontal tissues (presence of inflammatory conditions);
- contour anatomy (uniformly convex, s-shaped, concavity, proximity to furcation);
- tooth location in the arch (1–2 rooted or 3-rooted teeth);
- root position in alveolar bone;
- proximity of the target tooth to root and crown of adjacent teeth; and
- anatomy, pathologic conditions, artificial obstacles in the chamber and root canal system.

Among all, the geometry of residual tooth structure and subgingival location are the most frequently clinically encountered situations

**FIGURE 5** Presence of minus (white arrows) at the expense of the structure of both the upper right and left central incisors (A). The PBUt, thanks to an additive build-up restoration, allowed to recover the adequate morphology of the abutment (B).

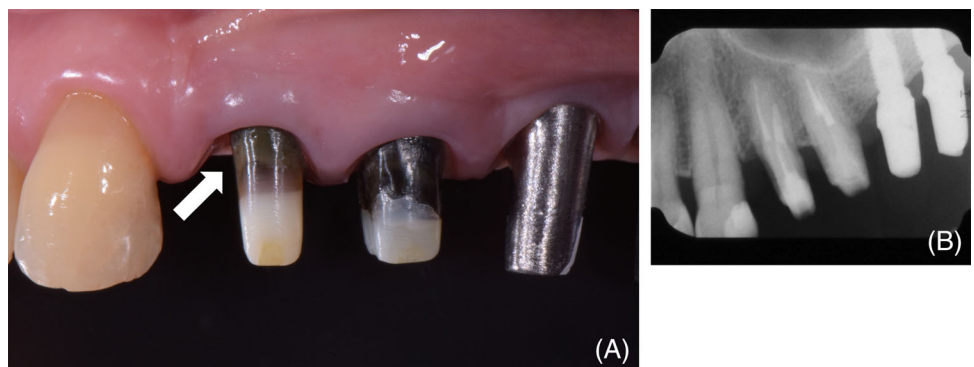


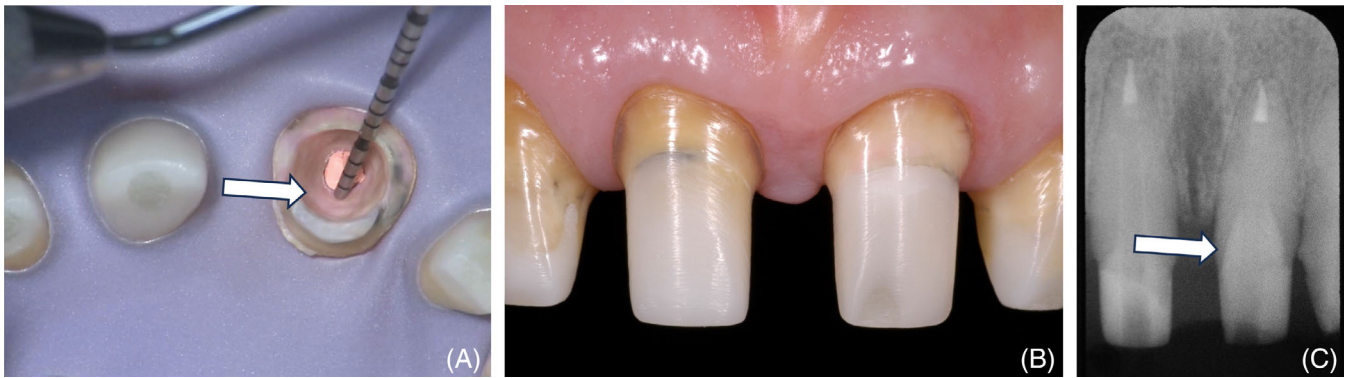**FIGURE 6** Example of reduced external thickness of the dentinal walls (A). After build-up restoration according to the PBUt (C).



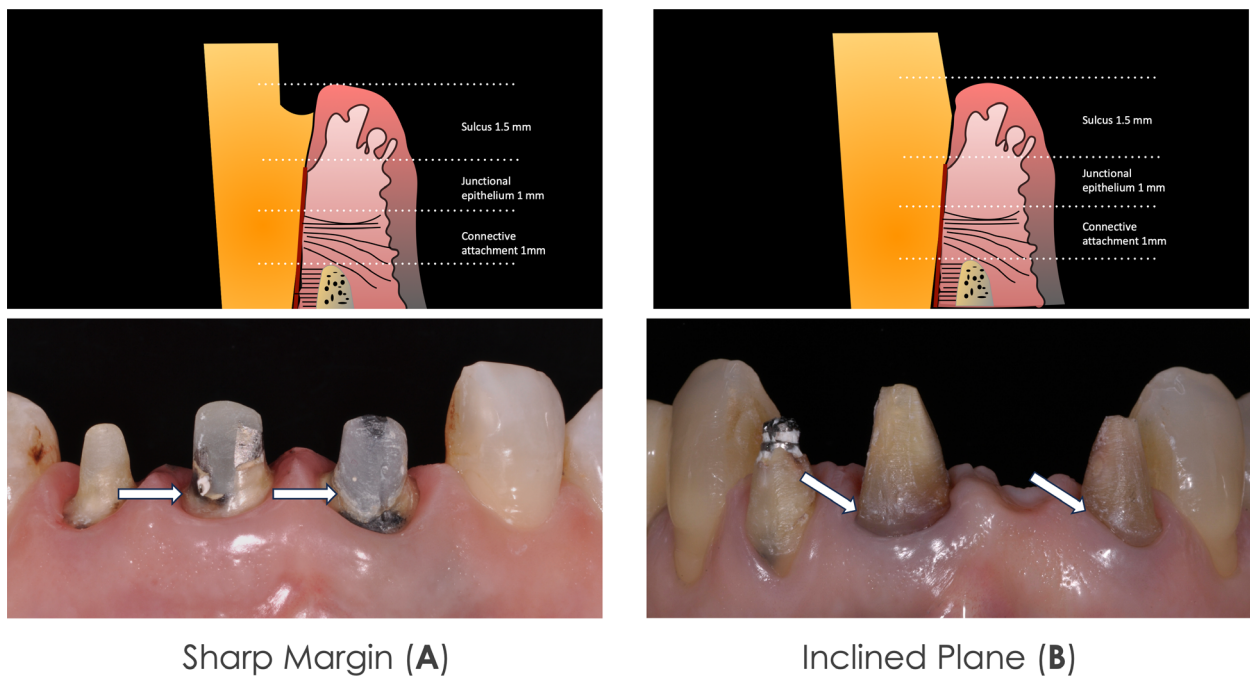
**FIGURE 7** Clinical situation in which aggressive caries lesions reduced the internal thickness of the upper left first premolar (A). B. Image showing the residual tooth structure after complete removal of the caries lesion under rubber dam isolation. C. The final restoration is a direct full crown composite restoration, which has been planned as a foundation restoration for orthodontic extrusion and full crown preparation.

**FIGURE 8** Image showing (A) a clinical case of external cervical defect on the mesial wall of the first upper premolar as a consequence of extensive root reshaping (white arrow) and (B) the rx of the foundation restoration with composite build-up and glass fiber post.





**FIGURE 9** The defect involves the internal portion of the cervical area (A). The abutment after the completion of the composite build-up and glass fiber post (B) with the rx showing the adaptation of the restoration in the deepest part of the cervical portion (C). This would reinforce the cervical region of the tooth abutment from a mechanical point of view.



**FIGURE 10** Two main geometries of the residual cervical structure can be individuated: sharp margin (A) and inclined plane (B). Under these two main configurations, several intermediate geometrical conditions can be then individuated, according to the entity and width of the sharp margin and tapering and inclination of the plane.

and, thereby, they deserve particular attention to establish a valid treatment plan.<sup>1,2,10</sup> Basically, the geometry of the sound cervical tooth structure can be a sharp margin or an inclined plane (Figure 10). The cervical tooth structure with sharp margins is usually the consequence of caries removal or, in case of prosthetic retreatment, the finishing line of horizontal preparation found at the crown removal. The cervical tooth structure with inclined plane is usually the consequence of fracture or, in case of prosthetic retreatment, the finishing area of vertical preparation found at the crown removal.

In the context of these two extreme configurations, there are all the intermediate geometrical conditions, with sharp margins that

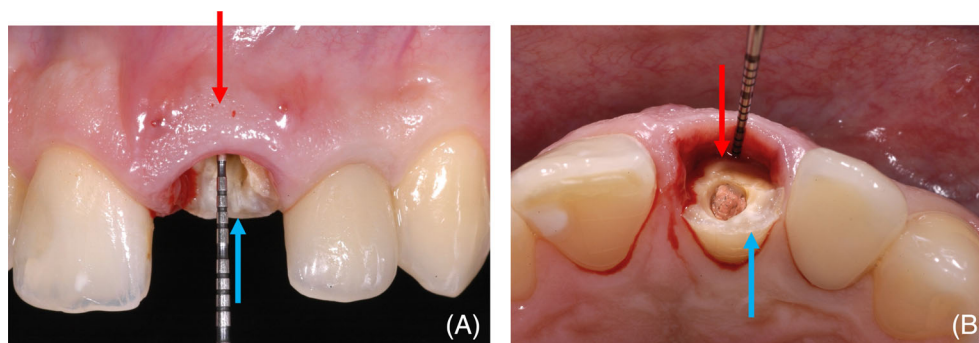
can have different widths and inclined planes that can have different tapers.

### 2.2.1 | Cervical tooth structure: A classification proposal

The proposed classification is based on the evaluation of the most apical location of the residual cervical structure along the whole tooth perimeter and the most coronal location of the buccal/lingual residual tooth structure, in order to respectively provide a standardized perspective of the biological and biomechanical characteristics of the tooth (Table 1 and Figure 11).

**TABLE 1** Overall classification of the structurally compromised teeth having in mind the biological assessments (dictated by the most apical location of the residual cervical structure) and biomechanical evaluations (related to the most coronal location of bucco/lingual coronal structure). It is important to mention that a series of classification combinations (i.e. scenario B in presence of c in one part of the residual tooth structure) can be clinically encountered and evaluated case-by-case. The capital and small letters are used for biological and biochemical evaluation, respectively.

Biological evaluation		Biomechanical evaluation	
Classification	Most apical location of the Cervical structure	Classification	Most coronal location of the buccal/lingual structure
W (Wall)	Supragingival tooth structure with height > 75% ideal abutment, thickness >1 mm, taper 10–12°	w (Wall)	Supragingival buccal/lingual tooth structure with height > 75% ideal abutment, thickness >1 mm, taper 10–12°
F (Ferrule)	Supragingival tooth structure with height >1.5 mm, thickness >1 mm, taper 10–12°	(Ferrule)	Supragingival buccal/lingual tooth structure with height < 75% ideal abutment, but >1.5 mm, thickness >1 mm, taper 10–12°
A (Absence of ferrule)	Supragingival tooth structure with height <1.5 mm	a (Absence of ferrule)	The most coronal location of the residual buccal/lingual structure is supragingival with no more than 1.5 mm height of residual tissues.
B (Intrasulcular)	Subgingival tooth structure in the gingival sulcus (up to 3 mm)	b (Intrasulcular)	The most coronal location of the buccal/lingual residual structure is subgingival and intrasulcular (up to 3 mm depth)
C (Superficial/Coronal STA)	Subgingival tooth structure coronal 1.5 mm to the bone crest	c (Superficial/Coronal STA)	The most coronal location of the residual buccal/lingual structure is subgingival, adjacent or in the coronal portion of the STA (1.5 mm above the bone crest)
D (Deep/apical STA)	Subgingival tooth structure coronal to the bone crest and <1.5 mm bone crest distance	d (Deep/apical STA)	The most coronal location of the residual buccal/lingual structure is subgingival, in the deeper apical portion of the STA but with a distance <1.5 mm the bone crest
R (Subcrestal root)	Subgingival tooth structure apical to the bone crest	r (Subcrestal root)	The most coronal location of the buccal/lingual structure is located underneath the bone crest, that is, it is subcrestal

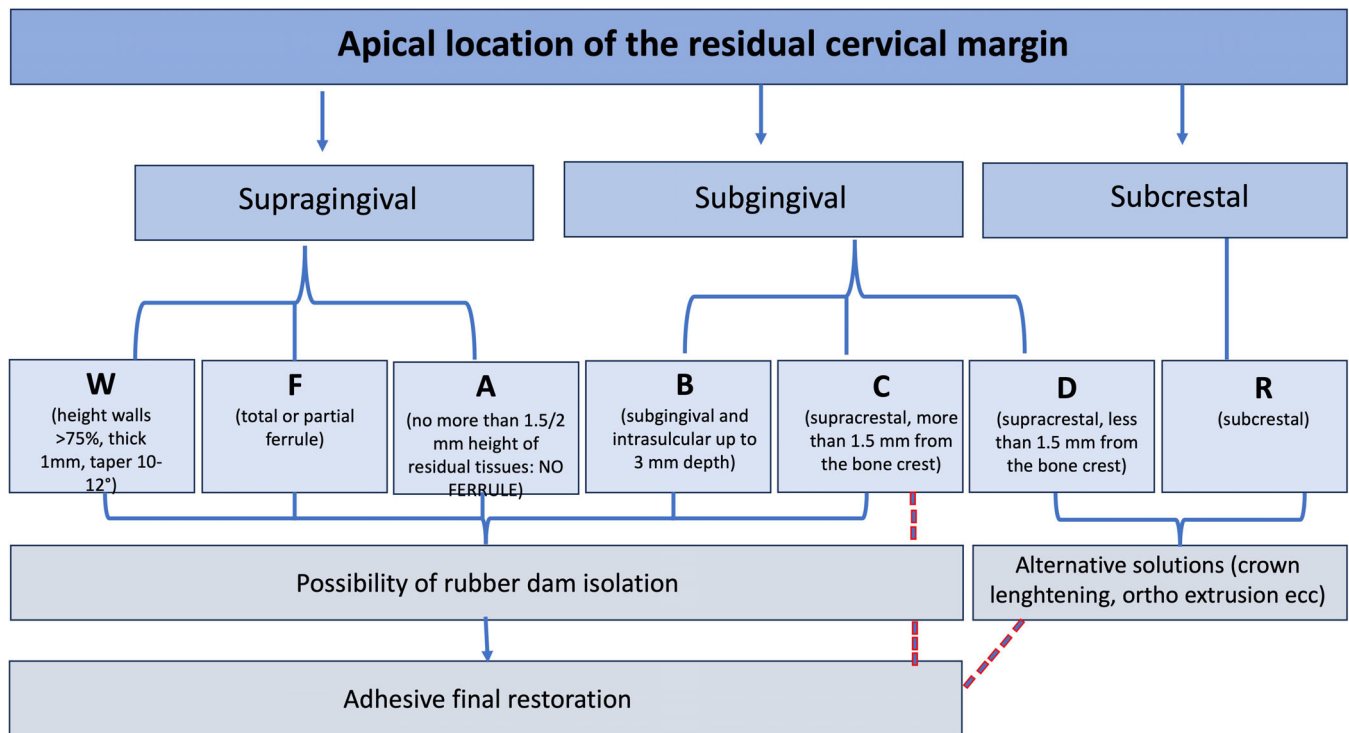


**FIGURE 11** An overall evaluation of residual dental structure of badly compromised teeth should be performed from a biological and biomechanical point of view, to establish the correct intervention. This can be performed by a 360° observation of the whole residual tooth structure. Biological evaluation is based on probing and radiographical assessment of the location of the most apical residual cervical structure (red arrows). Instead, the most coronal location of the residual buccal/lingual coronal structure would give information on the biomechanical characteristics of the tooth abutment (blue arrows). Both evaluations would drive the clinician choice toward the best operative approach to maintain the dental element.

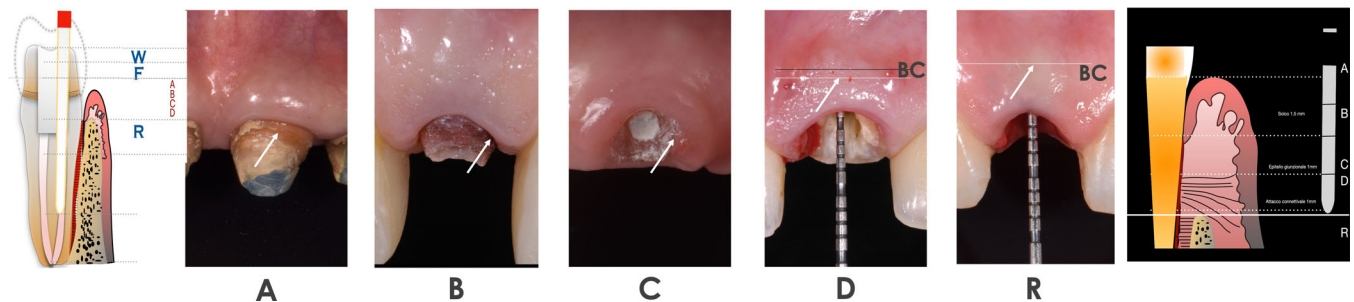
### 2.2.2 | Assessment of the most apical location of the residual cervical tooth structure (biological evaluation)

The apical location of the sound cervical tooth structure should be identified to establish a correct treatment plan with biological

prerequisites.<sup>39</sup> The residual cervical structure can be peripherally located supragingivally as a wall herein connotated as “W” (coronal structure with height > 75% than an ideal abutment, thickness >1 mm and taper of 10–12°), or with the presence of total or partial ferrule (classification “F”) (Figure 12). Clinical scenarios “W” and “F” are presented in the proposed classification, but they will be not treated in



**FIGURE 12** The assessment of the most apical location of the cervical tooth structure with respect to the periodontal tissues enables to distinguish different clinical scenarios. The cervical margin location can be located supragingivally (W, F, and A), subgingivally (B, C, and D) or subcrestally (R). The classification allows to identify whether the tooth abutment can be isolated with rubber dam and adhesively restored (W-C) or require for alternative strategies (i.e., surgical crown lengthening, orthodontic or surgical extrusion) (D and R). Particular attention should be focused on clinical scenario C, since, in case of necessity (re-evaluation of the treatment plan and/or periodontal inflammatory response), it is still possible to refer to alternative treatment approaches with the advantage, in this second option, to manage an already restored teeth, thus possibly favoring surgical/orthodontic procedures.

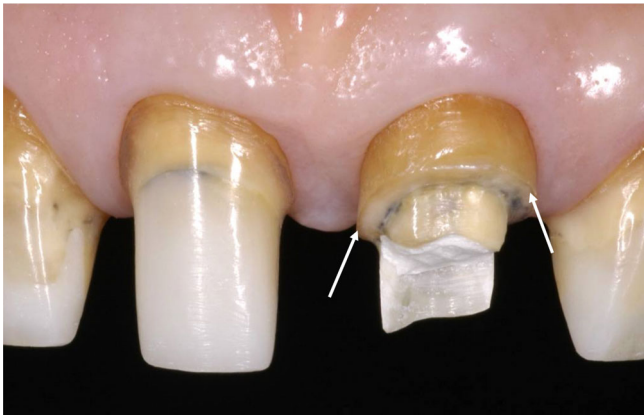


**FIGURE 13** Representative panel of the clinical scenarios individuated in the proposed classification of structurally compromised teeth. Except scenarios W (wall) and F (ferrule) that represent the most feasible restorative situations, scenario A-R are taken into consideration in the present study. In particular, the graphical representations indicate the biological range in which it is possible to localize the most apical margin of the residual cervical structure (A-R).

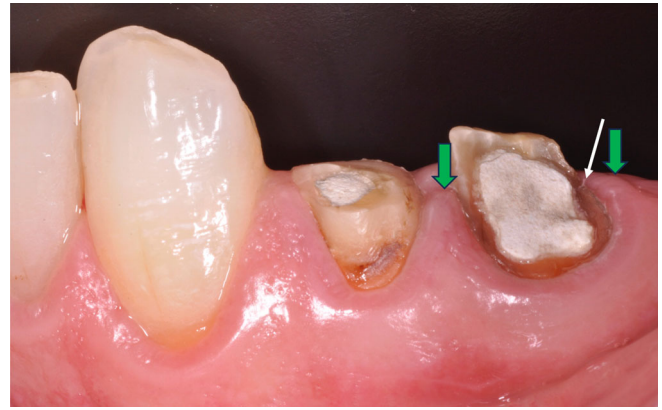detail as, for the purpose of this paper, they represent the most reliable supragingival situations which treatment does not require particular precautions except those related to the knowledge and management of daily adhesive restorative procedures.

According to the position of the most apical part of the cervical structure with respect to the gingival margin, gingival sulcus, STA and bone crest, 5 major different clinical scenarios can be individuated (Figure 13):

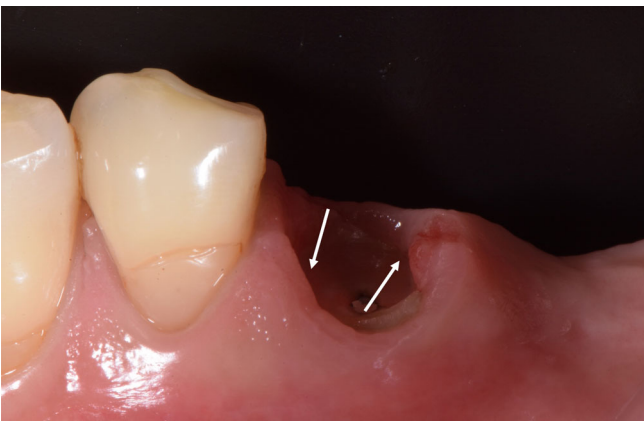- The most apical cervical structure to be restored is supragingival with no more than 1.5/2 mm height of residual tissues (no ferrule). The target tooth has the cervical structure, in one limited portion or along the whole tooth perimeter, coronal to the gingival margin and to the tip of the proximal papilla with no more than 1.5/2 mm height of residual tissues (Figure 14).
- The most apical cervical structure to be restored is subgingival and intrasulcular (up to 3 mm depth). The target tooth has the



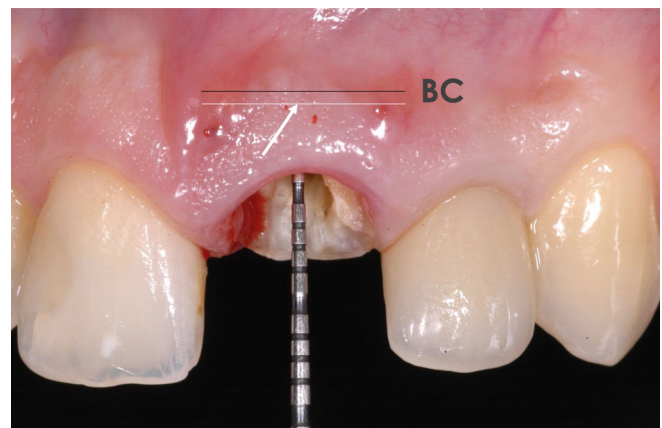
**FIGURE 14** Representative image of typical scenario A where, although a certain amount of supragingival cervical structure is present (white arrows), this is inferior to 1.5–2 mm at the proximal regions and therefore the tooth abutment is considered in absence of ferrule. In this situation, rubber dam positioning has no particular impediments.



**FIGURE 15** Representation of typical scenario B, constituted by the most apical location of the peripheral or partial residual cervical structure subgingivally (white arrow), and, in particular, the margin is located below the gingival margin and the tip of the proximal papilla (green arrows). From a biological point of view, in this scenario the most apical residual structure is located in the gingival sulcus.



**FIGURE 16** Image showing an example of a SCT corresponding to the clinical scenario C, according to the proposed classification. In this case, the most apical residual cervical structure is subgingival, but supracrestal (>1.5 mm above the bone crest). This clinical scenario in 1–2 rooted teeth, although clinically challenging, always allows dental dam isolation (Authors' recommendation).



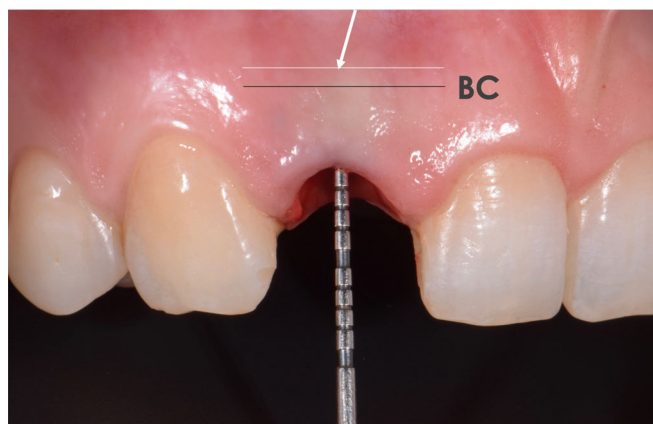
**FIGURE 17** Clinical scenario D in which the most apical residual tooth structure is located subgingival (white arrow and line) and with a distance <1–1.5 mm from the bone crest (BC, black line). Probing (as shown in the picture) and radiographs are necessary for the establishment of these measures.

cervical structure, in one limited portion or along the whole tooth perimeter, apical to the gingival margin and to the tip of the proximal papilla, but coronal to the periodontal attachment (that is, the cervical structure is in the gingival sulcus) (Figure 15).

- C. The most apical cervical structure to be restored is subgingival, adjacent or in the coronal portion of the STA. The target tooth has the cervical structure, in one limited portion or along the whole tooth perimeter, subgingival, in a corono-apical range from the bottom of the sulcus (when the sulcus depth is <3 mm) or the apical depth of the sulcus (when the sulcus depth is >3 mm) to a distance from the bone crest more than 1.5 mm (that is, the cervical

structure can be located at the bottom or apical depth of the sulcus or in the junctional epithelium or in the coronal portion of the connective attachment). Given the prevalence of the physiologic probing within 3 mm, this clinical scenario can also be defined as subsulcular (Figure 16).

- D. The most apical cervical structure is subgingival, in the deeper apical portion of the STA, at the level of the bone crest. The target tooth has the cervical structure, in one limited portion or along the whole tooth perimeter, subgingival, but with a distance less than 1.5 mm from the bone crest (that is the cervical structure is in the context of the deeper apical portion of the junctional epithelium or in the connective attachment). The defect is still supracrestal (Figure 17).



**FIGURE 18** The most apical location of the residual cervical structure (white arrow and line) is underneath the bone crest (BC, black line), therefore is subcrestal (scenario R).

E. The most apical cervical structure is located underneath the bone crest, that is, it is subcrestal (clinical scenario related to the location of the coronal third of the root) (Figure 18).

The proposed classification encloses all the possible clinical scenarios of SCT necessary for the determination of the biological conditions to determine the operative procedures related to the residual cervical tooth tissue in the corono-apical level, as depicted in Figures 12 and 13.

Following these indications, it would be possible to establish whether and how much the periodontal tissue can be displaced by means of dental clamping, allowing for the placement of rubber dam, with some clinical tips that will be presented in the Part II. Due to the close location to the bone crest, clinical scenarios D (in which the apical level of the cervical structure is still supracrestal but located at less than 1.5 mm to the bone crest) (Figure 17) and R (where the residual tooth structure is subcrestal) (Figure 18) represent the sole situations in which the placement of rubber dam is technically impracticable (Table 1). In these situations, alternative approaches should be considered, such as surgical crown lengthening or orthodontic or surgical extrusion to expose the sufficient amount of sound tooth structure to be isolated and used for restorative procedures.

The proposed classification particularly focuses on the specificity of the most challenging clinical situation for adhesive restoration, the scenario C (Figure 16). In this case, when dealing with 1- to 2-rooted teeth (i.e., from central incisors to second premolars), the authors consider dental clamping and rubber dam placement always feasible, and hence also the execution of adhesive restorative procedures. However, in these cases, the periodontal parameters should be closely monitored to evaluate whether signs of inflammation would occur over time.<sup>40</sup> In case periodontal inflammation occurs, alternative solutions can still be adopted (such as crown lengthening, orthodontic extrusion, periodontal surgery ecc), likewise facilitated by the previous evaluation of the quantity of tissue to be exposed and with the advantages of having the SCT already restored.

### 2.2.3 | Assessment of the most coronal location of the buccal/lingual residual cervical tooth structure (biomechanical evaluation)

Considering that the load-bearing forces have an occluso-gingival and bucco-lingual direction in the posterior teeth and bucco-lingual in the anterior teeth,<sup>21,22</sup> the likelihood to rely on preparation with partial ferrule effects limited to just one buccal or lingual side is clinically feasible<sup>2,27,36</sup>; thus, this structural condition represents the borderline situation with a reliable prognosis. In this regard, beside the biological evaluation of the most apical location of the residual cervical margin, it is deemed necessary considering the most coronal location of the residual structure for the biomechanical evaluation. Accordingly, Table 1 shows a classification of the different clinical scenarios of the buccal/lingual residual tooth structure that dictate the biomechanical characteristics of SCT and herein presented with lowercase letters.

## 3 | DISCUSSION

Natural teeth can undergo structural compromises as a result of rampant caries, fractures and severe wear. Furthermore, the presence of SCT under deficient full crowns is also a very frequent clinical reality. The possibility to reintervene in these situations has been made possible through the advancement in the materials' technology and improved knowledge of treatment possibilities that has widened the range of operative applications.<sup>2</sup>

Several strategical techniques have been proposed in the last decades for the reconstruction of SCT,<sup>25,26,41</sup> and this is evidence of the great interest invested to manage these clinical situations.

The subgingival location of the residual cervical margin has been considered defiant for bonding procedures, owing to the difficulties in rubber dam placement. Originally, surgical crown lengthening and orthodontic or surgical extrusion have been considered the possible clinical options to expose the necessary quantity of tooth structure to enable restorative and prosthetic procedures. However, these approaches may be considered disadvantageous from many aspects, of which the technical sensitivity, the economic expenditure, the longer treatment time, the risk of reducing the crown-to-root ratio and the potentially unesthetic results are some deterrents.<sup>10,23</sup>

Notwithstanding the increasing interest toward the preservation of natural teeth, this issue is still open to discussion. Besides the realization of esthetically pleasant restorations, a successful treatment of the tooth abutment is realized through the achievement of its maximum biomechanical resistance to detrimental forces and maintenance of healthy periodontal tissues. Therefore, the proposed classification aims at sustaining clinicians in the assessment of the potential periodontal infringement and the level of operative complexity (when considering the most apical location and geometry of the residual cervical structure) and the potential biomechanical resistance capability of the residual tooth structure (when considering the most coronal location of the buccal/lingual structure) (Table 1). To the best of authors' knowledge, this is the first attempt to provide a complete

evaluation of the tooth-related factors (biological and biomechanical) to support clinicians in the decision-making process of restorative procedures.

In particular, within this classification, the authors intend to draw the attention to those challenging clinical scenarios, such as B (with the most apical cervical structure located subgingival and intrasulcular) and C (subgingival up to 1.5 mm from the bone crest), that can pose clinicians in front of the decision on whether to intervene with direct restorative approaches or refer to more aggressive or time-consuming interventions. It should be pointed out that, in case orthodontic extrusion or surgical interventions have to be performed, the combined evaluation of the biologic needs at the peripheral cervical level and biomechanical considerations based on the residual bucco/lingual structure dictates the amount of tooth tissue that has to be exposed.

Concerns can be arisen when dealing with intrasulcular restoration, as it could be questioned whether the violation of STA would occur. In some previous studies, the intrasulcular location of the restoration margin has been considered liable to gingival inflammation, loss of attachment, and bleeding on probing.<sup>42,43</sup> Regarding the biometric data of the STA,<sup>44,45</sup> it should be noted that there is no clear consensus on its exact dimensions, with great inter- and intra-individual variations,<sup>46</sup> as the real dimensions can only be confirmed histologically.<sup>47</sup> It is interesting to mention that other studies have showed that, even if the radiographic distance between the bone crest and restoration margins is 0.5–1 mm, after 1-year no clinical signs of inflammation (no bleeding on probing) with only minimal loss of alveolar bone could be observed, providing that strict oral hygiene regime is respected.<sup>41,48</sup>

In author's experience, it has been substantially found that dental dam isolation is not related on how much the margin is subgingival, but it is related on how much the margin is supracrestal. Accordingly, 1.5 mm of supracrestal tooth structure has been shown to be the minimum residual tooth structure to perform a reliable dental clamping in 1- to 2-rooted teeth.

A restoration in the clinical scenario C of course requires a subsequent periodontal evaluation by clinical and radiographic examination in the months to come after the restorative phase in order to check-out the periodontal adaptative or pathological response.<sup>26,49</sup> Considering the standard deviation of periodontal connective attachment,<sup>47</sup> the possibility to perform a reliable adhesive foundation restoration at a distance from the bone crest of about 1.5 mm as suggested by the authors of this paper with a periodontal adaptation response is a prevalent clinical reality. As a consequence, a reliable direct adhesive restoration performed in critical subgingival condition (like scenario C) would always represent the first treatment option because in most cases it can be resolute (when in presence of periodontal adaptation); instead, in case of adverse periodontal condition, it would be however extremely effective as the best preliminary foundation restoration substrate for the surgical crown lengthening or orthodontic extrusion (Figure 12). In case of vertical prosthetic preparation, the peculiarity of the subsulcular condition of clinical scenario C allows the clinicians to identify the cervical tooth region to be prepared in order to achieve a finishing area along the whole sulcus after the healing of the periodontal marginal injury.<sup>50</sup>

As an operative summary, the authors intend to underline that clinical scenarios W, F and A represent the supragingival conditions which are practically undemanding; the clinical scenarios B and C represent the subgingival locations of the residual tooth structure that definitively prevents the possibility of dental dam isolation, thus requiring for alternative treatment plan (surgical crown lengthening and orthodontic extrusion). Finally, the clinical scenarios D and R can be defined as pericrestal.

Even though clinical trials are needed to put the proposed classification into practice, the part II of this paper will thoroughly discuss and justify the rationale behind it with the introduction of a novel technique for foundation restoration.

## 4 | CONCLUSIONS

The restoration of SCT requires careful biological and mechanical evaluations. The present classification is intended to enhance the existing and offer new standardized operative guidelines, enlarge the spectrum of strategical clinical options for the maintenance of the natural tooth and perform a risk-benefit analysis during diagnostic phases. Moreover, it is useful to dictate biologically and biomechanically oriented considerations on the amount of tooth structure to be exposed in case of necessity of orthodontic or surgical interventions.

The possibility of rubber dam placement in clinical scenario C (in which the most apical cervical structure is located subgingival up to 1.5 mm from the bone crest) was revisited, thus enlarging the operative possibility for the adhesive restoration of structurally compromised teeth.

## AUTHOR CONTRIBUTIONS

*Conceptualization:* Guido Fichera. *Methodology:* Guido Fichera, Vincenzo Picciariello, Claudia Mazzitelli. *Formal analysis and investigation:* Guido Fichera, Vincenzo Picciariello, Claudia Mazzitelli, Tatjana Maravic. *Writing - original draft preparation:* Guido Fichera, Claudia Mazzitelli, Tatjana Maravic, Uros Josic, Annalisa Mazzoni. *Writing - review and editing:* Guido Fichera, Uros Josic, Annalisa Mazzoni, Lorenzo Breschi. *Supervision:* Guido Fichera, Claudia Mazzitelli, Lorenzo Breschi.

## CONFLICT OF INTEREST STATEMENT

The authors do not have any financial interest in the companies whose materials are included in this article.

## DATA AVAILABILITY STATEMENT

Data sharing is not applicable to this article as no new data were created or analyzed in this study.

## ORCID

Lorenzo Breschi  <https://orcid.org/0000-0001-7621-226X>

## REFERENCES

1. Moghaddam AS, Radafshar G, Taramsari M, Darabi F. Long-term survival rate of teeth receiving multidisciplinary endodontic, periodontal and prosthodontic treatment. *J Oral Rehab.* 2014;41:236-242.

2. Mannocci F, Bitter K, Sauro S, Ferrari P, Austin R, Bhuvu B. Present status and future directions: the restoration of root filled teeth. *Int Endod J*. 2022;55:1059-1084.
3. Di Febo G, Bedendo A, Romano F, et al. Fixed prosthodontic treatment outcomes in the long-term management of patients with periodontal disease: a 20-year follow-up report. *Int J Prosthodont*. 2015; 28:246-251.
4. Bowley JF, Lee P, Lai WT. Axial wall angulation for rotational resistance in a theoretical-maxillary premolar model. *Clin Exp Dent Res*. 2019;5:638-647.
5. Bowley JF, Lai WF. Surface area improvement with grooves and boxes in mandibular molar crown preparations. *J Prosthet Dent*. 2007; 98:436-444.
6. Cameron SM, Morris WJ, Keesee SM, Barsky TB, Parker MH. The effect of preparation taper on the retention of cemented cast crowns under lateral fatigue loading. *J Prosthet Dent*. 2006;95:456-461.
7. Edelhoff D, Sorensen JA. Tooth structure removal associated with various preparation designs for anterior teeth. *J Prosthet Dent*. 2002; 87:503-509.
8. Juloski J, Apicella D, Ferrari M. The effect of ferrule height on stress distribution within a tooth restored with fibre posts and ceramic crown: a finite element analysis. *Dent Mater*. 2014;30:1304-1315.
9. Juloski J, Radovic I, Goracci C, Vulicevic ZR, Ferrari M. Ferrule effect: a literature review. *J Endod*. 2012;38:11-19.
10. Smukler H, Chaibi M. Periodontal and dental considerations in clinical crown extension: a rational basis for treatment. *Int J Periodontics Restorative Dent*. 1997;17:464-477.
11. Kocadereli I, Tasman F, Güner SB. Combined endodontic, orthodontic and prosthodontic treatment of fractured teeth. *Case Report Aust Dent J*. 1998;43:28-31.
12. Lanning SK, Waldrop TC, Gunsolley JC, Maynard JG. Surgical crown lengthening: evaluation of the biological width. *J Periodontol*. 2003; 74:468-474.
13. Felipe LA, Monteiro Júnior S, Cardoso LC, et al. Reestablishing biologic width with forced eruption. *Quintessence Int*. 2003;34: 733-738.
14. Shillingburg HT, Hobo S, Whitsett LD, et al. *Fundamentals of Fixed Prosthodontics*. 3rd ed. Quintessence; 1997 120, 139-142, 151-152.
15. D'Arcangelo C, Vanini L, Casinelli M, et al. Adhesive cementation of indirect composite inlays and onlays: a literature review. *Compend Contin Educ Dent*. 2015;36:570-577.
16. Christensen GJ. When to use fillers, build-ups or posts and cores. *J Am Dent Assoc*. 1996;127:1397-1398.
17. Pratt I, Aminoshariae A, Montagnese TA, Williams KA, Khalighinejad N, Mickel A. Eight-year retrospective study of the critical time lapse between root canal completion and crown placement: its influence on the survival of endodontically treated teeth. *J Endod*. 2016;42:1598-1603.
18. Jotkowitz A, Samet N. Rethinking ferrule—a new approach to an old dilemma. *Br Dent J*. 2010;209:25-33.
19. Cloet E, Debels E, Naert I. Controlled clinical trial on the outcome of glass fibre composite cores versus wrought posts and cast cores for the restoration of endodontically treated teeth: a 5-year follow-up study. *Int J Prosthodont*. 2017;30:71-79.
20. Schmitter M, Doz P, Rammelsberg P. Influence of clinical baseline findings on the survival of 2 post systems: a randomized clinical trial. *Int J Prosthodont*. 2007;20:173-178.
21. Sorrentino R, Monticelli F, Goracci C, et al. Effect of post-retained composite restorations and amount of coronal residual structure on the fracture resistance of endodontically-treated teeth. *Am J Dent*. 2007;20:269-274.
22. Maravic T, Comba A, Mazzitelli C, et al. Finite element and in vitro study on biomechanical behavior of endodontically treated premolars restored with direct or indirect composite restorations. *Sci Rep*. 2022; 12:12671.
23. Meng Q, Ma Q, Wang T, Chen Y. An in vitro study evaluating the effect of ferrule design on the fracture resistance of endodontically treated mandibular premolars after simulated crown lengthening or forced eruption methods. *BMC Oral Health*. 2018; 18:83.
24. Iaculli F, Rengo C, Lodato V, Patini R, Spagnuolo G, Rengo S. Fracture resistance of Endodontically-treated maxillary premolars restored with different type of posts and direct composite reconstructions: a systematic review and meta-analysis of in vitro studies. *Dent Mater*. 2021;37:e455-e484.
25. Dietschi D, Duc O, Krejci I, et al. Biomechanical considerations for the restoration of Endodontically treated teeth: a systematic review of the literature, part II (evaluation of fatigue behavior, interfaces, and in vivo studies). *Quintessence Int (Berl)*. 2008;39:117-129.
26. Eggmann F, Ayub JM, Conejo J, Blatz MB. Deep margin elevation – present status and future directions. *J Esthet Restor Dent*. 2023;35:26-47.
27. Mannocci F, Cowie J. Restoration of endodontically treated teeth. *Br Dent J*. 2014;216:341-346.
28. Acquaviva PA, Madini L, Krokidis A, et al. Adhesive restoration of endodontically treated premolars: influence of posts on cuspal deflection. *J Adhes Dent*. 2011;13:279-286.
29. El Ghoul W, Özcan M, Silwadi M, et al. Fracture resistance and failure modes of endocrowns manufactured with different CAD/CAM materials under axial and lateral loading. *J Esthet Restor Dent*. 2019;31: 378-387.
30. Ng CC, Dumbrigue HB, Al-Bayat MI, et al. Influence of remaining coronal tooth structure location on the fracture resistance of restored endodontically treated anterior teeth. *J Prosthet Dent*. 2006;95: 290-296.
31. Ferrari M, Vichi A, Fadda GM, et al. A randomized controlled trial of endodontically treated and restored premolars. *J Dent Res*. 2012;91: 725-785.
32. Veneziani M. Adhesive restorations in the posterior area with subgingival cervical margins: new classification and differentiated treatment approach. *Eur J Esthet Dent*. 2010;5:50-76.
33. Leprince JG, Leloup G, Hardy F. The ferrule effect in molars. *The Guidebook to Molar Endodontics*. Springer; 2017:180-182.
34. Pereira JR, Neto TDM, Porto VDC, et al. Influence of the remaining coronal structure on the resistance of teeth with intraradicular retainer. *Braz Dent J*. 2005;16:197-201.
35. Fokkinga WA, Kreulen CM, Bronkhorst EM, Creugers NHJ. Up to 17-year controlled clinical study on post-and-cores and covering crowns. *J Dent*. 2007;35:778-786.
36. Fichera G, Devoto W, Re D. Cavity configurations for indirect partial-coverage adhesive-cemented restorations. *Quintessence Dent Technol*. 2006;29:55-67.
37. Bhuvu B, Giovarruscio M, Rahim N, Bitter K, Mannocci F. The restoration of root filled teeth: a review of the clinical literature. *Int Endod J*. 2021;54:509-535.
38. Uy JN, Neo JCL, Chan SH. The effect of tooth and foundation restoration heights on the load fatigue performance of cast crowns. *J Prosthet Dent*. 2010;104:318-324.
39. Padbury A Jr, Eber R, Wang HL. Interactions between the gingiva and the margin of restorations. *J Clin Periodontol*. 2003;30:379-385.
40. Malentacca A, Zaccheo F, Scialanca M, Fordellone F, Rupe C, Lajolo C. Repair of teeth with cracks in crowns and roots: an observational clinical study. *Int Endod J*. 2021;54:1738-1753.
41. Frese C, Wolff D, Staehle HJ. Proximal box elevation with resin composite and the dogma of biological width: clinical R2-technique and critical review. *Oper Dent*. 2014;39:22-31.
42. Ferrari M, Koken S, Grandini S, Ferrari Cagidiaco E, Joda T, Discepoli N. Influence of cervical margin relocation (CMR) on periodontal health: 12-month results of a controlled trial. *J Dent*. 2018; 69:70-76.

43. Flores de Jacoby L, Zafiropoulos GG, Ciancio S. Effect of crown margin location on plaque and periodontal health. *Int J Periodont Rest Dent*. 1989;9:197-205.
44. Vacek JS, Gher ME, Assad DA, Richardson AC, Giambarresi LI. The dimensions of the human dentogingival junction. *Int J Periodontics Restorative Dent*. 1994;14:154-165.
45. Gargiulo A, Wentz FM, Orban B. Dimensions and relations of the dentogingival junction in humans. *J Periodontol*. 1961;32:261-267.
46. Jepsen S, Caton JG, Albandar JM, et al. Periodontal manifestations of systemic diseases and developmental and acquired conditions: consensus report of workgroup 3 of the 2017 world workshop on the classification of periodontal and Peri-implant diseases and conditions. *J Clin Periodontol*. 2018;45:S219-S229.
47. Bertoldi G, Monari E, Cortellini P, et al. Clinical and histological reaction of periodontal tissues to subgingival resin composite restorations. *Clin Oral Investig*. 2020;24:1001-1011.
48. Ercoli C, Caton JG. Dental prostheses and tooth-related factors. *J Clin Periodontol*. 2018;45:S207-S218.
49. Aldakheel M, Aldosary K, Alnafissah S, Alaamer R, Alqahtani A, Almuhtab N. Deep margin elevation: current concepts and clinical considerations: a review. *Medicina*. 2022;58(10):1482.
50. Abad-Coronel C, Villacís Manosalvas J, Palacio Sarmiento C, Esquivel J, Loi I, Pradies G. Clinical outcomes of the biologically oriented preparation technique (BOPT) in fixed dental prostheses: a systematic review. *J Prosthet Dent*. 2022:S0022-3913(22)00488-7. doi:[10.1016/j.prosdent.2022.07.010](https://doi.org/10.1016/j.prosdent.2022.07.010)

**How to cite this article:** Fichera G, Mazzitelli C, Picciariello V, et al. Structurally compromised teeth. Part I: Clinical considerations and novel classification proposal. *J Esthet Restor Dent*. 2024;36(1):7-19. doi:[10.1111/jerd.13117](https://doi.org/10.1111/jerd.13117)