

The role of postoperative radiotherapy in eccrine porocarcinoma: a multidisciplinary systematic review

B. FIONDA¹, A. DI STEFANI², V. LANCELOTTA¹, S. GENTILESCHI^{3,4}, A.A. CARETTO⁴, C. CASÀ¹, F. FEDERICO^{5,6}, A. REMBIELAK^{7,8}, E. ROSSI⁹, A.G. MORGANTI¹⁰, G. SCHINZARI^{9,11}, K. PERIS^{2,12}, L. TAGLIAFERRI¹

¹U.O.C. Radioterapia Oncologica, Dipartimento di Diagnostica per Immagini, Radioterapia Oncologica ed Ematologia, Fondazione Policlinico Universitario A. Gemelli IRCCS, Rome, Italy

²U.O.C. Dermatologia, Dipartimento di Scienze Mediche e Chirurgiche, Fondazione Policlinico Universitario A. Gemelli IRCCS, Rome, Italy

³Dipartimento Scienze della Salute della Donna, del Bambino e di Sanità Pubblica, Unità di Chirurgia Plastica, Fondazione Policlinico Universitario A. Gemelli IRCCS, Rome, Italy

⁴Istituto di Clinica Chirurgica, Università Cattolica del Sacro Cuore, Rome, Italy

⁵Istituto di Patologia, Fondazione Policlinico Universitario A. Gemelli IRCCS, Rome, Italy

⁶Istituto di Patologia, Università Cattolica del Sacro Cuore, Rome, Italy

⁷The Christie NHS Foundation Trust, Department of Clinical Oncology, Manchester, United Kingdom

⁸The University of Manchester, Manchester, United Kingdom

⁹UOC Oncologia Medica, Comprehensive Cancer Center, Fondazione Policlinico Universitario A. Gemelli, IRCCS, Rome, Italy

¹⁰Radiation Oncology, IRCCS Azienda Ospedaliero-Universitaria di Bologna; DIMES, Alma Mater Studiorum University of Bologna, Bologna, Italy

¹¹Oncologia Medica, Università Cattolica del Sacro Cuore, Rome, Italy

¹²Istituto di Dermatologia, Università Cattolica del Sacro Cuore, Rome, Italy

Abstract. – OBJECTIVE: Eccrine porocarcinoma (EPC) is a malignant adnexal tumor accounting for about 0.005% of skin tumors. The standard treatment of EPC is the complete surgical excision of the primary lesion and of the clinically involved lymph nodes. There is limited evidence regarding the role of radiotherapy (RT) in managing EPC after surgery. Therefore, the aim of this multidisciplinary systematic review is to analyze the available evidence about postoperative RT in the curative treatment of EPC.

MATERIALS AND METHODS: A systematic search strategy was launched through the main scientific databases including PubMed, Scopus and Cochrane. An additional manual search and a chain citation were performed about potentially relevant papers. The key words used for the search included “eccrine porocarcinoma”, “porocarcinoma”, “radiotherapy”, “radiation therapy”, “adjuvant radiotherapy” and “postoperative radiotherapy”.

RESULTS: A total of 104 publications were identified and 14 papers were included in the final analysis. The only articles found on adjuvant RT in EPC were case reports published between 1996 and 2019. There was a slight female prevalence (57% female/43% male) with

a mean age of 65 years (range 37-85). Head-and-neck region was the most frequently involved anatomical site followed by legs.

CONCLUSIONS: Adjuvant radiotherapy after surgical removal of EPC could be considered in cases with positive or close margins and in cases with unfavorable histological features. In view of limited literature data and the rarity of EPC the best treatment sequence should always be discussed within the frame of a multidisciplinary setting. Advances in knowledge: adjuvant radiotherapy after surgical removal of EPC could be considered in cases with positive or close margins and in cases with unfavorable histological features.

Key Words:

Porocarcinoma, Eccrine porocarcinoma, Radiotherapy, Radiation therapy, Adjuvant radiotherapy, Postoperative radiotherapy, Systematic review, Radical treatment.

Introduction

Eccrine porocarcinoma (EPC) is a malignant adnexal tumor which was first described

by Pinkus and Mehregan¹ in 1963 and defined as “epidermotropic eccrine carcinoma”. A few years later, Mishima and Morioka² used for the first time the term “eccrine porocarcinoma”, although it is now also named as “malignant eccrine poroma”.

EPC is a rare adnexal tumor accounting for about 0.005% of skin tumors with a mean age varying from 61.5 to 73 years and no sex predilection as reported in the 2018 WHO classification^{3,4}.

EPC is clinically characterized by a nodular, polypoid or plaque, often ulcerated and rarely pigmented lesion⁵. The most frequent site is the lower limbs followed by the trunk, head/scalp, and upper limbs. Histopathological examination shows a dermal proliferation of atypical and pleomorphic poroid cells with an intraepidermal component. Moreover, areas of a pre-existing poroma can sometimes be identified.

In fact, EPC may present with at least two different pathways of cancerogenesis: i) de novo generation or ii) transform from a benign pre-existing poroma, as highlighted by some studies with long term follow-up⁶. Crucial issues about EPC are the frequently challenging clinical diagnosis and the high risk of being overlooked or misinterpreted, more frequently as squamous or even as basal cell carcinomas⁷.

EPC may be subdivided into three different subtypes according to the margins pattern: pushing, infiltrative and pagetoid. These latter are associated with the lowest, intermediate, and highest probability of relapse, respectively⁸. Both local recurrence and involvement of regional lymph nodes may occur in 20% of cases, while distant metastasis develop in 10% of patients⁹. Histopathological features correlated with more aggressive biological behavior are: larger size, tumor depth > 7 mm, infiltrating margins, and high mitotic index¹⁰.

The standard treatment of EPC is the complete surgical excision of the primary lesion and of the clinically involved lymph nodes. The recommended safety surgical margin should be at least 2 cm¹¹. Regarding the nodal management in clinically negative with adverse histological features, currently, there are no formal criteria for sentinel node biopsy even though some authors support this approach¹².

There is limited evidence regarding the role of radiotherapy (RT) in managing EPC after surgery. In particular, there is a lack of systematic reviews of the literature on this topic. Therefore, the aim of this multidisciplinary systematic review is to

analyze the available evidence about postoperative RT in the curative treatment of EPC.

Materials and Methods

A systematic search strategy was launched through the main scientific databases including PubMed, Scopus and Cochrane. An additional manual search and a chain citation were performed about potentially relevant papers. The key words used for the search included “eccrine porocarcinoma”, “porocarcinoma”, “radiotherapy”, “radiation therapy”, “adjuvant radiotherapy” and “postoperative radiotherapy”.

A first team composed by one radiation oncologist, one dermatopathologist and one plastic surgeon (BF, ADS, SG) performed the initial literature search. A second team composed by another radiation oncologist and a plastic surgeon resolved disputes about the inclusion of the single studies (VL, AAC). A third team composed by four researchers including one radiation oncologist, one pathologist and two medical oncologists (CC, FF, RE, GS) performed the manuscript drafting. Finally, a committee composed by four seniors’ researchers including radiation oncologists and dermatologists gave the final approval to the manuscript (AR, AGM, LT, KP).

The search strategy followed the PRISMA 2020 statement (Preferred Reporting Items for Systematic Reviews and Meta-Analyses: an updated guideline for reporting systematic reviews) as shown in Figure 1¹³. There were no time restrictions and only papers published in English were considered. The inclusion criteria was: original papers on adjuvant RT in EPC. Commentaries, letters and reviews were not included.

Results

A total of 104 publications were identified. After removing duplicates, 73 papers were screened and 13 were excluded having been written in languages other than English. Sixty records were assessed and 14 papers were included in the final analysis after removing reviews, commentaries and reports in which RT was not used at all or delivered with palliative purpose¹⁴⁻²⁷.

Collected data were year of publication, age, sex, site of primary lesion, lymph node involvement, information about surgery (lesion removal

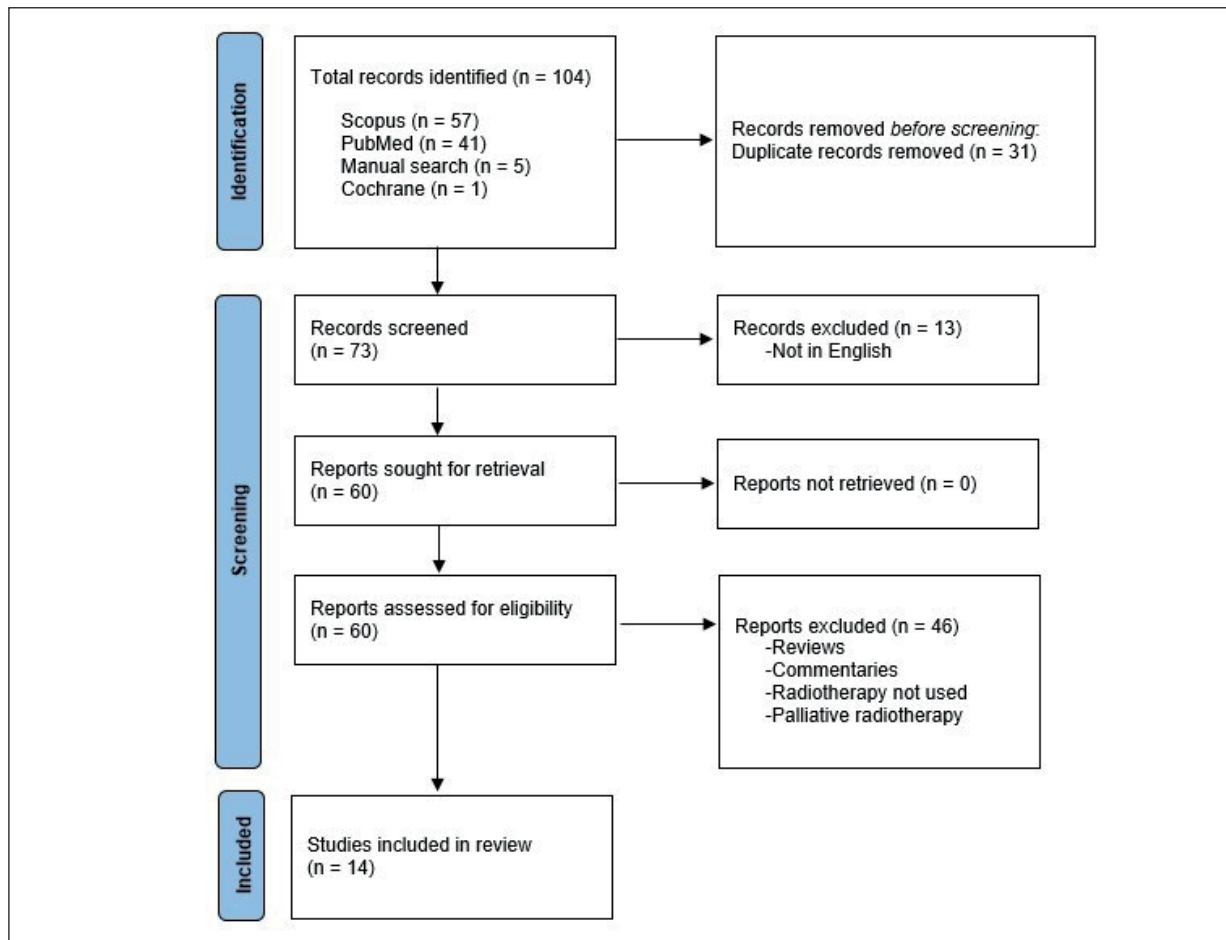


Figure 1. Search strategy.

+/- lymphadenectomy or lymph nodes excision), RT (volume, dose, technique), combined medical treatments, local control, locoregional control, distant metastases, and follow-up time.

Furthermore, only articles found on adjuvant RT in EPC were case reports published between 1996 and 2019.

Overall, there was a slight female prevalence (57% female/43% male) with a mean age of 65 years (range 37-85). Head-and-neck region was the most frequently involved anatomical site followed by legs.

Overall, in 12 out of the 14 cases some data was retrievable about pathological adverse features and/or subtype which led to the clinical decision for adjuvant RT. In particular, regarding the pathological adverse features, the most commonly reported included primary tumor with largest diameter (in 10 papers), post-operative margin status (in 5 papers), depth of invasion (in 3 papers), mitotic index (in 2 papers) and subtype (in

2 papers). A detailed summary of all findings is reported in Table I.

Discussion

A recent review by Salih et al²⁸ identified only fewer than 500 EPC cases reported in literature. Adjuvant RT could theoretically be useful in patients with lymph nodes involvement, perineural invasion, nodal extracapsular extension, positive surgical margins, high-grade histology, multi-focal disease and/or recurrent disease²⁹. However, a large retrospective analysis on 203 EPC patients from the SEER database did not report significantly improved OS in a small subgroup (4.4%) of patients treated with adjuvant RT after surgery³⁰. Currently, the available evidence on RT-treated EPC is based only on case-reports. Nevertheless, the results of our review deserve some comments.

Table I. Results of the 14 case reports included in this systematic review.

Author and Year	Age	Sex	Location	Lymph nodes involvement	Extension and timing of surgery (T and/or N)	Histopathological features and/or subtype	Irradiated site	Total dose	Radiotherapy technique	Other medical therapy	Local control	Locoregional control	Distant metastases	Follow-up
Shen et al ¹⁵ 2019	37	M	Posterior scalp	None	3 times	n.a.	Tumor Bed	24 Gy in 12 fx	n.a.	None	Yes	Yes	Yes	6 months
Lee et al ²¹ 2019	67	F	Left lower limb	Left inguinal and pelvic	Both T and N	Pagetoid subtype	Lymph node drainage	n.a.	n.a.	Sequential chemotherapy and immunotherapy (pembrolizumab)	Yes	Yes	Yes	84 months
Seo et al ²² 2019	85	M	Left cheek	Left laterocervical	Only T	T largest diameter (10 mm) Post-operative margin (5 mm)	Lymph node drainage	70 Gy in 35 fx	n.a.	None	Yes	Yes	No	14 months
Godillot et al ²⁰ 2017	64	F	Pubic	Bilateral inguinal	1 time for T and 2 times for N	T largest diameter (50 mm) Depth of invasion (39 mm) 12 mitoses/mm ²	Lymph node drainage	57,5 Gy	n.a.	Sequential chemotherapy and biological therapy (cetuximab)	Yes	Yes	Yes	24 months
Wang et al ²⁹ 2017	74	F	Scalp	Yes	Yes (but type not specified)	n.a.	Tumor Bed and lymph node drainage	60 Gy to T and 50 to N	n.a.	n.a.	n.a.	n.a.	Yes	n.a.
Fujimine-Sato et al ¹⁴ 2016	54	F	Vulva	None	Both T and N	T largest diameter (31 mm) Depth of invasion (>20 mm)	Tumor Bed and lymph node drainage	50,4 Gy in 28 fx	n.a.	Concomitant and sequential chemotherapy	Yes	Yes	Yes	12 months
Melgandi et al ²⁷ 2016	42	M	Right occipital scalp	Right laterocervical	Only T	T largest diameter (50 mm) Post-operative margin (involved)	Tumor Bed and lymph node drainage	64 Gy	n.a.	n.a.	n.a.	n.a.	n.a.	n.a.
Mishra et al ¹⁶ 2016	75	F	Vulva	Bilateral inguinal	Both T and N	T largest diameter (30 mm)	n.a.	n.a.	n.a.	n.a.	n.a.	n.a.	n.a.	n.a.
Fujimura et al ²³ 2014	85	F	Right cheek	Right laterocervical	Only T	T largest diameter (20 mm) Post-operative margin (20 mm)	Lymph node drainage	50 Gy in 5 fx	Cyberknife	None	Yes	Yes	No	12 months
Kurashige et al ²⁴ 2014	47	M	Right thigh	None	Yes (but type not specified)	Infiltrative subtype Depth of invasion (14 mm) 1.3/10 HPF	Tumor Bed	50 Gy	n.a.	None	Yes	Yes	No	48 months
Vleugels et al ¹⁹ 2012	59	F	Left forearm	Right axillary	Both T and N	Post-operative margin (free)	n.a.	54 Gy in 27 fx	n.a.	None	Yes	Yes	No	6 months
Zeidan et al ²⁵ 2010	76	M	Left temporal	None	Only T for 2 times	T largest diameter (20 mm)	Tumor Bed	60 GY in 30 fx	IMRT	None	Yes	Yes	No	10 months
Gonzalez-Lopez et al ²⁶ 2003	71	M	Right thigh	Bilateral inguinal	Both T and N	T largest diameter (40 mm)	Tumor Bed and lymph node drainage	55 Gy	Electrons	Concomitant and sequential chemotherapy	n.a.	n.a.	Yes	66 months
Katsanis et al ¹⁸ 1996	75	F	Vulva	Inguinal	Both T and N	T largest diameter (20 mm) Post-operative margin (free)	Tumor Bed and lymph node drainage	60 Gy in 30 fx	n.a.	None	Yes	Yes	No	19 months

Abbreviations used. M: Male; F: Female; T: Primary tumour; N: Nodal involvement; n.a.: Not available.

Total doses and fractionation varied significantly from 24 Gy in 12 fractions to 70 Gy in 35 fractions. This large inhomogeneity might be due to the different tumour sites, as well as the different RT techniques including electrons beams, intensity modulated RT, and cyberknife.

Interestingly, the most frequent site of primary EPC treated with postoperative RT was the scalp, despite the higher frequency of EPC in the lower limb and trunk. The greater feasibility of wider surgical resections in these latter sites, with consequent lower risk of positive or close margins, may explain the greater use of adjuvant RT in the scalp.

Overall, it can be observed that in the 14 patients included in this systematic review there were no cases of local or regional relapse. On the contrary, distant metastases were recorded in 42.8% of cases. This finding suggests the potential utility of adjuvant systemic treatments, especially in patients with multiple risk factors. In contrast, only two patients were treated with concurrent chemotherapy and only two received sequential biological therapy or immunotherapy within the analysed subjects. Furthermore, these data must be evaluated considering the short observation period of the analysed population. In fact, the duration of the follow-up was > 12 months in only six reports.

This systematic review has some limitations: i) the lack of information on the status of the surgical margins, ii) the lack of detailed description of the histopathological characteristics, and therefore of any risk factors, iii) the short observation period in the majority of patients, iv) the retrospective nature of the analysis, deriving from the design of the analysed studies (all case reports), and leading to the large inhomogeneity of used dose/fractionation. This last aspect prevents us from proposing clear recommendations on the optimal RT modalities in this setting.

Therefore, considering the low level of current evidence in this area, it is impossible to draw clear conclusions on the optimal postoperative management of the resected EPC. Similarly to Rabi et al³¹, we can only suggest discussing these patients, especially in the case of risk factors, within a multidisciplinary tumor board.

Furthermore, considering the rarity of EPC and therefore the impossibility of prospective studies, especially if monocentric, the only possible strategy to optimize the treatment of this tumor seems to collect data from different centers to share real life results, as already implemented by some authors for skin cancers³².

Conclusions

Adjuvant radiotherapy after surgical removal of EPC could be considered in cases with positive or close margins and in cases with unfavorable histological features. In view of limited literature data and the rarity of EPC the best treatment sequence should always be discussed within the frame of a multidisciplinary setting.

Conflict of Interest

The authors have declared no conflict of interest.

References

- 1) Pinkus H, Mehregan AH. Epidermotropic eccrine carcinoma. A case combining features of eccrine poroma and paget's dermatosis. *Arch Dermatol* 1963; 88: 597-606.
- 2) Mishima Y, Morioka S. Oncogenic differentiation of the intraepidermal eccrine sweat duct: eccrine poroma, poroepithelioma and porocarcinoma. *Dermatologica* 1969; 138: 238-250.
- 3) Craig PJ. An Overview of Uncommon Cutaneous Malignancies, Including Skin Appendageal (Adnexal) Tumours and Sarcomas. *Clin Oncol (R Coll Radiol)* 2019; 31: 769-778.
- 4) Kazakov DV, Argenyi ZB, Brenn T et al. Porocarcinoma. In: WHO Classification of Skin Tumours. 4th edn. Elder DE, Massi D, Scolyer RA, Willemze R. Ed. Lyon, France: International Agency for Research on Cancer; 2018.
- 5) Wick MR, Goellner JR, Wolfe JT 3rd, Su WP. Adnexal carcinomas of the skin. I. Eccrine carcinomas. *Cancer* 1985; 56: 1147-1162.
- 6) Pylyser K, De Wolf-Peeters C, Marien K. The histology of eccrine poromas: a study of 14 cases. *Dermatologica* 1983; 167: 243-249.
- 7) Gerber PA, Schulte KW, Ruzicka T, Bruch-Gerharz D. Eccrine porocarcinoma of the head: an important differential diagnosis in the elderly patient. *Dermatology* 2008; 216: 229-233.
- 8) Belin E, Ezzedine K, Stanislas S, Lalanne N, Beylot-Barry M, Taieb A, Vergier B, Jouary T. Factors in the surgical management of primary eccrine porocarcinoma: prognostic histological factors can guide the surgical procedure. *Br J Dermatol* 2011; 165: 985-989.
- 9) Xu YG, Aylward J, Longley BJ, Hinshaw MA, Snow SN. Eccrine Porocarcinoma Treated by Mohs Micrographic Surgery: Over 6-Year Follow-up of 12 Cases and Literature Review. *Dermatol Surg* 2015; 41: 685-692.
- 10) Robson A, Greene J, Ansari N, Kim B, Seed PT, McKee PH, Calonje E. Eccrine porocarcinoma (malignant eccrine poroma): a clinicopathologic study of 69 cases. *Am J Surg Pathol* 2001; 25: 710-720.

- 11) Worley B, Owen JL, Barker CA, Behshad R, Bichakjian CK, Bolotin D, Bordeaux JS, Bradshaw S, Cartee TV, Chandra S, Cho N, Choi J, Council ML, Eisen DB, Golda N, Huang CC, Ibrahim SF, Jiang SIB, Kim J, Lacouture M, Lawrence N, Lee EH, Leitenberger JJ, Maher IA, Mann M, Minkis K, Mittal B, Nehal KS, Neuhaus I, Ozog DM, Petersen B, Samie F, Shin TM, Sobanko JF, Somani AK, Stebbins WG, Thomas JR, Thomas V, Tse D, Waldman A, Xu YG, Yu SS, Zeitouni NC, Ramsay T, Poon E, Alam M. Evidence-Based Clinical Practice Guidelines for Microcystic Adnexal Carcinoma: Informed by a Systematic Review. *JAMA Dermatol* 2019; 155: 1059-1068.
- 12) Martinez SR, Barr KL, Canter RJ. Rare tumours through the looking glass: an examination of malignant cutaneous adnexal tumours. *Arch Dermatol* 2011; 147: 1058-1062.
- 13) Page MJ, McKenzie JE, Bossuyt PM, Boutron I, Hoffmann TC, Mulrow CD, Shamseer L, Tetzlaff JM, Akl EA, Brennan SE, Chou R, Glanville J, Grimshaw JM, Hróbjartsson A, Lalu MM, Li T, Loder EW, Mayo-Wilson E, McDonald S, McGuinness LA, Stewart LA, Thomas J, Tricco AC, Welch VA, Whiting P, Moher D. The PRISMA 2020 statement: an updated guideline for reporting systematic reviews. *BMJ* 2021; 372: n71.
- 14) Fujimine-Sato A, Toyoshima M, Shigeta S, Toki A, Kuno T, Sato I, Watanabe M, Niikura H, Yaegashi N. Eccrine porocarcinoma of the vulva: a case report and review of the literature. *J Med Case Rep* 2016; 10: 319.
- 15) Shen J, Pan X, Lu Y, Pan D, Ma Y, Zhan R. A case of eccrine porocarcinoma characterized by a progressive increase in the level of Ki-67 index: case report and review of literature. *BMC Surg* 2019; 19: 142.
- 16) Mishra P, Sen S, Sharma N, Sen D. Malignant Eccrine Poroma of the Vulva: An Intriguing Case of a Rare Tumour at an Unusual Site. *Indian J Dermatol* 2016; 61: 430-432.
- 17) Wang LS, Handorf EA, Wu H, Liu JC, Perlis CS, Galloway TJ. Surgery and Adjuvant Radiation for High-risk Skin Adnexal Carcinoma of the Head and Neck. *Am J Clin Oncol* 2017; 40: 429-432.
- 18) Katsanis WA, Doering DL, Bosscher JR, O'Connor DM. Vulvar eccrine porocarcinoma. *Gynecol Oncol* 1996; 62: 396-399.
- 19) Vleugels FR, Girouard SD, Schmults CD, Ng AK, Russell SE, Wang LC, Buzney EA. Metastatic eccrine porocarcinoma after Mohs micrographic surgery: a case report. *J Clin Oncol* 2012; 30: e188-191.
- 20) Godillot C, Boulinguez S, Riffaud L, Sibaud V, Chira C, Tournier E, Paul C, Meyer N. Complete response of a metastatic porocarcinoma treated with paclitaxel, cetuximab and radiotherapy. *Eur J Cancer* 2018; 90: 142-145.
- 21) Lee KA, Cioni M, Robson A, Bataille V. Metastatic porocarcinoma achieving complete radiological and clinical response with pembrolizumab. *BMJ Case Rep* 2019; 12: e228917.
- 22) Seo BF, Choi HJ, Jung SN. Eccrine porocarcinoma on the cheek. *Arch Craniofac Surg* 2019; 20: 48-50.
- 23) Fujimura T, Hashimoto A, Furudate S, Kambayashi Y, Haga T, Aiba S. Successful Treatment of Eccrine Porocarcinoma Metastasized to a Cervical Lymph Node with CyberKnife Radiosurgery. *Case Rep Dermatol* 2014; 6: 159-163.
- 24) Kurashige Y, Minemura T, Nagatani T. Eccrine porocarcinoma: clinical and pathological report of eight cases. *Case Rep Dermatol* 2013; 5: 259-266.
- 25) Zeidan YH, Zauls AJ, Bilic M, Lentsch EJ, Sharma AK. Treatment of eccrine porocarcinoma with metastasis to the parotid gland using intensity-modulated radiation therapy: a case report. *J Med Case Rep* 2010; 4: 147.
- 26) González-López MA, Vázquez-López F, Soler T, Gómez-Diéz S, Garcia YH, Manjón JA, López-Escobar M, Pérez-Oliva N. Metastatic eccrine porocarcinoma: a 5.6-year follow-up study of a patient treated with a combined therapeutic protocol. *Dermatol Surg* 2003; 29: 1227-1132.
- 27) Melgandi W, Benson R, Hakin A, Bhasker S. Porocarcinoma scalp with high risk features treated with surgery and adjuvant radiotherapy: A case report and review of literature. *J Egypt Natl Canc Inst* 2016; 28: 195-198.
- 28) Salih AM, Kakamad FH, Baba HO, Salih RQ, Hawbash MR, Mohammed SH, Othman S, Saeed YA, Habibullah IJ, Muhiyaldeen AS, Nawroly RO, Hammood ZD, Abdulkarim NH. Porocarcinoma: presentation and management, a meta-analysis of 453 cases. *Ann Med Surg (Lond)* 2017; 20: 74-79.
- 29) Wang LS, Handorf EA, Wu H, Liu JC, Perlis CS, Galloway TJ. Surgery and Adjuvant Radiation for High-risk Skin Adnexal Carcinoma of the Head and Neck. *Am J Clin Oncol* 2017; 40: 429-432.
- 30) Avraham JB, Villines D, Maker VK, August C, Maker AV. Survival after resection of cutaneous adnexal carcinomas with eccrine differentiation: risk factors and trends in outcomes. *J Surg Oncol* 2013; 108: 57-62.
- 31) Rabi S, Syder N, Ragab O, In G, Hu JC. Rapidly Progressive Porocarcinoma of the Ear and Multidisciplinary Approach to Management. *Dermatol Surg* 2021; 47: 404-406.
- 32) Lancellotta V, Guinot JL, Fionda B, Rembielak A, Di Stefani A, Gentileschi S, Federico F, Rossi E, Guix B, Chyrek AJ, Meritxell A, Villalba SR, Colloca GF, Dinapoli N, Masciocchi C, Lenkiewicz J, Capocchiano ND, Damiani A, Valentini V, Kovács G, Tagliaferri L. SKIN-COBRA (Consortium for Brachytherapy data Analysis) ontology: The first step towards interdisciplinary standardized data collection for personalized oncology in skin cancer. *J Contemp Brachytherapy* 2020; 12: 105-110.