



ALMA MATER STUDIORUM
UNIVERSITÀ DI BOLOGNA

ARCHIVIO ISTITUZIONALE DELLA RICERCA

Alma Mater Studiorum Università di Bologna Archivio istituzionale della ricerca

Description of the most severe signs in nail lichen planus: a strategy to contribute to the diagnosis of the severe stage

This is the final peer-reviewed author's accepted manuscript (postprint) of the following publication:

Published Version:

Ceccarelli MA, G.M. (2022). Description of the most severe signs in nail lichen planus: a strategy to contribute to the diagnosis of the severe stage. INTERNATIONAL JOURNAL OF DERMATOLOGY, 61(9), 1124-1130 [10.1111/ijd.16167].

Availability:

This version is available at: <https://hdl.handle.net/11585/902973> since: 2022-11-15

Published:

DOI: <http://doi.org/10.1111/ijd.16167>

Terms of use:

Some rights reserved. The terms and conditions for the reuse of this version of the manuscript are specified in the publishing policy. For all terms of use and more information see the publisher's website.

This item was downloaded from IRIS Università di Bologna (<https://cris.unibo.it/>).
When citing, please refer to the published version.

(Article begins on next page)

This is the final peer-reviewed accepted manuscript of:

Ceccarelli MA, Gavilanes-Coloma MC, D'almeida L, Azulay D, Iorizzo M, Starace M, Haneke E, Nakamura RC.

Description of the most severe signs in nail lichen planus: a strategy to contribute to the diagnosis of the severe stage.

Int J Dermatol. 2022 Sep; 61(9): 1124-1130.

The final published version is available online at: [10.1111/ijd.16167](https://doi.org/10.1111/ijd.16167)

Terms of use:

Some rights reserved. The terms and conditions for the reuse of this version of the manuscript are specified in the publishing policy. For all terms of use and more information see the publisher's website.

This item was downloaded from IRIS Università di Bologna (<https://cris.unibo.it/>)

When citing, please refer to the published version.

Title: Description of the most severe signs in nail lichen planus: A strategy to contribute to the diagnosis of the severe stage.

Authors:

Miguel A Ceccarelli, MD^{1,2}, Maria C Gavilanes-Coloma, MD¹, Luiza D'almeida, MD¹, David Azulay, MD, PhD¹, Matilde Iorizzo, MD, PhD³, Michela Starace, MD, PhD⁴, Eckart Haneke, MD, PhD^{5,6,7,8}, Robertha C Nakamura, MD, MSc^{1,2}

¹Nail Studies Center, Instituto de Dermatologia Professor Rubem David Azulay, Hospital Geral da Santa Casa da Misericórdia do Rio de Janeiro, Rio de Janeiro.

²Nail Diseases Outpatient Clinic, Department of Dermatology, Hospital Universitário Pedro Ernesto, Universidade do Estado do Rio de Janeiro (HUPE-UERJ), Rio de Janeiro, RJ, Brazil.

³Private Dermatology Practice, Bellinzona, Switzerland.

⁴Department of Specialised Experimental and Diagnostic Medicine, Dermatology, Alma Mater Studiorum, Università di Bologna, Bologna, Italy

⁵Department of Dermatology, Inselspital, University of Bern, Bern, Switzerland.

⁶Dermatology Practice Dermaticum, Freiburg, Germany.

⁷Centro Dermatología Epidermis, Inst CUF, Senhora da Hora, Grande Porto, Portugal.

⁸Department of Dermatology, University Hospital, Gent, Belgium.

Corresponding author:

Miguel A. Ceccarelli, MD

Instituto de Dermatologia Professor Rubem David Azulay
Hospital Geral da Santa Casa da Misericórdia do Rio de Janeiro
Rua Santa Luzia 206, Centro, Rio de Janeiro, Brazil.

Email: miguelceccarelli@hotmail.com

Telephone: +5521991387318

Figures: 5

Tables: 1

Funding sources: None

Conflicts of Interest: All authors declare that they have no conflict of interest

Running Head: Nail lichen planus

Keywords: dermoscopy, onychoscopy, nail lichen planus, onychoatrophy, dorsal pterygium, anonychia

Abstract

Background: Severe nail lichen planus does not respond well to treatment and is often poorly considered and described in detail.

Objective: We sought to describe the characteristics of severe NLP.

Methods: A retrospective data analysis was performed, including the photographic records of the most compromised nail of patients with NLP over 18 years old, who consulted between 2009 and 2019 the Instituto de Dermatologia Professor Rubem David Azulay in Rio de Janeiro, Brazil. Descriptive and statistical analysis using Fisher's exact test was performed to verify the hypothesis of independence between characteristics ($p < 0.05$).

Results: A total of 102 patients were included. Anonychia was associated with severe thinning of the nail plate, retraction of the nail bed or nail plate, residual nail plate, loss of proximal nail fold limits, and onychotrophy. Dorsal pterygium was associated with loss of proximal nail fold limits, onychotrophy and distal splitting greater than 50%.

Conclusion: We provide descriptions of the most severe signs in order to facilitate the clinical diagnosis when a biopsy is not feasible, and suggest an update of current NLP classifications.

Introduction:

Lichen planus (LP) is an inflammatory disease that can affect the skin, mucous membranes and appendages. It is a disease of low and variable prevalence, reported between 0.5 to 1% of the population. Nail lichen planus (NLP) affects 10% of patients with skin, scalp or mucosal involvement, but it can both be the first manifestation of the disease, as well as the only form of presentation. The isolated form is rather uncommon and represents about 2% of all nail disorders.¹ The nails of the hands are more frequently affected than those of the feet, mostly affecting people in the fifth decade of life.²

NLP diagnosis is mainly clinical, but diagnostic confirmation with histopathological analysis is recommended, especially in early-stage patients, being mandatory for monodactylous NLP.^{3,4,5} In recent years, dermoscopy has emerged as a useful non-invasive imaging tool, used at the time of physical examination of the nails, allowing a more careful assessment of NLP signs.⁶ The manifestations of NLP are typical and suggestive of the disease in most patients and depend on the time of diagnosis and the affected anatomical site, including the matrix (proximal and distal), nail bed and in some cases, the periungual tissues.⁷

The involvement of the nail matrix leads to changes of the lunula and the production of the nail plate, initially evidenced by onychorrhexis and distal splitting. Subsequently, crumbling of the nail plate and formation of a longitudinal fissure may appear. Other findings of matrix involvement have been described, such as nail plate thinning, pigmentary alterations, erythronychia, pitting and trachyonychia.^{2,5,8,9} Other findings described by Kharghoria et al. and Grover et al. such as nail bed dyschromia and lunula changes, such as stippled erythema, homogeneous erythema, flame-shaped lunula or yellow lunula exist.³ Onychomadesis can also occur. Nail bed involvement can be associated with onycholysis, splinter hemorrhages and mild subungual hyperkeratosis.^{2,5}

1
2
3 Some signs reflect involvement of both nail bed and nail matrix, such as dorsal pterygium,
4
5
6
7
8
9 almost exclusively detected by dermoscopy).⁷

10
11
12
13
14
15
16
17
18
19
20
21
22
23
24
25
26
27
28
29
30
31
32
33
34
35
36
37
38
39
40
41
42
43
44
45
46
47
48
49
50
51
52
53
54
55
56
57
58
59
60
About 20% of patients eventually develop dorsal pterygium, which is the irreversible
destruction of the nail matrix with a "v"-shaped extension of the proximal nail fold. About
1.3% of patients develop onychia, or complete loss of the nail, due to scarring. Most
features described above make it difficult to differentiate NLP from psoriasis, except for
the presence of dorsal pterygium that is highly suggestive of severe NLP.⁷

Two NLP classification systems are known. Gavilanes-Coloma et al.¹⁰ presented a
proposal for a clinical classification of the disease, consisting of a: 1) initial phase (red
lunula, pitting, onycholysis, onychorrhexis and paronychia); 2) evolutionary phase
(including longitudinal splitting, longitudinal erythronychia, trachyonychia, subungual
hyperkeratosis, melanonychia, fragmentation of the dorsum of the nail plate, convergence
of the longitudinal streaks to the center of the nail apparatus, splinter hemorrhages,
proximal leukonychia and onychomadesis); and 3) an aggressive phase (severe thinning
of the plaque, nail pterygium, onychia). The most recent classification was presented
by Iorizzo et al.¹¹ on the 2020 Nail Expert Consensus for Isolated NLP treatment, defining
NLP stages as: 1) mild: Thinning, longitudinal ridging, distal splitting less than 3 mm in
length, onycholysis less than 25%, without hyperkeratosis in the nail bed; 2) moderate:
Partial fissuring, longitudinal ridgings, distal splitting between 3 and 5 mm, onycholysis
between 25% and 50%, erythema in spots of the lunula and subungual hyperkeratosis);
and 3) severe: Complete fissuring, deep longitudinal ridgings, splitting greater than 5 mm,
onycholysis greater than 50%, diffuse erythema of the lunula.

1
2
3 Evidence on features and classification of NLP remains scarce, but has helped identify
4 involvement in a significantly larger number of nails as compared to clinical examination
5 alone.³ In this study, we sought to provide data for an updated classification for the severe
6 stage of NLP, based on the characteristics of patients with NLP and its relation to
7
8
9
10
11
12
13 anonychia and dorsal pterygium.

14 **Methods:**

15
16
17 A retrospective data analysis including NLP patients evaluated at the Nail Studies Center
18 of the Instituto de Dermatologia Professor Rubem David Azulay from the Santa Casa da
19 Misericórdia of Rio de Janeiro General Hospital from 2009 to 2019 was performed. We
20 included all patients aged over 18 years with a diagnosis of nail lichen planus, from a
21 database of medical records and patients' photographs including both hands and feet,
22 taken with a digital camera, as well as the dermoscopy of every digit (all 20 nails), and
23 excluded patients with any other previous nail disease. We selected the most
24 compromised nail of each participant, and then described the presence of 32
25 characteristics and epidemiological data. Descriptive analysis and statistical analysis
26 using Fisher's exact test was performed to verify the hypothesis of independence for
27 variables at a 5% significance level, between characteristics.
28
29
30
31
32
33
34
35
36
37
38
39
40
41

42 **Results:**

43
44 A total of 102 patients were included in the study. Three presented extra-ungual
45 involvement: lichen planopilaris, cutaneous lichen planus of the abdomen and lichen
46 planus of the extremities. None of them had NLP with associated oral or genital lichen
47 planus. Men (52%) were almost equally affected as women (48%). The mean age of the
48 patients was 45.5 ± 13.9 years (age range from 18 to 85 years) and 84.9% of the sample
49 was over 30 years old. The most commonly affected nail was present on patients' fingers
50 (71%) in comparison to toes (21%). First digits were most frequently affected (46,1%):
51
52
53
54
55
56
57
58
59
60

1
2
3 30,8% when affecting a thumb and 15,3% when a hallux. A total of 76 patients (74,5%)
4
5 had at least one characteristic associated with anonychia or dorsal pterygium.
6
7

8 **Clinical-dermoscopic findings**

9
10 In this study, 32 clinical-dermoscopic features were found, and classified according to the
11
12 affected nail component. These features were divided into 4 groups according to the
13
14 affected component of the nail apparatus: matrix, bed, mixed involvement of matrix and
15
16 bed, and periungual tissues, as well as classified according to how they were better
17
18 observed (Table 1).
19
20

21 **Anonychia and dorsal nail pterygium analysis**

22
23 It was first verified whether anonychia (Fig. 1) and nail pterygium (Fig. 2) were
24
25 independent variables (p-value of 0.381).
26
27

28 **Nail matrix**

29
30 Fourteen features were classified as changes of the nail matrix. The most frequent finding
31
32 was the presence of retraction of the nail plate (73.5%), followed by crumbling or
33
34 fragmentation of the dorsum or surface of the nail plate (67.6%), and onychorrhexis
35
36 (66.7%), followed by nail pitting (48%), onychoschizia (46.1%), proximal leukonychia
37
38 (46.1%) severe thinning of the nail plate (44.1%), yellowish chromonychia (39.2%),
39
40 erythronychia (35.3%), irregular lunula (25.5%), presence of distal splitting (23.5%),
41
42 onycholysis (23.5%), reddish lunula (17.6%) and trachyonychia (9.8%). No patient had
43
44 less than three or more than twelve of those characteristics. No patients with
45
46 onychomadesis were observed. We found a strong association between anonychia and
47
48 severe thinning of the nail plate ($p < 0.001$).
49
50
51

52
53 A quantitative assessment was performed for the nail plate retraction (retraction involving
54
55 only the nail plate and not the nail bed) and distal splitting percentages, showing an
56
57 average of $35.5\% \text{ CI} \pm 7.1$ and $36,77\% \pm 13.43$ respectively. Distal splitting was divided
58
59
60

1
2
3 in three groups as well: 10 (9,8%) participants presented less than 25%, 7 (6,9%) between
4
5 25% and 50%, and 7 (6,9%) more than 50%. We found an association between the
6
7 presence of retraction of the nail plate (Fig. 3) and anonychia ($p=0.019$), confirmed by an
8
9 even stronger association when analyzing a nail plate retraction greater than 50%
10
11 ($p<0.001$). We found a strong association between distal splitting and onycholysis
12
13 ($p<0.001$), and between dorsal pterygium and distal splitting greater than 50% ($p<0.008$).
14
15

16 17 **Nail bed**

18
19 Six characteristics were considered as nail bed changes. The presence of nail bed
20
21 retraction (also called disappearing nail bed)¹² was the most frequent feature (74.5%),
22
23 followed by nail bed erythema (63.7%) and nail bed spotted erythronychia (61.8%). A
24
25 quantitative assessment was performed for onycholysis percentage $47,3\% \pm 12.4$.
26
27 Onycholysis percentage was then divided into three groups: 3 (2,9%) participants
28
29 presented less than 25%, 11 (10,8%) between 25% and 50%, and 10 (9,8%) more than
30
31 50%. Other variables present were splinter hemorrhages (36.3%), and finally, subungual
32
33 hyperkeratosis (4.9%). Additionally, a quantitative assessment of the bed retraction was
34
35 performed, including a variable describing the percentage of nail bed retraction (Fig. 3),
36
37 with an average of $24.7\% \text{ CI} \pm 5.6$. No patient had all six studied features. We found a
38
39 significant p value for the association between the presence of anonychia and the presence
40
41 of nail bed retraction ($p=0.033$). Nail bed retraction greater than 50% and anonychia
42
43 presented a stronger association ($p<0.001$).
44
45
46
47
48

49 **Mixed involvement of the nail matrix and nail bed**

50
51 The most frequent findings were the convergence of the longitudinal streaks to the center
52
53 of the nail apparatus (66.7%), onychotrophy (50%) and hapalonychia (47.1%). Other
54
55 changes were melanonychia (26.5%), residual nail plate (20.6%), anonychia (11.8%),
56
57 bulge / pup tent (Fig 4, 10.8%), single dorsal pterygium (8.8%) and multiple dorsal
58
59
60

1
2
3 pterygium (2%), being the latter grouped in a variable called dorsal pterygium (10.8%).
4
5 No participants had more than five of those eight characteristics. Anonychia was
6
7 associated with residual nail plate, presenting a significant p value (0.016). We found a
8
9 significant p value for the association between the presence of pterygium and
10
11 onychotrophy (p=0.004), as well as between anonychia and onychotrophy (p=0.002)
12
13

14 **Periungual tissues**

15
16 Loss of the limits of a nail fold was the most frequent finding (79.4%), and represented
17
18 the partial or total disruption of a nail fold, where it is impossible to distinguish between
19
20 this structure and the nail bed or skin around it. Each individual nail fold involvement
21
22 was described: the loss of the limits of the distal groove (71.6%), loss of the limits of the
23
24 lateral folds (67.6%), and less frequently the loss of the limits of the proximal fold
25
26 (20.6%). Other findings were paronychia (21.6%), periungual hemorrhage (14.7%) and
27
28 pulpitis (10.8%). The average value of the number of features that affected the
29
30 perionychium was 1.27. All characteristics were not associated with nail pterygium or
31
32 anonychia, except for the loss of nail proximal fold limits for both features (p <0.001).
33
34
35
36

37 **Discussion**

38
39 Most of the epidemiological data was in agreement with the literature, being a disease
40
41 with similar frequencies between men and women. Participants' ages from our study
42
43 show a higher prevalence peak between the 30 to 50-year age groups, whereas the
44
45 literature described a higher prevalence in older patients. A recent study from Kharghoria
46
47 et al. described an even younger mean age (36.9 years). Likewise, a higher prevalence
48
49 was found in patients with lower Fitzpatrick skin type, more frequently II and III,
50
51 probably due to access to an outpatient specialized clinic on nail diseases, which
52
53 represents a barrier to healthcare for the population with lower income and higher
54
55 Fitzpatrick types. We observed a greater amount of severely affected fingers compared to
56
57
58
59
60

1
2
3 toes, the first digit being the most commonly affected, which is still debatable, since this
4 analyzed sample represents the participants' digit with the most severe involvement only.
5
6 Almost all of our participants had isolated nail lichen planus only, which differ to other
7
8 studies. Most of the characteristics were better addressed when using the dermoscope. On
9
10 our point of view, only three findings were better addressed using clinical pictures:
11
12 Hapalonychia, pulpitis and paronychia.
13
14
15

16 **Characteristics assessed according to affected nail component**

17
18 The description of those categories was reviewed by Goettmann et al. and Chiheb et al.
19
20 (nail matrix and nail bed), Nakamura et al. and Gavilanes-Coloma et al. (both including
21
22 nail matrix, nail bed, combined matrix and bed involvement, and perionychium) and by
23
24 Kharghoria et al. (nail matrix, nail bed and nail fold). Our results were different when
25
26 compared to other studies, where higher frequencies of other features exist, such as
27
28 pitting, trachyonychia, chromonychia, and onycholysis, subungual hyperkeratosis,
29
30 among others. Irregular lunula was the most frequent alteration of the lunula, followed by
31
32 reddish or erythematous lunula. All those findings could be explained based on our higher
33
34 proportion of participants with more advanced stages. Nail bed dyschromia, nail fold
35
36 papules, prominent hyponychial vascular structures and lunula variants, such as stippled
37
38 erythema, homogeneous erythema, flame-shaped lunula or yellow lunula were not
39
40 included.^{13, 14,15, 16, 17}
41
42
43
44
45

46
47 Studies on Asian and Indian participants showed higher melanonychia frequencies and
48
49 oral involvement when comparing to our study, probably due to the genetic profile of the
50
51 Brazilian population.^{13, 14,15, 16, 18}
52
53

54
55
56 Characteristics assessed according to variables without therapeutic response and its
57
58 importance for an aggressive therapeutic approach
59
60

1
2
3 Anonychia and dorsal nail pterygium are classically described as cicatricial features in
4 the literature, and it is vitally important to carry out early and aggressive treatment to
5 prevent progression to those features. A previous stage to dorsal nail pterygium, appears
6 as a nail fold bulge (Fig. 4) and is often accompanied by the pup-tent sign, occurring when
7 the nail plate splits, elevates longitudinally, and the lateral edges angle downward.^{19, 20}

8
9
10
11
12
13
14 As already described in the results, we found an association between anonychia and: 1)
15 severe thinning of the nail plate, 2) presence of retraction of the nail bed, 3) presence of
16 retraction of the nail plate, 4) onychoatrophy, 5) residual nail plate and 6) loss of proximal
17 nail fold limits.

18
19
20
21
22
23
24 These findings are compatible with the severe stage, since in anonychia, severe thinning
25 of the nail plate evolves into a residual and scaly nail plate until it finally disappears. This
26 was already mentioned in the proposal by Gavilanes-Coloma et al. The retraction of the
27 nail bed and nail plate are both involved in the process that leads to anonychia. The loss
28 of the proximal fold and onychoatrophy occur on latter stages seen in cases of greater
29 severity.

30
31
32
33
34
35
36
37
38
39 In the case of dorsal pterygium, we found an association of this finding with: 1) loss of
40 the limits of the proximal fold, 2) onychoatrophy and 3) distal splitting greater than 50%.
41 Some p values were close to be significant: presence of retraction of the nail bed greater
42 than 50%, presence of onycholysis and presence of distal splitting. We had some
43 difficulties when performing the quantitative assessment of onycholysis, since most
44 patients had a fragmented or absent nail plate, instead of just a detached one from the nail
45 bed. This represents a challenge when describing percentages, since the characteristics
46 are usually objectively difficult to describe in the most severe cases. Distal splitting was
47 described regardless of its size, using percentages instead, since anatomical differences
48 exist and defining a specific number may not be adequate to all individuals, which could
49
50
51
52
53
54
55
56
57
58
59
60

1
2
3 lead to bias. Onychorrhexis addressed the presence of any type of longitudinal grooves,
4
5 which eventually evolved into fissures, and this was not associated with anonychia or
6
7 distal pterygium.
8
9

10 **Limitations**

11
12 Since this is a retrospective study, from a consultation specialized on nail diseases, with
13
14 a limited number of samples and the absence of some data in the clinical records of the
15
16 participants, such as the duration of the condition and histopathological data, the selected
17
18 sample may not be representative of the population studied.
19
20

21 **Conclusions**

22
23 This retrospective study has the largest number of patients and characteristics evaluated
24
25 by means of clinical evaluation and dermoscopy, and provides data of the most severe
26
27 signs in order to help the clinical diagnosis when biopsy is not feasible. Based on our
28
29 findings, we suggest, in an exploratory manner, an update of the severe stage, including
30
31 both non-responsive and responsive to treatment signs, to alert clinicians that an
32
33 aggressive treatment approach is needed to avoid ending up in this stage. Suggested
34
35 characteristics to include are (Fig. 5): 1) Severe thinning of the nail plate, 2) nail plate or
36
37 nail bed retraction, 3) onychotrophy, 4) residual nail plate, 5) loss of proximal fold limits
38
39 and 6) distal splitting greater than 50%. Suggested features to be removed are: 1) complete
40
41 fissures, 2) deep longitudinal ridgings, 3) diffuse erythema of the lunula, 4) distal splitting
42
43 greater than 5 mm, and 5) onycholysis greater than 50%. Thus, we found it difficult to
44
45 find adequate and objective parameters to classify this disease and to serve as a reference
46
47 for making a better diagnosis of the most severe stage. Further prospective studies should
48
49 be carried out to assess these findings.
50
51
52
53
54
55
56
57
58
59
60

Acknowledgments:

The patients in this manuscript have given written informed consent to publication of their case details. IRB approval status: Reviewed and approved by Hospital Federal Cardoso Fontes IRB – Plataforma Brasil; approval code CAAE 30100919.5.0000.8066.

Figure legends:

Figure 1. Anonychia.

Figure 2. Dorsal pterygium.

Figure 3. Nail plate retraction (black line) and nail bed retraction "Disappearing nail bed" (white line).

Figure 4. Bulge.

Figure 5. Suggested updated severe stage for NLP.

Table legends:

Table 1. Nail unit signs of 102 patients affected by severe Nail Lichen Planus

References

1. Samman PD. The nails in lichen planus. *Br J Dermatol* 1961;73:288—92.
2. Goettman S, Zaraa I, Moulonguet I. Nail lichen planus: epidemiological, clinical, pathological, therapeutic and prognosis study of 67 cases. *J Eur Acad Dermatol Venereol*. 2012 Oct;26(10):1304-9.
3. Kharghoria G, Grover C, Bhattacharya SN. Nail dermatoscopic (onychosopic) features of nail lichen planus: A cross-sectional study. *Australas J Dermatol*. 2021 Feb;62(1):e79-e82. doi: 10.1111/ajd.13454. Epub 2020 Sep 11. PMID: 32915474.
4. André J, Moulonguet I, Goettmann-Bonvallot S. In situ amelanotic melanoma of the nail unit mimicking lichen planus. *Arch Dermatol* 2010;146:418-21.
5. Tosti A, Peluso A. M., Fanti P. A., & Piraccini B. M. (1993). Nail lichen planus: Clinical and pathologic study of twenty-four patients. *Journal of the American Academy of Dermatology*, 28(5), 724–730. doi:10.1016/0190-9622(93)70100-8.
6. Alessandrini A, Starace M, Piraccini BM. Dermoscopy in the evaluation of nail disorders. *Skin Appendage Disord* 2017;3:70-82.
7. Nakamura R, Broce AA, Palencia DP, Ortiz NI, Leverone A. Dermoscopy of Nail Lichen Planus. *Int J Dermatol*. 2013 Jun;52(6):684-687.
8. Kaur I, Jakhar D. Intraoperative onychoscopy and histopathological correlation of red lunula in nail lichen planus: a case series [published online ahead of print, 2020 May 1]. *Clin Exp Dermatol*. 2020;10.1111/ced.14265. doi:10.1111/ced.14265.
9. Żychowska M, Żychowska M. Nail Changes in Lichen Planus: A Single-Center Study. *J Cutan Med Surg*. 2021 May-Jun;25(3):281-285. doi: 10.1177/1203475420982554. Epub 2020 Dec 18. PMID: 33336579.
10. Gavilanes-Coloma MC. Evaluation of clinical dermoscopic findings in nail lichen planus: Proposal for a new classification. (2017). *J Am Acad Dermatol*. 76(6), AB128. doi:10.1016/j.jaad.2017.04.501.
11. Iorizzo M, Tosti A, Starace M, et al. Isolated Nail Lichen planus - an expert consensus on treatment of the classical form [published online ahead of print, 2020 Feb 26]. *J Am Acad Dermatol*. 2020;S0190-9622(20)30300-5. doi:10.1016/j.jaad.2020.02.056.
12. Daniel R, Meir B, Avner S. An Update on the Disappearing Nail Bed. *Skin Appendage Disord*. 2017 Mar;3(1):15-17. doi: 10.1159/000455013. Epub 2017 Jan 6. PMID: 28611995; PMCID: PMC5465661.

13. Chiheb S, et al. Clinical characteristics of nail lichen planus and follow-up: a descriptive study of 20 patients. *Ann Dermatol Venereol* 2015;142:21-5.
14. Gupta MK, Lipner SR. Review of Nail Lichen Planus: Epidemiology, Pathogenesis, Diagnosis, and Treatment. *Dermatol Clin*. 2021 Apr;39(2):221-230. doi: 10.1016/j.det.2020.12.002. Epub 2021 Feb 10. PMID: 33745635.
15. Grover C, Kharghoria G, Bhattacharya SN. Linear nail bed dyschromia: a distinctive dermoscopic feature of nail lichen planus. *Clin Exp Dermatol* 2019; 44: 697–699.
16. Sharma S, Kaur J, Bassi R, Sekhon HK. Dermatoscopy of Nail Lichen Planus: A Boon for Early Diagnosis. *J Clin Aesthet Dermatol*. 2021 Jul;14(7):34-37. Epub 2021 Jul 1. PMID: 34840648; PMCID: PMC8570357.
17. Elmas ÖF. Uncovering subtle nail involvement in lichen planus with dermoscopy: a prospective, controlled study. *Postepy Dermatol Alergol*. 2020 Jun;37(3):396-400. doi: 10.5114/ada.2020.96298. Epub 2020 Jul 16. PMID: 32792882; PMCID: PMC7394157.
18. Wechsurok P, Bunyaratavej S, Kiratiwongwan R, Suphatsathienkul P, Wongdama S, Leeyaphan C. Clinical features and treatment outcomes of nail lichen planus: A retrospective study. *JAAD Case Rep*. 2021 Sep 22;17:43-48. doi: 10.1016/j.jdc.2021.09.015. PMID: 34703863; PMCID: PMC8526913.
19. Kharghoria, G., Grover, C., Bhattacharya, S. N., & Sharma, S. (2020). Histopathological evaluation of nail lichen planus: a cross-sectional study. *Journal of Cutaneous Pathology*. doi:10.1111/cup.13783.
20. Naveen KN. Pup tent sign. *Indian Dermatol Online J*. 2014 Oct;5(4):552-3. doi: 10.4103/2229-5178.142574. PMID: 25396167; PMCID: PMC4228679.

Characteristics				
Characteristic	N	%	P Value (Dorsal Pterygium)	P Value (Anonychia)
Nail matrix characteristics				
Nail plate retraction	75	73.5	0.678	0.019
<i>Nail plate retraction greater than 50%</i>	12	11.1	0.051	<0.001
Crumbling or fragmentation of the dorsum of the nail plate	69	67.6	0.955	1.000
Onychorrhexis	68	66.7	0.970	1.000
Pitting or pits	49	48.0	0.873	1.000
Proximal leukonychia	47	46.1	0.842	1.000
Onychoschizia	47	46.1	0.953	1.000
Severe thinning of the nail plate	45	44.1	0.336	<0.001
Yellowish chromonychia	40	39.2	0.444	1.000
Erythronychia	36	35.3	0.590	0.968
Irregular lunula	26	25.5	0.829	0.867
Distal splitting	24	23.5	0.080	1.000
<i>Distal splitting less than 25%</i>	10	9,80	0.549	1.000
<i>Distal splitting between 25% and 50%</i>	7	6,9	1.000	1.000
<i>Distal splitting greater than 50%</i>	7	6,9	0.008	1.000
Reddish Lunula	18	17.6	0.617	0.916

Table 1. Nail unit signs of 102 patients affected by severe Nail Lichen Planus

Trachyonychia	10	9.8	0.294	0.731
Onychomadesis	0	0.0	1.000	1.000
Nail bed characteristics				
Nail bed retraction or disappearing nail bed	76	74.5	0.707	0,033
<i>Nail bed retraction or disappearing nail bed greater than 50%</i>	11	10.8	0,554	<0.001
Nail Bed erythema (no plate involved)	65	63.7	0.842	0.546
Spotted erythronychia	63	61.8	0.584	0.486
Splinter hemorrhages	37	36.3	0.838	0.973
Onycholysis	24	23.5	0.080	1.000
<i>Onycholysis less than 25%</i>	3	2,94	0.086	1.000
<i>Onycholysis between 25% and 50%</i>	11	10,78	0.203	1.000
<i>Onycholysis greater than 50%</i>	10	9,80	0.549	1.000
Subungual hyperkeratosis	5	4.9	0.442	1.000
Mixed compromise of the matrix and the nail bed				
Convergence of longitudinal streaks to the center of the nail apparatus	68	66.7	0.219	0.637
Onychoatrophy	51	50.0	0.004	0,002
Hapalonychia	48	47.1	0.858	0.996
Melanonychia	27	26.5	1.000	0.981
Residual nail plate	21	20.6	0.403	0.016
Anonychia	12	11.8	0.381	-

Dorsal nail pterygium	11	10.8	-	0.381
Bulge / pup tent	11	10.8	0.734	0.766
Periungual tissues characteristics				
Loss of nail fold (any): Disruption of any part of a nail fold.	81	79.4	0.289	0.052
<i>Loss of distal nail groove</i>	73	71,60%	0.835	0.215
<i>Loss of lateral nail fold</i>	69	67,60%	0.745	0.113
<i>Loss of proximal nail fold</i>	21	20,60%	<0.001	<0.001
Paronychia	22	21.6	0.941	0.503
Perionychial hemorrhage	15	14.7	1.000	0.558
Pulpitis	11	10.8	1.000	0.381

For Paper Review

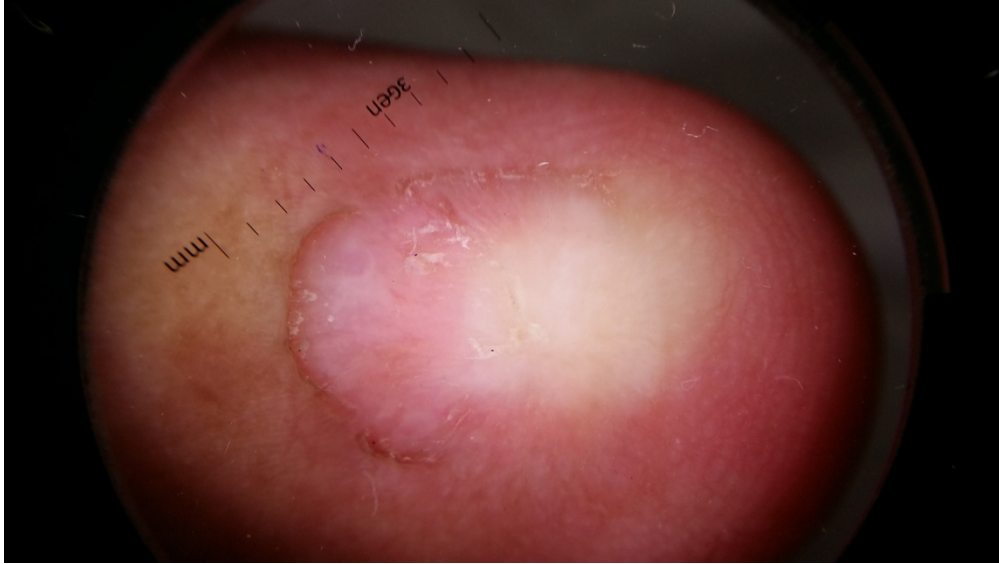

Figure 1. Anonychia

1456x819mm (72 x 72 DPI)

1
2
3
4
5
6
7
8
9
10
11
12
13
14
15
16
17
18
19
20
21
22
23
24
25
26
27
28
29
30
31
32
33
34
35
36
37
38
39
40
41
42
43
44
45
46
47
48
49
50
51
52
53
54
55
56
57
58
59
60

1
2
3
4
5
6
7
8
9
10
11
12
13
14
15
16
17
18
19
20
21
22
23
24
25
26
27
28
29
30
31
32
33
34
35
36
37
38
39
40
41
42
43
44
45
46
47
48
49
50
51
52
53
54
55
56
57
58
59
60

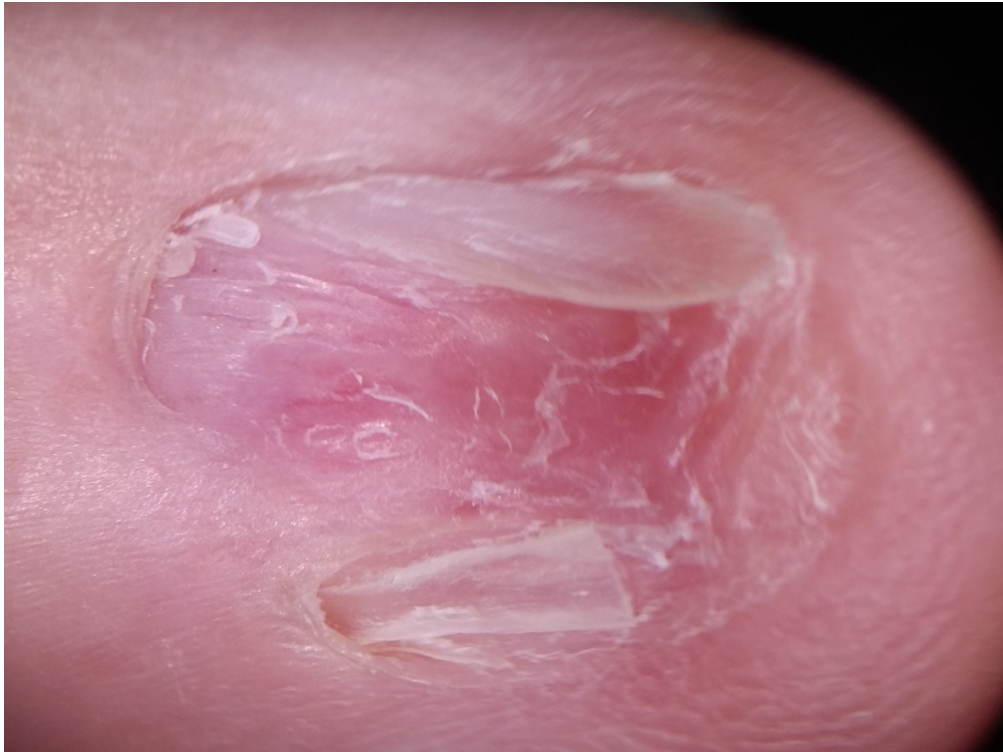

Figure 2. Dorsal pterygium

1151x863mm (72 x 72 DPI)

1
2
3
4
5
6
7
8
9
10
11
12
13
14
15
16
17
18
19
20
21
22
23
24
25
26
27
28
29
30
31
32
33
34
35
36
37
38
39
40
41
42
43
44
45
46
47
48
49
50
51
52
53
54
55
56
57
58
59
60

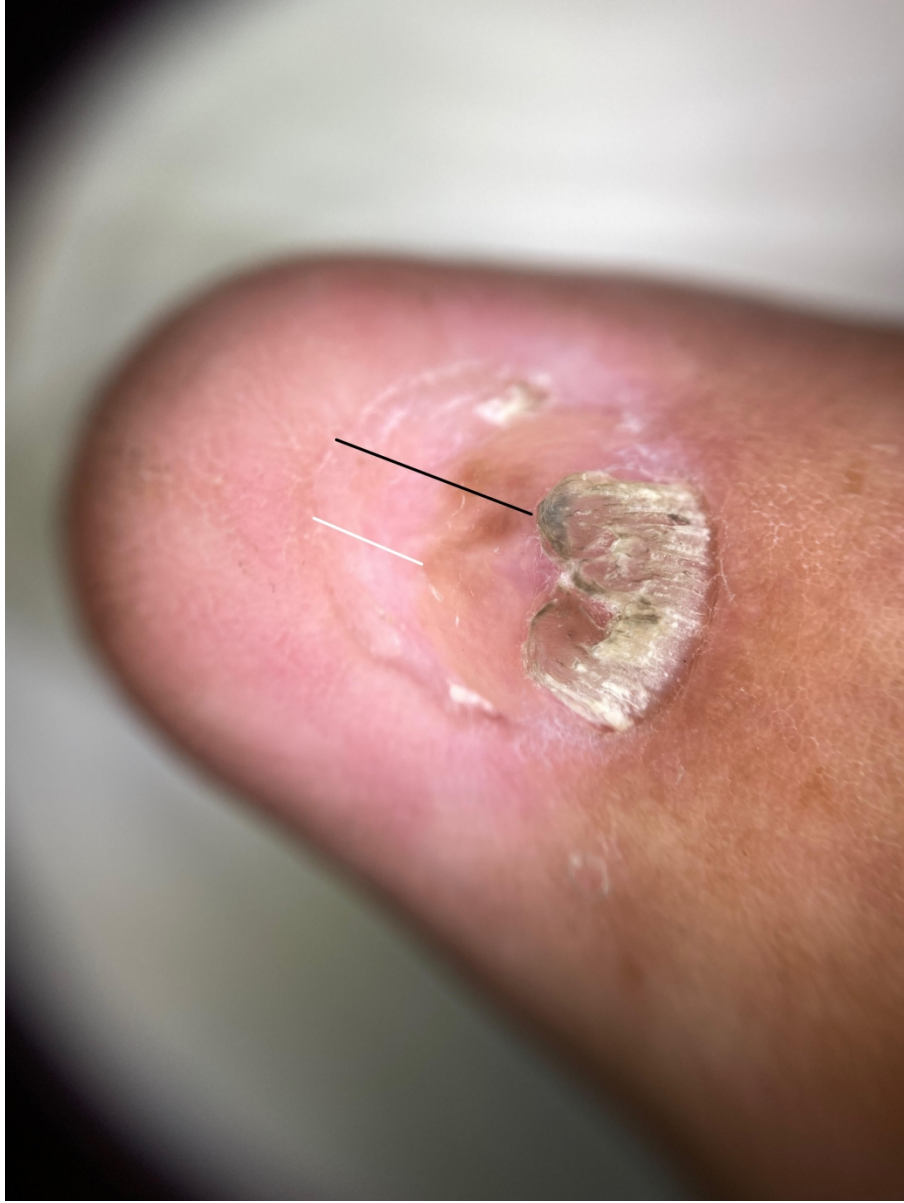

Figure 3. Nail plate retraction (black line) and nail bed retraction "Disappearing nail bed" (white line)

406x541mm (288 x 288 DPI)

1
2
3
4
5
6
7
8
9
10
11
12
13
14
15
16
17
18
19
20
21
22
23
24
25
26
27
28
29
30
31
32
33
34
35
36
37
38
39
40
41
42
43
44
45
46
47
48
49
50
51
52
53
54
55
56
57
58
59
60

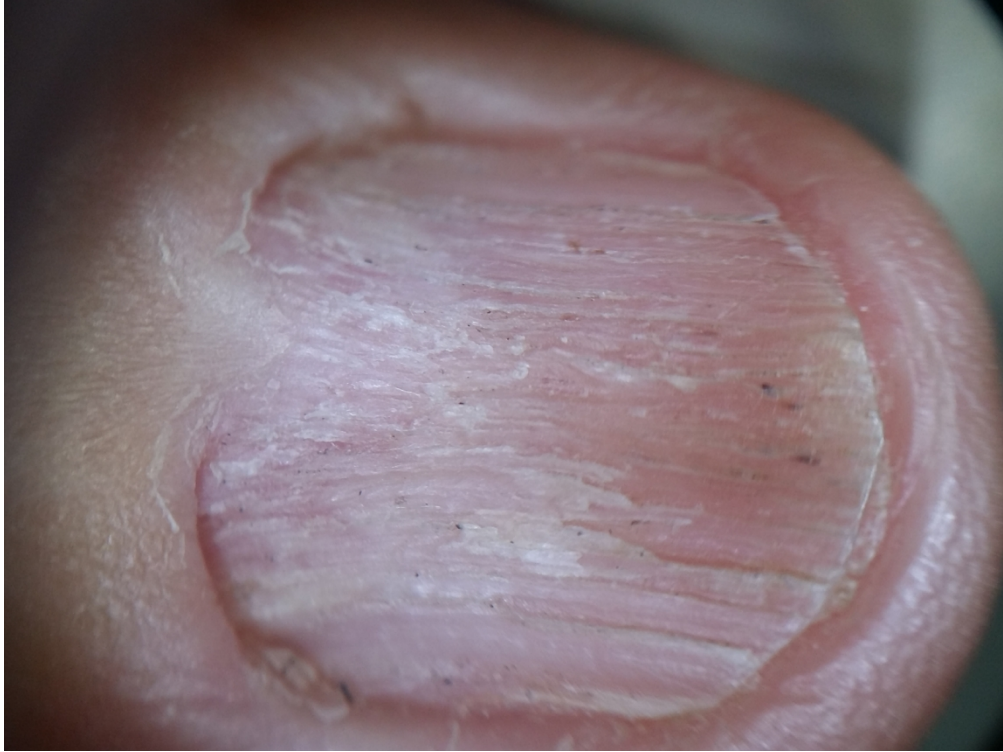

Figure 4. Bulge

1151x863mm (72 x 72 DPI)




Figure 5. Suggested updated severe stage for NLP.

327x112mm (150 x 150 DPI)