



ALMA MATER STUDIORUM
UNIVERSITÀ DI BOLOGNA

ARCHIVIO ISTITUZIONALE
DELLA RICERCA

Alma Mater Studiorum Università di Bologna Archivio istituzionale della ricerca

Median canaliform nail dystrophy of Heller in a patient with atopic dermatitis: 'miraculous' healing with dupilumab

This is the final peer-reviewed author's accepted manuscript (postprint) of the following publication:

Published Version:

Giura, M.T., Viola, R., Dika, E., Ribero, S., Ortoncelli, M. (2020). Median canaliform nail dystrophy of Heller in a patient with atopic dermatitis: 'miraculous' healing with dupilumab. *CLINICAL AND EXPERIMENTAL DERMATOLOGY*, 45(5), 601-602 [10.1111/ced.14169].

Availability:

This version is available at: <https://hdl.handle.net/11585/886227> since: 2022-05-18

Published:

DOI: <http://doi.org/10.1111/ced.14169>

Terms of use:

Some rights reserved. The terms and conditions for the reuse of this version of the manuscript are specified in the publishing policy. For all terms of use and more information see the publisher's website.

This item was downloaded from IRIS Università di Bologna (<https://cris.unibo.it/>).
When citing, please refer to the published version.

(Article begins on next page)



DR MARIA TERESA GIURA (Orcid ID : 0000-0001-7228-4477)

DR EMI DIKA (Orcid ID : 0000-0003-3186-2861)

DR SIMONE RIBERO (Orcid ID : 0000-0002-0098-1406)

Article type : Correspondence

Median canaliform nail dystrophy of Heller in a patient with atopic dermatitis: a “miraculous” healing with Dupilumab

M.T. Giura,¹ R. Viola,² E. Dika,³ S. Ribero,¹ M. Ortoncelli¹

¹ Medical Sciences Department, Dermatologic Clinic, University of Turin, Turin, Italy.

² Faculty of Medicine, University of Turin, Italy

³ Unit of Dermatology, Department of Experimental, Diagnostic and Specialty Medicine, University of Bologna, Bologna, Italy.

Corresponding Author: Simone Ribero, MD, PhD

E-mail: simone.ribero@unito.it

All authors have no conflicts of interest.

No funding sources were involved in this paper

This article has been accepted for publication and undergone full peer review but has not been through the copyediting, typesetting, pagination and proofreading process, which may lead to differences between this version and the [Version of Record](#). Please cite this article as [doi: 10.1111/CED.14169](https://doi.org/10.1111/CED.14169)

This article is protected by copyright. All rights reserved

KEY WORDS: median canaliform nail dystrophy of Heller, nail dystrophy and atopic dermatitis, Dupilumab therapy, pruritus therapy

Median canaliform nail dystrophy of Heller in a patient with atopic dermatitis (AD) can be caused by chronic trauma due to itching. By removing the pruritus, in this case with Dupilumab, given for severe AD, the nail dystrophy was also resolved.

Dear editor,

Median canaliform dystrophy of Heller is a relatively rare nail abnormality characterized by central single longitudinal split with an inverted fir tree pattern, that commonly involves the thumb nails, rarely other finger nails.¹

The pathogenesis is not entirely clear, the most common hypothesis is repetitive trauma to the proximal nail fold and the underlying nail matrix, also self-induced, or compression by subungual tumors. Familiar cases have been reported. But commonly the cause is idiopathic.²

The treatment is mainly focused on avoiding chronic nail trauma, but few cases have reported the efficacy of topical tacrolimus.³

A woman in her middle age affected by atopic dermatitis (AD) since childhood came to our observation for severe exacerbation of her AD, uncontrolled with the use of topical and systemic steroids or cyclosporine. In a careful clinical analysis, in addition to the AD manifestations, the presence of median longitudinal dystrophy of the right thumb nail was observed. No other fingernails or toenails were involved. The patient referred its occurrence since a couple of years (Fig 1A) and no one else in the family had this condition.

In the case of our patient the cause of the canaliform dystrophy is probably due to the chronic pruritus related to AD, as also described by Wang C. et al.⁴

Given the severity of the AD, Dupilumab therapy was administered as follows: initial dose of 600 mg followed by 300 mg every two weeks.

Dupilumab is an IL-4 receptor subunit α (IL-4 R α) antagonist that inhibits IL-4 and IL-13 signalling and, consequently, the entire Th2 pathway.

These interleukins would appear to be key mediators in the mechanism of chronic pruritus related to AD.

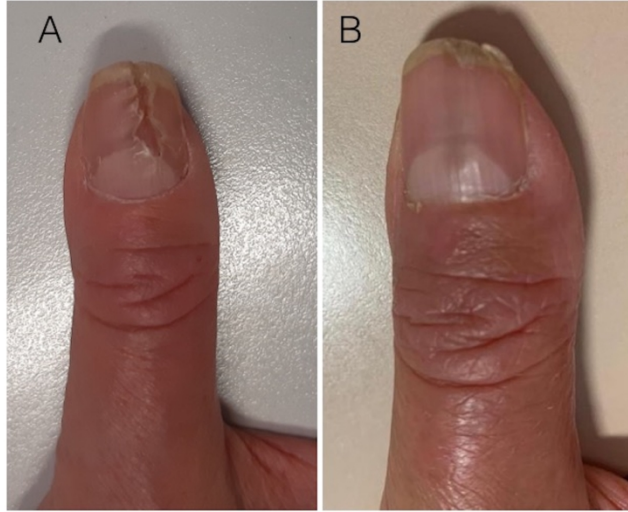
Oetjen et al. have shown that in part chronic pruritus is dependent on neuronal IL-4R α signaling. The IL-4R α is expressed directly on sensory neurons both in mice and in the human dorsal root ganglia and the Th2 cytokines (IL-4, IL-13 and IL-31) directly activate these neurons; blocking IL-4R α , chronic itching is attenuated in a murine mouse model when the same mechanism is effectively actuated.⁵

After 4 months of Dupilumab treatment was found not only an improvement of the skin manifestation, but also a complete remission of the median canaliform nail dystrophy (Fig 1B). The result obtained is probably due to the efficacy of the drug in improving the itch symptom with consequent cessation of the repeated trauma on the nail by the patient.

REFERENCES

1. Tosti A, Piraccini BM. Biology of nails and nail disorders. In: Wolff K, Goldsmith LA, Katz SI, Gilchrist B, Paller A, Leffell D, eds. Fitzpatrick's Dermatology in General Medicine, 7th edn. New York: McGraw-Hill; 2008:778-794.
2. Sweeney S, Cohen P, Schulze K, Nelson BR. Familial median canaliform nail dystrophy. *Cutis* 2005; 75: 161–5.
3. Kim BY, Jin SP, Won CH, Cho S. Treatment of median canaliform nail dystrophy with topical 0.1% tacrolimus ointment. *J Dermatol.* 2010 Jun;37:573–574.
4. Wang C, Lee S, Howard A, Foley P. Coexisting median canaliform nail dystrophy and habit-tic deformity in a patient with atopic dermatitis. *Australas J Dermatol.* 2019 Jun 3. doi: 10.1111/ajd.13084.
5. Oetjen L.K, Mack M.R, Feng J, et al. Sensory Neurons Co-opt Classical Immune Signaling Pathways to Mediate Chronic Itch. *Cell* 2017, 171, 217–228.e213.

Fig 1: A) Median canaliform dystrophy of Heller in a patient with AD after one month of Dupilumab (fingernails growth rate is about 3 mm/month). B) Remission of the median canaliform dystrophy of Heller after 4 month of Dupilumab



ced_14169_f1.jpg