

Genital tract involvements in a bull affected by bovine besnoitiosis

Masebo N.T., Bolcato M., Jacinto J.G.P., Gentile A., Militerno G.
(Department of Veterinary Medical Sciences - Bologna - Italy)



ALMA MATER STUDIORUM
UNIVERSITÀ DI BOLOGNA

Background

Bovine besnoitiosis is a parasitic disease of cattle caused by the cyst-forming coccidian *Besnoitia besnoiti*. The parasite targets mainly the skin, mucosal membranes, scleral conjunctiva, testis, and endothelial cells of large vessels.

Objective

To describe the gross and histopathological testicular lesions observed in a 14-months-old Limousine bull, imported from France and referred for thickening of the skin and enlargement of the testis and finally diagnosed as affected by Besnoitiosis. The diagnosis was confirmed by histological investigation of skin sampled via biopsy.

Materials and Methods

Gross examination and histological investigation were carried out on the reproductive tract of the bull sampled during slaughtering. The considered parts were skin of the scrotum, testis, testicular coverings, epididymis, penis, and penis retractor muscle.

These tissue were fixed in 10% buffered formalin, embedded in paraffin wax, and processed for histological investigation.

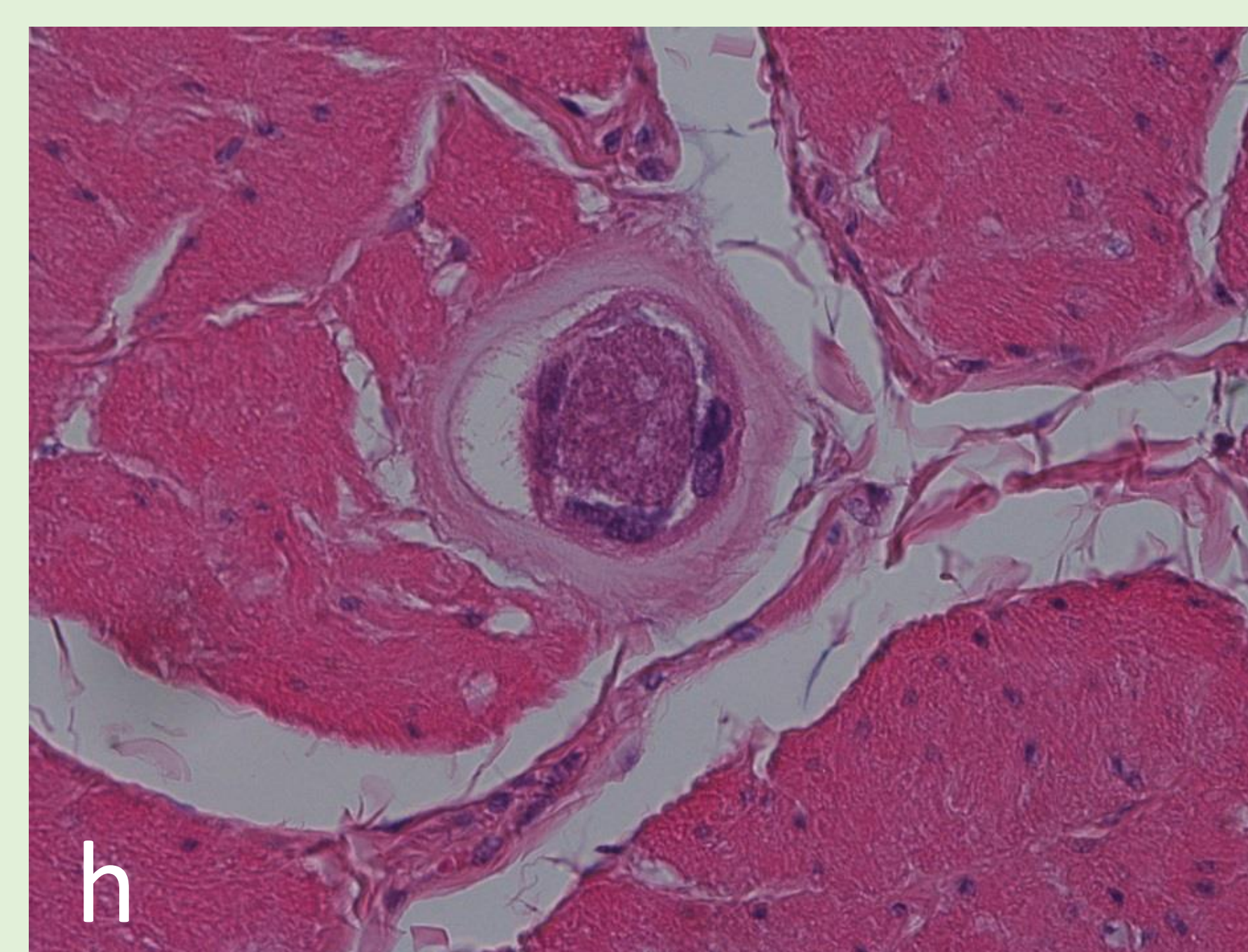
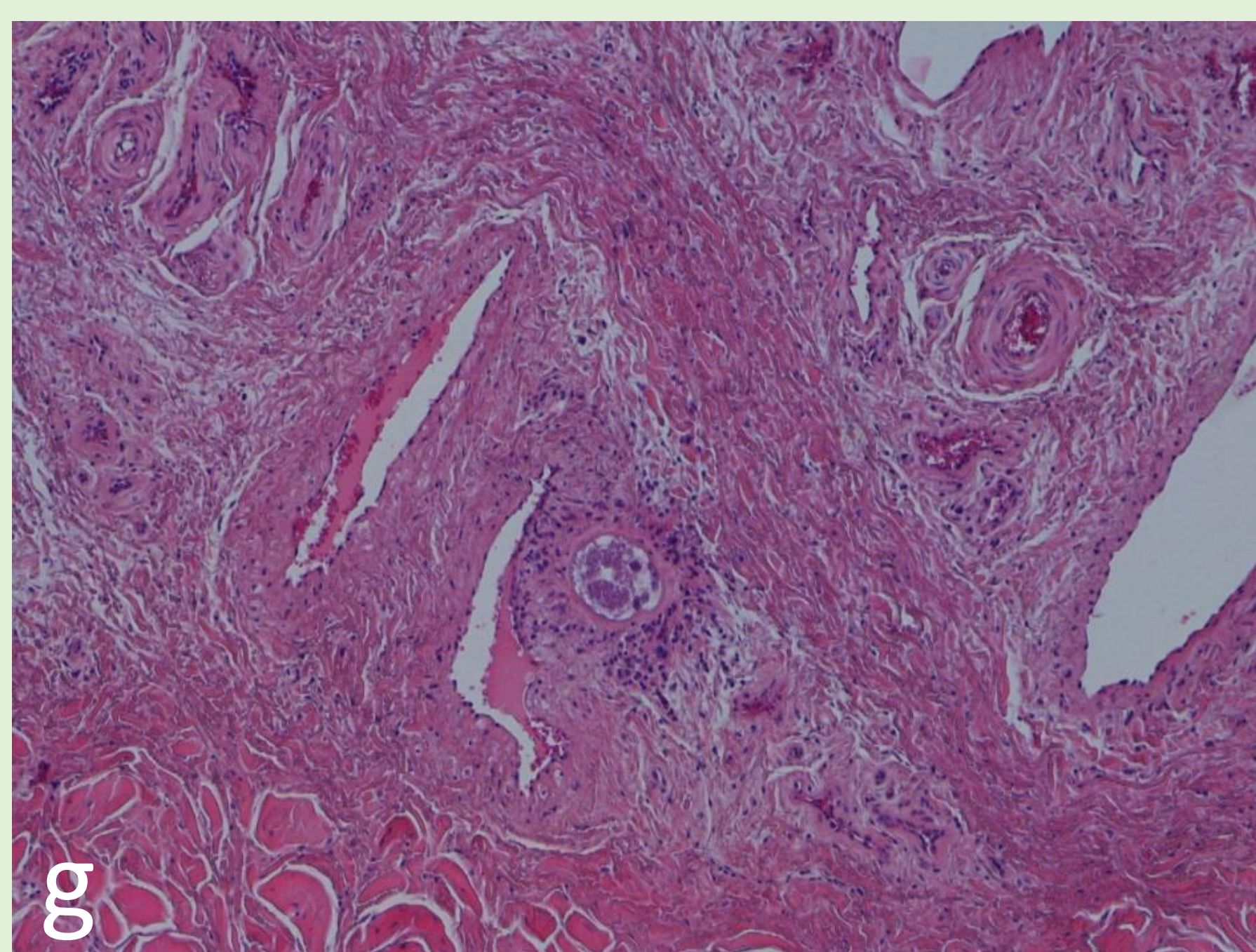
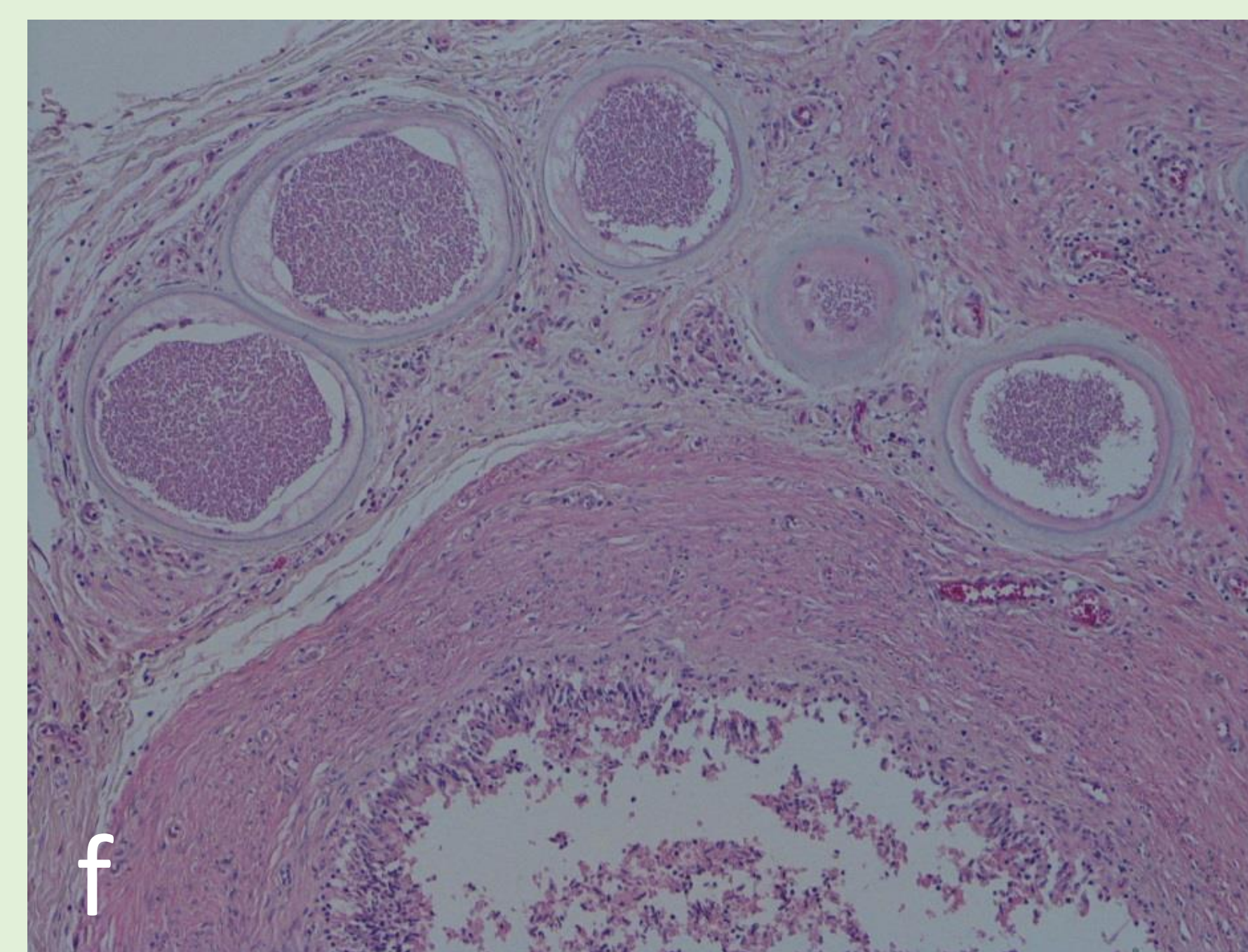
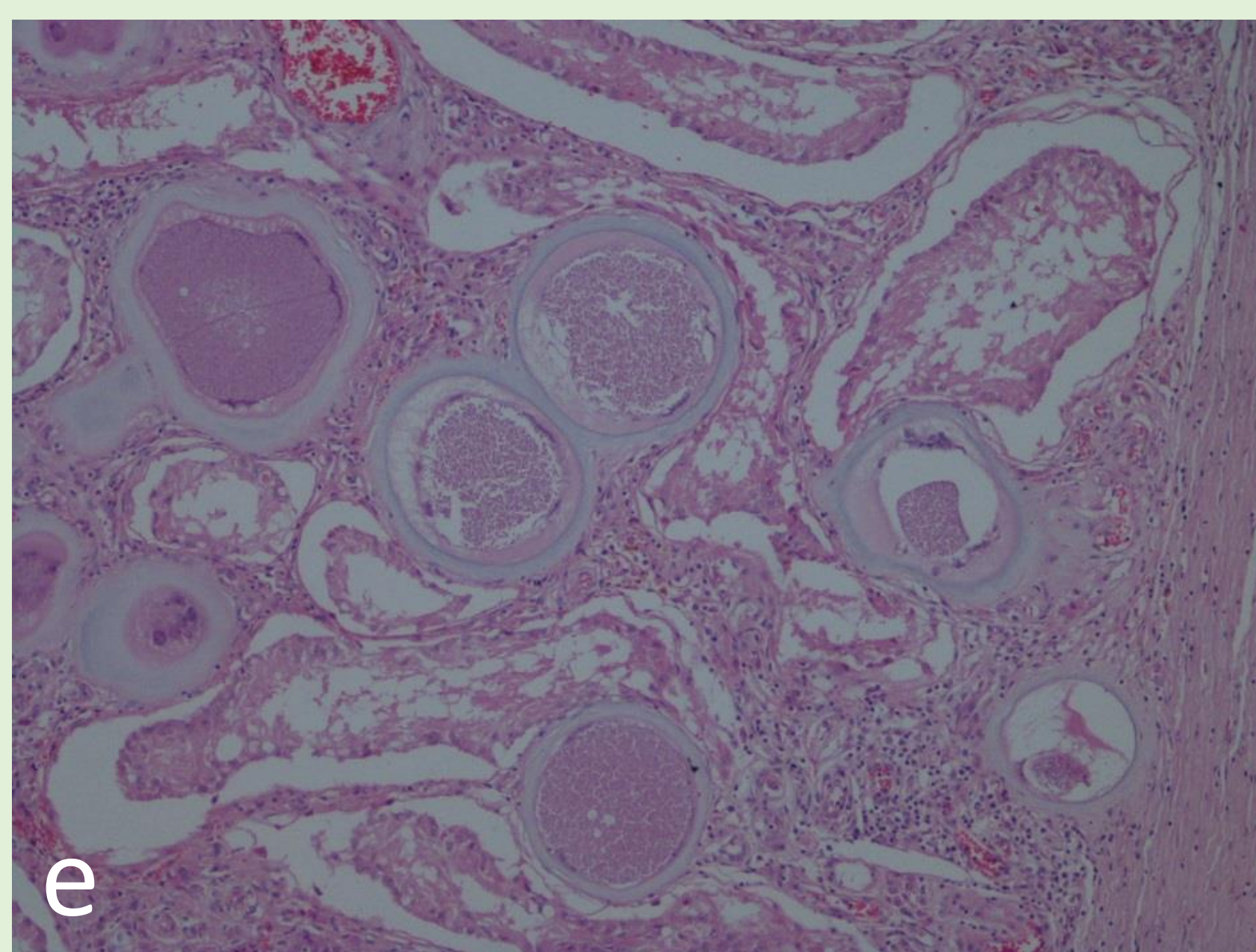
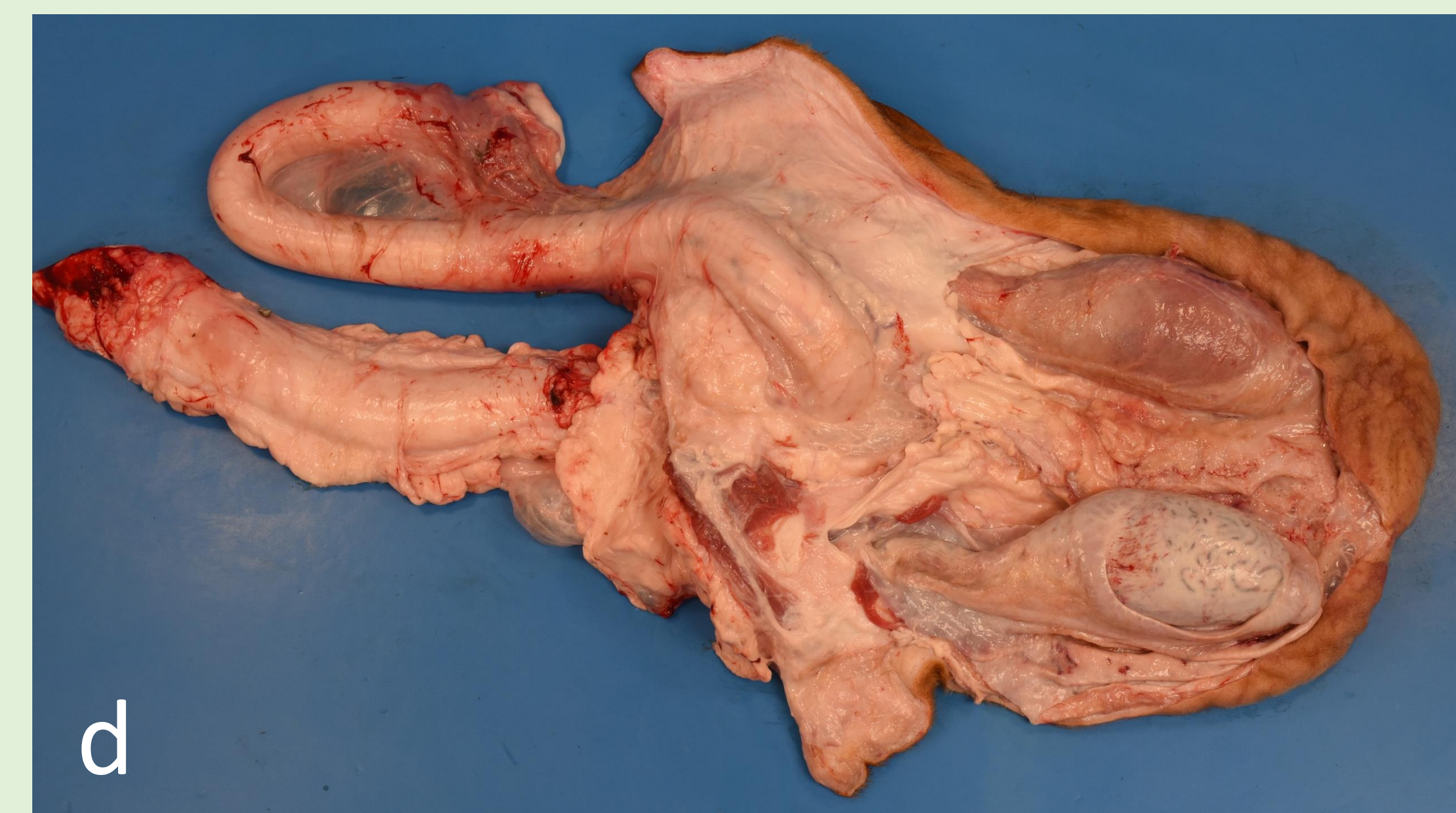
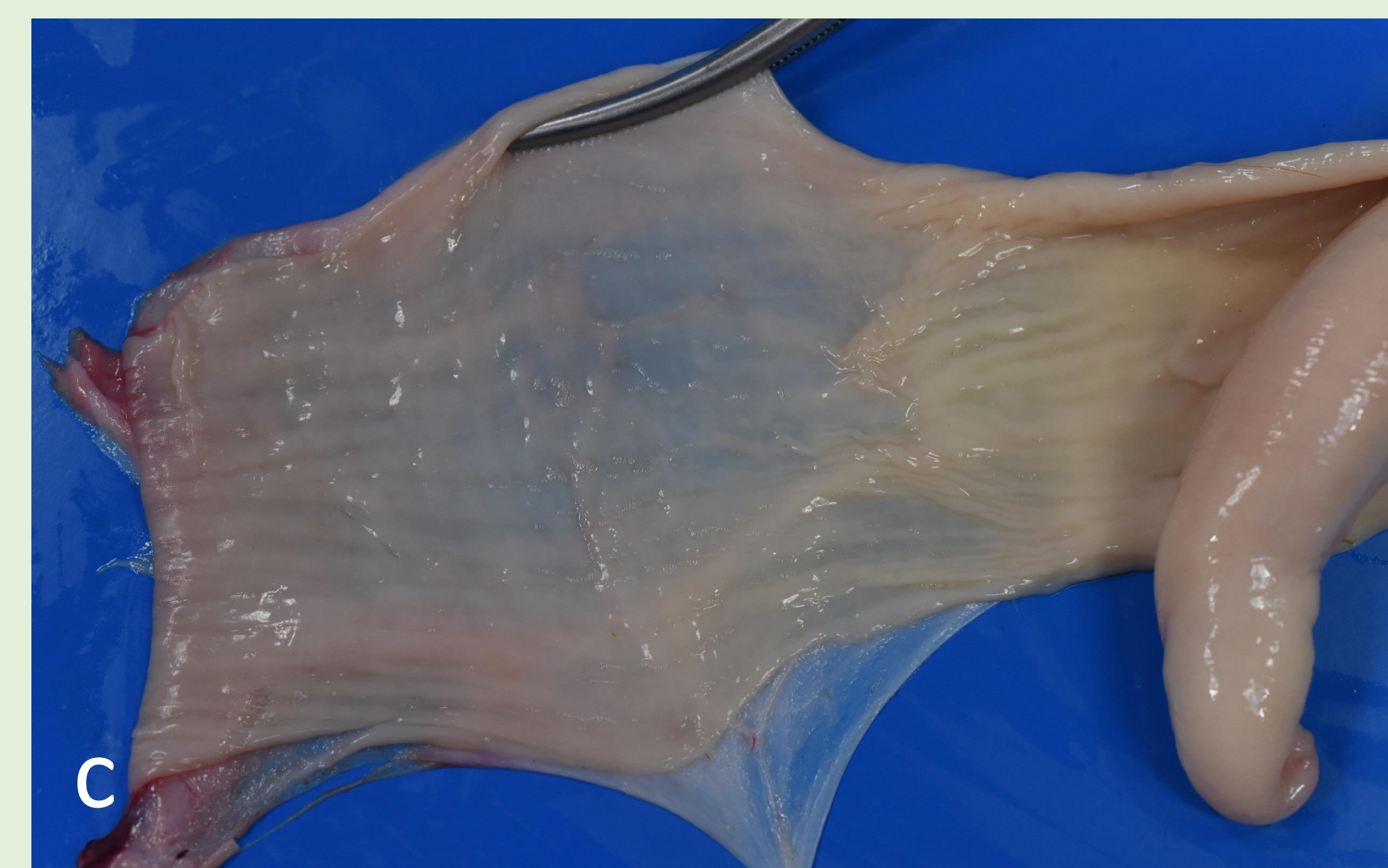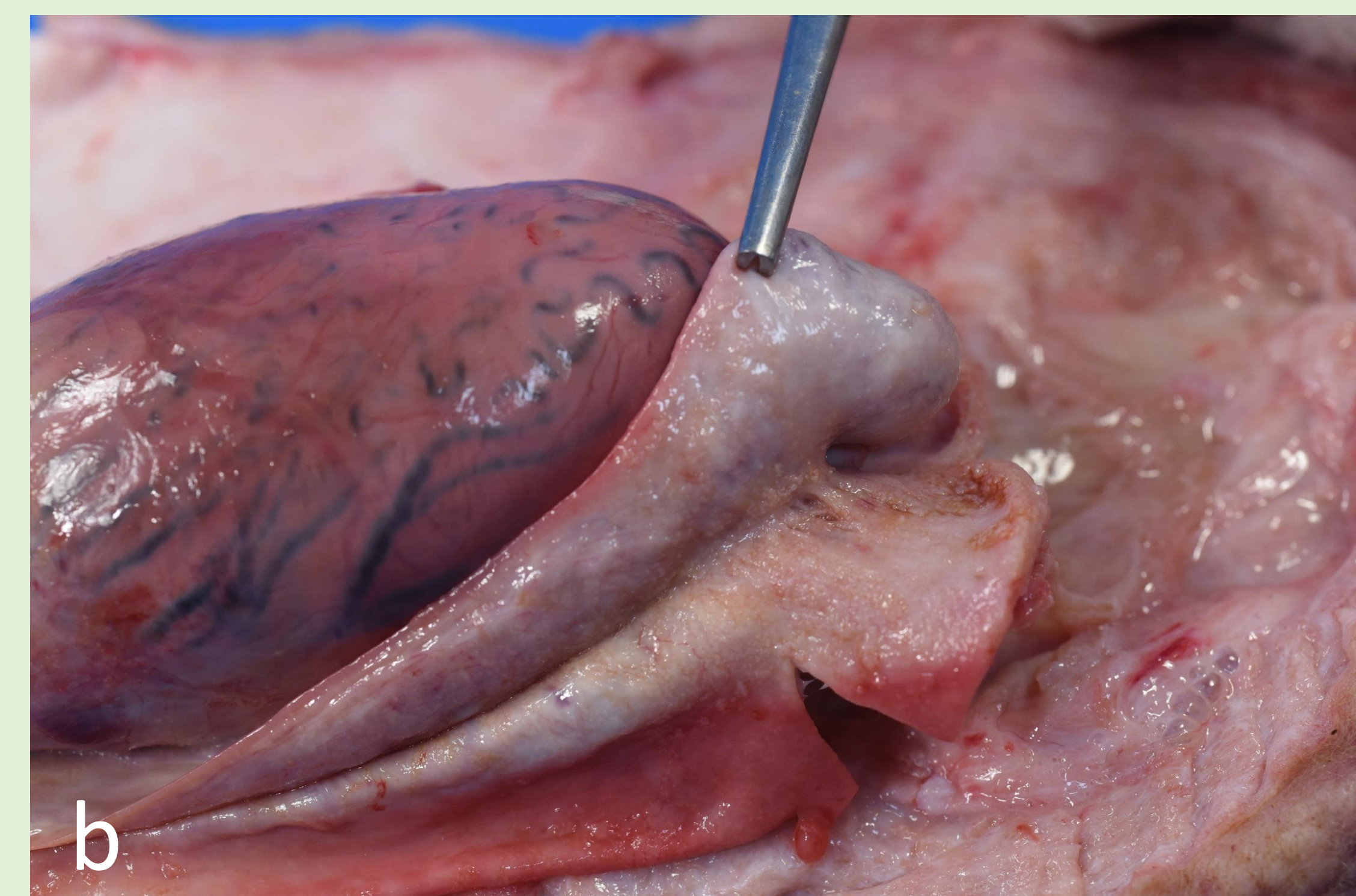
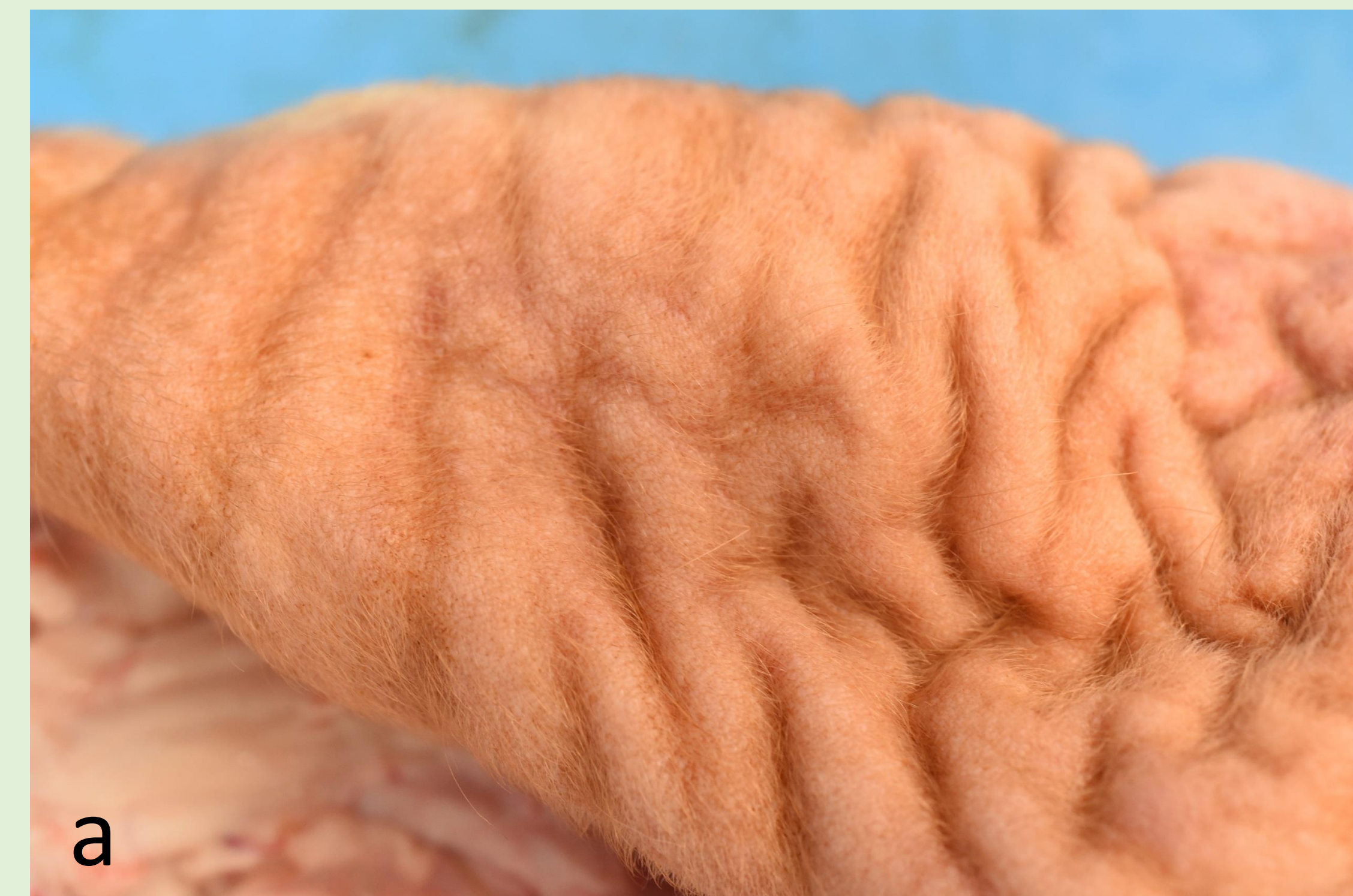Results

Gross examination showed: thickening and lichenification of the scrotal skin (a), visible cysts at the level of the testicular coverings (b), preputial mucosa (c), hyperemia of the right testis (d).

The main microscopical finding was the presence of several *Besnoitia. spp* cysts in the skin and subcutaneous tissue of the scrotum, in the testicular coverings as well as in the testicular tubules (e), and epididymis. (f) The *Besnoitia spp.* cysts ranged in size from 250 to 300 μm in diameter. They had a 10-20 μm thick wall with three layers: an outer hyaline layer, a middle layer with host cells cytoplasm and nuclei, and an inner membrane with the parasitophorous vacuole containing typical 7.0 \times 2.0 μm basophilic banana-shaped *Besnoitia spp.* Bradyzoites.

Plasmocytic and histiocytic inflammatory reaction, with sparse eosinophilic granulocytes infiltration were observed around some broken cysts.

Numerous *Besnoitia spp.* cysts were also observed in the cross section of the penis (g) and the penis retractor muscle (h). A moderate inflammatory response, composed by macrophages, eosinophils and scattered lymphocytes, was seen near and around the cysts.



Discussion and conclusions

The presence of cysts and its secondary inflammatory reactions may explain the impaired fertility that has been already described in the case of Besnoitiosis. Potential explanations may be:

- interference with normal spermatogenesis by the cysts in the interstitial spaces and under the epithelial cells in the seminiferous tubules;
- direct pressure on the germinal epithelial cells by the cysts that can cause pressure atrophy of epididymal and/or testicular tissues;
- reduction of the blood flow, local testicular necrosis and development of fibrotic foci due to the inflammation caused by the cysts in the blood vessel walls of the testis and pampiniform plexus, with repercussion on the seminiferous tubule health;
- abnormal thermoregulation of the testis due to the thickened scrotum;
- abnormal thermoregulation of the testis due to vascular lesions in pampiniform plexus provoking testicular degeneration;
- tissutal fibrosis due to the inflammatory reaction to the presence of the cysts.

