

Alma Mater Studiorum Università di Bologna
Archivio istituzionale della ricerca

Effect of body-part specificity and meaning in gesture imitation in left hemisphere stroke patients

This is the final peer-reviewed author's accepted manuscript (postprint) of the following publication:

Published Version:

Tessari, A., Mengotti, P., Faccioli, L., Tuoizzi, G., Boscarato, S., Taricco, M., et al. (2021). Effect of body-part specificity and meaning in gesture imitation in left hemisphere stroke patients. *NEUROPSYCHOLOGIA*, 151, 1-10 [10.1016/j.neuropsychologia.2020.107720].

Availability:

This version is available at: <https://hdl.handle.net/11585/833878> since: 2023-05-22

Published:

DOI: <http://doi.org/10.1016/j.neuropsychologia.2020.107720>

Terms of use:

Some rights reserved. The terms and conditions for the reuse of this version of the manuscript are specified in the publishing policy. For all terms of use and more information see the publisher's website.

This item was downloaded from IRIS Università di Bologna (<https://cris.unibo.it/>).
When citing, please refer to the published version.

(Article begins on next page)

This is the final peer-reviewed accepted manuscript of:

Tessari, A., Mengotti, P., Faccioli, L., Tuozi, G., Boscarato, S., Taricco, M., & Rumiati, R. I. (2021). Effect of body-part specificity and meaning in gesture imitation in left hemisphere stroke patients. *Neuropsychologia*, 151, 107720. <https://doi.org/10.1016/j.neuropsychologia.2020.107720>

The final published version is available online at:
<https://doi.org/10.1016/j.neuropsychologia.2020.107720>

Terms of use:

Some rights reserved. The terms and conditions for the reuse of this version of the manuscript are specified in the publishing policy. For all terms of use and more information see the publisher's website.

This item was downloaded from IRIS Università di Bologna (<https://cris.unibo.it/>)

When citing, please refer to the published version.

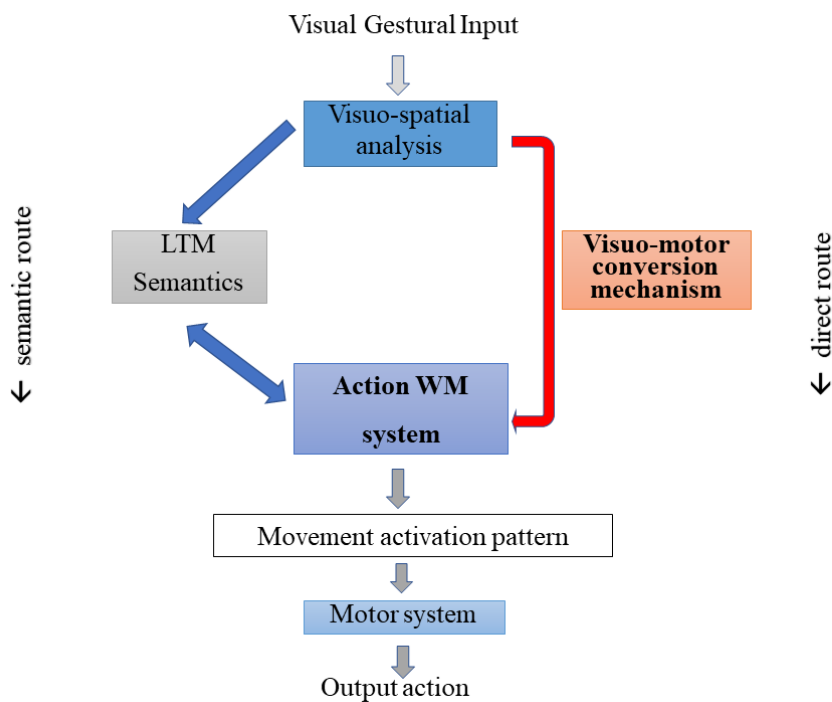
1 **ABSTRACT**

2 Previous studies showed that imitation of finger and hand/arm gestures could be
3 differentially impaired after brain damage. However, so far, the interaction between gesture
4 meaning and body part in imitation deficits has not been fully assessed. In the present study, we
5 aimed at filling this gap by testing 36 unilateral left brain-damaged patients with and without
6 apraxia (20 apraxics), and 29 healthy controls on an imitation task of either finger or hand/arm
7 meaningful (MF) gestures and meaningless (ML) movements, using a large sample of stimuli and
8 controlling for the composition of the experimental list. Left-brain damaged patients imitated ML
9 finger worse than hand/arm movements, whereas they did not show the same difference in MF
10 gesture imitation. In addition, apraxic patients imitated finger movements worse than hand/arm
11 movements. Furthermore, apraxic patients' imitation performance was equally affected irrespective
12 of the action meaning, whereas non-apraxic patients showed better imitation performance on MF
13 gestures. Results suggest that MF gestures are processed as a whole, as imitation of these gestures
14 relies on the stored motor programs in long-term memory, independently of the body part involved.
15 In contrast, ML movements seem to be processed through direct visuo-motor transformations, with
16 left-brain damage specifically disrupting imitation performance of the more cognitive demanding
17 finger movements.

18
19
20
21
22 **Keywords:** Apraxia; imitation; left brain-damage; body; finger gestures; meaning.
23

1 **Introduction**

2 Imitation is a fundamental ability that allows individuals to efficiently acquire a wide range
3 of movements by observing a demonstrator performing them. The tendency to imitate has been
4 extensively studied in children (e.g., Ray & Heyes, 2011) and adults (e.g., Rumiati & Bekkering,
5 2003), as well as in monkeys and great apes (e.g., Tomasello, Savage-Rumbaugh, Kruger, 1993).
6 This ability can be selectively impaired after brain damage giving rise to a syndrome clinically
7 called ideomotor apraxia. Ideomotor apraxia has been defined as a deficit in the intentional
8 execution of gestures that cannot be explained as being due to simple motor or sensorial deficits, to
9 comprehension deficits, object recognition problems or frontal inertia (see De Renzi & Faglioni,
10 1999). Rothi, Ochipa and Heilman (1991) proposed the first cognitive model of gesture recognition
11 and production that distinguished between input and output processes, between different types of
12 stimulus (gesture or object), and different modalities in which gestures and objects are presented
13 (verbal vs. visual). As far as imitation is concerned, the original model by Rothi et al. (1991), as
14 well as its following evolutions (e.g., Cubelli, Marchetti, Boscolo, della Sala, 2000; Rumiati &
15 Tessari, 2002; Buxbaum & Randerath, 2018), hypothesized the existence of two separate processes
16 for transforming the visual input (i.e., the seen gesture as shown by the demonstrator) into a motor
17 act (i.e., the imitated movement): the semantic and the direct route. After the first common stage,
18 during which a movement is analysed, one of the two routes is selected depending on whether the
19 movement is already known or not. The semantic route is selected for known, meaningful (MF)
20 gestures that already belong to a person's repertoire, and that are stored in the semantic long-term
21 memory (LTM). The direct route is selected when a new, meaningless (ML) movement is
22 presented, as no matching representation can be found in the semantic memory. This mechanism
23 allows converting any visually presented movement, including MF gestures, into motor output, by
24 parsing it in smaller and simpler motor components. The outcome of this visuomotor transformation
25 is then briefly kept in the motor short-term/working memory (WM) system (hypothesized by
26 Cubelli et al., 2000, and empirically confirmed by Rumiati & Tessari, 2002; see also Buxbaum and
27 Randerath, 2018). The motor WM system is common to the direct and semantic route and allows
28 learning new actions. See Figure 1.



1
 2 **Figure 1:** A modified version of the model originally proposed by Tessari et al. (2007). The model
 3 includes two routes involved in the imitation of meaningful (MF) and meaningless (ML) gestures.
 4 After the first common visuo-spatial analysis is performed, if the action to be imitated is ML, then
 5 the direct route is selected, whereas if the action is MF, then the semantic route is preferably
 6 selected (although the direct route can also be used). The motor short-term/working memory
 7 subsystem is common to both the semantic and direct route, and it is essential for motor learning.
 8 LTM: long term memory; WM: working memory.

9
 10 Evidence for the existence of these putative two routes in imitation comes from several
 11 neuropsychological studies with brain-damaged patients (e.g., Bartolo, Cubelli, Della Sala, Drei, &
 12 Marchetti, 2001; Cubelli et al., 2000; Goldenberg & Hagmann, 1997; Mengotti, Corradi-Dell’Acqua;
 13 Negri, Ukmar, Pesavento & Rumiati, 2013; Tessari, Canessa, Ukmar e Rumiati, 2007), as well as
 14 from experimental studies on healthy adults (e.g., Carmo & Rumiati, 2009; Rumiati & Tessari, 2002;
 15 Tessari & Rumiati, 2004; Tessari, Bosanac & Rumiati, 2006) and children (Sebastianutto, Mengotti,
 16 Spiezio, Rumiati, Balaban, 2017). In particular, double dissociating cases of patients with selective
 17 deficits in imitating either MF gestures or ML movements were documented (Bartolo et al., 2001;
 18 Mengotti et al., 2013; Tessari et al., 2007), thus providing causal evidence in support of the relative
 19 independence of the two routes.

20 Interestingly, these dissociations between patients emerged when MF gestures and ML
 21 movements were presented in separate lists. The list-composition effect was described first by
 22 Tessari & Rumiati (2004) in healthy individuals, using particular experimental manipulations of

1 stimulus presentation, and later replicated in many other studies (Cubelli, Bartolo, Nichelli, Della
2 Sala, 2006; Rumiati, Weiss, Tessari et al., 2005; Tessari et al., 2007; Carmo & Rumiati, 2009; Press
3 & Heyes, 2008). More specifically, when MF gestures and ML movements are intermingled, the
4 direct route is selected to imitate both types of stimuli, and no difference emerges in imitation
5 performance between the two. However, when the two types of stimuli are presented in separate lists,
6 the semantic route predominates for imitating MF gestures and the direct route for imitating the ML
7 movements (Cubelli et al., 2000; Tessari & Cubelli; 2014; Tessari & Rumiati, 2004; Tessari et al.,
8 2007). Indeed, in neuropsychological studies in which the mixed presentation of MF and ML stimuli
9 was used, no dissociations between the two were reported (e.g., Achilles, Fink, Fischer, et al., 2016;
10 Achilles, Ballweg, Niessen, Kusch, Ant, Fink & Weiss, 2019; Hoeren, Kümmerer, Bormann et al.,
11 2004; Toraldo; Reverberi & Rumiati, 2003).

12 The imitation deficits have been associated with lesions of the left inferior parietal lobe and its
13 underlying white matter, the premotor cortex (e.g., Basso, Luzzatti & Spinnler, 1980; Dressing,
14 Nitschke, Kümmerer et al., 2018; Geshwind, 1965; Goldenberg & Randerath, 2015; Rothi &
15 Heilmann, 1985; Rothi et al., 1991; Sirigu, Cohen, Duhamel, Pillon, Dubois & Agid, 1995; Tessari et
16 al., 2007; Weiss, Rahbari, Hesse & Fink, 2008), and the basal ganglia and thalamus (see Leiguarda,
17 2001, for a review). Moreover, when the meaning of the stimuli was considered, the imitation of MF
18 gestures and ML movements revealed a certain degree of overlap in inferior parietal regions, but also
19 discrete neural correlates for the two stimulus types (see Achilles et al., 2016; Achilles et al., 2019;
20 Bartolo et al., 2001; Goldenberg & Hagmann, 1997; Hoeren et al., 2014; Mengotti et al., 2013;
21 Rumiati et al., 2005; Peigneux, Van der Linden, Garraux, et al., 2004; Tessari et al., 2007). In
22 particular, the direct route that processes ML movements, has been associated with more dorsal or
23 posterior parietal regions, within the dorso-dorsal stream (see Binkofski & Buxbaum, 2013, for a
24 review; Hoeren et al., 2014; Martin, Beume, Kümmerer, et al., 2016a; Martin, Dressing, Bormann, et
25 al., 2016b; Rumiati et al., 2015).

26 However, the semantic route processing MF gestures has been associated with regions within
27 both the ventral stream, encompassing the posterior/superior portion and the anterior portion of
28 the temporal lobe, and the ventro-dorsal stream, including the ventral part of the inferior parietal
29 cortex (Hoeren et al. 2014; Martin et al. 2016a; 2016b; Rijnters, Weiller, Bormann & Musso, 2012;
30 Rumiati et al., 2015; Tessari et al., 2007; Weiller, Bormann, Saur, Musso & Rijnties, 2009; Weiller,
31 Ubben, Kaesberg, Kalbe, Kessler, Liebig & Fink, 2011). The ventral stream is mainly involved in
32 decoding the meaning of a movement and it plays an important role in processing MF intransitive

1 gestures; on the other hand, the ventro-dorsal stream seems to store gesture “engrams”, and it is
2 supposed to process mainly tool-related, transitive MF gestures (Dressing et al., 2018). However,
3 there is some evidence that the ventro-dorsal stream might also support imitation of ML movements
4 (i.e., Buxbaum et al., 2014; Mengotti et al., 2013; Tessari et al., 2007).

5 Action imitation is influenced not only by the meaning of the gesture but also by the body-
6 part that performs it. In particular, a distinction has been made between imitation of finger gestures
7 and imitation of hand/arm gestures, reflecting grasping and reaching, respectively.
8 Neuropsychological studies have long shown that these two motor components, although usually
9 interacting, are relatively independent and can be selectively affected by brain lesions (e.g.,
10 Jeannerod, Decety & Michel, 1994; Shallice, Venable & Rumiati, 2005; Sirigu, Grafman, Bressler &
11 Sunderland, 1991; Poizner, Mack, Verfaellie, Rothi & Heilman, 1990). In particular, a double
12 dissociation in apraxic patients making perseverative errors when pantomiming object use or using
13 them, with either the arm or the hand, was also documented (Shallice et al., 2005). As regards the
14 anatomical substrates, in several studies imitation of ML finger and hand/arm configurations, and
15 sometimes also of MF gestures, was found to be associated with different brain regions depending on
16 the body parts involved in the gestures (Goldenberg & Hagmann, 1997; Goldenberg, 1999; 2001;
17 Goldenberg & Strauss, 2001; Goldenberg & Karnath, 2006). For example, Goldenberg and Karnath
18 (2006) found a behavioural double dissociation between hand and finger imitation, associated with an
19 anatomical anterior (finger)/posterior (hand) dissociation in left brain-damaged patients. Lesions
20 including the inferior frontal operculum generated impairments in imitation of ML finger gestures,
21 while posterior lesions, particularly the posterior parietal lobule, led to impairments in imitation of
22 hand/arm postures (see Doern, Fink, Saliger, Karbe, Koch & Weiss, 2011, Tanaka & Inui, 2001;
23 Tanaka, Inui, Iwaki, Konishi & Nakai, 2001, for similar results). However, other studies led to
24 different results: a study on a larger sample of patients with left hemisphere lesions did not confirm
25 such an anterior/posterior dissociation but reported an association between the dorso-dorsal stream, in
26 particular, the inferior and superior parietal lobe, and the overall ability to imitate ML finger and
27 arm/hand of gestures (Hoeren et al., 2014). Also, Achilles and colleagues (Achilles, Weiss, Fink,
28 Binder, Price & Hope, 2017) investigated the effect of body part (hand/arm vs. finger) only in ML
29 movement imitation in a large sample of patients. They found that hand and finger ML movements
30 share similar neural circuits in the left hemisphere and did not find the double dissociation between
31 hand/arm and finger imitation reported in other studies (e.g., Doern et al., 2011; Goldenberg &

1 Strauss, 2001; Goldenberg & Karnath, 2006). Thus, nowadays a study investigating all possible
2 combinations of gesture meaning (MF vs. ML) and body part (finger vs hand/arm) is still needed.

3 In this study, in a group of unilateral left brain-damaged patients, we tested whether different
4 neuropsychological patterns would emerge depending on not only the meaning of intransitive
5 gestures to be imitated but also to the body part involved (finger vs. hand/arm component). At
6 variance with the studies mentioned above, we employed all possible combinations of the factors
7 affecting imitation: gesture meaning and body part involved in gesture imitation (i.e., both MF and
8 ML gestures involving either fingers and hand/arm). Indeed, previous studies reported differences in
9 imitation processing between finger and hand ML movements (Goldenberg and Karnath, 2006;
10 Achilles et al., 2017), or between MF gestures and ML finger movements (Achilles et al., 2016;
11 2019). Given the confound effects discussed above, we also controlled for the list composition.
12 Moreover, a large sample of MF and ML finger and hand/arm gestures was used in order to
13 overcome a shortcoming of previous studies (see Achilles et al., 2016's criticism).

14 We predicted that the body part involved in the gesture should differentially influence the
15 imitation of MF and ML gestures. A gradient of complexity might emerge between imitation of ML
16 finger and hand/arm gestures, with the former being more difficult to imitate than the latter. Finger
17 gestures seem to be characterized by a greater biomechanical complexity than hand/arm gestures,
18 requiring higher demands on movements precision in configuring all individual fingers (as also
19 suggested by Achilles et al., 2019). On the contrary, MF gestures, being already known, should be
20 recalled as a single chunk from LTM. Therefore finger and hand/arm MF gestures should be
21 imitated to the same extent independently of the body part involved or the gesture complexity.

22 **Methods**

23 **Participants**

24 *Patients.* A group of 36 patients with left hemisphere damage (12 females) took part in the
25 study (mean age= 69.53, SD=12.24; mean education=10.03, SD=4.38; mean months from
26 onset=2.2, SD=1.16). They were recruited in the rehabilitation ward of "Sant'Orsola Malpighi"
27 hospital in Bologna and the rehabilitation and neurological unit of "Ospedali Riuniti" hospital in
28 Trieste. The inclusion criteria were the following: having a single focal unilateral left-hemispheric
29 lesion, according to clinical information and CT or MRI scans; being physically able to complete
30 the experiment; having no history of alcohol or other substance abuse; being younger than 90 years;
31 having at least 3-years of education. All patients suffered from a stroke and were all tested in their
32 chronic state from one to five months from illness onset. The demographic variables are

1 summarized in Table 1. All patients underwent a neuropsychological evaluation in order to assess
 2 general intelligence, language functions, executive functions, memory, visuo-spatial and attentional
 3 abilities. See Table 2 for details.

4 Twenty patients were apraxic to two tests for the diagnosis of ideomotor apraxia: De Renzi
 5 et al.'s test (De Renzi, Motti & Nichelli, 1980; requiring imitation of mixed MF intransitive
 6 gestures and ML movements) and STIMA (Tessari, Toraldo, Lunardelli, Zadini, & Rumiati, 2015;
 7 based on the presentation of separated lists of intransitive MF gestures and ML movements). There
 8 was a very high agreement between the results at the two tests (Cohen's kappa= 0.888).

9 As tool use was not assessed, the diagnosis of apraxia was based on performance in
 10 imitation of intransitive gestures and meaningless movements, clinically referred to as ideomotor
 11 apraxia.

12

	<i>N</i>	Education		♂	♀	Age	
		Mean	SD			Mean	SD
LBD patients	36	10.07	4.40	24	12	69.97	12.16
Controls	29	10.32	3.74	13	16	64.59	10.64
				<i>t</i> (65)=0.252, <i>p</i> > 0.05		<i>t</i> (65)=1.124, <i>p</i> > 0.05	

13 **Table 1** The demographic variables of all participants (patients and healthy controls) who took part
 14 in the study are presented. In the bottom line, *t*-test comparisons are reported for age and
 15 education.

16

Demographic data					Neuropsychological testing (part 1)							
Case	Age	Gender	Education (years)	Testing post-onset (months)	Token Test	Naming	LTM (Prose)	LTM (Rey's Figure)	STM (Corsi)	STM (Span fwd)	WM (Span bwd)	
C1	77	M	13	2	n.a	n.a	n.a	n.a	4.25	4.75	3.21	
C2	72	F	13	1	50*	115	15.00	n.a	5.25	6.75	5.08	
C3	76	F	5	1	36°	15	n.a	n.a	2.25	t.i.	n.a.	
C4	77	M	17	1	50°	0	n.a	n.a	n.a	t.i.	n.a.	
C5	80	M	17	2	9*	109	n.a.	n.a.	5.25	5	n.a.	
C6	47	M	8	2	36°	17	n.a	n.a	3.5	n.a	n.a	
C7	63	F	13	1	14°	102	n.a	n.a	3.25	t.i.	n.a.	
C8	79	F	8	3	25*	83	n.a	n.a	4.5	4	n.a	
C9	73	M	8	2	18°	112	n.a	18.25	2	4.25	3.39	
C10	66	M	8	2	20°	100	9.6	n.a	4	4.25	5.28	
C11	29	F	13	4	50°	n.a.	n.a	n.a	4.5	n.a.	n.a.	
C12	77	M	8	1	28°	107	12.05	n.a	4	4.25	3.52	
C13	77	M	8	1	24°	96	10.85	n.a	4	6.25	2.52	
C14	62	M	8	1	5°	102	n.a	n.a	4.5	4	3	
C15	82	F	12	1	n.a	n.a	n.a	n.a	"	3	n.a.	
C16	57	M	8	2	47*	118	11.05	n.a	3.75	4	2.1	
C17	69	M	17	3	42*	90	6.5	n.a	5	3.5	3.87	
C18	55	M	18	2	n.a	90	n.a	n.a	3.75	4.5	n.a	
C19	64	M	5	2	30°	110	13.5	n.a	3	3.5	3.52	
C20	53	M	18	1	22*	25	n.a	n.a	2.75	3.75	2.5	
C21	78	M	5	5	43°	108	10.9	n.a	5.25	4.5	2.93	
C22	73	F	18	3	n.a	86	n.a	n.a	n.a	3.5	2	
C23	55	F	10	3	n.a	n.a	n.a	n.a	5.25	4.5	n.a	
C24	75	F	5	3	34*	23	n.a	n.a	5.25	4.75	n.a	
C25	81	M	5	2	30*	79	11.6	n.a	4.25	4	3.13	
C26	58	M	8	4	30*	84	n.a	n.a	n.a	2	n.a	
C27	81	F	7	5	34	53	0.5	n.a	4.5	3.25	2.68	

C28	80	M	8	2	31*	87	n.a	n.a	n.a	n.a	n.a
C29	64	F	13	2	14°	21	n.a	29.25	4.25	n.a	n.a
C30	72	F	3	2	31*	88	n.a	n.a	5.25	6.5	6.84
C31	80	M	13	1	47°	118	0.00	n.a	4.25	4	2.37
C32	60	M	13	2	t.i.	t.i.	n.a	n.a	6.25	"	n.a.
C33	87	M	7	4	37°	70	0.75	n.a	3.5	1.25	0.89
C34	64	M	8	1	33°	58	8.5	n.a	4	5.25	3.28
C34	85	M	5	3	30°	93	n.a	25.75	4.5	n.a	n.a
C36	75	M	8		30*	60	n.a	n.a	3	n.a	n.a

Neuropsychological testing (part 2)								Imitation			
Case	Raven	Weigl	TMT A	TMT B	VOSP shape detection	VOSP object decision	IMA (STIM A)	MF		ML	
								finger	hand/arm	finger	hand/arm
C1	33.8	11.75	24	236	20	15	68	8	9	7	9
C2	33.1	10	35	95	20	15	70	9	9	9	8
C3	21.2	7.25	t.i.	t.i.	14	16	54	6	7	5	7
C4	20.8	1.5	194	t.i.	19	12	37	2	4	3	6
C5	27.5	11	35	t.i.	20	18	31	3	2	2	6
C6	34.3	5	59	179	20	18	39	6	5	2	6
C7	21.2	7.25	t.i.	t.i.	14	16	49	4	5	6	7
C8	31	6.5	48	76	20	16	44	4	5	4	6
C9	28.3	10.25	90	452	18	19	48	5	2	6	8
C10	27	6.75	210	752	20	15	61	8	6	5	8
C11	29.8	9.75	36	189	20	17	56	7	5	8	8
C12	16.3	9.25	179	332	20	16	69	9	8	8	8
C13	24.3	5.25	102	262	20	16	42	3	4	1	8
C14	33.4	12.5	33	340	19	19	68	9	9	8	8
C15	19.5	2	303	t.i.	19	n.a.	53	3	6	7	6
C16	23.8	10.25	44	212	18	11	52	4	6	6	8
C17	33.4	9.5	41	194	20	18	72	9	9	9	9
C18	29.6	5.75	n.a	n.a	20	18	68	8	8	9	8
C19	30.9	5.75	110	415	16	18	65	8	8	8	7
C20	19.6	1.75	29	201	20	16	72	9	9	9	9
C21	30	16.5	46	244	19	16	71	9	8	9	9
C22	23	3.25	37	138	19	15	40	2	5	3	5
C23	32.3	n.a	n.a	64	20	19	53	5	7	3	7
C24	35.2	n.a	n.a	n.a	20	19	42	1	5	3	8

C25	24	5	211	427	20	19	53	7	4	4	9
C26	21.4	3.25		t.i.b	19	13	65	8	9	6	8
C27	26.1	3	175	336	20	20	61	8	7	7	7
C28	31.1	9	n.a	4	20	17	54	8	6	5	6
C29	30.4	3.25	172	NA	20	15	65	9	8	6	7
C30	31.5	9	n.a	t.i	19	17	64	9	7	7	7
C31	18.5	12.5	238	545	20	14	63	8	7	7	8
		0									
C32	32.8	8	94	t.i.	20	13	65	8	9	7	7
C33	28.1	1	393	559	15	12	32	0	0	6	5
C34	26	8	195	456	18	16	50	8	6	5	4
C34	32	n.a	147	313	19	17	58	8	6	6	8
C36	33.3	9	n.a	n.a	18	17	58	7	7	5	7

1
2 *Table 2: table consists of three main section a) The demographic variables of patients; b)*
3 *Standardized neuropsychological tests used to assess general intelligence (Raven Progressive*
4 *Matrices PM47, Carlesimo et al., 1996), language functions (Comprehension: *Token test, Spinnler*
5 *and Tognoni., 1987; ° AAT Token test; Production: AAT, naming test Luzzatti, Willmes, De Bleser,*
6 *1996), executive functions (Trail Making Test, part B; Giovagnoli, Del Pesce, Mascheroni,*
7 *Simoncelli, Laiacona, & Capitani, 1996; Weigl’s sorting test; Spinnler & Tognoni, 1987), memory*
8 *(15 words memory test, Rey, 1964; Corsi spatial short-term memory, Spinnler & Tognoni, 1987;*
9 *digit span for verbal short-term memory digit, Orsini, Grossi, Capitani, Laiacona, Papagno, &*
10 *Vallar, 1987), visuo-spatial (VOSP, Visual Object and Space Perception battery; shape detection*
11 *and shape decision; Warrington & James, 1991), attentional (Trail Making Test, part A;*
12 *Giovagnoli et al., 1996) abilities. “t.i.”: test interrupted because the patient was not able to*
13 *perform the task. “n.a.”: test not administered. ^aDeficit due to neglect. Pathological scores are*
14 *reported in bold; c) Raw data of the experimental imitation task (scores are reported out of 9).*
15
16

17 *Controls.* Twenty-nine healthy adults (16 females) served as a control group for the imitation
18 task. The two groups did not differ from the patients’ group for demographic variables (i.e., age,
19 education and gender; independent-samples t-tests, All Ps > 0.05).

20 All participants gave informed consent according to the Declaration of Helsinki. The study
21 was approved by the Ethics Committees of Sant’Orsola-Malpighi Hospital and SISSA.

22

23 **Stimuli and procedure**

24 The experimental task consisted in an imitation task of finger and hand/arm gestures
25 controlled for meaning (both MF and ML gestures). Eighteen known, intransitive (i.e., symbolic)
26 unilateral MF gestures and 18 new, unrecognizable ML movements, matched for complexity with
27 the MF ones were used as stimuli. The gestures are taken from a controlled set of gestures used in
28 previous research (Bonivento, Rumiati, Biasutti, & Humphreys, 2013; Carmo & Rumiati, 2009;

1 Mengotti, Ripamonti, Pesavento, & Rumiati, 2015; Mengotti, Corradi-Dell'Acqua, Negri, Ukmar,
2 Pesavento, & Rumiati, 2013; Tessari et al., 2015; see Appendix 1). Half of both MF and ML
3 gestures involved movements mainly performed with the fingers (i.e., distal movements, for
4 example, the OK gesture). The remaining half gestures involved movements primarily performed
5 with the hand/arm (e.g., the military salute). MF and ML gestures were presented in two consecutive
6 but separate blocks: the MF gestures block was presented first, in order to prevent the patients from
7 selecting the direct route to imitate both types of gestures. Indeed, if the ML gesture block were
8 presented first, this might trigger the selection of the direct route to imitate them and, by inertia,
9 continue to imitate the MF actions using this route, instead of the semantic route. The order in which
10 MF and ML gestures are presented in an imitation task has been proved to be very important in
11 highlighting specific deficits of the semantic and the direct routes (Cubelli et al., 2006; Tessari &
12 Cubelli, 2014; Tessari & Rumiati, 2004; Tessari et al., 2007).

13 Based on previous studies (e.g., Carmo & Rumiati, 2009; Tessari & Rumiati, 2004), an action
14 was considered incorrect if it involved one of the following errors:

15 1) Spatial error: the overall movement is correct, but the hand or the arm posture are moved
16 along the wrong direction, or the wrong plane, or the movement endpoint is not reproduced
17 correctly;

18 2) Visual error: the patient reproduces a movement that is visually similar to the shown one,
19 but it is not included in the list, or she/he merges two gestures included in the list;

20 3) Omission: the patient does not reproduce any gesture;

21 4) Unrecognizable gesture: the patient produces a movement that the experimenter does not
22 recognize.

23 An imitated action was scored 0 if the imitation contained a mistake and 1 if it was correctly
24 imitated. The maximum score of the imitation test is 36: 9 for finger MF gestures and, 9 for
25 hand/arm MF gestures (18 total MF gestures); 9 for finger ML movements, and 9 for hand/arm ML
26 movements (18 total ML movements). The raw scores of the imitation test for each condition are
27 reported in Table 2.

28 The experimenter sat in front of the patient and performed the gestures with the same
29 ipsilesional limb that the patient could use for imitation in a mirror configuration.

30 At the end of the imitation test, patients were required to recognize the previously presented
31 MF gestures to assess whether their semantics was intact or not. All patients performed at the
32 ceiling in the MF gestures recognition.

1 **Lesion analyses**

2 CT or MRI scans were available for 30 of the 36 patients included in the study; therefore,
3 lesion analyses were performed on this number of patients. An experienced neuroradiologist (L.F.),
4 blind to the hypotheses of the study, mapped the lesioned areas of each patient onto the normalized
5 MNI template using MRICron (<https://www.nitrc.org/projects/mricron>; Rorden, Karnath, &
6 Bonilha, 2007).

7 We first inspected our sample by overlaying the lesions of the left brain-damaged patients,
8 thus creating a map of the regions more often lesioned. We then analysed our lesion data adopting
9 the subtraction approach (Rorden and Karnath, 2004). Using MRICroN, the lesions of all patients
10 with defective performance, on the one hand, and those of all patients with normal performance on
11 the other hand, were overlapped separately for each condition. Patients' performance was
12 considered defective or within normal range based on individual t-scores, calculated with the
13 software Singlims_ES
14 (http://homepages.abdn.ac.uk/j.crawford/pages/dept/Single_Case_Effect_Sizes.htm) following the
15 approach described in Crawford and Garthwaite (2005). Data for each participant and for the
16 control group of healthy participants were entered as raw scores. The software provides a t-score for
17 each individual performance and estimates the abnormality of the individual score with respect to
18 the mean performance of the corresponding control sample. Subsequently, the overlap of the group
19 showing no deficit in the condition of interest was subtracted from the overlap of the patients that
20 presented a deficit in that condition. The lesion map generated by the subtraction highlights only the
21 regions that are functionally involved in the task, independently of the anatomical vulnerability of
22 the regions. Even if the subtraction approach is more reliable than simple overlap in highlighting
23 lesioned regions underlying the deficit (and not only the more frequently lesioned regions), it is still
24 a descriptive method that does not allow for statistical inference (de Haan & Karnath, 2018).

25 We first produced subtraction maps of lesioned regions associated with a deficit in imitating
26 overall MF gestures and ML movements and, secondly, more specific maps for finger and hand/arm
27 imitation separately for the two stimulus types. Only regions lesioned in at least 40% of the patients
28 are described and shown, with the exception of the finger ML movements imitation, which are
29 reported at a less restrictive threshold of 25% of patients with a lesion.

1 **Results**

2 *Behavioural results*

3 Overall the group of healthy controls performed better than the patients in the imitation task
4 (independent samples t-test, $t(63) = 5.38$, $p < 0.001$; controls' mean = 33.10, SE = 0.41, and
5 patients' mean = 25.80, SE = 1.17). Healthy controls showed significant differences neither
6 between imitation of MF finger vs. MF hand/arm gestures ($t(28) = .81$, $p = .42$) nor between ML
7 finger vs. ML hand/arm movements ($t(28) = 1.62$, $p = .12$).

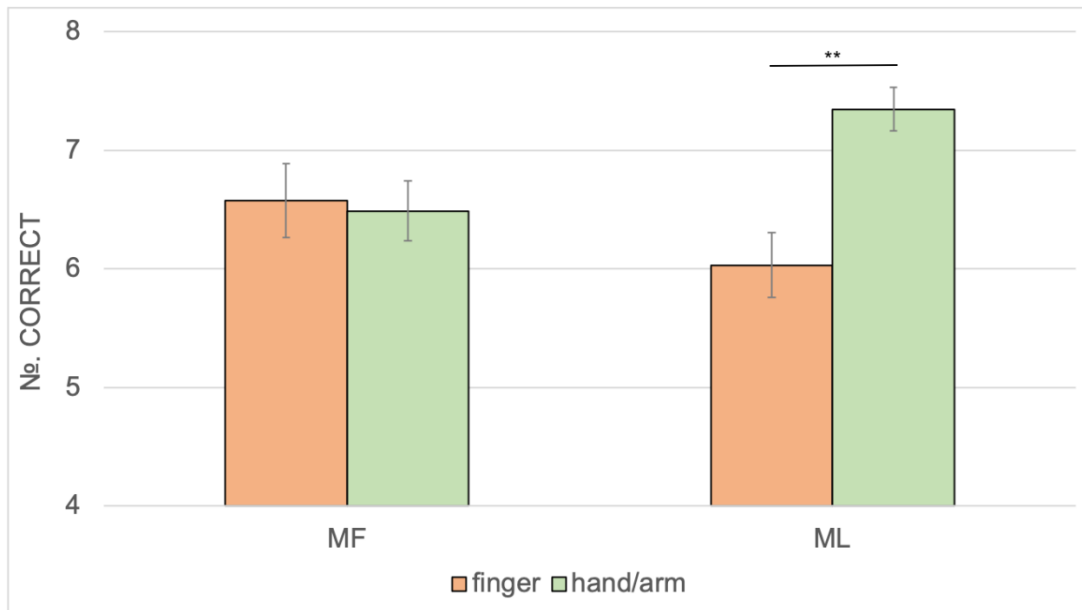
8 We then proceeded analysing only the patients' group by comparing apraxic and non-
9 apraxic patients. The mixed ANOVA on imitation scores included the following factors: Gesture
10 type (MF vs. ML gestures), Body component (fingers vs. hand/arm) as within-subjects factors, and
11 Apraxia (apraxic patients vs. non-apraxic patients) as a between-subjects factor.

12 The Gesture type x Body component interaction was significant ($F(1,34) = 11.87$, $p = 0.001$,
13 $\eta^2 = 0.19$; See Figure 2): Finger movements were imitated to the same extent of hand/arm
14 movements when MF gestures were shown (two tailed t-test with Bonferroni correction, $t(35) =$
15 0.195 , $p = 0.846$; mean MF finger movements = 6.57, SE = 0.31 and mean MF hand/arm
16 movements = 6.49, SE = 0.25), while ML gestures showed a significant difference, with hand/arm
17 movements better imitated than finger ones (two tailed t-test with Bonferroni correction, $t(35) =$
18 4.27 , $p < 0.001$; mean ML finger movements = 6.03 SE = 0.27 and mean ML hand/arm movements
19 = 7.34, SE = 0.18); Gesture type x Apraxia ($F(1,34) = 8.12$, $p = 0.007$; $\eta^2 = 0.19$) and Body
20 component x Apraxia ($F(1,34) = 8.06$, $p = 0.008$, $\eta^2 = 0.19$) interactions were also significant.
21 Apraxic patients imitated MF and ML gestures to the same extent ($t(19) = 2.05$, $p = 0.055$; mean
22 MF gestures = 4.25, SE = 0.32 and mean ML gestures = 5.62, SE = 0.24), whereas non-apraxic
23 patients imitated MF better than ML gestures ($t(15) = 3.91$, $p = 0.006$; mean MF gestures = 8.31,
24 SE = 0.36 and mean ML gestures = 7.75, SE = 0.26). Non-apraxic patients imitated both finger and
25 hand/arm gestures at the same extent ($t(15) = 0.00$, $p = 1$), but apraxic patients showed a difference
26 between the two body components ($t(19) = 3.42$, $p = 0.003$), with less accurate performance on
27 finger gestures (mean = 4.57, SE = 0.31) than hand/arm ones (mean = 5.80, SE = 0.22).

28 Moreover, the main factors Body component and Apraxia were significant. Overall,
29 hand/arm gestures were better imitated than the finger ones ($F(1,34) = 8.06$, $p = 0.008$, $\eta^2 = 0.19$;
30 finger gestures = 6.30, SE = 0.23, and hand/arm gestures = 6.92, SE = 0.17), and non-apraxic
31 patients imitated more gestures than the apraxic ones ($F(1,34) = 68.66$, $p < 0.001$, $\eta^2 = 0.67$; mean

1 apraxic patients = 5.19, SE = 0.23 and mean non-apraxic patients = 8.03, SE = 0.26). The Gesture
2 type factor was not significant.

3



4

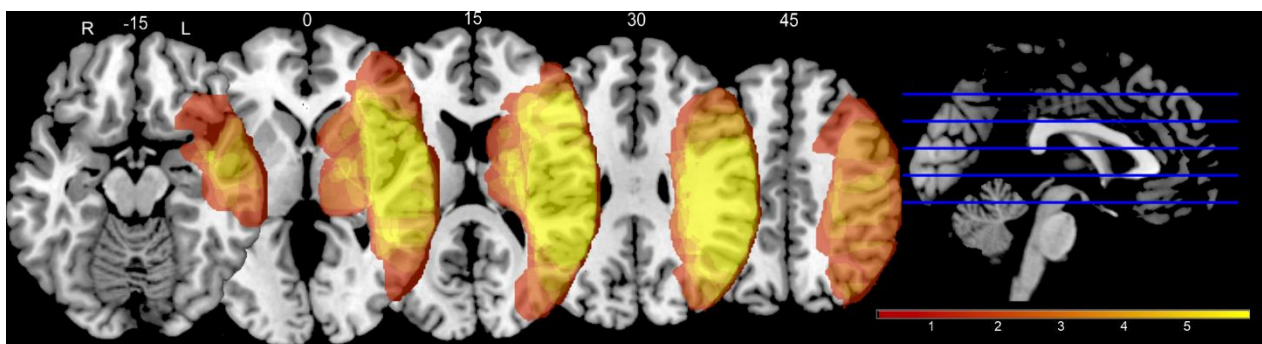
5 **Figure 2.** The two-way Gesture type x Meaning interaction performed on patients' data (both
6 apraxic and non-apraxic patients) is displayed. Average scores of correctly imitated actions are
7 presented for both meaningful (MF) and meaningless (ML) gestures according to the involved body
8 district. Error bars represent the standard error of the mean.

9

10 Lesion analysis

11 We first inspected our sample by overlaying the lesions of the left brain-damaged patients,
12 thus creating a map of the regions more often lesioned (see Figure 3).

13



14

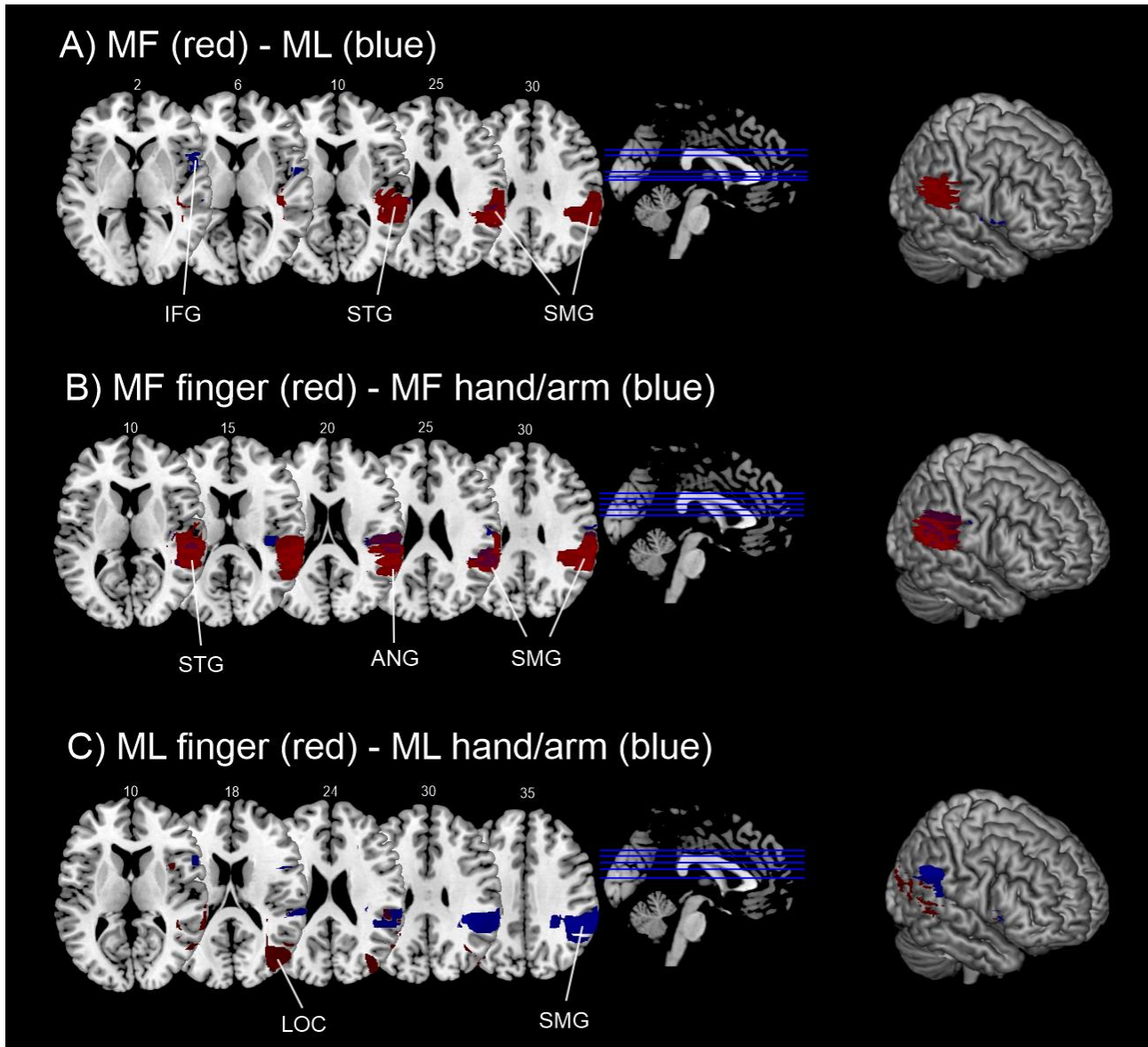
15 **Figure 3.** Results of the lesions overlap for all patients.

1
2
3
4
5
6
7
8
9
10
11
12
13
14
15
16
17
18
19
20
21
22
23
24
25
26
27
28
29
30
31

Then, we performed a subtraction analysis for each stimulus type, first distinguishing the stimuli according to their meaning (MF vs. ML) and, secondly, distinguishing them according to the effector used to imitate (finger vs. hand/arm), separately for MF and ML gestures. We subtracted the lesioned regions of patients without an imitation deficit in that specific type of gesture (no-deficit group) from the lesioned regions of the patients that showed a deficit in imitation of the respective type of gesture, as established on the basis of the t-scores calculated on individual patients' performance (see Methods).

Lesions in patients with impaired imitation of MF gestures, after subtracting the lesions of the no-deficit group, involved mainly the inferior parietal lobe, including supramarginal and angular gyri, parietal operculum and the posterior part of the superior and middle temporal gyri. In contrast, lesions in patients with impaired imitation of ML movements, after subtracting the lesions of the no-deficit group, involved mainly inferior frontal regions, including small parts of the inferior frontal gyrus, central and frontal operculum, but also a small part of the supramarginal gyrus, overlapping with the correlates of MF gestures imitation (see Figure 4A).

Within MF gestures, regions lesioned in patients with impaired imitation in finger gestures, after subtracting the lesions of the no-deficit group, were mainly located in the superior temporal gyrus, the planum temporale, the parietal operculum, the supramarginal and angular gyri. Again, within MF gestures, regions lesioned in patients with impaired imitation in hand/arm gestures, after subtracting the lesions of the no-deficit group, were mainly located in the middle temporal gyrus, the planum temporale, the parietal operculum, the temporo-occipital junction, the supramarginal and angular gyri (see Figure 4B). Within ML movements, regions lesioned in patients with impaired imitation in finger movements, after subtracting the lesions of the no-deficit group (using a less restrictive threshold of percentage of patients lesioned), were mainly located in the middle temporal gyrus, the temporo-occipital junction, and the lateral occipital cortex. In contrast, the regions lesioned in patients with impaired imitation in hand/arm movements, after subtracting the lesions of the no-deficit group, were mainly located in the inferior frontal, supramarginal and angular gyri (see Figure 4C). In addition, small clusters both for finger and hand/arm ML movements were located in inferior frontal regions, involving, in particular, the insular cortex for finger and the inferior frontal gyrus for hand/arm ML movements.



1

2 **Figure 4.** Results of the subtraction analysis. Regions specifically damaged in the group of
 3 patients that presented a deficit in the condition of interest are shown, after subtraction from the
 4 group of patients that did not present a deficit in that condition. The subtraction maps for the
 5 different types of gestures were then superimposed only for display purposes. A) Subtraction maps
 6 for overall MF (in red) and ML gesture imitation (in blue). The overlap between the two conditions
 7 is shown in violet. B) Subtraction maps for MF finger (in red) and MF hand/arm gesture imitation
 8 (in blue). C) Subtraction maps for ML finger (in red) and ML hand/arm movements imitation (in
 9 blue). Only regions lesioned in at least 40% of the patients are shown, only for ML finger
 10 movements regions lesioned in at least 25% of the patients are shown. IFG: inferior frontal gyrus;
 11 INS: insula; MTG: middle temporal gyrus; superior temporal gyrus; ANG: angular gyrus; SMG:
 12 supramarginal gyrus; LOC: lateral occipital cortex.

1 **Discussion**

2 In this study, for the first time, the imitation of either finger or hand/arm components of both
3 MF and ML gestures was compared and analysed. In particular, this is the first study to investigate
4 the difference between finger and hand/arm in MF gestures, as previous studies investigated this
5 aspect only in ML gestures (e.g., Goldenberg and Karnath, 2006; Achilles et al., 2017) or restricted
6 their investigation to MF and ML finger gestures (Achilles et al., 2016; 2019).

7 We tested whether different neuropsychological patterns emerge in left brain-damaged
8 patients, according to not only the meaning of the gesture but also the body parts involved (i.e.,
9 fingers vs. hand/arm). Indeed, we predicted a different pattern for ML and MF gestures. Imitation of
10 ML movements should reflect a gradient of complexity from hand/arm movements to finger
11 movements as the biomechanical constraints are more complicated for finger movements than for
12 hand/arm movements. On the contrary, MF gestures are likely to be less taxed by the structural and
13 biomechanical complexity of the movement as they should benefit from being represented in LTM.
14 Such a behavioural prediction also suggests that possible neuroanatomical segregation depending on
15 the body part might emerge in ML but not MF gestures.

16 At a behavioral level, the main result is the Gesture type x Body component interaction,
17 indicating that left-brain damaged patients imitated finger ML movements worse than hand/arm ML
18 ones, while no differences between finger and hand/arm MF gestures emerged. Such a different
19 pattern of results is interpreted as MF gestures being retrieved as a whole from LTM, without being
20 broken down into chunks, thus not taxing cognitive resources as ML movements do (see Rumiati &
21 Tessari, 2002, for a detailed discussion on the role of meaning on motor WM; Tessari & Rumiati,
22 2004; Tessari et al., 2007). It has been demonstrated that ML movements tax the motor WM system
23 more than MF gestures whose production is facilitated by being already in one's gesture repertoire.
24 In a series of experiments using a dual-task procedure, the existence of a motor short-term/WM
25 system that retains both ML and MF gestures for a limited time was established (Rumiati & Tessari,
26 2002). We proved that a secondary motor suppression task affected gesture encoding and retention
27 more for ML movements than for MF ones, showing that ML movements were more difficult to
28 encode and retain. Moreover, once learned, ML movements were imitated at the same extent of MF
29 gestures through the semantic route (Tessari et al., 2006). In addition, we showed that a finger
30 motor suppression task interfered more with the encoding of gestures than a hand/arm suppression
31 task (Tessari & Rumiati, 2002). The finger suppression task seems to require more cognitive
32 resources than the hand/arm task, leading to reduced motor span. Thus, ML finger movements

1 might be particularly sensitive in differentiating between patients with and without apraxia as the
2 direct route for processing ML movements is more resource-demanding and error-prone than the
3 semantic route for processing MF gestures (Dovern et al., 2012; Tessari & Rumiati, 2004).

4 This difference emerged because, at variance with other studies (see Toraldo et al., 2003),
5 we controlled for the list composition effect by presenting MF and ML stimuli in separate lists.
6 Indeed, when (finger and hand/arm) MF gestures are presented in the same list, the semantic route
7 is selected; and the (left hemisphere) damage affects imitation of either finger or hand/arm gestures
8 equally, since these gestures are stored in LTM. On the other hand, the imitation of ML movements
9 differed depending on the body part involved, with finger movements being more error-prone than
10 the hand/arm ones, in line with previous evidence (e.g., Achilles et al., 2016). Imitation through the
11 direct route is more resource-demanding (as a decomposition/re-composition into elementary motor
12 units is necessary), and finger imitation is likely to engage also visuospatial abilities and a more
13 complex brain network than hand imitation. Goldenberg and Karnath (2006) suggested that finger
14 imitation is more complex than hand/arm postures as it also includes a cognitive component of
15 “selection” of the appropriate elements, involving the IFG as brain region supporting this additional
16 process. According to these authors, finger configurations involve the selection of a limited set of
17 elements that only differ in their serial position. They also found a double dissociation between
18 hand and finger imitation, paired with an anatomical anterior (finger)/posterior (hand) dissociation
19 in left brain-damaged patients. However, a study on a larger sample of patients with left hemisphere
20 lesions did not confirm such an anterior/posterior dissociation but showed instead an association
21 between the dorso-dorsal stream, in particular the inferior and superior parietal lobe, and the overall
22 ability to imitate ML finger and hand/arm gestures (Hoeren et al., 2014).

23 Likewise, in the present study apraxic patients showed this difficulty gradient in imitation of
24 the two body components, with a worse imitation performance on finger than hand/arm gestures,
25 whereas non-apraxic patients imitated both finger and hand/arm gestures to the same extent. This
26 pattern was probably driven by the ML movements, despite a non-significant triple interaction.

27 Additionally, apraxic patients’ imitation did not differ depending on the meaning of the
28 stimulus (MF and ML), whereas non-apraxic patients imitated MF gestures better than ML
29 movements. Previous studies with both patients and healthy individuals are consistent with the
30 present results, as they show better imitation of MF gestures than ML movements (e.g., Achilles et
31 al., 2016; 2019; Cubelli et al., 2000; Rumiati & Tessari, 2002; Tessari and Rumiati, 2004; Tessari
32 et al., 2007; Press & Heyes, 2012). As regards the failure to observe a difference between MF and

1 ML in the apraxic patients, this is not surprising as the ability to imitate and produce MF gestures
2 are often impaired in apraxia (e.g., Heilman & Rothi, 2003; Leiguarda & Marsden, 2000) and brain
3 lesions might affect the two routes at the same time.

4 The lesion analysis results are generally supportive of the involvement for the ventro-dorsal
5 stream for imitation of MF intransitive gestures, encompassing the inferior parietal lobe, in line with
6 previous evidence (Buxbaum, Shapiro & Coslett, 2014; Dressing et al., 2018; Hoeren et al., 2014;
7 Lesourd, Osiurak, Baumard, Bartolo, Vanbellingen & Reynaud, 2018; Mengotti et al., 2013; Tessari
8 et al., 2007). The subtraction analysis concerning imitation of ML movements revealed a small
9 overlap with the lesion correlates of imitation of MF gestures in the supramarginal gyrus,
10 suggesting that the ventro-dorsal stream might also support imitation of unknown movements.
11 Whether the ventro-dorsal stream supports imitation of ML movements is still open to debate, with
12 contrasting findings. Some studies indeed reported the involvement of the inferior parietal lobe in
13 imitation of ML movement (e.g., Buxbaum et al., 2014; Lesourd et al., 2018; Mengotti et al., 2013;
14 Mühlau, Hermsdörfer, Goldenberg et al., 2005; Tessari et al., 2007), whereas other studies
15 implicated the dorso-dorsal stream in imitation of ML movements (e.g., Hoeren et al., 2014; Martin
16 et al., 2016a; 2016b; Vry et al., 2015). Additionally, imitation of ML movements was associated
17 with the involvement of the inferior frontal gyrus. The IFG has been frequently found to be
18 involved in imitation of gestures, especially in neuroimaging studies (Caspers, Zilles, Laird, &
19 Eickhoff, 2010, for a meta-analysis), as well as in imitation of ML finger postures (Goldenberg &
20 Karnath, 2006). However, the IFG involvement in imitation of MF gestures could also be due to its
21 role of interface between language and action (Weiss; Ubben, Kaesberg, et al., 2016) or in
22 processing intransitive MF gestures (in the left hemisphere, see Lesourd et al., 2018, for a recent
23 review).

24 Regarding the role of the ventral stream, the involvement of the middle temporal gyrus in
25 imitation of MF gestures is in line with previous neuropsychological observations (e.g., Kalenine,
26 Buxbaum & Coslett, 2010) but also with the higher blood signal response to intransitive gestures
27 compartmented to transitive ones in the middle portion of the left middle temporal gyrus in healthy
28 participants (Papeo, Agostini & Lignau, 2019). At odds with other studies (e.g., Dressing et al.,
29 2016; Hoeren et al. 2014; Martin et al. 2016a; 2016b; Rijnters et al., 2012; Rumiati et al., 2015;
30 Tessari et al., 2007; Weiller et al., 2009; 2011), the lesion analysis did not reveal the involvement of
31 the anterior portion of the temporal lobe. Consistently with this finding, we also observed that none

1 of the patients failed to recognize the MF gestures, suggesting that they have a normal ability to
2 extract the meaning from the presented MF gestures whose conceptual representation was intact.

3 As for specific lesion correlates of finger and hand/arm imitation within MF and ML
4 gestures, lesion analysis associated the poor performance in imitation of finger or hand/arm ML
5 movements with lesions to different regions depending on the body part involved. In contrast,
6 imitation of finger and hand/arm MF gestures seemed to involve the same regions of the inferior
7 parietal lobe, including the supramarginal and angular gyri. Overall, we did not find an
8 anterior/posterior dissociation based on the body part involved in the movement, in contrast with
9 Goldenberg & Karnath (2006), and more in line with other recent studies (Achilles et al., 2017;
10 Hoeren et al., 2014). Focusing on hand/arm gestures, both for MF and ML, an impairment in
11 imitating these gestures seemed to be associated with lesions to similar regions of the inferior
12 parietal lobe, particularly the supramarginal gyrus. Additionally, imitation of hand/arm ML
13 movements seemed to be associated with lesions to the inferior frontal gyrus, at odds with previous
14 literature (e.g., Goldenberg & Karnath, 2006; Tanaka & Inui, 2002). However, the IFG was also
15 found for the subtraction analysis for imitation of overall ML movements, suggesting a more
16 general role of this region, as previously discussed. Impairment in imitation of finger gestures, on
17 the contrary, seemed to be associated with a more diverse network, not only encompassing the
18 inferior parietal lobe for MF gestures, but also lateral occipital regions for ML movements. This
19 result is generally supportive of the hypothesis of finger gestures as being intrinsically more
20 complex for imitation, with the semantic aspect of imitation (MF gestures) coded in the ventro-
21 dorsal stream, and further non-semantic aspects processed elsewhere, possibly in the inferior frontal
22 gyrus and in the dorso-dorsal system as shown in previous studies (Goldenberg & Karnath, 2006;
23 Hoeren et al., 2014; Achilles et al., 2019), or in occipito-temporal regions, such as the lateral
24 occipital cortex (LOC), as suggested by the present results. The LOC is a high-order visual area
25 usually involved in object recognition (Grill-Spector et al., 1999; Larsson and Heeger, 2006). The
26 need for visual processing of complex stimuli such as finger configurations might explain this
27 region's involvement. The temporo-occipital cortex has been reported in patients as a lesion
28 correlate of imitation of both ML movements as well as pantomimes (Hoeren et al., 2014), as well
29 as in healthy participants as neural correlates of ML movements imitation (Rumiati et al., 2005).
30 This region is possibly forwarding higher-order visual information to the parietal lobe for imitation
31 processing.

32

1 To conclude, the present results enrich the extant knowledge on imitation. By investigating
2 both the effects of body-part specificity and meaning in apraxic and non-apraxic patients, we were
3 able to show how the body-part does not modulate imitation of MF gestures. In contrast, a different
4 pattern is observed for ML movements, with reduced imitation of those involving finger
5 configurations. In addition, the present results support the importance of considering not only
6 gesture meaning and body-part specificity, but also gesture list composition, in studies investigating
7 imitation in patients, and apraxia particularly. Thus, controlling for list composition must become a
8 methodological requirement for future studies.

9

10 **Conclusion**

11 In the present study, we demonstrated that finger and hand/arm movements were
12 differentially processed in imitation of ML movements, whereas imitation of MF gestures showed
13 no such dissociation. This is in line with the existing cognitive theories of the dual routes of gesture
14 imitation: in the imitation of MF gestures, the primary role is played by the stored motor
15 representations in LTM recalled as meaningful chunks, independently of the body part involved in
16 the movement; on the contrary, when ML movements are imitated, the direct route of visuomotor
17 conversion is used, including body-part specific mechanisms.

1 **Acknowledgment:** This study was supported by a grant from the Fondazione Cassa di Risparmio di
2 Bologna (n.2005/2445), in which AT and GT were involved.

3

4 **Competing interests**

5 The authors report no competing interests.

6

7 **Authors' contribution:** **A.T.:** Conceptualization, Methodology, Formal analysis, Data
8 curation, Writing- Original draft preparation; Writing- Reviewing and Editing; Supervision;
9 Funding acquisition; **P.M.:** Formal analysis, Data curation, Writing- Original draft preparation;
10 Writing- Reviewing and Editing; Visualization; **L.F.:** Data curation; **G.T.:** Funding, Supervision;
11 **S.B.:** Investigation; **M.T.:** Resources; Supervision; **R.I.R.:** Writing- Reviewing and Editing.

12

1 **References**

- 2 Achilles, E. I. S., Fink, G. R., Fischer, M. H., Dovern, A., Held, A., Timpert, D. C., ... & Weiss, P.
3 H. (2016). Effect of meaning on apraxic finger imitation deficits. *Neuropsychologia*, 82, 74-
4 83.
- 5 Achilles, E. I., Ballweg, C. S., Niessen, E., Kusch, M., Ant, J. M., Fink, G. R., & Weiss, P.
6 H. (2019). Neural correlates of differential finger gesture imitation deficits in left
7 hemisphere stroke. *NeuroImage: Clinical*, 23, 101915.
- 8 Achilles, E. I., Weiss, P. H., Fink, G. R., Binder, E., Price, C. J., & Hope, T. M. (2017).
9 Using multi-level Bayesian lesion-symptom mapping to probe the body-part-specificity
10 of gesture imitation skills. *NeuroImage*, 161, 94-103.
- 11 Bartolo, A., Cubelli, R., Della Sala, S., Drei, S., e Marchetti, C. (2001). Double dissociation
12 between meaningful and meaningless gesture production in apraxia. *Cortex*, 37, 696-
13 699.
- 14 Basso, A., Luzzatti, C., & Spinnler, H. (1980). Is ideomotor apraxia the outcome of damage to
15 well-defined regions of the left hemisphere? Neuropsychological study of CAT correlation.
16 *Journal of Neurology, Neurosurgery & Psychiatry*, 43(2), 118-126.
- 17 Bonivento, C., Rumiati, R. I., Biasutti, E., & Humphreys, G. W. (2013). The role of the basal
18 ganglia in action imitation: neuropsychological evidence from Parkinson's disease patients.
19 *Experimental brain research*, 224(2), 211-220.
- 20 Binkofski, F., & Buxbaum, L. J. (2013). Two action systems in the human brain. *Brain and*
21 *language*, 127(2), 222-229.
- 22 Buxbaum, L. J., & Randerath, J. (2018). Limb apraxia and the left parietal lobe. In *Handbook of*
23 *clinical neurology* (Vol. 151, pp. 349-363). Elsevier.

1 Buxbaum, L. J., Shapiro, A. D., & Coslett, H. B. (2014). Critical brain regions for tool-related and
2 imitative actions: a componential analysis. *Brain*, *137*(7), 1971-1985.

3 Carlesimo, G. A., Caltagirone, C., Gainotti, G. U. I. D., Fadda, L., Gallassi, R., Lorusso, S., ... &
4 Parnetti, L. (1996). The mental deterioration battery: normative data, diagnostic reliability
5 and qualitative analyses of cognitive impairment. *European Neurology*, *36*(6), 378-384.

6 Carmo, J. C., & Rumiati, R. I. (2009). Imitation of transitive and intransitive actions in healthy
7 individuals. *Brain and cognition*, *69*(3), 460-464.

8 Caspers, S., Zilles, K., Laird, A. R., & Eickhoff, S. B. (2010). ALE meta-analysis of action
9 observation and imitation in the human brain. *Neuroimage*, *50*(3), 1148-1167.

10 Crawford, J. R., & Garthwaite, P. H. (2005). Testing for suspected impairments and dissociations
11 in single-case studies in neuropsychology: evaluation of alternatives using monte carlo
12 simulations and revised tests for dissociations. *Neuropsychology*, *19*(3), 318.

13 Cubelli, R., Bartolo, A., Nichelli, P., & Della Sala, S. (2006). List effect in apraxia assessment.
14 *Neuroscience letters*, *407*(2), 118-120.

15 Cubelli, R., Marchetti, C., Boscolo, G., e Della Sala, S. (2000). Cognition in action: Testing a
16 model of limb apraxia. *Brain and Cognition*, *44*, 144-165.

17 de Haan, B., & Karnath, H. O. (2018). A hitchhiker's guide to lesion-behaviour
18 mapping. *Neuropsychologia*, *115*, 5-16.

19 De Renzi, E. & Faglioni, P. (1999). Apraxia. In Denes G and Pizzamiglio L (Eds), Handbook
20 of Clinical and Experimental Neuropsychology. Hove: Psychology Press, 1999, pp. 421-
21 440.

22 De Renzi, E., Motti, F., & Nichelli, P. (1980). Imitating gestures: a quantitative approach to
23 ideomotor apraxia. *Archives of Neurology*, *37*(1), 6-10.

- 1 Dovern, A., Fink, G. R., Saliger, J., Karbe, H., Koch, I., & Weiss, P. H. (2011). Apraxia impairs
2 intentional retrieval of incidentally acquired motor knowledge. *Journal of Neuroscience*,
3 31(22), 8102-8108.
- 4 Dressing, A., Nitschke, K., Kümmerer, D., Bormann, T., Beume, L., Schmidt, C. S., ... & Kaller,
5 C. P. (2018). Distinct contributions of dorsal and ventral streams to imitation of tool-use and
6 communicative gestures. *Cerebral Cortex*, 28(2), 474-492.
- 7 Geschwind, N. (1965). Disconnexion syndromes in animal and man. *Brain*, 88, 585–644.
- 8 Giovagnoli, A. R., Del Pesce, M., Mascheroni, S., Simoncelli, M., Laiacona, M., & Capitani, E.
9 (1996). Trail making test: normative values from 287 normal adult controls. *The Italian*
10 *Journal of Neurological Sciences*, 17(4), 305-309.
- 11 Goldenberg, G. (1999). Matching and imitation of hand and finger postures in patients with
12 damage in the left or right hemispheres. *Neuropsychologia*, 37(5), 559-566.
- 13 Goldenberg, G. (2001). Imitation and matching of hand and finger postures. *Neuroimage*, 14(1),
14 S132-S136.
- 15 Goldenberg, G., & Hagmann, S. (1997). The meaning of meaningless gestures: A study of visuo-
16 imitative apraxia. *Neuropsychologia*, 35(3), 333-341.
- 17 Goldenberg, G., & Karnath, H. O. (2006). The neural basis of imitation is body part specific.
18 *Journal of Neuroscience*, 26(23), 6282-6287.
- 19 Goldenberg, G., & Randerath, J. (2015). Shared neural substrates of apraxia and aphasia.
20 *Neuropsychologia*, 75, 40-49.
- 21 Goldenberg, G., & Strauss, S. (2002). Hemisphere asymmetries for imitation of novel gestures.
22 *Neurology*, 59(6), 893-897.

1 Grill-Spector, K., Kushnir, T., Edelman, S., Avidan, G., Itzhak, Y., & Malach, R. (1999).
2 Differential processing of objects under various viewing conditions in the human lateral
3 occipital complex. *Neuron*, 24(1), 187-203.

4 Hoeren, M., Kümmerer, D., Bormann, T., Beume, L., Ludwig, V. M., Vry, M. S., ... & Weiller, C.
5 (2014). Neural bases of imitation and pantomime in acute stroke patients: distinct streams
6 for praxis. *Brain*, 137(10), 2796-2810.

7 Kalénine, S., Buxbaum, L. J., & Coslett, H. B. (2010). Critical brain regions for action
8 recognition: lesion symptom mapping in left hemisphere stroke. *Brain*, 133(11), 3269-3280.

9 Jeannerod, M., Decety, J., & Michel, F. (1994). Impairment of grasping movements following a
10 bilateral posterior parietal lesion. *Neuropsychologia*, 32(4), 369-380.

11 Larsson, J., & Heeger, D. J. (2006). Two retinotopic visual areas in human lateral occipital cortex.
12 *Journal of neuroscience*, 26(51), 13128-13142.

13 Lesourd, M., Osiurak, F., Baumard, J., Bartolo, A., Vanbellingen, T., & Reynaud, E. (2018).
14 Cerebral correlates of imitation of intransitive gestures: An integrative review of
15 neuroimaging data and brain lesion studies. *Neuroscience & biobehavioral reviews*, 95, 44-
16 60.

17 Luzzatti, C., Willmes, K., De Bleser, R. (1996). Aachener Aphasie Test (AAT)-versione italiana.
18 Organizzazioni Speciali, Firenze.

19 Martin, M., Beume, L., Kümmerer, D., Schmidt, C. S., Bormann, T., Dressing, A., ... & Kaller, C.
20 P. (2016). Differential roles of ventral and dorsal streams for conceptual and production-
21 related components of tool use in acute stroke patients. *Cerebral Cortex*, 26(9), 3754-3771.

22 Martin, M., Dressing, A., Bormann, T., Schmidt, C. S., Kümmerer, D., Beume, L., ... & Weiller,
23 C. (2017). Componential network for the recognition of tool-associated actions: evidence

1 from voxel-based lesion-symptom mapping in acute stroke patients. *Cerebral Cortex*, 27(8),
2 4139-4152.

3 Mengotti, P., Corradi-Dell'Acqua, C., Negri, G. A., Ukmar, M., Pesavento, V., & Rumiati, R. I.
4 (2013). Selective imitation impairments differentially interact with language processing.
5 *Brain*, 136(8), 2602-2618.

6 Mengotti, P., Corradi-Dell'Acqua, C., Negri, G. A., Ukmar, M., Pesavento, V., & Rumiati, R. I.
7 (2013). Selective imitation impairments differentially interact with language processing.
8 *Brain*, 136(8), 2602-2618.

9 Mengotti, P., Ripamonti, E., Pesavento, V., & Rumiati, R. I. (2015). Anatomical and spatial
10 matching in imitation: Evidence from left and right brain-damaged patients.
11 *Neuropsychologia*, 79, 256-271.

12 Mühlau, M., Hermsdörfer, J., Goldenberg, G., Wohlschläger, A. M., Castrop, F., Stahl, R., ... &
13 Conrad, B. (2005). Left inferior parietal dominance in gesture imitation: an fMRI study.
14 *Neuropsychologia*, 43(7), 1086-1098.

15 Orsini, A., Grossi, D., Capitani, E., Laiacona, M., Papagno, C., & Vallar, G. (1987). Verbal and
16 spatial immediate memory span: normative data from 1355 adults and 1112 children. *The*
17 *Italian Journal of Neurological Sciences*, 8(6), 537-548.

18 Papeo, L., Agostini, B., & Lingnau, A. (2019). The Large-Scale organization of gestures and
19 words in the middle temporal gyrus. *Journal of Neuroscience*, 39(30), 5966-5974.

20 Peigneux, P., Van der Linden, M., Garraux, G., Laureys, S., Degueldre, C., Aerts, J., ... &
21 Salmon, E. (2004). Imaging a cognitive model of apraxia: The neural substrate of
22 gesture-specific cognitive processes. *Human brain mapping*, 21(3), 119-142.

1 Poizner, H., Mack, L., Verfaellie, M., Rothi, L. J. G., & Heilman, K. M. (1990). Three-
2 dimensional computergraphic analysis of apraxia: neural representations of learned
3 movement. *Brain*, *113*(1), 85-101.

4 Press, C., & Heyes, C. (2008). Stimulus-driven selection of routes to imitation. *Experimental*
5 *brain research*, *188*(1), 147.

6 Ray E, Heyes C. (2011). Imitation in infancy: the wealth of the stimulus. *Developmental Science*,
7 *14*, 92–105.

8 Rijntjes, M., Weiller, C., Bormann, T., & Musso, M. (2012). The dual loop model: its relation to
9 language and other modalities. *Frontiers in evolutionary neuroscience*, *4*, 9.

10 Rorden, C., & Karnath, H. O. (2004). Using human brain lesions to infer function: a relic from a
11 past era in the fMRI age?. *Nature Reviews Neuroscience*, *5*(10), 812.

12 Rorden, C., Karnath, H. O., & Bonilha, L. (2007). Improving lesion-symptom mapping. *Journal of*
13 *cognitive neuroscience*, *19*(7), 1081-1088.

14 Rothi, L. J. G., & Heilman, K. M. (1985). Ideomotor apraxia: Gestural discrimination,
15 comprehension and memory. In *Advances in psychology* (Vol. 23, pp. 65-74). North-
16 Holland.

17 Rothi, L.J.G., Ochipa, C., e Heilman, K.M. (1991). A cognitive neuropsychological model of limb
18 praxis. *Cognitive Neuropsychology*, *8*, 443-458.

19 Rumiati, R. I., & Bekkering, H. (2003). To imitate or not to imitate? How the brain can do it, that
20 is the question!. *Brain and Cognition*, *53*(3), 479-482.

21 Rumiati, R. I., Weiss, P. H., Tessari, A., Assmus, A., Zilles, K., Herzog, H., & Fink, G. R. (2005).
22 Common and differential neural mechanisms supporting imitation of meaningful and
23 meaningless actions. *Journal of Cognitive Neuroscience*, *17*(9), 1420-1431.

1 Rumiati, R.I., & Tessari, A. (2002). Imitation of novel and well-known actions: the role of short-
2 term memory. *Experimental Brain Research*, *142*, 425-433.

3 Sebastianutto, L., Mengotti, P., Spiezio, C., Rumiati, R. I., & Balaban, E. (2017). Dual-route
4 imitation in preschool children. *Acta psychologica*, *173*, 94-100.

5 Shallice, T., Venable, N., & Rumiati, R. I. (2005). Dissociable distal and proximal motor
6 components: Evidence from perseverative errors in three apraxic patients. *Cognitive*
7 *Neuropsychology*, *22*(5), 625-639.

8 Sirigu, A., Cohen, L., Duhamel, J. R., Pillon, B., Dubois, B., & Agid, Y. (1995). A selective
9 impairment of hand posture for object utilization in apraxia. *Cortex*, *31*(1), 41-55.

10 Sirigu, A., Grafman, J., Bressler, K., & Sunderland, T. (1991). Multiple representations contribute
11 to body knowledge processing: Evidence from a case of autotopagnosia. *Brain*, *114*(1), 629-
12 642.

13 Spinnler, H., & Tognoni, G. (1987). Standardizzazione e taratura italiana di test neuropsicologici.
14 Italian standardization and validation neuropsychological tests. *Italian Journal of*
15 *Neurological Sciences*, *6*, suppl. 8, 1-20.

16 Tanaka, S., & Inui, T. (2002). Cortical involvement for action imitation of hand/arm postures
17 versus finger configurations: an fMRI study. *Neuroreport*, *13*(13), 1599-1602.

18 Tanaka, S., Inui, T., Iwaki, S., Konishi, J., & Nakai, T. (2001). Neural substrates involved in
19 imitating finger configurations: an fMRI study. *Neuroreport*, *12*(6), 1171-1174.

20 Tessari, A., & Cubelli, R. (2014). Route selection in action imitation: a matter of strategic choice?.
21 *Cortex; a journal devoted to the study of the nervous system and behavior*, *57*, 277-8.

22 Tessari, A., & Rumiati, R.I. (2004). The strategic control of multiple routes in imitation of
23 actions. *Journal of Experimental Psychology: Human Perception and Performance*, *30*,
24 1107–1116.

- 1 Tessari, A., Bosanac, D., & Rumiati, R. I. (2006). Effect of learning on imitation of new actions:
2 implications for a memory model. *Experimental brain research*, 173(3), 507-513.
- 3 Tessari, A., Canessa, N., Ukmar, M., & Rumiati, R. I. (2007). Neuropsychological evidence for a
4 strategic control of multiple routes in imitation. *Brain*, 130(4), 1111-1126.
- 5 Tessari, A., Toraldo, A., Lunardelli, A., Zadini, A., & Rumiati, R. I. (2015). STIMA: a short
6 screening test for ideo-motor apraxia, selective for action meaning and bodily district.
7 *Neurological Sciences*, 36(6), 977-984.
- 8 Tomasello M, Savage-Rumbaugh S, Kruger AC. (1993) Imitative learning of actions on objects
9 by children, chimpanzees, and enculturated chimpanzees. *Child Development*, 64, 1688–
10 1705.
- 11 Toraldo, A., Reverberi, C., & Rumiati, R. I. (2001). Critical dimensions affecting imitation
12 performance of patients with ideomotor apraxia. *Cortex*, 37(5), 737-740.
- 13 Vry, M. S., Tritchler, L. C., Hamzei, F., et al.,(2015). The ventral fiber pathway for pantomime
14 of object use. *Neuroimage*, 106, 252-263.
- 15 Warrington, E. K., & James, M. (1991). The visual object and space perception battery. Thames
16 Valley Test Company, Bury St Edmunds, UK.
- 17 Weiller, C., Bormann, T., Saur, D., Musso, M., & Rijntjes, M. (2011). How the ventral pathway
18 got lost—And what its recovery might mean. *Brain and language*, 118(1-2), 29-39.
- 19 Weiller, C., Musso, M., Rijntjes, M., & Saur, D. (2009). Please don't underestimate the ventral
20 pathway in language. *Trends in cognitive sciences*, 13(9), 369.
- 21 Weiss, P. H., Rahbari, N. N., Hesse, M. D., & Fink, G. R. (2008). Deficient sequencing of
22 pantomimes in apraxia. *Neurology*, 70(11), 834-840.

1 Weiss, P. H., Ubben, S. D., Kaesberg, S., Kalbe, E., Kessler, J., Liebig, T., & Fink, G. R. (2016).

2 Where language meets meaningful action: a combined behavior and lesion analysis of

3 aphasia and apraxia. *Brain Structure and Function*, 221(1), 563-576.

4

1 Appendix

List of then meaningful and meaningless gestures used in the test (for the Italian culture). In the brackets a “F” indicates the case of gestures with a main finger component and “H/A” the case of a gesture with a main hand/arm component.

MEANINGFUL (MF) GESTURES

01. I am tired/ I go to sleep (H/A)
02. Military salute (H/A)
03. I am hungry (H/A)
04. No! (F)
05. Hallo (F)
06. Later (F)
07. Silence! (H/A)
08. Crazy (H/A)
09. Stop! (H/A)
10. Well done (F)
11. Come here! (F)
12. Finger crossed (F)
13. Hitch-hiking (H/A)
14. Listening (H/A)
15. Strength (H/A)
16. So-and-so/more or less (F)
17. Go away (F)
18. Victory (F)

MEANINGLESS (ML) GESTURES

01. Horizontal palm up on the abdomen (H/A)
02. Horizontal back hand under the chin (H/A)
03. Hand over the opposite shoulder (H/A)
04. Pinkie straight down (F)
05. Thumb close the middle finger (F)
06. Closed fist with the palm up and the thumb pointing outward (F)
07. Back of the hand horizontally placed on the eyes (H/A)
08. Back of the hand on the contralateral cheek (H/A)
09. Palm of the hand on the nape (H/A)
10. Extended thumb and pinkie, other fingers closed in a fist and hand positioned with the back toward the observer (F)
11. Horizontal hand with the middle finger over the index finger (F)
12. Fist with the thumb extended toward the body midline (F)
13. Palm of the hand on the ipsilateral shoulder (H/A)
14. Palm of the hand toward the observer and positioned perpendicularly over the head (H/A)

15. Back of the hand toward the observer, hand upright with the top of the finger under the chin (H/A)

16. Hand closed in a fist, with the back toward the observer and positioned over the pinkie with the index finger pointing toward the body midline (F)

17. Back of the hand toward the observer and hand lying on the pinkie side with the thumb closed to the index finger (F)

18. Hand closed around the thumb in a fist (F)