



ALMA MATER STUDIORUM
UNIVERSITÀ DI BOLOGNA

ARCHIVIO ISTITUZIONALE
DELLA RICERCA

Alma Mater Studiorum Università di Bologna Archivio istituzionale della ricerca

Factors Affecting Soft and Hard Tissues Around Two-Pies Transmucosal Implants: A 3-Year Prospective Cohort Study

This is the final peer-reviewed author's accepted manuscript (postprint) of the following publication:

Published Version:

Prati C., Zamparini F., Canullo L., Pirani C., Botticelli D., Gandolfi M.G. (2020). Factors Affecting Soft and Hard Tissues Around Two-Pies Transmucosal Implants: A 3-Year Prospective Cohort Study. THE INTERNATIONAL JOURNAL OF ORAL & MAXILLOFACIAL IMPLANTS, 35(5), 1022-1036 [10.11607/jomi.7778].

Availability:

This version is available at: <https://hdl.handle.net/11585/799707> since: 2021-02-15

Published:

DOI: <http://doi.org/10.11607/jomi.7778>

Terms of use:

Some rights reserved. The terms and conditions for the reuse of this version of the manuscript are specified in the publishing policy. For all terms of use and more information see the publisher's website.

This item was downloaded from IRIS Università di Bologna (<https://cris.unibo.it/>).
When citing, please refer to the published version.

(Article begins on next page)

ABSTRACT

Purpose: This 3-year study aimed to evaluate hard and soft tissues modification around a two-piece implant characterized by a transmucosal hyperbolic neck in healthy consecutive patients with need for single-tooth replacement.

Methods: Two-piece implants (n=66) were placed with flapless technique in 56 patients (27 Males; 29 Females; mean age 55 ± 9 years): 16 immediately after root extraction (immediate group), 20 after 8-12 weeks (early group) and 30 after 10 or more months (delayed group). The transmucosal hyperbolic neck resulted exposed 1-1.5mm above gingival level.

Customized abutments were positioned three months later with the abutment-implant connection located approx. 1-1.5mm above soft tissue level. Provisional cemented resin crowns were designed with the finishing line at the hyperbolic neck and then positioned to avoid excessive compression of soft tissues, to guide gingival contours. Twenty days later, a definitive metal ceramic crown was cemented. In all patients gingival biotype (thin or thick) was also evaluated.

Primary outcomes: 36-month implant survival rate, peri-implant marginal bone level changes (MBL, in mm) **observed** in single-blind on radiographs at 1, 3, 6, 12, 24 and 36 months (T₁, T₃, T₆, T₁₂, T₂₄ and T₃₆) and Pink Esthetic Score (PES) at T₆, T₁₂ and T₃₆ to analyse soft tissue adaptation after loading and crown application.

Secondary outcomes: Plaque Score and Bleeding on Probing (BoP).

Linear regression models and Multilevel-mixed logistic regression were used to detect any statistical difference of MBL according to operative parameters. Kruskal Wallis One Way **ANOVA** on Ranks was performed to assess statistical differences of PES at T₆, T₁₂ and T₃₆.

Results: Survival rate was 100%. Drop-out was 1.79%. No infections, mucositis or peri implantitis have been reported. Implants placed in thick biotype tissues showed a statistically different lower bone loss at 36 months **with respect to** thin biotype ($p < 0.05$). At 36 months, early group showed lower bone loss as compared to delayed group ($p < 0.05$). Multilevel-mixed logistic regression revealed that gingival biotype resulted the parameter mostly related to MBL variations ($p = 0.025$).

PES value (Mean \pm SD) at T₆ was 10.76 ± 1.19 (Median 11; Range 8-13; IQR 10-12). The values statistically increased at T₁₂ and T₃₆, where the Mean values were 11.76 ± 1.10 (Median 12; Range 9-13; IQR 11-12) and 11.83 ± 1.03 (Median 12; Range 9-14; IQR 11-13).

Conclusion: MBL and soft tissues clinical parameters measured around two-piece hyperbolic neck implants were stable during the 3-year follow-up and free from complications. The exposure of hyperbolic neck for 1.0-1.5mm allowed a flapless one-stage surgery which supported a fast adaptation of the soft tissues, evidenced by high PES values and low percentages of BoP. The results from the study imply a new simple approach in **the clinical** management of gingival and bone tissue.

Keywords: flapless procedure; prospective cohort study; single implant; hyperbolic neck; transmucosal placement.

INTRODUCTION

The morphology and the healing phases of tissues around implants are important biological conditions for function and aesthetic.^{1,2} To achieve a fast stability of hard and soft tissue, different factors should be considered in the early healing stage after implant placement, such as implant placement timing and bone quality,^{3,4} surgical procedures (i.e. flapless implant insertion), implant exposure and superinfection, implant micromovements, early occlusal loads⁵⁻⁷ and cleansability of the implant restorations.^{8,9} Implant-abutment connection is another important biological condition for post-loading crestal bone remodelling processes.^{10,11} Bacteria infiltration of the micro gap,¹² chronic trauma and stress at the implant-abutment level and repetitive motions of the abutment provide risks for soft tissue damage and gingival aesthetic alterations, bone critical remodelling and failures.¹³

Transmucosal implants have been proposed in many clinical studies as they require only a one-stage technique when compared to submerged two-stage technique^{5,14-17} and provide good performances in terms of peri-implant bone preservation.¹⁷ Transmucosal one-stage technique may reduce surgical trauma and reduce any further surgical manipulation of gingival tissue before and during prosthetic procedures. A better control of impressions and less discomfort for patients are additional advantages¹⁵.

Innovative clinical strategies such as one-piece implants with flapless technique¹⁸⁻²¹ or the use of transmucosal/transgingival healing screw in the early phases after implant insertion at crestal bone level^{5,15, 22,23} have been proposed in clinical studies to try to overcome the limits of two-stage techniques which require a second surgical step to expose submerged implant.

Recent immunohistochemical studies demonstrated that transmucosal implants applied with one-stage technique showed gingival tissues with similar immune cell population and response to submerged implants.²⁴

Scanning electron microscopy (SEM) analysis of exposed abutment of human transmucosal implants showed the presence of a “clear zone” free from any biofilm connected with periimplant mucosa, acting as a protective functional barrier.^{25,26}

Histological studies in animal models demonstrated that transmucosal implants showed less marginal bone loss and less degree of gingival inflammation than submerged implants^{10,27,28}

A transmucosal implant with an innovative hyperbolic neck may represent a further approach in line with the concept to create the clinical-biological conditions to induce an early gingival adaptation and healing and to minimize soft tissue trauma by avoiding secondary surgeries to expose the implant.

The two-piece hyperbolic neck implant was designed to keep exposed a portion of 1-1.5 mm neck after flapless surgical placement.²⁹

This neck may allow a transmucosal placement, **relocating implant-abutment junction** above the tissue levels and consequently **distant** from **crestal** bone and gingival margins. To date, few information about the use of hyperbolic-neck implant is present.³⁰⁻³²

The purpose of the present investigation was to **study** the hard and soft tissue modifications of a novel transmucosal two-piece implant with the hyperbolic neck exposed above tissue levels in a cohort of patients followed **for at least** 3 years.

Primary outcome measures were implant survival rate, crestal marginal bone level changes (MBL) and Pink Esthetic Score (PES) up to 36 months.

Secondary outcomes were plaque score (PS) and bleeding on probing (BoP), measured around the implant neck.

MATERIALS AND METHODS

Study design and patient enrolment

The clinical investigation was settled as a longitudinal prospective cohort study in single-blind on patients **with requirement for rehabilitation with a single-tooth implant**. Radiographic and clinical indicators were measured in the time of the settled study.

The investigation was performed in a University Endodontic Clinical Department and in two private clinics in the same geographical area. Surgeries were performed by the same operator trained in flapless surgery. Recruitment of patients started in September 2014 and ended in February 2016. Follow-up was performed between October 2014 and March 2019 by the same clinical team included as authors.

Subjects included in this investigation were treated according to the principles established by the Declaration of Helsinki as modified in 2013.³³ Patients were delivered a written and oral information before the recruitment in the study and signing the consent form. The document was prepared according to the Consolidated Standards of Reporting trials guidelines for reporting clinical trials³⁴ and complying the guidelines previously published by Dodson in 2007.³⁵

Patients allocation

Inclusion and exclusion criteria are illustrated in Tables 1 and 2.

Clinical criteria for extraction, post-extraction healing and implant placement timing were defined by an experienced senior university medical dentist. Immediate, early or delayed placements criteria³ were selected following clinical parameters for the best clinical practice (judgmental allocation).³⁶

The defined placement timing groups were:

- Immediate post-extraction group:³ **Placement of implant into** socket immediately after extraction of **seriously-compromised hopeless-teeth free from infection** or of teeth affected by **granuloma**.
- Early group:³ implant insertion was achieved in healed bone after 8-12 weeks from extraction of teeth affected by acute **endodontic abscess or periapical infection and severe symptoms**.

- Delayed group:³ implant placement was performed in edentulous mature bone 10-12 months after teeth removal.

Environmental scanning electron microscopy (ESEM) of the implant neck

Morphological microanalyses of the transmucosal hyperbolic neck surface were performed using an Environmental Scanning Electron Microscope (Zeiss EVO 50; Carl Zeiss, Germany).

The implant was examined without any previous treatment (sample was not coated) following a previously published protocol. Operative parameters were the following: accelerating voltage of 20 kV, low vacuum (100 Pascal) with working distance of 8.5 mm,. The detection level was 0.5 wt%, while resolution 133-eV and amplification time of 100 μ s.³⁷

Pre-surgical protocol

Each patient received oral antibiotic (1gr amoxicillin/clavulanic) a tablet 24 and 12 hours before scheduled surgery. Chlorhexidine digluconate 0.12% gel (Corsodyl Gel, GlaxoSmithKline, UK) was prescribed 3 applications per day. Antibiotic administration was scheduled for 5 post-operative days.

Implant surgery

All implant placements were performed by one senior operator (CP). Mepivacaine chlorhydrate 30mg/ml (Carboplyina, Dentsply Italia srl, Italy) was used as local anaesthesia.

All implants were positioned with single-stage procedures and without use of surgical guides.

Immediate implant placement

Teeth extractions were made with attention to prevent any trauma. A careful inspection of the socket was made followed by a radiographic evaluation. When present, the periapical tissue which presented sign of granulation was removed with great attention from the socket apical portion and carefully inspected. A first drill (1.2 mm) working at 250 rpm under saline solution irrigation was used as guide. The position and the inclination of palatal bone wall indicated the direction and the other position parameters. Calibrated drills (used at 225 rpm) were mounted on low-speed hand piece (W&H Austria) to prepare the implant housing. The apical portion of the sockets was prepared to obtain a first anchorage for implant. Usually 3.0 mm depth were enough to obtain the stability.

Cortico-cancellous bone (Osteobiol MP3, Tecknoss Dental, Italy) was inserted into the surgical site in four cases. The procedures were selected to replace the lack of bone tissues and to reduce the gap between the bony walls and the implant surface.

Acid-etched titanium implants (Prima, Sweden & Martina, Italy) with surface treated by zirconium oxide particles blasts were used in the study. Implants were characterized by a 2.8 mm anodized smooth machined long hyperbolic neck as illustrated in Figures 1 and 2.

All implants were surgically inserted to maintain the blasted surface at cortical crestal bone level and the smooth surface of neck 1.0-1.2 mm above the gingival margin, to achieve the transmucosal emergence of neck. A sealing thin screw (height 1.0mm) was kept in place for the 3 months healing time. An eugenol-free surgical dressing (Coe Pack, America Inc, IL, USA) was placed on the area of implant placement and kept in position for 5-7 days.

Early and delayed implant insertion

Similar surgical procedures were performed for both early and delayed groups. In these cases, no any type of flaps were made before implant placement.

A first guide drill (diameter 1.2mm) was utilized to mark the position and to define the direction angle and depth of placement. The drill crossed the entire gingival thickness, the cortical and cancellous bone. All procedures were under saline solution irrigation. Calibrated drills working at 225 rpm were then utilized, creating a calibrated diameter for implant site and a corrected depth.

The implants were positioned to achieve a transmucosal healing. The implant rough surface was placed in correspondence of crestal bone and the smooth neck was calibrated at 1-1.2 mm above the surface of soft tissues (Figure 3). A thin screw (1.0mm height) was kept in place to seal the connection for the next three months. The surgical dressing was kept on the area of implant placement for 5-7 days.

Maryland bridge placement

A bonded Maryland bridge was applied when possible and used as “interim” prosthesis in 46 cases during healing phase period. The enamel surfaces of teeth adjacent the implant were acid etched (H₃PO₄ gel - M ESPE, MN, USA) and water rinsed for 20-25 seconds. A single-component enamel/dentin adhesive (Scotchbond Universal Bonding, 3M ESPE, MN, USA) was brushed on the enamel surface. A dual cement (Relyx Ultimate, 3M ESPE, MN, USA) was mixed and positioned to bond and keep in place the Maryland bridge.

Post-operative procedures

Instruction for patients included to follow a soft diet regime for one week to prevent any trauma in the area. Chlorhexidine-based mouthwash (0.12%) was prescribed and suggested to rinse 3 times/day for 3 weeks and to perform oral hygiene procedures on the surgical dressing for the first week and to continue for 2 weeks after surgical pack removal. Hence, brushing and flossing were permitted.

Prosthetic rehabilitation

After three months, polyether impressions (Permadyne and Garant, 3M ESPE, MN, USA) were obtained using plastic customized trays. In all patients the pick-up impression technique was performed by two operators to obtain gypsum models. Custom resin crowns were prepared as provisional prosthesis. The gingival finishing

line of crowns was designed to be in delicate contact with gingival-papilla line to obtain a moderate compression of the periimplant soft tissues. Customized titanium abutments were prepared and positioned after approx. 7 days from impression. The provisional resin crowns were placed and fixed with zinc-oxide temporary cement (Temp Bond NE, Kerr, Italy). The connection between implant and abutment connection resulted at 1-1.5 mm from the gingival external margin and for this reason completely covered by the crown. The application of the abutment increased the retention offered by the cement-crown monoblock. Definitive metal-ceramic crowns were prepared on the same models. Both metal and ceramic finishing lines were designed and fabricated to fit in correspondence of the implant hyperbolic neck. Definitive metal-ceramic crowns were fixed after 3-4 weeks using a radiopaque polycarboxylate powder/liquid cement (Heraeus Kulzer GmbH, Germany) with careful attention to prevent any cement overflowing and excess. Two experienced prosthodontists made all the laboratory and clinical prosthetic procedures

Implant clinical evaluation and patient follow-up

Instruction in oral hygiene practice and motivation were verbally discussed with the patients. Scaling and root planning was performed every 6 months or more frequent when modest plaque and calculus was observed and still present after the follow-up clinical control.

Hard and soft tissues evaluation

MBL: periapical X-rays were taken using a paralleling technique with Rinn-holders and analog films (Kodak Ektaspeed Plus, NY, USA) after implant insertion and at 1 (T₁), 3 (T₃), 6 (T₆), 12 (T₁₂), 24 (T₂₄) and 36 (T₃₆) months after implant placement.

Periapical X-rays were performed following an accurate standardization, carried out before of the study. The following X-rays parameters were used: target-film distance was approx. 30 cm, exposure time was 0.41s, 70 kV voltage and 8 mA intensity. X-rays development was performed in a developer unit (Euronda s.p.a., Italy), at standard room temperature (25°C) with 12 s developing and 25 s fixing time, following the manufacturer indications. When not fulfilling the parameters, patients were asked to get a new radiograph. All periapical radiographs were then scanned with a scanner with the following acquisition parameters: resolution 968 dpi and x20 magnification factor.

The morphology of peri-implant marginal bone was carefully examined. MBL was assessed at the distal and mesial side, calculating the distance between the implant platform (reference point) to the most coronal bone-to-implant contact. A 0.1mm steps scale was used to perform the measurements, according to previous studies^{22,38} corrected according to the implant diameter and length of each implant.³⁹

One additional examiner performed in single-blind the X-rays evaluation. A preliminary careful calibration was performed using reference radiographs with various periimplant marginal bone level measures and defined instructions.

PES: The evaluation was made after 6, 12 and 36 months according with previous investigation.⁴⁰

The photographs were analysed twice by a blinded trained examiner at an interval of 4 weeks. The photographs were re-evaluated in the reverse order at the second assessment. A total of 7 variables were evaluated and compared to a natural reference tooth. Mesial papilla, distal papilla, soft-tissue level, soft-tissue contour, alveolar process deficiency, soft-tissue colour and soft tissue texture. A 0-1-2 scoring system was used (0 was defined as the lowest; 2 was the highest value). In this way, the maximum rate of PES was 14.

Peri-implant soft tissue thickness: soft tissue thickness around implants and the corresponding mesial/distal neighbouring teeth was defined. Buccal gingival soft tissues was pierced at 3 mm apical to the margin by using an endodontic instrument (K-file #20; Dentsply-Maillefer, Switzerland). According with previous studies, soft tissue was defined thick (thickness more than 2mm) or thin (thickness minor or equal to 2mm).⁴¹⁻

43

Plaque score: Plaque score around implant-crown was evaluated at four sites (distal, mesial, palatal and vestibular) at T₁₂ and T₃₆. Dichotomous scores were defined (0= absence of visible plaque at the soft tissue margin; 1= visible plaque at the soft tissue margin).⁴⁴

BoP: BoP around the implant crown was defined at four sites (distal, mesial, palatal and vestibular) at T₁₂ and T₃₆. Dichotomous scores were defined (0= negative bleeding; 1= positive bleeding).⁴⁴

Statistical analysis

Statistical analyses of MBL were calculated using Stata 13.1 software (StataCorp, College Station, TX, Usa). Linear regression models were fitted to evaluate the presence of statistical differences among the parameters, times and their interactions. To evaluate the data correlation due to the presence of multiple implants per subject, the before-mentioned regression models were estimated following a generalized estimating equation approach. Estimates of coefficients' standard errors and confidence intervals were adjusted by using a robust variance-covariance estimator.⁴⁵

A multiple linear regression with stepwise selection was fitted to consider any relationship between MBL at T₃₆ and the following parameters: location (mandible/ maxilla), gender (female/male), endodontic adjacent teeth (no/yes), position (anterior/posterior), implant placement (delayed/immediate/early), implant length (10/ 11.5), implant diameter (3.8/ 4.25/ 5.0), and gingival biotype (thick/thin).

Box plots were made using Sigma plot 12 (Systat, IL, USA) for MBL range and distribution as a function of implant placement timing and gingival biotype .

PES was analyzed using Sigma plot 12 software (Systat, Chicago, IL, USA). Kruskal-Wallis One Way Analysis of Variance on Ranks was performed, to evaluate any statistical differences among total PES at 6, 12 and 36 months. p values was previously set at 0.05.

RESULTS

ESEM micromorphological evaluation of the implant neck

The surface of hyperbolic neck and body of the implant has been observed using ESEM.

Analysis at low magnification (approx. 90x) were performed to observe the neck geometry and the implant abutment connection. (Figure 1)

The morphology of neck (2.8 mm) was characterized by two distinct areas. A 2.0 mm hyperbolic neck and 0.8 mm cylindrical portion. ESEM images at high magnification (1000x) revealed an anodized machined micromorphology with regular microgrooves, ranging 10-25 μm . The microgrooved morphology was detected over all the 2.8mm transmucosal neck and ended in correspondence of the first implant thread. In this area, the machined pit transition zone was detected.

The implant connection was an internal hexagon with a small internal collar, designed to distribute the occlusal load and to provide a greater stability. (Figure 2)

Study population and demographic data

Fifty-six patients (27 men, 29 women: mean age 55 ± 9 years) with a total of 66 implant rehabilitations were included. The survival rate was 100%. One patient failed to comply with the follow-up visits (drop out was 1.79%). No biological complications, including wound infections, osteitis or bone graft sequestration occurred during the entire follow-up. Two screw loosening were observed at 20 and 24 months from insertion. Crowns were gently removed, and a new connection screw provided and tightened in the same session. No other complications or loosening occurred.

MBL assessment

Table 3 report the implant distribution and MBL (in mm, expressed as mean \pm standard deviation) according to the evaluated pre-operative, intra-operative and post-operative parameters.

Early and immediate placement groups proved mean MBL of 0.16 ± 0.33 and 0.19 ± 0.23 at T_6 , both statistically different ($p < 0.05$) to the values of delayed group, that revealed a higher bone loss (mean MBL was 0.42 ± 0.26).

This difference is reduced at T_{36} , as early implant group showed significantly lower bone loss values from delayed group implants ($p = 0.005$). On the contrary, immediate implant group revealed no statistical differences from both delayed ($p = 0.16$) and early implants ($p = 0.28$). The mean values were 0.81 ± 0.43 for delayed, 0.43 ± 0.44 for early and 0.55 ± 0.42 for immediate implants.

A constant over time MBL during the healing time (T_3), initial loading time (T_6) and (T_{12}) from the insertion ($p > 0.05$) was observed for thick biotype implants, revealing a crestal bone stability during the healing phases

and leading to stable MBL values at T₂₄ and T₃₆. On the contrary, Thin biotype implants revealed MBL variation up to T₃ which increased until T₂₄ and was stable at T₃₆.

Box plots considering implant placement timing and gingival biotype are illustrated in Figures 4,5.

Interestingly, only immediate implants revealed a large values distribution at T₃ (Figure 4a), ascribable to crestal bone remodelling of post-extraction sockets.

Early implants showed a more stable MBL values at all the evaluation times (Figure 4b). Instead, delayed implants showed the widest distribution of values at T₃₆, with negative outliers, defined by bone loss (Figure 4c).

Figure 5a reports a wider distribution and a consistent decrement of MBL values for implants surrounded by thin biotype. On the contrary, MBL of implants surrounded by a thick biotype showed a higher stability (Figure 5b).

Multiple-mixed logistic regression analysis exploring all factors associated to MBL at T₃₆ is showed in Table 4a, corroborating that gingival biotype significantly influenced MBL results at T₃₆ (p= 0.031). Gingival biotype resulted the most significant parameter associated to MBL at T₃₆ (p= 0.025) after stepwise selection (Table 4b).

PES, BoP and PS assessment

PES at T₆, T₁₂ and T₃₆ are illustrated in Figure 6. Mean 6-month PES was 10.76± 1.19 (Median 11; Range 8-13; IQR 10-12). These values significantly increased at 12 and 36 months, the mean values were 11.76 ± 1.10 (Median 12; Range 9-13; IQR 11-12) and 11.83 ± 1.03 (Median 12; Range 9-14; IQR 11-13) respectively.

Mesial and distal papilla parameters improved after T₁₂, with slight modifications after final evaluation (T₃₆). No 0 scores were observed at both 12 months and 36 months.

Other soft tissue parameters increased to the highest score. Soft tissues texture and gingival color presented the highest score in 92-95% of the samples at T₃₆. The data proved the presence of healthy tissue free from inflammation and gingival discoloration. Soft tissue level and contour scores also increased during the observation time.

Plaque score and BoP are illustrated in **Table 5**. A low % of BoP positive sites were recorded at final T₃₆., while Plaque score index resulted positive at mesial site (23.3%). Both values resulted lower than T₁₂ values. Two representative clinical cases are reported in **Figures 7 and 8**.

DISCUSSION

The study investigated the use of implants designed with a long smooth hyperbolic neck placed in a transmucosal configuration on consecutive patients and their effectiveness on clinical and MBL up to 3 years. The study demonstrated that neck exposition resulted free from complications such as gingivitis, mucositis and implant failures during healing time. MBL was stable in both pre-loading and post-loading

time in accordance with the traditional accepted success criteria.⁴⁶ Neck exposition during the healing time displayed a limited plaque accumulation, as evidenced by low BoP and Plaque scores values.

The neck morphology and use of transmucosal technique present some clinical advantages and some limitations, identified in the study. The neck diameter resulted narrower than implant diameter (Figure 1) and the hyperbolic configuration was partially positioned into the thickness of gingival tissues (Figure 3). The pictures obtained by the use of scanning microscopy illustrated the hyperbolic profile neck (emerging from the implant body) and the surface micromorphology (Figures 1,2).

Implant placement was made using a flapless one-stage technique leaving exposed the hyperbolic neck (Figures 7,8). The use of transmucosal implant is well-documented and offers many advantages as no second surgical re-entry is needed to expose the implant before prosthetic phases.⁴⁷ Cohort studies on one-stage implants revealed reduced bone loss and satisfactory gingival tissues preservation.^{5,22,23} The one-stage protocol allowed the healing and soft tissues maturation around the machined neck and helped soft tissues to remain stable and healthy in post-surgical time (as showed in Figure 8). The exposed neck prevented gingival overgrowth during the 3-month healing phase and the mucosal tissue filled the space around the hyperbolic neck.

As the emergence profile resulted exposed 1.0-1.5mm above the gingival mucosa, a more coronal implant-abutment connection - more distant from the bone tissues- is obtained, avoiding secondary peri-implant tissues manipulation. The present concept is in accordance with Romanos *et al.*⁴⁸ proposing the insertion of definitive abutment immediately after implant insertion (“One-time abutment concept”) and avoiding further disconnections as a useful strategy to avoid bone loss in submerged or crestal level implants⁴⁸ and also with Sanz *et al.* which used a healing screw to obtain a transmucosal healing.^{5,22,23}

A more coronal neck-abutment connection eliminates the risks for bacterial leakage, described for crestal and subcrestal placement, where the connection between the implant and the abutment is located at bone level.⁴⁹ A further characteristic of a coronal/supragingival hyperbolic neck-abutment connection is the greater available space for metal and ceramic thickness of the crown.

Abutment increased the retention of crowns that are cemented on the neck and on the abutment surface. The relative short hyperbolic neck represents a simplification to avoid the limit of true one-piece implants that presents a high exposed abutment and requires immediate provisional crown positionment.⁵⁰

The positioning of implant-abutment junction at subcrestal level usually increase the increase the risk for cement excess,^{51,52} while the presence of a deep mucosal tunnel may add further risks for peri-implant mucositis.²⁰

The design and preparation for provisional and definitive crowns were based on the so called biological oriented preparation technique (BOPT) concept.⁵³ So, each crown was designed to have a gentle contact with the gingival margin with modest tissue compression and with the finishing line at neck level.

No tissue inflammation or peri-implantitis were observed after crown cementation. Temporary zinc-oxide eugenol-based cement has been selected for provisional restorations as enough retention on the hyperbolic neck was obtained (no provisional decemented crowns were reported). Radiopaque definitive polycarboxylate cement was selected as easy to be removed and for its adequate setting time (approx. 5 minutes).

A transmucosal one-piece implant with a smooth higher conical neck has been previously proposed by Hann.⁵⁴ Additional studies analyzed this implant in a number of clinical conditions with conflicting results. In particular, bone loss, recessions of the soft tissues and high implant losses were reported by Ostman *et al.* when placing these implants with immediate load and *in situ* abutment customization.⁵⁰

In this study, selected significative parameters affecting MBL were analysed.^{4,55,56} Gingival biotype was the parameter responsible for the most significative association with MBL. Implants positioned in patients with thick biotypes showed a more stable crestal MBL when compared to thin biotypes. The study confirms that gingival thickness is one of the most important parameter which affect MBL during the peri-implant bone remodeling, as demonstrated in several animal models⁷ and in some clinical studies.^{57,58} Establishment of a biological barrier between the oral environment the implant, leading to a more stable connective tissue was observed around transmucosal neck of implants with a thick biotype.²⁶

As interesting considerations, immediate and early groups proved a similar MBL progression trend up to 12 months from insertion. On the contrary, delayed group exhibited a higher bone loss in the initial 6 months time, significantly different from the other groups ($p < 0.005$). Old mineralized mature cortical bone offers a limited new bone formation, as observed in recent histological investigation.^{59,60} Oral bone density may probably be different in mature long time edentulous bone when compared to healing alveolar sockets. In addition, long time edentulous cortical bone could be severely damaged by surgical procedures and may require additional bone resorbing osteoclasts to completely remove cortical bone debris.⁵⁹

The use of PES offered the possibility to evaluate soft tissues modification during the clinical follow-up.⁴⁰ The majority of the studies used PES only in the anterior region, that is the most esthetic area.^{3,44,61,62} Only a clinical investigation proposed PES in the posterior region.⁶³

In the present clinical trial, PES evidenced both in anterior and posterior areas an important gingival improvement from at 12 months from implant insertion, with a general stability at 3 years. Gingival soft tissue resulted sound and proved a stable morphology in all groups. As important element, high number of samples exhibited the highest score value for parameter soft tissue texture, soft tissue color and alveolar process deficiency at 36 month evaluation. The result support the use of the adopted flapless technique with the novel implant neck design.

The ZirTi surface of the investigated implant was analysed in several animal (dog) studies and presents favourable osseointegration data, as demonstrated by high bone-implant contact values.^{64,65} Implants with the

same surface morphology, but different macromorphology of the neck, has been recently documented by clinical studies^{23,56} and by ESEM-EDX analysis on human histological samples of retrieved implant biopsies.⁶⁶ In the present study, a 3.0% of screw loosening has been reported. This percentage was in line with a previously-published review, taking account studies conducted in a university setting, which revealed an estimate 3-year complication free period of 97.6%.⁶⁷ Other studies reported that annual loosening rate is approx. 2.29%, with a 4-year loosening rate of 8.5%.^{68,69} The two screw loosening may be attributable to a technical operative error.

The implant-abutment connection differs from traditional internal hexagon, as a small collar was designed to distribute the occlusal load and to provide a greater stability.⁷⁰ A previous finite element method evidenced a 20% increase to structure loosening and deformation of the present connection when compared to other 3 traditional implant abutment connection, which was attributable to the presence of the internal collar.⁷⁰

Some limitations of the technique and implant design must be reported. The neck transmucosal profile cannot be altered after insertion into the bone. This means that the implant angulation needs to be carefully planned before surgery. A skilled operator must insert the implant in the right location, parallel to the adjacent roots, avoiding implant malposition that cannot be corrected by abutment angulation.⁷¹

Provisional Maryland bridge restorations were cemented in a large number of cases and keep in position during the healing time. The bonded bridges may be necessary to avoid any aesthetic disadvantage of transmucosal implant neck exposure, according with Tonetti et al.⁷²

Some limitations may be considered with the short-term follow-up. The preliminary findings of this study must be validated with a longer follow-up. Moreover, soft tissues morphology around the implants should be investigated by histological studies, still lacking in literature.

CONCLUSION

This 3-year study demonstrated that:

- novel two-piece implants with transmucosal hyperbolic neck proved low number of complications, stable MBL and adequate PES in anterior and posterior regions.
- transmucosal flapless one-stage technique allows a soft tissue healing as evidenced by PES parameters after short time and 3 years.
- cement-retained crowns may be easily applied without cement excess and subsequent gingival inflammation.
- timing of implant placement and gingival biotype were the pre-operative factors to be considered for the clinical results.

REFERENCES

1. Berglundh T, Persson L, Klinge B. A systematic review of the incidence of biological and technical complications in implant dentistry reported in prospective longitudinal studies of at least 5 years. *J Clin Periodontol* 2002;29:197-212.
2. Qian J, Wennerberg A, Albrektsson T. Reason for marginal bone loss around oral implants. *Clin Implant Dent Relat Res* 2012;14:792-807.
3. Hämmerle CH, Chen ST, Wilson TG Jr. Consensus statements and recommended clinical procedures regarding the placement of implants in extraction sockets. *Int J Oral Maxillofac Implant* 2004 19:26-28.
- 4 Chrcanovic BR, Albrektsson T, Wennerberg A. Flapless versus conventional flapped dental implant surgery: a meta-Analysis. *PLOS ONE* 2014;9:1-14.
5. Sanz M, Ivanoff CJ, Weingart D, Wiltfang J, Gahlert M, Cordaro L et al. Clinical and Radiologic Outcomes after Submerged and Transmucosal Implant Placement with Two-Piece Implants in the Anterior Maxilla and Mandible: 3-Year Results of a Randomized Controlled Clinical Trial. *Clin Implant Dent Relat Res* 2015;17:234-246.
6. Berglundh T, Lindhe J. Dimension of the Periimplant mucosa. Biological width revisited. *J Clin Periodontol* 1996; 23:971-973.
7. Jung RE, Zembic A, Pjetursson BE, Zwahlen M, Thoma DS. Systematic review of the survival rate and the incidence of biological, technical, and aesthetic complications of single crowns on implants reported in longitudinal studies with a mean follow-up of 5 years. *Clin Oral Implants Res* 2012;23:2-21.
8. Pontoriero R, Tonelli MP, Carnevale G, Mombelli A, Nyman SR, Lang NP. Experimentally induced periimplant mucositis. A clinical study in humans. *Clin Oral Implants Res* 1994;5:254-259.
9. Heitz-Mayfield LJA, Salvi GE. Peri-implant mucositis. *J Clin Periodontol* 2018;45:237-245.
10. Hermann JS, Buser D, Schenk RK, Cochran DL. Crestal bone changes around titanium implants. A histometric evaluation of unloaded non-submerged and submerged implants in the canine mandible. *J Periodontol* 2000;71:1412-1424.
11. Broggini N, McManus LM, Hermann JS, Medina R, Schenk RK, Buser D, et al. Peri-implant inflammation defined by the implant-abutment interface. *J Dent Res* 2006;85:473-478.
12. Barone A, Alfonsi F, Derchi G, Tonelli P, Toti P, Marchionni S, Covani U. The Effect of Insertion Torque on the Clinical Outcome of Single Implants: A Randomized Clinical Trial. *Clin Implant Dent Relat Res* 2016;18:588-600.
13. Crespi R, Capparè P, Polizzi E, Gherlone E. Fresh-Socket Implants of Different Collar Length: Clinical Evaluation in the Aesthetic Zone. *Clin Implant Dent Relat Res* 2015;17:871-878.
14. Buser D, Mericske-Stern R, Dula K, Lang NP. Clinical experience with one-stage, non-submerged dental implants. *Adv Dent Res* 1999;13:153-161.
15. Flores-Guillen J, Álvarez-Novoa C, Barbieri G, Martín C, Sanz M. Five-year outcomes of a randomized clinical trial comparing bone-level implants with either submerged or transmucosal healing. *J Clin Periodontol* 2018;45:125-135.
16. French D, Cochran DL, Ofec R. Retrospective Cohort Study of 4,591 Straumann Implants Placed in 2,060 Patients in Private Practice with up to 10-Year Follow-up: The Relationship Between Crestal Bone Level and Soft Tissue Condition. *Int J Oral Maxillofac Implants* 2016;31:168-178.

- 17 Paul S, Petsch M, Held U. Modeling of Crestal Bone After Submerged vs Transmucosal Implant Placement: A Systematic Review with Meta-Analysis. *Int J Oral Maxillofac Implants* 2017;32:1039-1050.
- 18 Finne K, Rompen E, Toljanic J. Clinical evaluation of a prospective multicenter study on 1 -piece implants. Part 1: Marginal bone level evaluation after 1 year of follow-up. *Int J Oral Maxillofac Implants* 2007;22:226-234.
- 19 Schwarz F, Messias A, Sanz-Sánchez I, Carrillo de Albornoz A, Nicolau P, Taylor T, Beuer F, Schär A, Sader R, Guerra F, Sanz M. Influence of implant neck and abutment characteristics on peri-implant tissue health and stability. Oral reconstruction foundation consensus report. *Clin Oral Implants Res*. 2019;30:588-593.
- 20 Chan D, Pelekos G, Ho D, Cortellini P, Tonetti MS. The depth of the implant mucosal tunnel modifies the development and resolution of experimental peri-implant mucositis: A case-control study. *J Clin Periodontol* 2019;46:248-255.
21. Sato J, Watanabe G, Ando M, Shimoo Y, Shizukuda K, Kimura T, Kobayashi M. A prospective multicenter study of immediate function of 1-piece implants: a 3-year follow-up report. *J Prosthet Dent* 2014;112:784-91.
22. Sanz M, Cecchinato D, Ferrus J, Salvi GE, Ramseier C, Lang NP, Lindhe J. Implants placed in fresh extraction sockets in the maxilla: clinical and radiographic outcomes from a 3-year follow-up examination. *Clin Oral Implants Res* 2014;25:321-327.
23. Sanz-Martín I, Sanz-Sánchez I, Noguero F, Cok S, Ortiz-Vigón A, Sanz M. Randomized controlled clinical trial comparing two dental implants with different neck configurations. *Clin Implant Dent Relat Res* 2017;19:512-522.
24. Martínez-González JM, Martín-Ares M, Martínez-Rodríguez N, Barona-Dorado C, Sanz-Alonso J, Cortés-Bretón-Brinkmann J, Ata-Ali J. Comparison of peri-implant soft tissues in submerged versus transmucosal healing: A split mouth prospective immunohistochemical study. *Arch Oral Biol* 2018;90:61-66.
25. Tomasi C, Tessarolo F, Caola I, Wennström J, Nollo G, Berglundh T. Morphogenesis of peri-implant mucosa revisited: An experimental study in humans. *Clin Oral Implants Res* 2014;25:997-1003.
26. Tomasi C, Tessarolo F, Caola I, Piccoli F, Wennström JL, Nollo G, Berglundh T. Early healing of peri-implant mucosa in man. *J Clin Periodontol*. 2016;43:816-824.
27. Alomrani AN, Hermann JS, Jones AA, Buser D, Schoolfield J, Cochran DL. The effect of a machined collar on coronal hard tissue around titanium implants: a radiographic study in the canine mandible. *Int J Oral Maxillofac Implants* 2005;20:677-686.
28. Valles C, Rodríguez-Ciurana X, Nart J, Santos A, Galofre M, Tarnow D. Influence of Implant Neck Surface and Placement Depth on Crestal Bone Changes Around Platform-Switched Implants: A Clinical and Radiographic Study in Dogs. *J Periodontol* 2017;88:1200-1210.
29. Zamparini F, Pirani C, Chavarria-Bolanos D, Gandolfi MG, Prati C. Rehabilitation of anterior maxilla with a novel hyperbolic profile transmucosal implant in elderly patients. *Minerva Stomatol* 2019;68:249-258.
30. Canullo L, Tallarico M, Pradies G, Marinotti F, Loi I, Cocchetto R. Soft and hard tissue response to an implant with a convergent collar in the esthetic area: preliminary report at 18 months. *Int J Esthet Dent* 2017;12:306-323.
31. Solá-Ruiz MF, Highsmith JDR, Labaig-Rueda C, Agustín-Panadero R. Biologically oriented preparation technique (BOPT) for implant-supported fixed prostheses. *J Clin Exp Dent* 2017;9:603-607.
32. Prati C, Zamparini F, Pirani C, Montebugnoli L, Gandolfi MG. Multifactorial statistical analysis toward evaluation of MBL, PES and PI of a novel nonsubmerged implant to restore a single tooth: A 1-year prospective cohort study. *J Oral Sci Rehab* 2017;3:32-41.
33. World Medical Association Declaration of Helsinki: Ethical principles for medical research involving human subjects.

JAMA. 2013;310:2191-2194.

34. Vandembroucke JP, von Elm E, Altman DG et al. Strengthening the reporting of observational studies in epidemiology (STROBE): explanation and elaboration PLoS Med 2007;4:1628-1654.

35. Dodson TB. A guide for preparing a patient-oriented research manuscript. Oral Surg Oral Med Oral Pathol Radiol Endod 2007;104:307-315.

36. Taxel P, Ortiz D, Shafer D, Pendrys D, Reisine S, Rengasamy K, Freilich M. The relationship between implant stability and bone health markers in post-menopausal women with bisphosphonate exposure. Clin Oral Invest 2014;18:49-57.

37. Gandolfi MG, Taddei P, Siboni F, Perrotti V, Iezzi G, Piattelli A, Prati C. Micro-topography and reactivity of implant surfaces: an in vitro study in simulated body fluid (SBF). Microsc Microanal. 2015;21:190-203.

38. Thoma DS, Sanz Martin I, Benic GI, Roos M, Hämmerle CH. Prospective randomized controlled study comparing two dental implant systems: demographic and radiographic results at one year of loading. Clin Oral Implants Res 2014;25:142-149.

39. Galindo-Moreno P, León-Cano A, Ortega-Oller I, Monje A, Suárez F, ÓValle F, Spinato S, Catena A. Prosthetic abutment height is a key factor in peri-implant marginal bone loss. J Dent Res 2014;93:80-85.

40. Fürhauser R, Florescu D, Benesch T, Haas R, Mailath G, Watzek G. Evaluation of soft tissue around single-tooth implant crowns: the pink esthetic score. Clin Oral Implants Res 2005;16:639-644.

41. Cosgarea R, Gasparik C, Dudea D, Culic B, Dannewitz B, Sculean A. Peri-implant soft tissue colour around titanium and zirconia abutments: a prospective randomized controlled clinical study. Clin Oral Implants Res 2015;26:537-544.

42. Zembic A, Sailer I, Jung RE, Hammerle CHF. Randomized-controlled clinical trial of customized zirconia and titanium implant abutments for single tooth implants in canine and posterior regions: 3-year results. Clin Oral Implants Res 2009;20:802-808.

43. Ferrari M, Carrabba M, Vichi A, Goracci C, Cagidiaco MC. Influence of abutment color and mucosal thickness on soft tissue color. Int J Oral Maxillofac Implants 2017;32:393-399.

44. Cosyn J, Eghbali A, Hermans A, Vervaeke S, De Bruyn H, Cleymaet R. A 5-year prospective study on single immediate implants in the aesthetic zone. J Clin Periodontol 2016;43: 702-709.

45. Rogers WH. Regression standard errors in clustered samples. Stata Technical Bulletin 1993;13:19-23.

46. Albrektsson T, Zarb G, Worthington P, Eriksson AR. The long-term efficacy of currently used dental implants: a review and proposed criteria of success. Int J Oral Maxillofac Implants. 1986;1:11-25.

47. Stoupe J, Lee CT, Glick J, Sanz-Miralles E, Chiuzan C, Papapanou PN. Immediate implant placement and provisionalization in the aesthetic zone using a flapless or a flap-involving approach: a randomized controlled trial. J Clin Periodontol. 2016;43:1171-1179.

48. Romanos GE, Aydin E, Gaertner K, Nentwig G-. Long-term results after subcrestal or crestal placement of delayed loaded implants. Clin Implant Dent Relat Res 2015;17:133-141.

49. Piattelli A, Scarano A, Paolantonio M, Assenza B, Leghissa GC, Di Bonaventura G, et al. Fluids and microbial penetration in the internal part of cement-retained versus screw-retained implant-abutment connections. J Periodontol 2001;72:1146-1150.

50. Östman PO, Hellman M, Albrektsson T and Sennerby L. Direct loading of Nobel Direct® and Nobel Perfect® one-piece implants: a 1-year prospective clinical and radiographic study. *Clin Oral Implants Res* 2007;18:409-418.
51. Sailer I, Mühlemann S, Zwahlen M, Hämmerle CHF, Schneider D. Cemented and screw-retained implant reconstructions: A systematic review of the survival and complication rates. *Clin Oral Implants Res* 2012;23:163-201.
52. Sancho-Puchades M, Crameri D, Özcan M, Sailer I, Jung RE, Hämmerle CHF, Thoma DS. The influence of the emergence profile on the amount of undetected cement excess after delivery of cement-retained implant reconstructions. *Clin Oral Implants Res* 2017;28:1515-1522.
53. Loi I, Di Felice A. Biologically oriented preparation technique (BOPT): a new approach for prosthetic restoration of periodontically healthy teeth. *Eur J Esthet Dent* 2013;8:10-23.
54. Hahn, J. One-piece root-form implants: a return to simplicity. *Journal of Oral Implantology* 2005;31: 77–84.
55. Prati C, Zamparini F, Scialabba VS Gatto MR, Piattelli A, Montebugnoli L, Gandolfi MG. A 3-year prospective cohort study on 132 calcium phosphate blasted implants: flap vs flapless technique. *Int J Oral Maxillofac Implants.* 2016;31:413-423.
56. Prati C, Zamparini F, Pirani C, Gatto MR, Piattelli A, Gandolfi MG. Immediate Early and Delayed Implants: A 2-Year Prospective Cohort Study of 131 Transmucosal Flapless Implants Placed in Sites With Different Pre-extractive Endodontic Infections. *Impl Dent* 2017; 26:654-663.
57. Puisys A, Linkevicius T. The influence of mucosal tissue thickening on crestal bone stability around bone-level implants. A prospective controlled clinical trial. *Clin Oral Implants Res* 2015;26:123-129.
58. Linkevicius T, Linkevicius R, Alkimavicius J, Linkeviciene L, Andrijauskas P, Puisys A. Influence of titanium base, lithium disilicate restoration and vertical soft tissue thickness on bone stability around triangular-shaped implants: A prospective clinical trial. *Clin Oral Implants Res* 2018;29:716-724.
59. Mainetti T, Lang NP, Bengazi F et al. Immediate loading of implants installed in a healed alveolar bony ridge or immediately after tooth extraction: an experimental study in dogs. *Clin Oral Implants Res* 2015;26:435-441.
60. Mainetti T, Lang NP, Bengazi F et al. Sequential healing at implants installed immediately into extraction sockets. An experimental study in dogs. *Clin Oral Implants Res* 2016; 27:130-138.
61. Raes F, Cosyn J, De Bruyn H. Clinical, esthetic and patient-related outcome of immediately loaded single implants in the anterior maxilla: a prospective study in extraction sockets, healed ridges and grafted sites. *Clin Implant Dent Relat Res* 2013;15:819-835.
62. Cosyn J, Eghbali A, De Bruyn H, Dierens M, De Rouck T. Single Implant Treatment in Healing Versus Healed Sites of the Anterior Maxilla: An Esthetic Evaluation. *Clin Implant Dent Relat Res* 2012;14:517-526.
63. Weinlander M, Lekovic V, Spadijer-Gostovic S, Milicic B, Wegscheider WA, Piehslinger E. Soft tissue development around abutments with a circular macro-groove in healed sites of partially edentulous posterior maxillae and mandibles: a clinical pilot study. *Clin.Oral Impl Res* 2010; 22:743–752
64. Canullo L, Tallarico M, Botticelli D, Alccayhuaman KAA, Martins Neto EC, Xavier SP. Hard and soft tissue changes around implants activated using plasma of argon: A histomorphometric study in dog. *Clin Oral Implants Res* 2018;29:389-395.

65. Yonezawa D, Piattelli A, Favero R, Ferri M, Iezzi G, Botticelli D. Bone healing at functionally loaded and unloaded screw-shaped implants supporting single crowns: A histomorphometric study in humans. *Int J Oral Maxillofac Implants* 2018;33:181-187.
66. Prati C, Zamparini F, Botticelli D, Ferri M, Yonezawa D, Piattelli A, Gandolfi MG. The Use of ESEM-EDX as an Innovative Tool to Analyze the Mineral Structure of Peri-Implant Human Bone. *Materials* 2020;13:1671-1682.
67. Theoharidou A, Petridis HP, Tzannas K, Garefis P *Int J Oral Maxillofac Implants*. 2008; 23:681-690
68. Pjetursson BE, Asgeirsson AG, Zwahlen M, Sailer I. Improvements in implant dentistry over the last decade: comparison of survival and complication rates in older and newer publications. *The International journal of oral & maxillofacial implants*. 2014; 29 Suppl:308–324.
69. Shi JY, Jie-Ni, Zhuang LF, Zhang XM, Fan LF, Lai HC. Peri-implant conditions and marginal bone loss around cemented and screw-retained single implant crowns in posterior regions: A retrospective cohort study with up to 4 years follow-up. *PLoS One* 2018;13: e0191717.
70. Covani U, Ricci M, Tonelli P, Barone A. An evaluation of new designs in implant-abutment connections: a finite element method assessment. *Implant Dent* 2013;22:263-267.
71. De Bruyn H, Atashkadeh M, Cosyn J, van de Velde T. Clinical outcome and bone preservation of single TiUnite™ implants installed with flapless or flap surgery. *Clin Implant Dent Relat Res* 2011;13:175-83.
72. Tonetti MS, Cortellini P, Graziani F, Cairo F, Lang NP, Abundo R, Conforti GP, Marquardt S, Rasperini G, Silvestri M, Wallkamm B, Wetzel A. Immediate versus delayed implant placement after anterior single tooth extraction: the timing randomized controlled clinical trial. *J Clin Periodontol*. 2017;44:215-224

Table 1	Inclusion criteria
	<ul style="list-style-type: none">- age within 18 and 75 years- presence of a compromised unrestorable tooth with presence of both adjacent teeth- acceptance of a 3-year hygiene recall program and implant follow-up- smoking less than 10 cigarettes per day

Table 2	Exclusion criteria
	<ul style="list-style-type: none">- ASA score ≥ 3- Lack of motivation and poor oral hygiene- pocket probing depth >4 mm and positive bleeding on probing in the natural dentition, expressing active periodontal disease- smoke 10 or more cigarettes per day- Uncontrolled type 2 diabetes- local and/or systemic diseases which possibly compromise post-operative healing and osseointegration- Substances abuse, such as alcohol or drugs- pregnancy or lactation status- occlusal disorders, including bruxism, or other malocclusions- any use of bisphosphonate drugs

Table 3. MBL (Mean \pm SD) of the placed implants according to the operative parameters: different superscript letters represent statistically significant differences in the same horizontal row (capital letters among times) or in the same column (small letters for each parameter). P value was set at 0.05

		n	T ₁	T ₃	T ₆	T ₁₂	T ₂₄	T ₃₆
<i>Pre-operative parameters</i>								
Implant location	Maxilla	52	0.01 \pm 0.24 ^{Aa}	0.16 \pm 0.39 ^{Ba}	0.24 \pm 0.32 ^{Ba}	0.40 \pm 0.43 ^{Ca}	0.60 \pm 0.46 ^{Ca}	0.53 \pm 0.49 ^{Ca}
	Mandible	14	0.08 \pm 0.22 ^{Aa}	0.26 \pm 0.35 ^{Ba}	0.39 \pm 0.25 ^{Ba}	0.54 \pm 0.41 ^{Ca}	0.82 \pm 0.48 ^{Da}	0.85 \pm 0.47 ^{Da}
Implant position	Anterior	17	-0.02 \pm 0.18 ^{Aa}	0.11 \pm 0.33 ^{Ba}	0.19 \pm 0.29 ^{Ba}	0.26 \pm 0.36 ^{Ba}	0.57 \pm 0.39 ^{Ca}	0.46 \pm 0.35 ^{Ca}
	Posterior	49	0.06 \pm 0.23 ^{Aa}	0.21 \pm 0.36 ^{Ba}	0.32 \pm 0.33 ^{Ba}	0.51 \pm 0.41 ^{Cb}	0.69 \pm 0.48 ^{Ca}	0.71 \pm 0.43 ^{Ca}
Gender	Male	29	0.05 \pm 0.23 ^{Aa}	0.23 \pm 0.35 ^{Ba}	0.29 \pm 0.33 ^{Ba}	0.41 \pm 0.41 ^{Ca}	0.62 \pm 0.48 ^{Ca}	0.64 \pm 0.47 ^{Ca}
	Female	37	0.03 \pm 0.23 ^{Aa}	0.15 \pm 0.36 ^{Ba}	0.26 \pm 0.32 ^{Ba}	0.47 \pm 0.42 ^{Ba}	0.70 \pm 0.49 ^{Ca}	0.68 \pm 0.48 ^{Ca}
Endodontic adjacent teeth	No	30	0.03 \pm 0.22 ^{Aa}	0.24 \pm 0.37 ^{Ba}	0.31 \pm 0.33 ^{Ba}	0.46 \pm 0.42 ^{BCa}	0.68 \pm 0.48 ^{Ca}	0.65 \pm 0.48 ^{Ca}
	Yes	36	0.04 \pm 0.23 ^{Aa}	0.15 \pm 0.36 ^{Ba}	0.26 \pm 0.32 ^{Ba}	0.43 \pm 0.41 ^{BCa}	0.64 \pm 0.48 ^{Ca}	0.68 \pm 0.47 ^{Ca}
Implant placement	Immediate	16	0.06 \pm 0.13 ^{Aa}	0.15 \pm 0.34 ^{Ba}	0.19 \pm 0.23 ^{Ba}	0.24 \pm 0.30 ^{Ba}	0.63 \pm 0.32 ^{Cab}	0.55 \pm 0.42 ^{Cab}
	Early	20	0.01 \pm 0.23 ^{Aa}	0.13 \pm 0.41 ^{Ba}	0.16 \pm 0.33 ^{Ba}	0.27 \pm 0.40 ^{BCa}	0.40 \pm 0.45 ^{Ca}	0.43 \pm 0.44 ^{Ca}
	Delayed	30	0.05 \pm 0.25 ^{Aa}	0.26 \pm 0.33 ^{Bb}	0.42 \pm 0.26 ^{Cb}	0.63 \pm 0.38 ^{Db}	0.84 \pm 0.47 ^{Eb}	0.81 \pm 0.43 ^{Eb}
<i>Intra-operative parameters</i>								
Implant Diameter	3.8	23	0.11 \pm 0.23 ^{Aa}	0.29 \pm 0.36 ^{Aa}	0.38 \pm 0.32 ^{ABa}	0.57 \pm 0.41 ^{Ba}	0.78 \pm 0.49 ^{BCa}	0.87 \pm 0.49 ^{Ca}
	4.25	34	0.01 \pm 0.22 ^{Aa}	0.13 \pm 0.36 ^{Aa}	0.24 \pm 0.32 ^{Ba}	0.42 \pm 0.41 ^{BCa}	0.65 \pm 0.48 ^{Ca}	0.60 \pm 0.47 ^{Ca}
	5.0	9	-0.05 \pm 0.20 ^{Aa}	0.10 \pm 0.33 ^{Aa}	0.16 \pm 0.30 ^{Aa}	0.25 \pm 0.38 ^{ABa}	0.37 \pm 0.42 ^{Ba}	0.48 \pm 0.38 ^{Ba}
Implant Length	10.0	43	0.06 \pm 0.54 ^{Aa}	0.15 \pm 0.54 ^{Aa}	0.26 \pm 0.54 ^{Ba}	0.45 \pm 0.54 ^{BCa}	0.68 \pm 0.54 ^{Ca}	0.72 \pm 0.54 ^{Ca}
	11.5	23	0.02 \pm 0.23 ^{Aa}	0.25 \pm 0.23 ^{Ba}	0.31 \pm 0.23 ^{Ba}	0.43 \pm 0.23 ^{Ba}	0.56 \pm 0.23 ^{Ca}	0.51 \pm 0.23 ^{Ca}
<i>Post-operative parameters</i>								
Gingival thickness	Thin	40	0.08 \pm 0.21 ^{Aa}	0.26 \pm 0.29 ^{Ba}	0.38 \pm 0.25 ^{Ca}	0.60 \pm 0.37 ^{Da}	0.82 \pm 0.48 ^{Ea}	0.78 \pm 0.46 ^{Ea}
	Thick	26	-0.02 \pm 0.23 ^{Aa}	0.08 \pm 0.43 ^{Ba}	0.14 \pm 0.37 ^{Bb}	0.24 \pm 0.39 ^{Bb}	0.46 \pm 0.44 ^{Cb}	0.51 \pm 0.41 ^{Cb}
Total		66	0.04 \pm 0.22 ^A	0.19 \pm 0.35 ^B	0.24 \pm 0.32 ^B	0.44 \pm 0.36 ^C	0.66 \pm 0.46 ^D	0.69 \pm 0.49 ^D

Table 4a Multilevel-mixed logistic regression exploring factor associated to MBL at 36 months

Groups	Coefficient	SE	95% CI	p-value
<i>Pre-operative parameters</i>				
Gender	-0.350	0.003	(-0.347; 0.277)	0.826
Position	-0.044	0.181	(-0.400; 0.311)	0.808
Location	-0.019	0.147	(-0.309; 0.270)	0.895
Implant placement group	0.148	0.104	(-0.057; 0.354)	0.157
Endodontic adjacent teeth	0.888	0.136	(-0.179; 0.357)	0.518
<i>Intra-operative parameters</i>				
Implant Diameter	-0.125	0.115	(-0.352; 0.100)	0.276
Implant Length	-0.081	0.128	(-0.332; 0.169)	0.525
<i>Post-operative parameters</i>				
Gingival biotype	-0.296	0.138	(-0.567; 0.02)	0.031

Table 4b After stepwise selection

Groups	Coefficient	Robust SE	95% CI	p-value
Implant placement group	0.142	0.084	(-0.244; -0.308)	0.094
Gingival biotype	-0.304	0.136	(-0.570; -0.037)	0.025

Table 5 Periodontal parameters around implant restorations after definitive load

	Plaque Score (PS)				Bleeding on probing (BoP)			
	T ₁₂		T ₃₆		T ₁₂		T ₃₆	
	0 (%)	1 (%)	0 (%)	1 (%)	0 (n%)	1 (n%)	0 (n%)	1 (n%)
Mesial	63.8	36.2	76.7	23.3	90.4	9.6	93.8	6.2
Distal	75.7	24.3	86.0	14.0	95.3	4.7	95.3	4.7
Vestibular	80.5	19.5	95.3	4.7	90.4	9.6	97.6	2.4
Palatal	75.7	24.3	90.6	9.4	95.3	4.7	95.3	4.7

A null (0) value indicates no BoP or PS; A 1 value indicates positive BoP or PS

Figures:




Figure 1. ESEM (Environmental Scanning Electron Microscope) images of Prama implant. Images were focused on the implant transmucosal hyperbolic neck and on the internal connection. (a) 2.0mm anodized neck, presenting a hyperbolic profile. (b) The implant-abutment connection was an internal hexagon with a small collar designed to distribute the occlusal load and to provide a greater stability. The convergent hyperbolic design is visible in both pictures.




Figure 2. ESEM (Environmental scanning electron microscopy) images of the coronal portion of Prama implant. (a) ESEM analysis at 90x magnification evidences the transition between the transmucosal portion of the implant, which is constituted by two different topographical areas, each of these were observed at 1000x magnification. (b) ESEM image of the 2.0 mm hyperbolic neck, revealing a machined anodized surface, with regular microgrooves of 10-25 μm . (c) ESEM image of the 0.8mm cylindrical machined portion, revealing a similar micromorphology when compared with the hyperbolic neck. (d) ESEM image at 1000x of the machined pit transition, revealing a moderately rough surface. Cylindrical machined portion (0.8mm) and part of hyperbolic neck are usually placed in contact and immersed in the mucosa. The most coronal part of the hyperbolic neck is sealed by cemented crown. The machined pit transition zone must be placed in relationship with bone and mucosa.

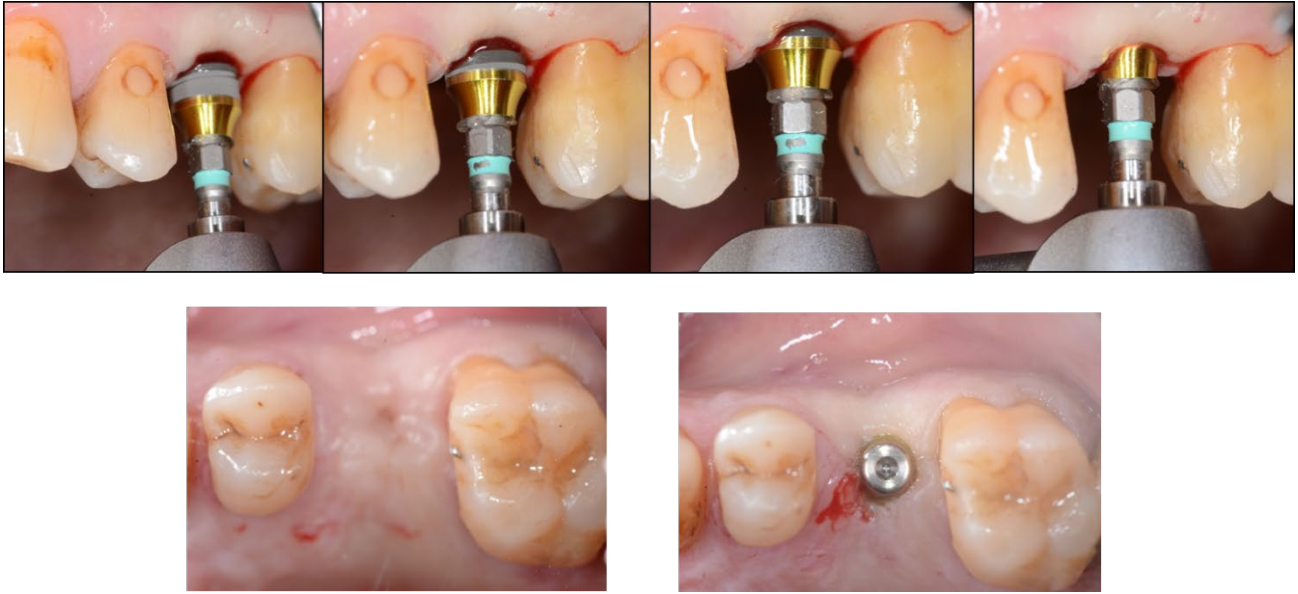


Figure 3. Surgical phases of Prama implant insertion on a healed ridge using a flapless technique. Extraction was performed 3 months before for tooth fracture. Please note that the cylindrical machined portion is positioned at the hard-soft tissue interface, while the hyperbolic neck resulted partially exposed above tissue level (1.0-1.5mm), which avoids a second stage surgery before prosthetic procedures.

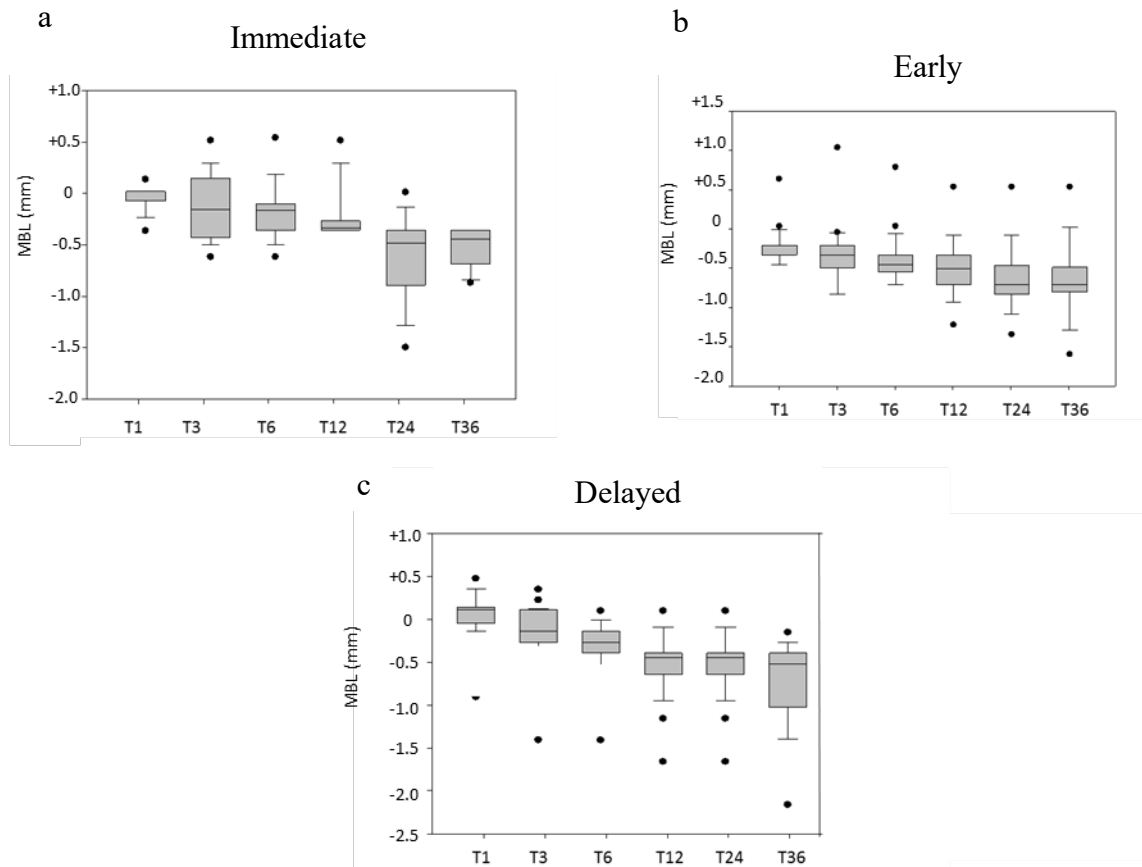


Figure 4. Box plot reporting MBL of (a) immediate, (b) early and (c) delayed implants in the present investigation. Delayed group reports the widest distribution of values at 2 and 3 years from implant insertion (T₂₄ and T₃₆), revealing also a greater presence of negative outlier (indicating bone loss). Interestingly, immediate group showed a larger distribution of MBL values at 3 months (T₃), which was attributed to the alveolar bone remodeling processes of post-extraction sockets.

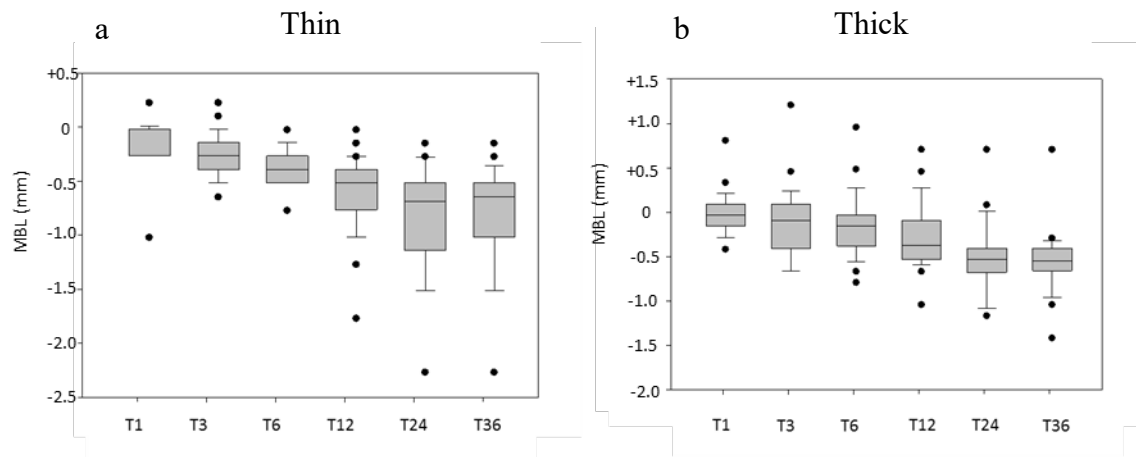


Figure 5. Box plots depicting MBL of implants surrounded by a thin or a thick soft tissue biotype: (a) a larger distribution and a marked MBL variation is observed in thin group. On the contrary, a more stable MBL, in particular after 1 month (T₁), 24 months (T₂₄) and 36 months (T₃₆) was observed in thick biotype group.

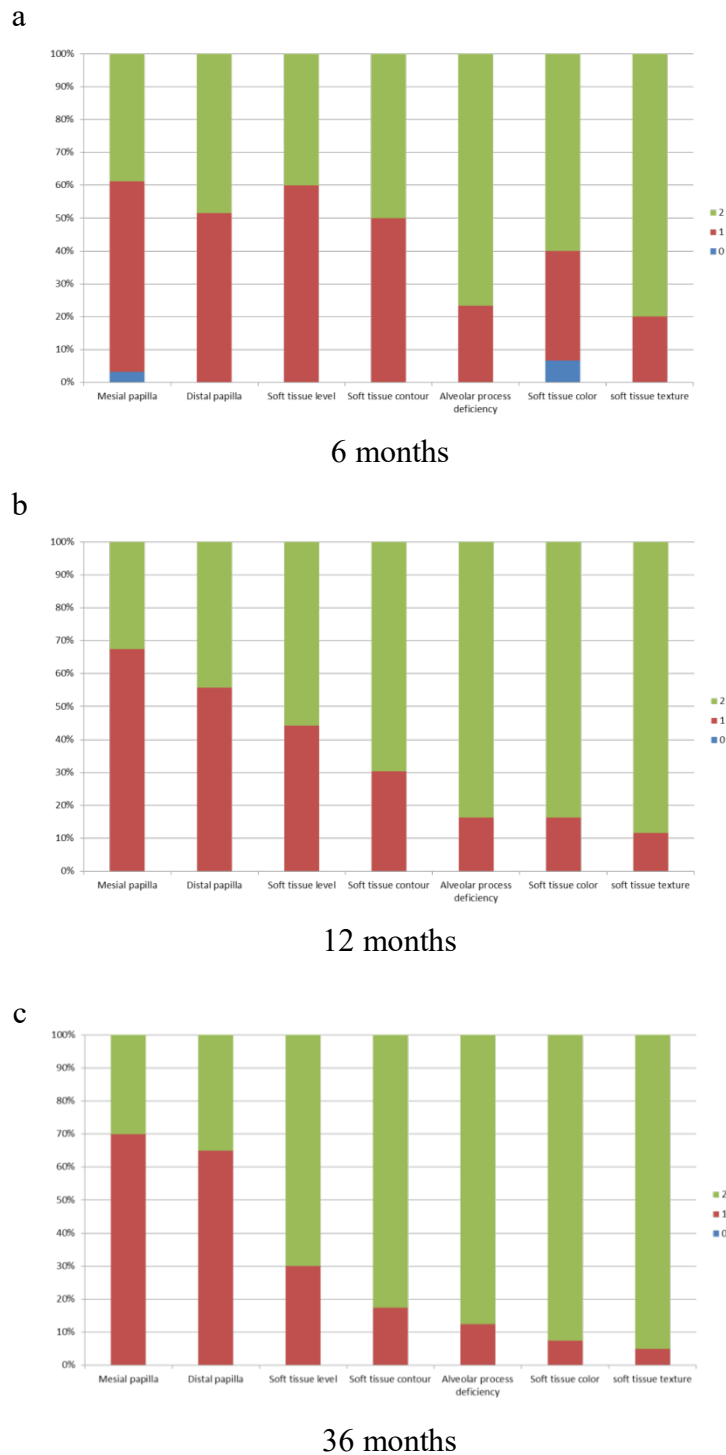


Figure 6. Graphs reporting PES scores at different time from insertion, namely after 6 (a), 12 (b) and 36 months (c). No zero scores were observed reported at 12 and 36 months from insertion. PES at 6 months was significantly different when compared to 12 months values ($p < 0.05$). On the contrary, no differences were observed between values at 12 months and 36 months ($p > 0.05$).

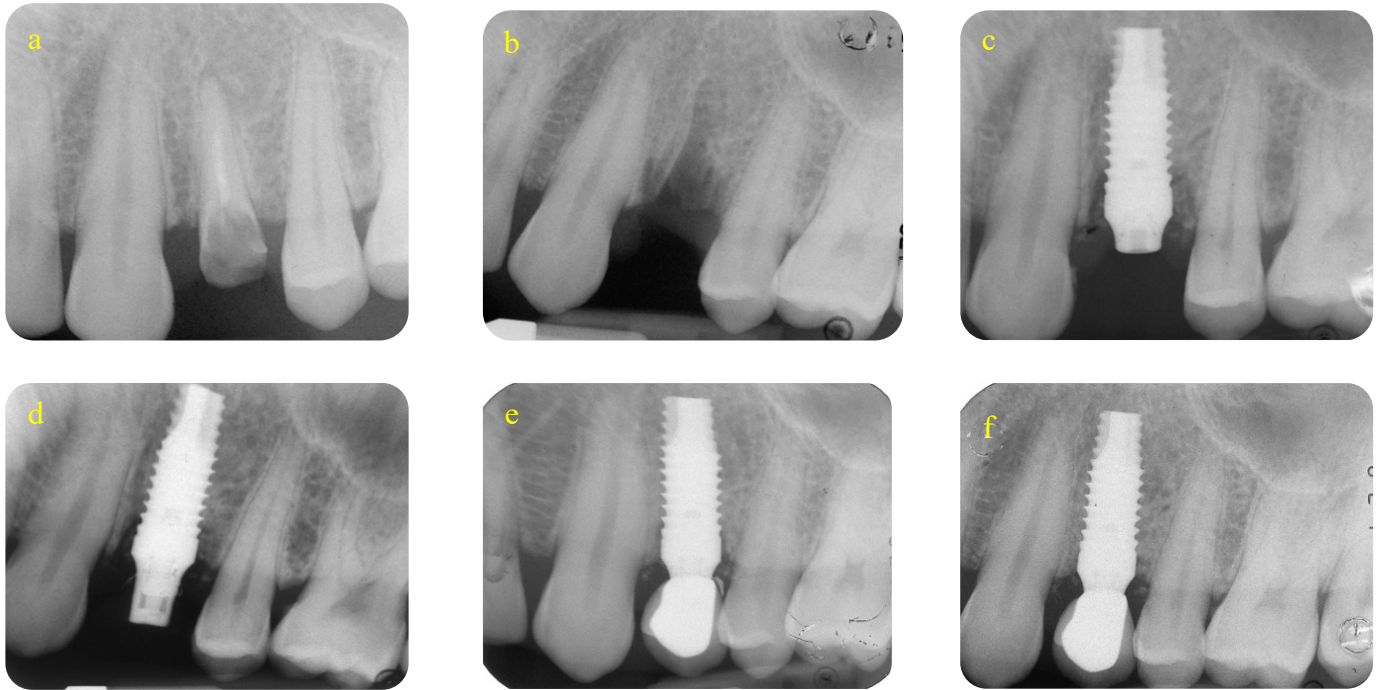


Figure 7. Fractured root canal treated tooth (a). Tooth was extracted (b) and immediate implant placement performed (c) due to the absence of periapical infection. Please note the hyperbolic neck left exposed 1-1,5mm above the tissue levels. (d) abutment application and morphology of hyperbolic neck abutment. (e) Definitive metal-ceramic crown and (f) follow-up at 36 months from insertion. Please note that the definitive metal ceramic crown margin ends on the implant hyperbolic neck. MBL markedly improved at 12 and 36 months after implant insertion, with no biological and technical complications.

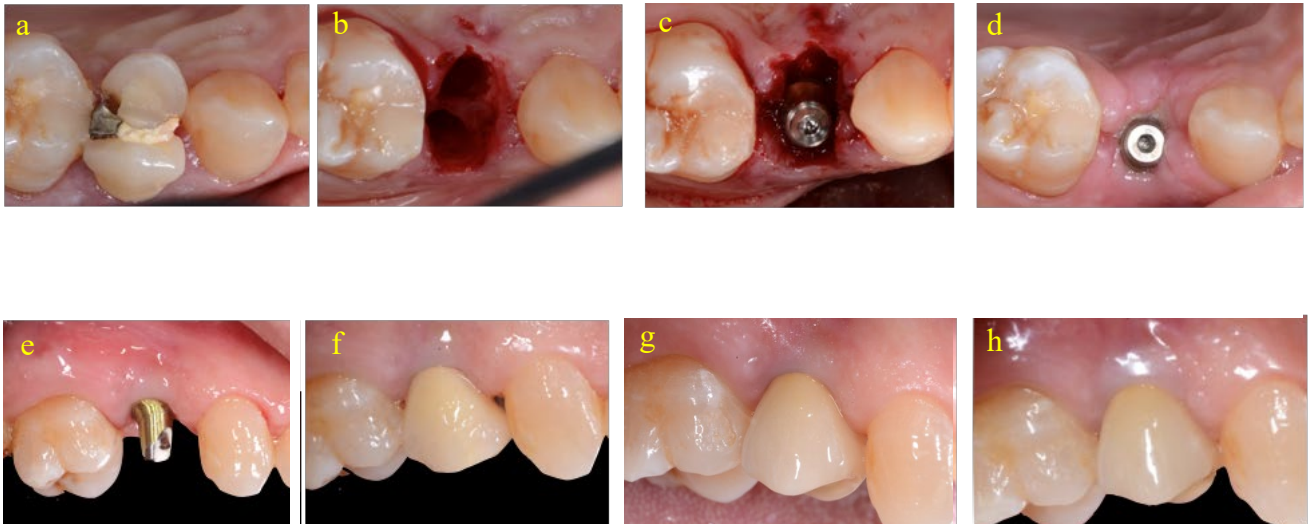


Figure 8. (a) 58-year old patient with fractured root canal treated tooth. Immediate implant insertion was performed due to the absence of periapical lesion (b,c). Uneventful healing was obtained at 1 week (d). Prosthetic phases: please note the angled abutment of Prama implant and the internal abutment connection (e). Provisional and definitive crown were cemented without tissue compression (f). After 36 months, no inflammation was observed, while mesial and distal papilla showed satisfactory results (g).