

Alma Mater Studiorum Università di Bologna
Archivio istituzionale della ricerca

A multilevel analysis of platform-switching flapless implants placed at tissue level: 4-year prospective cohort study

This is the final peer-reviewed author's accepted manuscript (postprint) of the following publication:

Published Version:

Prati C., Zamparini F., Pirani C., Montebugnoli L., Canullo L., Gandolfi M.G. (2020). A multilevel analysis of platform-switching flapless implants placed at tissue level: 4-year prospective cohort study. THE INTERNATIONAL JOURNAL OF ORAL & MAXILLOFACIAL IMPLANTS, 35(2), 330-341 [10.11607/jomi.7541].

Availability:

This version is available at: <https://hdl.handle.net/11585/799703> since: 2021-02-15

Published:

DOI: <http://doi.org/10.11607/jomi.7541>

Terms of use:

Some rights reserved. The terms and conditions for the reuse of this version of the manuscript are specified in the publishing policy. For all terms of use and more information see the publisher's website.

This item was downloaded from IRIS Università di Bologna (<https://cris.unibo.it/>).
When citing, please refer to the published version.

(Article begins on next page)

A multi-level analysis of platform-switching flapless implants placed tissue-level: 4-year prospective cohort study

Carlo Prati, MD, DDS, PhD¹, Fausto Zamparini, DDS, MEndo, PhD^{1,2}, Chiara Pirani, DDS, MEndo, PhD¹, Lucio Montebugnoli MD, DDS³, Luigi Canullo MD, DDS⁴, Maria Giovanna Gandolfi, DBiol, MBiol, PhD²

1 Endodontic Clinical Section, School of Dentistry, Department of Biomedical and Neuromotor Sciences, University of Bologna, Bologna, Italy.

2 Laboratory of Biomaterials and Oral Pathology, School of Dentistry, Department of Biomedical and Neuromotor Sciences, University of Bologna, Bologna, Italy.

3 Oral Sciences Section, School of Dentistry, Department of Biomedical and Neuromotor Sciences, University of Bologna, Bologna, Italy.

4 Private Practice, Rome, Italy

Reprint request and correspondence to: Prof. Carlo Prati, MD, DDS, PhD, Via San Vitale 59, 40125 Bologna, Italy, Phone +39-051-2088126, Fax +39-051-225208, E-mail: carlo.prati@unibo.it

Disclosure: The authors claim to have no financial interest, either directly or indirectly, in the products or information listed in the article.

ABSTRACT

Purpose: To evaluate the factors affecting peri-implant marginal bone level of single platform-switch implants placed with smooth neck at gingival level (tissue level) by using a flapless technique.

Material and Methods: 76 consecutive patients received 128 titanium implants with a zirconium-oxide blasted surface (ZirTi) and a platform-switching neck tulip-configuration. Implants were loaded 3 months after insertion with a provisional resin crown and after approx. 15 days with a definitive ceramic crown. Peri-implant marginal bone level (MBL) was measured on periapical radiographs at 1,3,6,12,24, 36 and 48 months by blinded assessor. The following parameters were evaluated: Implant placement groups (immediate, early, delayed), location (maxillary/mandibular), gingival thickness (thin/thick), sex (male/female), endodontically treated adjacent teeth (yes/no). Multilevel analyses exploring factors associated to MBL at 36 and 48 months were performed.

Results: The survival rate was 98.4%. Mean MBL at 36 and 48 months was $0.95\text{mm} \pm 0.85$ and 0.99 ± 0.68 respectively, not statistically different from the values at 24 months ($p > 0.05$).

Mandibular location, delayed implants and presence of adjacent endodontic treated teeth showed significantly higher bone loss at 36 months ($p < 0.05$). Interestingly, at 48 months only implant placement timing showed statistically significant differences. Delayed implants showed increased bone loss when compared to both early and immediate groups ($p < 0.05$).

Multilevel analysis confirmed the statistical significance of implant location ($p = 0.031$; 95%CI:0.031-0.659), endodontically treated adjacent teeth ($p = 0.001$; 95%CI:-1.228-0.859) and implant placement group ($p = 0.045$; 95%CI:0.003-0.337) as factors affecting MBL at 36 months. All the investigated parameters, with the only exception of implant placement group ($p = 0.020$; 95%CI:0.334-1.432) were not statistically significant at 48 months ($p > 0.05$).

Conclusion: Platform-switch implants placed nonsubmerged with a flapless approach showed a reduced bone loss progression in the first 4 years from insertion, as MBL remained stable at longer times (36 and 48 months). Implants placed after 10-12 months after extraction showed a higher bone loss when compared to early and immediate implants.

Keywords: MBL, dental implants, flapless surgery, best clinical practice, platform-switch.

1 INTRODUCTION

2

3 Although submerged dental implants show high and predicable long-term success,^{1,2} a growing
4 interest in less invasive protocols is reported in literature.³

5

6 Placement of implants in a **nonsubmerged tissue-level approach** has been proposed in different
7 studies as a predictable technique with similar risks compared to traditional submerged technique^{4,6}
8 and high long term survival.⁷ Nonsubmerged healing is usually achieved placing a bone level
9 implant and immediately positioning a healing screw which remain exposed to the oral
10 environment.⁸ Key factors to preserve marginal bone level (MBL) are implant abutment connection,
11 implant neck configuration and surgical techniques.⁹⁻¹¹

12

13 **Platform switch** concept has been reported by Lazara and Porter in 2006.¹² Through the
14 repositioning of a cylindrical implant abutment junction far from the crestal bone, platform switch
15 demonstrated reduced bone loss values.^{12,13}

16 Implants with this configuration are usually positioned at bone level (submerged), with the neck at
17 crestal bone height (equicrestally) or 1mm under (subcrestally).¹⁴

18 **Histological findings**, however, revealed that when tapered platform-switch implants are
19 positioned subcrestally, greater bone remodeling may be expected, as the removal of a great portion
20 of the coronal bone during site preparation could compromise blood supply of the remaining cortical
21 bone.^{14,15}

22 A low invasive approach could be placing a flapless switching platform implant in a supracrestal
23 position, with the rough surface positioned at the bony crest and the smooth machined neck at tissue
24 level, allowing the implant cover screw to be exposed at the oral environment.

25

26 **MBL differences** represent an important analysis which may provide information on peri-implant

27 bone health/disease.¹⁶ Indeed, the radiographic assessment of MBL at different endpoints gives
28 important information regarding the hard and soft tissues modification which occurs in the early
29 healing phases (pre-loading period)^{17,18} or after the definitive restoration (post-loading period).¹⁹
30 Numerous other conditions, as well as pre, intra and post-operative parameters may affect peri-
31 implant marginal bone morphology/environment and clinical-radiographic aspects.
32 Different **statistical methodologies**, such as multilevel analysis²⁰ or linear logistic regressions^{21,22}
33 have been proposed and used to evaluate and correlate strategic-technical (i.e. surgical) decision
34 with many factors associated to MBL such as bone quality, implant diameter, implant surface, and
35 type of prosthetic prosthesis.²¹

36

37 To the best of our knowledge, no studies have ever analysed multiple operative factors associated
38 to MBL modifications around nonsubmerged tulip-shaped platform-switch flapless implants.

39

40 Therefore, the aim of this consecutive, non-randomized prospective cohort study was to investigate
41 factors which may affect MBL around implants placed nonsubmerged. Different pre-operative, intra
42 and post-operative clinical parameters have been analyzed at 1, 3 (preloading time) and at 6, 12, 24,
43 36 and 48 months.

44

45 **MATERIALS AND METHODS**

46 **Study setting and patient selection**

47 The study design was a single-blind human longitudinal prospective cohort study comparing the
48 clinical and radiographic outcome after 4 years for the treatment of patients who had been lost one
49 or more teeth for endodontic, root fracture and deep-cariou lesions.

50 The study was conducted in one University Endodontic Clinical Department and in two private
51 dental offices between January 2011 and January June 2018 by the same clinical team.

52 Recruitment of patients was performed from October 2009 to June 2014.

53 Once included in the study, patients were treated from January 2010 to July 2014.

54 All patients included in this investigation were treated according to the principles established by the
55 Declaration of Helsinki as modified in 2013.²³

56 Before enrolment, written and verbal information were given by the clinical staff and each patient
57 gave a written consent according to the above-mentioned principles. An additional signed informed
58 consent was obtained from all patients stating that they accepted the treatment plan and agreed to
59 cover the costs and follow the maintenance hygiene program. This report was written according to
60 the Consolidated Standards of Reporting trials guidelines for reporting clinical trials (STROBE)²⁴
61 and respecting the guidelines published by Dodson in 2007.²⁵

62 The patients were considered eligible or non-eligible for inclusion in the clinical protocol based on
63 the following criteria:

64 Inclusion criteria

- 65 - 18-75 years of age at the time of implant placement
- 66 - partially dentate requiring dental implants
- 67 - possibility to be included in a hygiene recall program and implant control for at least 4 years

68

69 Exclusion criteria

- 70 - Medical and/or general contraindications for the surgical procedures (ASA score ≥ 3)
- 71 - poor oral hygiene and lack of motivation
- 72 - active clinical periodontal disease in the dentition expressed by probing pocket depth >4 mm and
73 bleeding on probing
- 74 - smoking more than 20 cigarettes by day
- 75 - uncontrolled diabetes mellitus
- 76 - systemic or local diseases that could compromise post-operative healing and osseointegration
- 77 - alcohol and/or drug abuse
- 78 - pregnancy or lactating

79 - malocclusion and other occlusal disorder (bruxism)

80 - bisphosphonate therapy

81 Clinical evaluations of periapical status were made by three experienced operators included as

82 Authors.

83

84 **Treatment procedures**

85 Choice of the surgical approach and timing of implant placement, (immediate, early, delayed
86 according to the timing classification proposed by the Third ITI Consensus Conference)²⁶ was not
87 determined randomly as the purpose of the study was to use well-defined clinical parameters for the
88 “best clinical practice”.²⁷

89 Therefore, the choice of the different surgical approach and the consequent clinical decision and
90 implant placement timing (immediate, early and delayed) was made on the basis of the following
91 clinical criteria: presence of acute endodontic periapical lesion (with pain, fistula, exudate/pus,
92 tenderness and radiographic apical translucency or all of them) and/or the presence of chronic
93 periapical disease (Periapical Index or PAI 3-4).²⁸

94 The three surgical timings were defined as follow:

95 - Immediate post-extraction implant (Type 1 for ITI)²⁶: when the implant was placed into fresh
96 extraction socket immediately after extraction of root affected by chronic periapical disease and/or
97 seriously damaged hopeless (or fractured) teeth were assigned to this group. Only chronic periapical
98 lesions were present and identified by periapical radiolucency.

99 - Early implant (Type 2 for ITI)²⁶: when the implant was placed in healed bone after 8-12 weeks
100 after extraction of root affected by acute periapical lesion and/or abscess, pus and clinical symptoms.

101 - Delayed implant (Type 4 for ITI)²⁶: when the implant was placed in edentulous mature bone 10-
102 12 months after the tooth extraction for different reasons,

103

104 **Surgical procedures**

105 Cylindrical implants (SP Premium, Sweden & Martina, Padova, Italy) with zirconium-oxide blasted
106 (ZirTi) surface, smooth machined collar 0.5 mm, tulip-shape profile switching platform emergence
107 profile 0.3 mm, hexagonal internal connection and 3.8 or 4.25 or 5.0 mm diameter (10.0 mm or 11.5
108 mm length) were used.

109 One single experienced surgeon performed all surgeries.

110 A careful occlusal and periodontal examination was performed on each patient, including presence
111 of plaque, gingivitis, pocket depth and radiographic bone loss of all remaining teeth. Oral hygiene
112 instruction and periodontal therapy were performed when and where indicated.

113 Two days prior to the intervention, all patients were asked to comply with a pharmacological regime
114 that included amoxicillin/clavulanic acid 1 gr tablet and application of chlorhexidine digluconate
115 0.20% gel (Corsodyl Gel, GlaxoSmithKline UK, Brentford, UK) twice a day, according with a
116 previous study.²⁹

117 Antibiotic administration continued during 5-6 days after surgery.

118 All surgical procedures were conducted under local anesthesia with mepivacaine chlorhydrate
119 30mg/ml (Carboplyina, Dentsply Italia srl, Roma, Italy). No computer-aided guide was used.

120 Implants were placed in order to obtain transmucosal nonsubmerged tissue level position healing.
121 The smooth machined collar of the implant platform was placed in the thickness of gingival tissue
122 while the divergent rough implant portion was lean/nested at the bony crest (using standard
123 protocol). In all implants an adequate primary stability was obtained. The final insertion torque
124 value ranged between 20-70 N/cm² and was recorded. Considering the thickness of the mucosa, a 1
125 mm or 2-3 mm high cover-healing screw, that emerged just over the gingival level, was applied.

126

127 **Immediate implant placement**

128 For immediate post-extractive insertion an atraumatic flapless root extraction was performed and a
129 careful inspection of the socket site was made. All granulation tissue was gently debrided from the
130 apical portion of the socket.

131 Then a 1.2 mm drill was used to prepare the intra-socket place, following the palatal bony walls as
132 a guide. Twist and calibrated drills at 225 rpm were then used and irrigated with sterile saline
133 solution.

134 Primary implant stability was obtained by anchoring the implant in the remaining apical portion of
135 the socket at least 3 mm beyond the root apex area.

136 When necessary, (4 cases) a porcine corticocancellous bone substitute (Osteobiol MP3, Tecknoss
137 Dental, Coazze, Italy) was applied into the surgical site to fill the socket and to reduce any gaps
138 between the implant and the residual bone.

139 Considering the thickness of the mucosa, a 1 mm or 2-3 mm high cover-healing screw, that emerged
140 just over the gingival level, was applied, following a nonsubmerged healing approach (as above
141 mentioned).

142

143 **Early and delayed implant placement**

144 The surgical procedures were similar for the Early and Delayed placements. No flaps were reflected.

145 An initial 1.2 mm diameter drill was used to mark the position, angle and depth. The drill passed
146 through the mucosa (transmucosal), cortical bone and cancellous bone under copious saline
147 irrigation. A twist and calibrated drill at 225 rpm was used and a site of the adequate depth and
148 diameter was created whilst irrigating with sterile saline solution.

149 The entire rough surface region of implants was positioned approx. 1 mm under the cortical bone
150 level and smooth machined collars of the implant platform were placed in the thickness of gingival
151 tissue. The cover screw was at tissue level exposed.

152 Considering the thickness of the mucosa, a 1 mm or 2-3 mm high cover-healing screw, that emerged
153 just over the gingival level, was applied, following a nonsubmerged healing approach (as above
154 mentioned). No computer-aided surgical guides were used.

155

156 **Post-operative procedures**

157 A surgical dressing (Coe-Pak, GC, Tokyo, Japan) was placed on the wound in all patients and
158 removed at the first clinical control after one week
159 Patients were instructed to follow a soft diet regime for one week, to rinse 3 time/day with 0.12%
160 chlorhexidine gel for 3 weeks and to perform oral hygiene on the Coe-Pak using a normal-medium
161 toothbrush for the first week and for 2 weeks after surgical pack removal. Thereafter, conventional
162 brushing and flossing were permitted.

163

164 **Prosthetic rehabilitation**

165 Prosthetic phases started after 3 months from implant insertion. No second surgeries to expose the
166 implant neck were performed. Briefly, cover screws were removed, impression posts were placed
167 and impressions made with polyether materials (PermadyneTM and GarandTM, 3M ESPE, St Paul,
168 MN, USA) in customized trays for pick up technique.

169 Customized definitive abutments were screwed on the implants after approx. 15 days and
170 provisional resin crowns cemented with temporary zinc-oxide eugenol cement (Temp Bond, Kerr,
171 Scafati, Italy).

172 Definitive prosthetic metal-ceramic rehabilitation, made by two equally experienced
173 prosthodontists, were positioned on definitive abutments and fixed with polycarboxylate cement
174 (Heraeus Kulzer GmbH, Hanau, Germany) 12-15 days later.³⁰

175 The quantity of the extruded cement was reduced by filling the occlusal half of the crown and
176 maintaining an occlusal space of the abutment screw channel as internal venting to minimize the
177 hydraulic pressure through slowing cement escape. Patients were instructed to continuously bite on
178 a cotton roll for 5 minutes. Subsequently dental floss was used to remove the cement flow.

179

180

181 **Follow-up implant evaluation**

182 Active periodontal therapy consisting of motivation, instruction in oral hygiene practice, scaling

183 and root planning was performed during the entire time of observation, no bleeding on probing and
184 pocket probing depth ≥ 3 mm were detected during the follow-up procedures. Routinary follow-up
185 visits were performed every 6 months from implant loading. Occurrence of endodontic treatments
186 on implant adjacent teeth was also recorded.

187

188

189 **Gingival thickness evaluation**

190 The soft tissue thickness around implants and their corresponding mesial neighboring teeth was
191 determined at 4 year follow-up. The soft tissue was pierced mid-facially at three millimeters apical
192 to the gingival margin with an endodontic file. (K-file Nr. 20; Dentsply-Maillefer, Switzerland).
193 Gingival biotype was defined thick (soft tissue thickness > 2 mm) or thin (soft tissue thickness \leq
194 2mm).³¹⁻³³

195

196 **Radiographic assessment**

197 Intraoral periapical radiographs of all implants were taken using a paralleling technique with Rinn-
198 holders and analog films (Kodak Ektaspeed Plus, Eastman Kodak Co., Rochester, NY, USA) after
199 implant placement (baseline) and at 1, 3, 6, 12 and 24 months after implant insertion.

200 All X-rays were scanned with a slide scanner with a resolution of 968 dpi and a magnification factor
201 of x20. Length and diameter of implants were used to calibrate the measurement.

202 The crestal marginal bone and the bone-implant interface were examined to evaluate the marginal
203 bone morphology. MBL was assessed at the mesial and distal implant surfaces by measuring the
204 distance between the reference point of the implant platform to the most coronal bone-to-implant
205 contact level using a scale divided into 0.1 mm steps according to previous studies^{34,35} and corrected
206 according to the know height and width of each implant.³⁶

207 Radiographic evaluation was performed in single-blind by one additional examiner. Before
208 evaluating the radiographs, the examiner was calibrated by using well-defined instructions and

209 reference radiographs with different marginal bone level measures.

210

211 **Evaluated Variables**

212 MBL was measured and evaluated according to the following variables:

213 1) Preoperative parameters: Implant location (maxilla/mandible), Implant position

214 (anterior/posterior) Gender (male/female), Endodontically treated adjacent teeth (yes/no),

215 Smoke (yes/no), Implant placement timing (immediate/early/delayed)

216 2) Intra operative parameters: Implant diameter (3.8/4.25/5.0)

217 3) Post-operative parameters: Gingival thickness (yes/no)

218

219 **Statistical analysis**

220 Statistical analyses were performed using Stata 13.1 (StataCorp, College Station, TX).

221 Linear regression models were fitted to evaluate the existence of any significant difference

222 regarding endodontically treated adjacent teeth (yes/no), times (one month, 3 months, 6 months, 12,

223 24, 36 and 48 months), and the interactions between endodontically treated adjacent teeth and time.

224 To take into account the correlation in the data due to the presence of multiple implants per subject,

225 the abovementioned regression models were estimated following a generalized estimating equation

226 (GEE) approach. The estimates of coefficients' standard errors and confidence intervals were

227 adjusted by using a robust variance-covariance estimator.³⁷ The same analysis was performed for

228 all the operative variables.

229 A multiple linear regression with stepwise selection was fitted to evaluate the relationship between

230 MBL at 36, 48 months and the following variables: gender (male/female), smoke (yes/no), location

231 (mandible/maxilla), implant position (anterior/posterior), endodontic adjacent teeth (yes/no),

232 adjacent teeth coronal restoration (direct/indirect/no restoration), implant placement timing

233 (immediate/early/delayed), implant diameter (3.8/4.25/5.0), gingival thickness" (thin/thick).

234 Box plots were created by using Sigma plot 12 software (Systat, Usa) to show the range and

235 distribution of MBL (mm) as a function of implant placement timing (immediate, early delayed) at
236 at 1, 3, 6, 12, 24, 36 and 48 months from implant insertion.

237

238 **RESULTS**

239 *Study population and demographic data*

240 According to the inclusion/exclusion criteria, 76 patients (128 implants) were studied with a mean
241 age of 55.6 ± 10.7 years (42 women and 34 men). Eight patients (17 implants) were identified as
242 smokers, consuming between 10 to 20 cigarettes/day and included in the study; these patients were
243 distributed evenly across the three groups (3 in immediate, 2 in early and 3 in delayed group).

244 The survival rate was 98.4% as 2 delayed implants failed during the observational time.

245 Two non-smoker patients dropped out after 6 and 36 months, respectively. Total drop
246 out was 2.58%.

247 No wound infection, osteitis and bone graft sequestration occurred during follow-up period.

248 Mucositis was observed in one patient after 3 months caused by a recurrent unscrewing of the
249 implant abutment. The abutment was removed and the area was carefully treated with chlorhexidine
250 0.12%. After 1 month, a new abutment was screwed and a new metal-ceramic crown was cemented.

251 Two series of periapical radiograph is reported in **Figs 1,2**.

252

253 *Radiographic and clinical assessment*

254 Mean MBL did not significantly change from T_{24} to T_{36} and T_{48} ($p > 0.05$). The values were 0.89 0.95
255 and 0.99 mm, respectively.

256 MBL of implants placed according to all the evaluated parameters is reported in **Table 1**.

257 Regarding pre-operative parameters, no statistical differences were observed for **implant position**,
258 **gender** and **smoke** at T_{36} . Differently, **implant location**, **presence of endodontic adjacent teeth**
259 and **implant placement timing significantly affected MBL**, revealing the most considerable
260 variations at T_{36} .

261 Concerning **implant diameter** as intra-operative and **gingival thickness** as post operative
262 parameter, no MBL significant differences were present at both T₃₆ and T₄₈ (p>0.05).
263 Significant differences were present considering **implant location** at T₃₆ (maxilla/mandible)
264 (p=0.004). Implant placed in the maxilla showed reduced bone loss when compared to that placed
265 in the mandible.
266 Implants placed in sites with no **adjacent endodontically treated teeth** shows a more stable MBL
267 at T₃₆ (mean MBL was 0.70mm vs 1.16mm, respectively), the differences were statistically
268 significant (p<0.001).
269 Considering **implant placement timing**, MBL increased significantly with time (from 1 month and
270 3-month pre-loading evaluation to the 24-36 month post-loading evaluation) in all the three groups
271 (immediate, early and delayed). Early implants showed the lowest bone loss at all the evaluation
272 times. Immediate implants demonstrated a similar behavior up to T₆.
273
274 Interestingly, when considering MBL at T₄₈, only **implant placement timing** shows statistically
275 significant differences. Delayed implants shows a higher MBL variation (mean value was 1.22±
276 0.69) mm when compared to both immediate and early implants (values were 0.76± 0.58 and
277 0.73±0.57, respectively).
278
279 Multilevel mixed logistic regression analysis at T₃₆ is reported in **Table 2a**.
280 The analysis confirms the significant influence of **endodontically treated adjacent teeth**
281 (p<0.0001), **implant placement timing** (p=0.044) and **implant location** (maxilla/mandible)
282 (p=0.019). No statistical differences were observed for the other parameters (p<0.05),
283
284 Multiple linear regression after stepwise selection (**Table 2b**) additionally confirms that all the 3
285 variables statistically affected MBL at T₃₆ (p value was 0.001 for endodontic treated adjacent teeth,
286 0.031 for implant location and 0.044 for implant placement timing).

287 Multilevel mixed logistic regression analysis at T₄₈ is reported in **Table 3a**. Interestingly, none of
288 the evaluated parameters appears to significantly affect MBL at this time. Implant placement group
289 appears to be a factor which significantly affects implant MBL only after stepwise logistic
290 regression, confirming data shown in Table 1 (p=0.020). (**Table 3b**)
291 Box plots representations concerning implant placement timing are showed in **Figure 3**. Delayed
292 group showed the highest presence of outliers, in particular after T₆ from insertion (post loading
293 period). Early group showed the most stable MBL values (less wide distributions) up to T₆
294 (preloading time) and at T₄₈.

295

296 **DISCUSSION**

297 This is the first 4-year study where platform-switch implants were used with an enlarged implant
298 neck positioned following a nonsubmerged healing. The results obtained confirms previously
299 reported 2-year prospective study.³⁰

300

301 The enlarged neck resulted partially immersed along the soft tissues thickness, the entire 0.50 mm
302 smooth machined neck surface close to the most superficial gingiva and the rough surface close to
303 the deeper gingival tissues.

304 **Several benefits** may be provided following this protocol. As cover screws (or healing screws,
305 depending on the soft tissue thickness) resulted exposed at soft tissue levels, additional surgeries
306 before the prosthetic phases could be avoided. The **implant-abutment connection**, as well as the
307 crown margins, resulted more distant from bone tissues, allowing a better control of cement flowing
308 from the restoration and avoiding the risks for **cement overflow** and cement retention in proximity
309 with the bone tissues.³⁸

310 This risk was reported in studies where subcrestal or equicrestal implants have been performed,
311 conditions where cement excess cannot be adequately controlled³⁹⁻⁴¹ or when methacrylate based
312 cements are used.⁴² A recent study evaluated clinical radiographic and immunologic parameters

313 around platform switch dental implants with cement retained or screw retained restorations.⁴³
314 Conclusions were that the type of crown retention does not affect BoP, Pocket depth, MBL and
315 levels of IL-1B. In the present study a polycarboxylate cement was used as luting agent.

316

317 **MBL values follow a similar trend** when compared to previously reported with other implant
318 brands,⁴⁴ neck,⁴⁵ insertion depth,⁵ and surgical interventions.¹⁸ A previous randomized clinical trial
319 evaluating bone level implants placed submerged or with a transmucosal approach found similar
320 MBL values at 36 months.⁵ Likewise, MBL remained stable after the first 12 months from insertion,
321 where the greater bone level changes occurred.⁵ A recently published randomized clinical trial
322 comparing flared tissue level versus platform-switch bone level implants found lower MBL values
323 at 5 years (mean MBL of tissue level implant was 0.61 ± 0.75)⁴⁴ than that reported in our study (0.99
324 ± 0.68). However, pre-loading MBL changes were not considered in that study as the MBL
325 evaluation started from the delivery of the definitive crown.

326 Significant bone level changes/remodeling during the **pre load period occurs**. This concept has
327 been also reported with other implants and surgical approaches.^{17,18}

328 Indeed, in the present study, mean MBL at 3 months (pre-load) was statistically different to 6
329 months MBL (post load) ($p=0.001$), the values being 0.28 ± 0.56 and 0.47 ± 0.57 respectively, thus
330 corroborating this hypothesis.

331

332 Data on implant depth insertion, are mostly from histological studies (45-Romanos 2015). Implants
333 with a tulip-shaped (flared) neck placed in a most apical position revealed more bone loss when
334 compared to the same implants placed supracrestally. This was attributed to the removal of a great
335 portion of the coronal bone, thus potentially compromising blood supply of the remaining cortical
336 bone.^{14,15}

337 In accordance with these histological findings, a recent randomized clinical trial concluded that the
338 preparation of the implant site following a subcrestal approach may induce more stress on marginal
339 bone, which can turn into greater bone resorption after implant placement.⁴⁶

340

341 **Different operative variables** have been analyzed in this study, which found to be important in on
342 bone level changes. Some of them revealed to greatly affect MBL.

343 **Implant location, presence of endodontic adjacent teeth and implant placement timing** were
344 significantly related to MBL at T₃₆.

345 Delayed group (implant placement timing) revealed significant differences from T₃ to T₄₈, showing
346 greater bone loss compared to both immediate and early implants. Indeed, box plots (**Figure 3**)
347 clearly evidences that delayed implants presented a wider distribution of implant with MBL values
348 > 1.0 mm at T₄₈.

349

350 **Implant position** parameter did not significantly influence MBL at T₃₆ and at T₄₈(p>0.05). The
351 group discrepancies may have influenced this result.

352

353 **Presence of endodontically treated adjacent teeth** close to peri-implant site are rarely reported
354 even though among all causes of implant failures, retrograde peri-implantitis or endodontic peri-
355 implantitis may have a central role.^{47,48}

356 In the present study, the presence of one or more **endodontic treated teeth** adjacent to the implant
357 site (**Endodontic adjacent teeth** parameter) appears to affect MBL only at T₃₆ (p=0.042): mean
358 MBL of implants with no adjacent endodontic treated teeth varied from 0.82mm ± 0.73 at T₂₄ to
359 0.72mm ± 0.68 at T₃₆ (**p>0.05**).

360 Retrograde peri-implantitis may be an important cause of implant failures, the infection triggered
361 by bacteria present in an adjacent (generally) active periapical lesion.⁴⁷

362 In some cases, dormant bacteria may remain silent around asymptomatic endodontic treated teeth.

363 49-51

364 A radiological follow-up of endodontic treated teeth might be important to identify this critical
365 condition.

366

367 Considering **gender**, female patients showed an increased MBL after 3 years, compared to males
368 (mean MBL was 1.08mm vs 0.83mm respectively). These differences, however, were not
369 statistically significant ($p=0.157$). From literature, male patients seem to have higher risks of
370 implant failure however these data are controversial as it is difficult to correlate peri-implant bone
371 loss and patient gender.⁵²

372 In the present study **smoke** was found to not significantly affect MBL in the medium-term. The
373 small sample size of smoking patients and the groups discrepancies (17 implants in 8 patients vs 92
374 implants in 57 patients) may justify this finding.

375

376 **Gingival thickness** was evaluated in all patients at 48-month follow-up. Interestingly, even though
377 thin biotype showed higher values of MBL this parameter appears not to influence MBL at 36 and
378 48 months($p>0.05$).

379

380 Implants placement timing was found to be the most significant factors affecting MBL on
381 nonsubmerged platform-switch tulip-shaped implants. In particular delayed implant groups showed
382 the greatest bone loss. Differences were statistically significant at all the evaluation times. Drilling
383 procedures at the implant site may be responsible for bone necrosis and bone smear layer formation,
384 inducing the activation of osteoclasts and vascularization damage. Both these conditions may be
385 responsible for higher bone resorption of the mature cortical bone.^{53,54}

386 It should be underlined that the reduced bone loss values reported in this study may be influenced
387 by the operator expertise who performed the surgeries and the possibility of patients to be included
388 in a hygienic recall programme. This protocol should be further validated with long term follow-up.

389

390 **Conclusions**

391 Conclusion may be summarized as follows:

392

393 - Tulip-shaped neck platform switch implants may be placed at tissue level (nonsubmerged)
394 with a minimally invasive flapless technique.

395 - The present protocol demonstrated a reduced bone loss in the early phases from implant
396 placement and a MBL stability at 36 and 48 months.

397 - Among all the evaluated parameters, only implant placement timing appears to significantly
398 affect MBL before loading and during the entire period of observation.

399 - Delayed implant placement was responsible for higher bone loss when compared to early
400 and immediate implants

401

402

403

404

405

406

407

408

409 **REFERENCES**

410

- 411 1. Jung RE, Zembic A, Pjetursson BE, Zwahlen M, Thoma DS. Systematic review of the survival rate and the incidence
412 of biological, technical, and aesthetic complications of single crowns on implants reported in longitudinal studies with
413 a mean follow-up of 5 years. *Clin Oral Implants Res* 2012;23:2-21.
414
- 415 2. Pjetursson BE, Thoma D, Jung R, Zwahlen M, Zembic A. A systematic review of the survival and complication rates
416 of implant-supported fixed dental prostheses (FDPs) after a mean observation period of at least 5 years. *Clin Oral*
417 *Implants Res* 2012;23:22-38.
418
- 419 3. Cordaro L, Torsello F, Chen S, Ganeles J, Brägger U, Hämmerle C. Implant-supported single tooth restoration in the
420 esthetic zone: Transmucosal and submerged healing provide similar outcome when simultaneous bone augmentation is
421 needed. *Clin Oral Implants Res* 2013;24:1130-1136.
422
- 423 4. Paul S, Petsch M, Held U. Modeling of Crestal Bone After Submerged vs Transmucosal Implant Placement: A
424 Systematic Review with Meta-Analysis. *Int J Oral Maxillofac Implants* 2017;32:1039-1050.
425
- 426 5. Sanz Martin I, Benic GI, Hammerle CH, Thoma DS. Prospective randomized controlled clinical study comparing
427 two dental implant types: Volumetric soft tissue changes at 1 year of loading. *Clin Oral Implants Res* 2016;27:406-411.
428
- 429 6. Giacomel MC, Camati P, Souza J, Deliberador T. Comparison of Marginal Bone Level Changes of Immediately
430 Loaded Implants, Delayed Loaded Nonsubmerged Implants, and Delayed Loaded Submerged Implants: A Randomized
431 Clinical Trial. *Int J Oral Maxillofac Implants* 2017;32:661-666.
432
- 433 7. Buser D, Janner SFM, Wittneben J-, Brägger U, Ramseier CA, Salvi GE. 10-Year Survival and Success Rates of 511
434 Titanium Implants with a Sandblasted and Acid-Etched Surface: A Retrospective Study in 303 Partially Edentulous
435 Patients. *Clin Implant Dent Relat Res* 2012;14:839-851.
436
- 437 8. Sanz M, Ivanoff CJ, Weingart D, Wiltfang J, Gahlert M, Cordaro L et al. Clinical and Radiologic Outcomes after
438 Submerged and Transmucosal Implant Placement with Two-Piece Implants in the Anterior Maxilla and Mandible: 3-
439 Year Results of a Randomized Controlled Clinical Trial. *Clin Implant Dent Relat Res* 2015;17:234-246.
440
- 441 9. Hermann JS, Buser D, Schenk RK, Schoolfield JD, Cochran DL. Biologic Width around one- and two-piece titanium

442 implants. Clin Oral Implants Res 2001;12:559-571.

443

444 10. Schwarz F, Mihatovic I, Golubovich V, Schär A, Sager M, Becker J. Impact of abutment microstructure and
445 insertion depth on crestal bone changes at nonsubmerged titanium implants with platform switch. Clin Oral Implants
446 Res. 2015;26:287-92.

447

448 11. Flores-Guillen J, Álvarez-Novoa C, Barbieri G, Martín C, Sanz M. Five-year outcomes of a randomized clinical
449 trial comparing bone-level implants with either submerged or transmucosal healing. J Clin Periodontol 2018;45:125-
450 135.

451

452 12. Lazzara RJ, Porter SS. Platform switching: A new concept in implant dentistry for controlling post-restorative crestal
453 bone levels. Int J Periodontics Restorative Dent 2006;26:9-17.

454

455 13. Canullo L, Fedele GR, Iannello G, Jepsen S. Platform switching and marginal bone-level alterations: The results of
456 a randomized-controlled trial. Clin Oral Implants Res 2010;21:115-121.

457

458 14. Valles C, Rodríguez-Ciurana X, Nart J, Santos A, Galofre M, Tarnow D. Influence of Implant Neck Surface and
459 Placement Depth on Crestal Bone Changes Around Platform-Switched Implants: A Clinical and Radiographic Study in
460 Dogs. J Periodontol 2017;88:1200-1210.

461

462 15. Alomrani AN, Hermann JS, Jones AA, Buser D, Schoolfield J, Cochran DL. The effect of a machined collar on
463 coronal hard tissue around titanium implants: a radiographic study in the canine mandible. Int J Oral Maxillofac
464 Implants 2005;20:677-686.

464

465 16. Klinge B. Peri-implant marginal bone loss: An academic controversy or a clinical challenge? Eur J Oral Implantol
466 2012;5:13-19.

467

468 17. Nickenig HJ, Wichmann M, Schlegel KA, Nkenke E, Eitner S. Radiographic evaluation of marginal bone levels
469 during healing period, adjacent to parallel-screw cylinder implants inserted in the posterior zone of the jaws, placed
470 with flapless surgery. Clin Oral Implants Res 2010;21:1386-1393.

471

472 18. Prati C, Zamparini F, Scialabba VS, Gatto MR, Piattelli A, Montebugnoli L *et al.* A 3-year prospective cohort study

473 on 132 calcium phosphate blasted implants: flap vs flapless technique. *Int J Oral Maxillofac Implants* 2016;31:413-423.
474

475 19. French D, Cochran DL, Ofec R. Retrospective Cohort Study of 4,591 Straumann Implants Placed in 2,060 Patients
476 in Private Practice with up to 10-Year Follow-up: The Relationship Between Crestal Bone Level and Soft Tissue
477 Condition. *Int J Oral Maxillofac Implants* 2016;31:168-178.
478

479 20. Cairo F, Carnevale G, Buti J, Nieri M, Mervelt J, Tonelli P *et al.* Soft-tissue re-growth following fibre retention
480 osseous resective surgery or osseous resective surgery: a multilevel analysis. *J Clin Periodontol* 2015;42:373-9.
481

482 21. Ibañez C, Catena A, Galindo-Moreno P, Noguerol B, Magán-Fernández A, Mesa F. Relationship Between Long-
483 Term Marginal Bone Loss and Bone Quality, Implant Width, and Surface. *Int J Oral Maxillofac Implants* 2016;31:398-
484 405.
485

486 22. Zucchelli G, Mounssif I, Mazzotti C, Stefanini M, Marzadori M, Petracci E, et al. Coronally advanced flap with and
487 without connective tissue graft for the treatment of multiple gingival recessions: A comparative short- and long-term
488 controlled randomized clinical trial. *J Clin Periodontol* 2014;41:396-403.
489

490 23. World Medical Association Declaration of Helsinki: Ethical principles for medical research involving human
491 subjects. *JAMA* 2013;310:2191-2194.
492

493 24. Vandembroucke JP, von Elm E, Altman DG, Gøtzsche PC, Mulrow CD, Pocock SJ et al. Strengthening the reporting
494 of observational studies in epidemiology (STROBE): explanation and elaboration *PLoS Med* 2007;4:1628-1654.
495

496 25. Dodson TB. A guide for preparing a patient-oriented research manuscript. *Oral Surg Oral Med Oral Pathol Radiol*
497 *Endod* 2007;104:307-315.
498

499 26. Hämmerle CH, Chen ST, Wilson TG Jr. Consensus statements and recommended clinical procedures regarding the
500 placement of implants in extraction sockets. *Int J Oral Maxillofac Implants* 2004 19:26-28.
501

502 27. Taxel P, Ortiz D, Shafer D, Pendrys D, Reisine S, Rengasamy K et al. The relationship between implant stability
503 and bone health markers in post-menopausal women with bisphosphonate exposure. *Clin Oral Invest* 2014;18:49-57.

504

505 28. Ørstavik D, Kerekes K, Eriksen HM. The periapical index: a scoring system for radiographic assessment of apical
506 periodontitis. *Endod Dent Traumatol* 1986;2:20-34.

507

508 29. Anitua E, Piñas L, Begoña L, Orive G. Long-term retrospective evaluation of short implants in the posterior areas:
509 clinical results after 10–12 years. *J Clin Periodontol* 2014;41:404-411.

510

511 30. Prati C, Zamparini F, Pirani C, Gatto MR, Piattelli A, Gandolfi MG. Immediate early and delayed implants: A 2-
512 year prospective cohort study of 131 transmucosal flapless implants placed in sites with different pre-extractive
513 endodontic infections. *Implant Dent* 2017;26:654-663.

514

515 31. Cosgarea R, Gasparik C, Dudea D, Culic B, Dannewitz B, Sculean A. Peri-implant soft tissue colour around
516 titanium and zirconia abutments: a prospective randomized controlled clinical study. *Clin Oral Implants Res*
517 2015;26:537-544.

518

519 32. Zembic A, Sailer I, Jung RE, Hammerle CH. Randomized-controlled clinical trial of customized zirconia and
520 titanium implant abutments for single tooth implants in canine and posterior regions: 3-year results. *Clin Oral Implants*
521 *Res* 2009;20:802-808.

522

523 33. Ferrari M, Carrabba M, Vichi A, Goracci C, Cagidiaco MC. Influence of abutment color and mucosal thickness on
524 soft tissue color. *Int J Oral Maxillofac Implants* 2017;32:393-399.

525

526 34. Sanz M, Cecchinato D, Ferrus J, Salvi GE, Ramseier C, Lang NP et al. Implants placed in fresh extraction sockets
527 in the maxilla: clinical and radiographic outcomes from a 3-year follow-up examination. *Clin Oral Implants Res*
528 2014;25:321-327.

529

530 35. Thoma DS, Sanz Martin I, Benic GI, Roos M, Hämmerle CH. Prospective randomized controlled study comparing
531 two dental implant systems: demographic and radiographic results at one year of loading. *Clin Oral Implants Res*
532 2014;25:142-149.

533

534 36. Galindo-Moreno P, León-Cano A, Ortega-Oller I, Monje A, O Valle F, Catena A. Marginal bone loss as success

535 criterion in implant dentistry: beyond 2 mm. *Clin Oral Implants Res* 2015;26:28-34.

536

537 37. Rogers WH. Regression standard errors in clustered samples. *Stata Technical Bulletin* 1993;13:19-23.

538

539 38. Buser D, Mericske-Stern R, Dula K, Lang NP. Clinical experience with one-stage, non-submerged dental implants.

540 *Adv Dent Res* 1999;13:153-161.

541

542 39. Linkevicius T, Puisys A, Vindasiute E, Linkeviciene L, Apse P. Does residual cement around implant-supported

543 restorations cause peri-implant disease? A retrospective case analysis. *Clinical Oral Implant Research* 2013; 24:1179-

544 1184.

545 40. Linkevicius T, Vindasiute E, Puisys A, Peciuliene V. The influence of margin location on the amount of undetected

546 cement excess after delivery of cement-retained implant restorations. *Clinical Oral Implant Research* 2011;22:1379-

547 1384

548

549 41. Canullo L, Cocchetto R, Marinotti F, Oltra DP, Diago MP, Loi I. Clinical evaluation of an improved cementation

550 technique for implant-supported restorations: a randomized controlled trial. *Clin Oral Implants Res* 2016;27:1492-1499.

551

552 42. Korsch M, Obst U, Walther W. Cement-associated peri-implantitis: a retrospective clinical observational study of

553 fixed implant-supported restorations using a methacrylate cement. *Clin Oral Implants Res* 2014;25:797-802.

554

555 43. Al Amri MD, Al-Rasheed AS, Al-Kheraif AA, Alfadda SA. Comparison of Clinical, Radiographic, and

556 Immunologic Inflammatory Parameters Around Dental Implants with Cement-Retained and Screw-Retained

557 Restorations: A 5-Year Prospective Cohort Study in Men. *Int J Prosthodont* 2017;30:384-389.

558 44. Lago L, da Silva L, Martinez-Silva I, Rilo B. Radiographic Assessment Of Crestal Bone Loss In Tissue-Level

559 Implants Restored By Platform Matching Compared With Bone-Level Implants Restored By Platform Switching: A

560 Randomized, Controlled, Split-Mouth Trial With 3-Year Follow-Up. *Int J Oral Maxillofac Implants* 2018 in press.

561

562 45. Romanos GE, Aydin E, Gaertner K, Nentwig G. Long-term results after subcrestal or crestal placement of delayed

563 loaded implants. *Clin Implant Dent Relat Res* 2015;17:133-141.

564

565 46. Gatti C, Gatti F, Silvestri M, Mintrone F, Rossi R, Tridondani G et al. A Prospective Multicenter Study on
566 Radiographic Crestal Bone Changes Around Dental Implants Placed at Crestal or Subcrestal Level: One-Year Findings.
567 Int J Oral Maxillofac Implants 2018;33:913-918.
568

569 47. Quirynen M, Vogels R, Alsaadi R, Naert I, Jacobs R, van Steenberghe D. Predisposing conditions for retrograde
570 peri-implantitis and treatment suggestions. Clin Oral Implants Res 2005;16:599-608.
571

572 48. López-Martínez F, Gómez Moreno G, Olivares-Ponce P, Eduardo Jaramillo D, Eduardo Maté Sánchez de Val J,
573 Calvo-Guirado JL. Implants failures related to endodontic treatment. An observational retrospective study. Clin Oral
574 Implants Res 2015;26:992-995.
575

576 49. Nair PNR On the causes of persistent apical periodontitis: A review. Int Endod J 2006;39:249-281.
577

578 50. Siqueira Jr. JF, Rôças IN, Ricucci D, Hülsmann M. Causes and management of post-treatment apical periodontitis.
579 Br Dent J 2014; 216:305-312.
580

581 51. Zhou W, Han C, Li D, Li Y, Song Y, Zhao Y. Endodontic treatment of teeth induces retrograde peri-implantitis.
582 Clin Oral Implants Res 2009;20:1326-1332.
583

584 52. Chrcanovic BR, Albrektsson T, Wennerberg A. Dental implants inserted in male versus female patients: a systematic
585 review and meta-analysis. J Oral Rehabil 2015;42:709-722.
586

587 53. Baffone GM, Botticelli D, Pantani F, Cardoso LC, Schweikert MT, Lang NP. Influence of various implant platform
588 configurations on peri-implant tissue dimensions: An experimental study in dog. Clin Oral Implants Res 2011;22:438-
589 444.
590

591 54. Baffone GM, Botticelli D, Pereira FP, Favero G, Schweikert M, Lang NP. Influence of buccal bony crest width on
592 marginal dimensions of periimplant hard and soft tissues after implant installation an experimental study in dogs. Clin
593 Oral Implants Res 2013;24:250-254.
594
595
596

597 **FIGURES:**

598

599

600

601

602

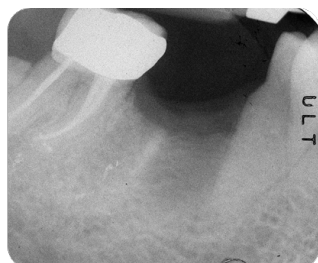603

604

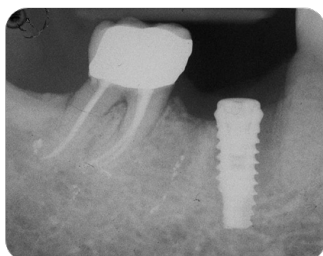605

606

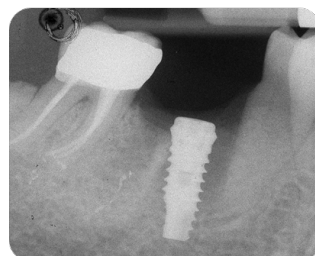
607



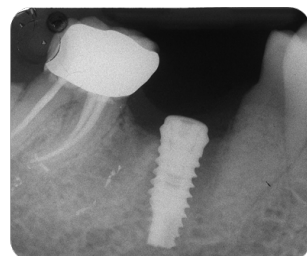
Post-extraction



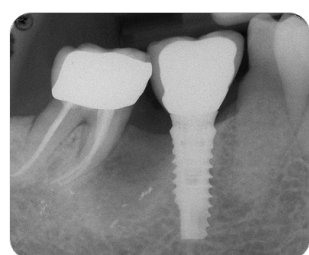
Early insertion



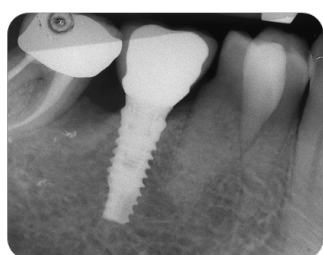
1 month



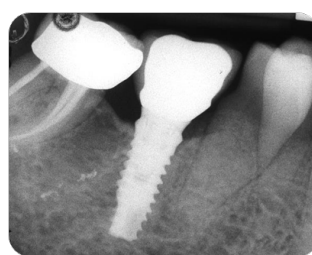
3 month



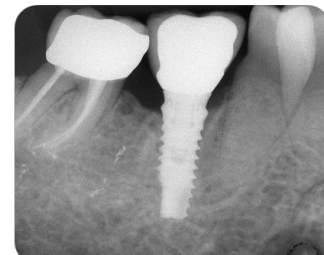
12 month



24 month



36 month



48 month

608 **Figure 1:** 49-year old female nonsmoker patient with early post-extractive site (first lower right
609 root treated molar was extracted for root fracture 2 months before). A 4.25x 11.5 mm platform
610 switch implants was placed nonsubmerged by using flapless technique. No complications were
611 observed. After 3 months an impression was taken without second stage surgeries. MBL resulted
612 stable at preloading time (1,3 months from implant insertion) and at 12 and 24 months (post-loading
613 time). Please note that the crown margin ends approx. 2mm from the alveolar bone. In this way,
614 cement excesses may be more easily removed. Crestal bone loss has been evidenced at 36 and 48
615 months.

616

617

618

619

620

621

622

623

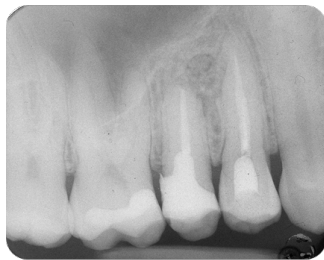624

625

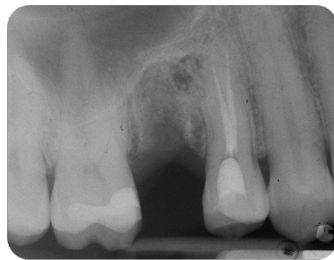626

627

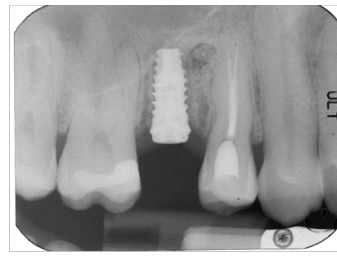
628



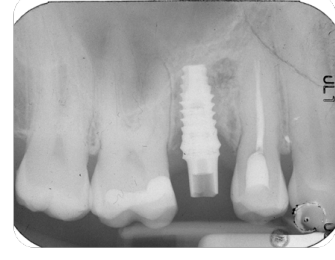
Preoperative



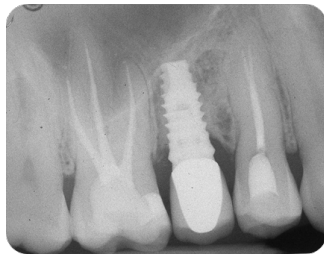
Extraction



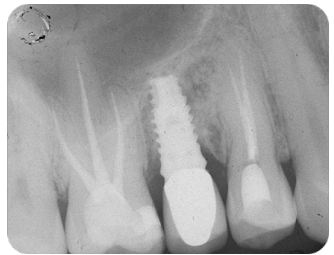
Early insertion



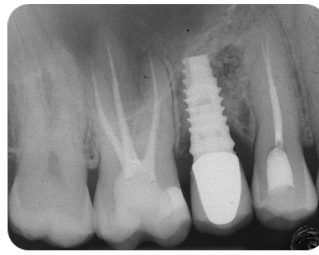
3 months



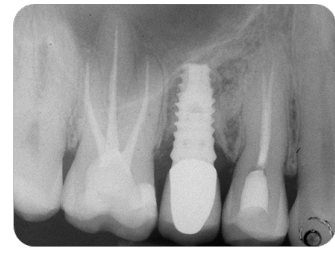
12 months



24 months



36 months



48 months

629 **Figure 2:** 42 year old female patient with upper right premolar presenting a vertical root fracture
630 and active periapical lesion (periapical fistula). Extraction was performed and implant insertion was
631 scheduled 3 months after (early insertion). A 4.25x10mm implant was inserted with a flapless
632 technique. Impression were taken after 3 months and a provisional crown cemented. Initial bone
633 loss have been observed during pre-loading period. MBL remained stable up to 48 months. Note
634 the presence of 2 endodontic treated teeth 10-12 months from implant insetion. Bone loss was
635 observed.

636

637

638

639

640

641

642

643

644

645

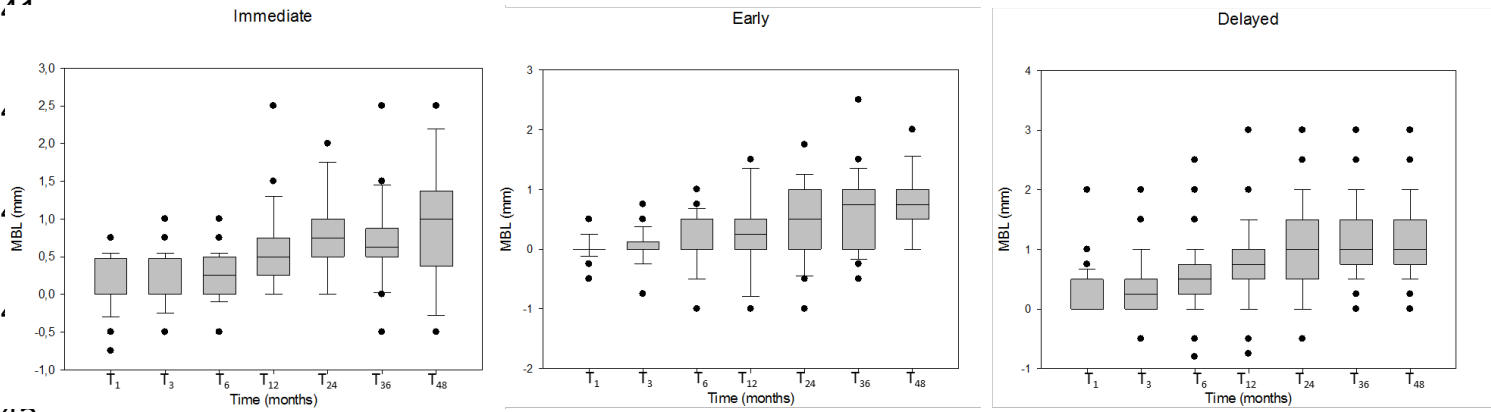
646 **Figure 3** Boxplot representation of placed implants at different evaluation times. Outliers are
647 represented by circle points.

648

649

650

651



653
654
655
656
657
658
659
660
661
662
663
664
665
666
667
668
669
670

Table 1. MBL (Mean ± SD) of the placed implants according to the operative parameters

	n	T ₁	T ₃	T ₆	T ₁₂	T ₂₄	T ₃₆	T ₄₈
<i>Pre-operative parameters</i>								
Implant location	Maxilla	0.15 ± 0.38 ^{Aa}	0.23 ± 0.65 ^{Aa}	0.32 ± 0.51 ^{ABb}	0.50 ± 0.61 ^{Bb}	0.72 ± 0.76 ^{Ca}	0.75 ± 0.75 ^{Cb}	0.86 ± 0.69 ^{Ca}
	Mandible	0.29 ± 0.44 ^A	0.36 ± 0.49 ^{Aa}	0.63 ± 0.67 ^{Ba}	0.90 ± 0.75 ^{Ca}	1.05 ± 0.80 ^{Ca}	1.20 ± 0.87 ^{Ca}	1.19 ± 0.71 ^{Ca}
Implant position	Anterior	0.20 ± 0.39 ^{Aa}	0.22 ± 0.60 ^{Aa}	0.39 ± 0.57 ^{Ba}	0.50 ± 0.69 ^{Ba}	1.18 ± 0.77 ^{Ca}	0.91 ± 0.89 ^{Ca}	0.80 ± 0.64 ^{Ca}
	Posterior	0.22 ± 0.40 ^{Aa}	0.29 ± 0.57 ^{Aa}	0.48 ± 0.52 ^{Ba}	0.65 ± 0.70 ^{Ca}	0.87 ± 0.76 ^{Da}	0.95 ± 0.81 ^{Da}	1.03 ± 0.68 ^{Da}
Gender	Male	0.12 ± 0.36 ^{Aa}	0.15 ± 0.41 ^{Aa}	0.29 ± 0.54 ^{Ba}	0.52 ± 0.68 ^{Ca}	0.74 ± 0.66 ^{Da}	0.83 ± 0.71 ^{Da}	0.85 ± 0.64 ^{Da}
	Female	0.27 ± 0.49 ^{Aa}	0.39 ± 0.65 ^{Ab}	0.59 ± 0.61 ^{Bb}	0.82 ± 0.69 ^{Cb}	1.05 ± 0.82 ^{Da}	1.08 ± 0.91 ^{Da}	1.21 ± 0.68 ^{Da}
Endodontic adjacent teeth	No	0.19 ± 0.38 ^{Aa}	0.25 ± 0.56 ^{Aa}	0.42 ± 0.61 ^{Ba}	0.56 ± 0.69 ^{Ba}	0.82 ± 0.73 ^{Ca}	0.70 ± 0.68 ^{Ba}	0.88 ± 0.68 ^{Ba}
	Yes	0.23 ± 0.39 ^{Aa}	0.28 ± 0.51 ^{Aa}	0.49 ± 0.56 ^{Ba}	0.76 ± 0.68 ^{Ca}	0.95 ± 0.65 ^{Da}	1.16 ± 0.69 ^{Eb}	1.17 ± 0.68 ^{Ea}
Smoke	Smokers	0.11 ± 0.42 ^{Aa}	0.12 ± 0.52 ^{Aa}	0.19 ± 0.56 ^{Aa}	0.57 ± 0.75 ^{Ba}	0.81 ± 0.86 ^{Ca}	0.82 ± 0.96 ^{Ca}	0.84 ± 0.67 ^{Ca}
	Non smokers	0.22 ± 0.41 ^{Aa}	0.27 ± 0.53 ^{Aa}	0.46 ± 0.52 ^{Ba}	0.69 ± 0.35 ^{Ba}	0.88 ± 0.75 ^{Ca}	0.97 ± 0.89 ^{Ca}	1.07 ± 0.65 ^{Ca}
Implant placement	Immediate	0.09 ± 0.30 ^{Aa}	0.14 ± 0.35 ^{Aa}	0.23 ± 0.27 ^{Ba}	0.61 ± 0.59 ^{Ca}	0.80 ± 0.62 ^{Ca}	0.73 ± 1.07 ^{Ca}	0.76 ± 0.58 ^{Ca}
	Early	0.01 ± 0.18 ^{Aa}	0.03 ± 0.29 ^{Aa}	0.10 ± 0.47 ^{Aa}	0.22 ± 0.66 ^{Bb}	0.53 ± 0.67 ^{Ba}	0.66 ± 0.71 ^{Bab}	0.73 ± 0.57 ^{Ba}
Delayed	0.29 ± 0.45 ^{Ab}	0.39 ± 0.62 ^{Ab}	0.62 ± 0.66 ^{Bb}	0.82 ± 0.68 ^{Ca}	1.02 ± 0.76 ^{Da}	1.16 ± 0.81 ^{Db}	1.22 ± 0.69 ^{Db}	
<i>Intra-operative parameter</i>								
Implant Diameter	3.8	0.27 ± 0.30 ^{Aa}	0.34 ± 0.33 ^{Aa}	0.43 ± 0.27 ^{ABa}	0.60 ± 0.69 ^{Ba}	0.76 ± 0.70 ^{Ba}	0.99 ± 0.70 ^{Ca}	0.95 ± 0.67 ^{Ca}
	4.25	0.22 ± 0.19 ^{Aa}	0.33 ± 0.29 ^{Aa}	0.56 ± 0.47 ^{Ba}	0.76 ± 0.64 ^{Ba}	1.07 ± 0.72 ^{Ca}	0.96 ± 0.72 ^{Ca}	1.08 ± 0.67 ^{Ca}
	5.0	0.11 ± 0.41 ^{Aa}	0.08 ± 0.62 ^{Aa}	0.24 ± 0.64 ^{Ba}	0.57 ± 0.84 ^{Ca}	0.75 ± 1.01 ^{Da}	0.83 ± 1.01 ^{Da}	0.91 ± 0.65 ^{Da}
<i>Post-operative parameter</i>								
Gingival thickness	Thin	0.19 ± 0.34 ^{Aa}	0.27 ± 0.39 ^{Aa}	0.53 ± 0.58 ^{Ba}	0.75 ± 0.66 ^{Ba}	0.97 ± 0.77 ^{Ba}	1.06 ± 0.82 ^{Ca}	1.16 ± 0.72 ^{Ca}
	Thick	0.25 ± 0.48 ^{Aa}	0.31 ± 0.75 ^{Aa}	0.38 ± 0.64 ^{ABa}	0.53 ± 0.75 ^{Ba}	0.78 ± 0.79 ^{Ba}	0.81 ± 0.81 ^{Ba}	0.80 ± 0.65 ^{Ba}
Total	128	0.21 ± 0.38 ^A	0.28 ± 0.56 ^A	0.47 ± 0.57 ^B	0.67 ± 0.78 ^C	0.89 ± 0.81 ^D	0.95 ± 0.85 ^D	0.99 ± 0.68 ^D

Table 2a. Multilevel-mixed logistic regression exploring factor associated to MBL at 36 months

Groups	Coefficient	Robust SE	95% CI	p-value
<i>Pre-operative parameters</i>				
Gender	0.204	0.144	(-0.079; 0.487)	0.158
Location	0.373	0.159	(0.061; 0.685)	0.019
Smoke	0.252	0.146	(-0.034; 0.137)	0.084
Position	-0.276	0.169	(-0.609; 0.056)	0.104
Endodontically treated adjacent teeth	0.501	0.143	(0.219; 0.780)	<0.0001
Implant placement group	0.181	0.089	(0.005; 0.357)	0.044
<i>Intra-operative parameters</i>				
Implant Diameter	0.052	0.118	(-0.179; 0.283)	0.659
<i>Post-operative parameters</i>				
Gingival biotype	-0.128	0.135	(-0.394; 0.137)	0.343

Table 2b Multiple linear regression after stepwise selection

Groups	Coefficient	Robust SE	95% CI	p-value
Implant placement group	0.168	0.083	(0.003; 0.337)	0.045
Location	0.335	0.155	(0.031; 0.639)	0.031
Endodontically treated adjacent teeth	-0.57	0.335	(-1.228; 0.859)	0.001

671

672

673

674

675

676

Table 3a. Multilevel-mixed logistic regression exploring factor associated to MBL at 48 months

Groups	Coefficient	Robust SE	95% CI	p-value
<i>Pre-operative parameters</i>				
Gender	0.226	0.190	(-0.146; 0.598)	0.234
Location	0.138	0.237	(-0.326; 0.604)	0.559
Smoke	0.252	0.146	(-0.034; 0.137)	0.084
Position	-0.186	0.308	(-0.792; 0.419)	0.546
Endodontically treated adjacent teeth	0.329	0.172	(-0.009; 0.668)	0.056
Implant placement group	0.180	0.150	(-0.113; 0.475)	0.229
<i>Intra-operative parameters</i>				
Implant Diameter	0.075	0.121	(-0.161; 0.31)	0.532
<i>Post-operative parameters</i>				
Gingival biotype	-0.224	0.186	(-0.254; 0.432)	0.227

Table 3b Multiple linear regression after stepwise selection

Groups	Coefficient	Robust SE	95% CI	p-value
Implant placement group	0.231	0.998	(0.362; 0.427)	0.020
Thickness	-0.291	0.280	(0.334; 1.432)	0.076