

Splenic Marginal Zone Lymphoma in 5 Dogs (2001–2008)

D. Stefanello*, P. Valenti*, E. Zini, S. Comazzi, M.E. Gelain, P. Roccabianca, G. Avallone, M. Caniatti, and L. Marconato

Background: Splenic marginal zone lymphomas (MZL) in dogs arise from the marginal zone of B-cell follicles and can progress slowly.

Objectives: To describe clinical features, treatment, and outcome of dogs with splenic MZL.

Animals: Five dogs with naturally occurring MZL.

Methods: Clinical, laboratory, and follow-up data were retrospectively reviewed. Diagnosis was based on clinical, histopathological, and immunophenotypic features.

Results: All dogs had stage IV disease; among them, 2 were symptomatic (substage “b”) because of splenic rupture. Four dogs underwent splenectomy and adjuvant doxorubicin, and 1 dog underwent surgery only. Three out of the 4 dogs treated with surgery and chemotherapy died of causes unrelated to lymphoma, after 760, 939, and 1,825 days, whereas the remaining dog was alive and in complete remission after 445 days. The dog not receiving any adjuvant treatment had recurrence of the tumor after 180 days.

Conclusions and Clinical Importance: Splenic MZL appears indolent and can benefit from splenectomy, with or without systemic chemotherapy.

Key words: Canine; Indolent lymphoma; Spleen.

The marginal zone is an anatomically distinct B-cell compartment surrounding the lymphocytic corona of the mantle zone in lymph node(s) (LNs), spleen, and mucosa-associated lymphoid tissues (MALT).¹ Lymphomas arising from this particular location within lymphoid follicles are named marginal zone lymphoma (MZL).

The World Health Organization (WHO) histological classification (2008) further divided human MZL into 3 subtypes, including that of MALT, spleen, and LNs²; the clinical course is different for each of them. The WHO classification of hematopoietic and lymphoid tumors of domestic animals has also divided them into subtypes.^{1,3,4} Because of the limited number of reported splenic MZL cases, a precise recommendation for therapy is not yet available. The goal of this report was to describe clinical features, treatment, and outcome of dogs with splenic MZL.

From the Department of Veterinary Clinical Sciences, School of Veterinary Medicine, University of Milan, Milan, Italy (Stefanello, Valenti); the Clinic for Small Animal Internal Medicine, Vetsuisse Faculty, University of Zürich, Zürich, Switzerland (Zini); the Department of Animal Pathology, Hygiene and Public Health, School of Veterinary Medicine, University of Milan, Milan, Italy (Comazzi, Gelain, Roccabianca, Avallone, Caniatti); and the Clinica Veterinaria L'Arca, Naples, Italy (Marconato). Dr Marconato and Dr Valenti are presently affiliated with the Animal Oncology and Imaging Center, Rothusstrasse 2,6331, Hünenberg, Switzerland. Findings of this study were presented in part at the Annual ESVONC Congress, Turin, Italy, 2010.

**Contributed equally to the work.*

Corresponding author: L. Marconato, DVM, DECVIM-CA (Oncology), Animal Oncology and Imaging Center, Rothusstrasse 2, CH-6331, Hünenberg, Switzerland; e-mail: marconato@aoicenter.ch.

Submitted September 21, 2009; Revised August 26, 2010; Accepted September 28, 2010.

Copyright © 2010 by the American College of Veterinary Internal Medicine

10.1111/j.1939-1676.2010.0639.x

Abbreviations:

BM	bone marrow
CR	complete remission
LN(s)	lymph node(s)
MALT	mucosa-associated lymphoid tissues
MMC	medium macronucleated cell
MZL	marginal zone lymphoma
PD	progressive disease
PR	partial remission
WHO	World Health Organization

Materials and Methods

Criteria for Selection of Cases

Medical records were reviewed to identify dogs with a histological diagnosis of MZL presented to the authors' institutions between 2001 and 2008. To be enrolled in the study, a complete staging work-up had to be available, including signalment, history, presence or absence of clinical signs, hematological profile, calcemia, thoracic radiographs, abdominal ultrasound, cytology and immunophenotype of enlarged LN(s), spleen or liver, cytological and immunophenotypic bone marrow (BM) evaluation, with or without histopathological examination of the involved tissue(s). Clonality assessment was performed on spleen samples to confirm the neoplastic origin of the disease.

Data pertaining to number and type of therapies given, response, and outcome were retrieved.

Morphologic Features and Immunophenotype

Histological slides, including sections used for immunophenotyping, were reviewed to confirm the diagnosis. The diagnosis was made according to WHO histological classification.^{3–5} Immunophenotyping had to demonstrate the B-cell nature of neoplastic lymphocytes.

Polymerase chain reaction (PCR) for antigen receptor rearrangement (PARR) was performed on formalin fixed-paraffin embedded samples. DNA was isolated with a commercially available kit in accordance with the manufacturer's protocol.³ Nucleic acid was spectrophotometrically measured with an ND-100 Spectrophotometer^b

and PCR for GAPDH sequences was performed to evaluate the presence of amplifiable DNA. Amplification of immunoglobulin sequence was performed as already described.⁶

Treatment and Response Assessment

Treatment was provided by the attending clinician and was not standardized. Dogs were treated according to disease stage and location with therapeutic options being available at the time of diagnosis.

Outcome was recorded for each included case. Complete remission (CR) was defined as no clinical evidence of lymphoma. Partial remission (PR) was defined as 50% or greater decrease in one dimension of measurable tumor. Stable disease was defined as less than a 50% decrease in 1 dimension but no more than a 10% increase in any dimension of all measurable tumors. Progressive disease (PD) was defined as a 10% or more increase in any dimension of measurable tumor. Relapse was defined as clinical reappearance and cytological evidence of lymphoma in any anatomical site in dogs that have had CR, whereas relapse for animals with PR was defined as progression. Responses lasting <21 days were considered as PD.

To evaluate response, reevaluation was conducted at the end of the adopted therapy, and monthly thereafter until relapse. All enrolled dogs were monitored by the same clinician.

Results

Dogs

Nine client-owned dogs with splenic MZL were identified as potential cases for inclusion in the study. However, among them, only 5 had an available histopathological diagnosis of MZL and were enrolled. The other 4 had a cytological diagnosis of medium macronucleated cell (MMC) and were therefore not included in the study.

Of the 5 dogs enrolled, 2 were pure-bred, 3 were mixed-bred. There were 4 males (3 intact, 1 castrated) and 1 spayed female. Median age was 8 years (range, 7–10 years) and median weight was 10 kg (range, 8.0–29.0 kg). All dogs had stage IV disease. Two dogs had signs related to hemoabdomen (“b” substage).

All dogs were treatment-naïve at time of diagnosis.

Anemia (hematocrit <35%) was observed in 2 dogs and none was hypercalcemic ($\text{Ca}^{2+} > 12 \text{ mg/dL}$). Two dogs had hemoabdomen because of splenic rupture. An abdominal mass was palpated during routine examination in the remaining 3 dogs. In all dogs a focal, well demarcated, hypoechoic mass was delineated in the spleen on ultrasonographic examination. In all dogs, both cytology and histology were available. Impression smears of the spleen were obtained after splenectomy, and cytology was consistent with a MMC diagnosis in all of them. Histological samples were diagnosed as MZL lymphomas, being characterized by focally extensive nodular splenic lesions often surrounded by hemorrhage or areas of severe extramedullary hematopoiesis (Figs 1–4). Splenic neoplastic nodules examined in early cases were composed of the characteristic lighter stained broad and continuous cuff of cells around small foci of darkly stained residual small cells of mantle cell cuff with collapsed germinal centers. In more advanced cases, the multinodular pattern persisted but mantle cells were lost

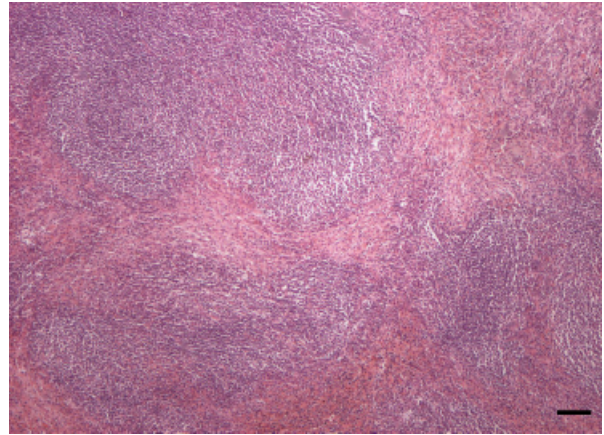


Fig 1. Histology of the spleen. Effacement of normal architecture by coalescing nodules composed of a prevalence of marginal cells and characterized by loss of mantle cells. Hematoxylin and eosin, bar = 170 μm .

and nodules tended to coalesce. Neoplastic cells were monomorphic, with variably evident cell boundaries, an abundant lightly eosinophilic cytoplasm, and round, 10–14 μm nuclei with 1 distinct nucleolus. Mitoses were rare to absent in all cases. Cells expressed consistently CD79-alpha and CD20 and were CD3-epsilon negative.

B-cell clonality was detected in 3 splenic cases. In 2 cases, formalin-fixed paraffin embedded tissue yielded very low DNA amounts, thereby precluding the possibility to assess clonality on them.

Treatment and Outcome

Among the 5 dogs, 4 underwent splenectomy and received chemotherapy (doxorubicin as single agent) thereafter, and 1 was splenectomized with no further treatment. Three out of the 4 dogs treated with surgery and adjuvant chemotherapy died of causes unrelated to lymphoma, after 760, 939, and 1,825 days, whereas the

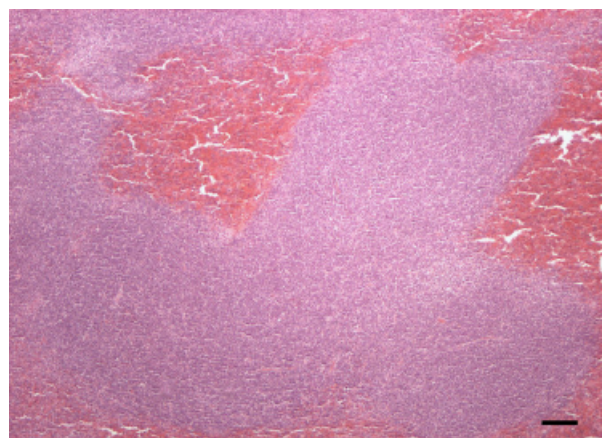


Fig 2. Histology of the spleen. Coalescing areas of neoplastic cells with abundant eosinophilic cytoplasm and complete loss of normal splenic architecture, bar = 160 μm .

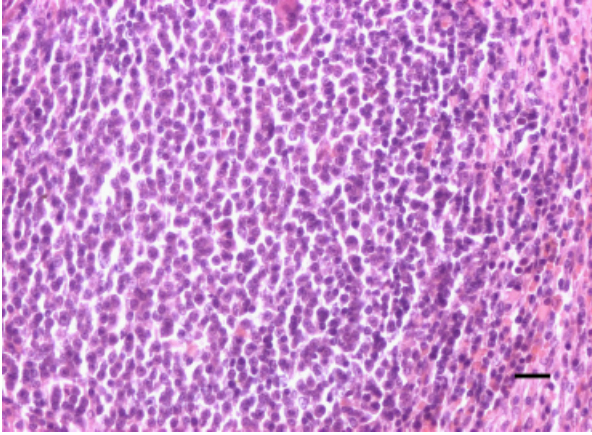


Fig 3. Histology of the spleen. High magnification of a nodule of Figure 1 characterized by compression of residual splenic parenchyma by marginal zone expansion, bar = 45 μ m.

remaining dog was alive and in CR at the end of the study, after 445 days.

The dog not receiving any adjuvant treatment experienced tumor relapse after 180 days and was euthanized. Relapse occurred in the peripheral LN(s) and was confirmed by means of cytology.

Discussion

MZL is a well-known clinicopathological entity in human medicine and clinical outcome mostly depends on anatomical site of involvement.⁷ In veterinary medicine, the recognition of MZL as a distinct disease has been recent,^{1,3} therefore data on natural history and treatment response have been limited. Our goal was to describe clinical characteristics, treatment, and outcome of dogs with splenic MZL, to understand whether they behave like the indolent ones, as previously stated,³ or should be considered as clinically aggressive. By definition, indo-

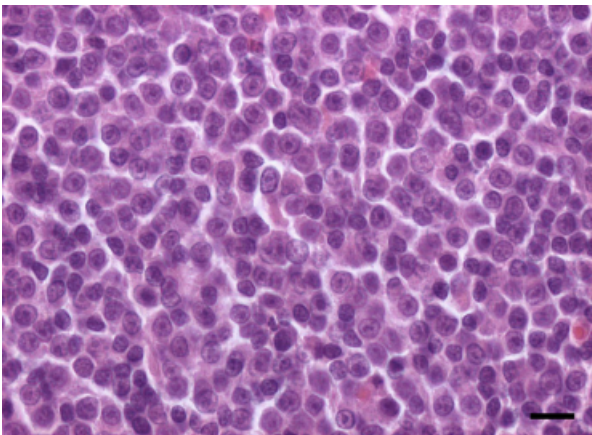


Fig 4. Histology of the spleen. Substitution of a normal follicle by a monomorphic population of cells with central round nucleus characterized by chromatin peripheralization and evidence of a central prominent nucleolus, bar = 25 μ m.

lent lymphomas grow slowly or remain stable for long periods of time, and are histologically of low to intermediate grade. Indolent lymphomas are traditionally moderately to fairly chemo- and radio-resistant; therefore a conservative treatment is usually suggested, meaning metronomic strategy instead of a dose-intense approach (aiming at administering the chemotherapeutic drugs as high as possible), to keep quality of life and avoid unnecessary toxicity. If lymphoma is asymptomatic, deferring treatment may represent an option.

MZL is the lymphoma type most frequently arising in the spleen in both humans and dogs. Splenic MZL is characterized by uniform involvement of follicular areas, leading to generalized splenomegaly in human patients,^{8,9} which usually becomes symptomatic if massive or if associated with peripheral cytopenias. BM and blood are frequently involved (in up to 90% of cases) without worsening prognosis.¹⁰ Because of the relatively benign clinical course, treatment is required in selected cases only, such as those exhibiting symptomatic splenomegaly and/or cytopenia, with splenectomy being the treatment of choice.^{10,11} Follow-up chemotherapy (mainly consisting of alkylating agents or purine analogues) can play a role in the presence of poor prognostic factors, positive staging work-up, “b” substage and/or cytologic presence of large cells (>20%).¹²

In our series of dogs, the hallmark of splenic MZL was a focal hypoechoic mass, as previously described,³ which only became symptomatic in case of rupture, leading to secondary hemoabdomen. Early in the disease, splenic MZL was identified accidentally during palpation. This is in contrast with high-grade lymphomas, in which generalized splenomegaly, rather than an isolated mass, is usually observed.¹³ Unlike human patients, in which BM involvement is very common, in this series none of the dogs had BM infiltration at presentation. Based on our results, splenic MZL may have an indolent biologic behavior, and this is in agreement with a previous study.³ Diagnosis is usually made when dogs become symptomatic, as in case of splenic rupture, or by abdominal ultrasound performed for other reasons. Here, treatment of splenic MZL varied: 4 dogs underwent splenectomy and adjuvant chemotherapy, whereas 1 dog underwent surgery only. The 3 longest survivals were recorded in dogs treated by means of surgery and adjuvant chemotherapy, possibly suggesting a benefit for the combined therapy. Lymphoma cases are usually treated pharmacologically in dogs, and the role of splenectomy has been limited to palliate clinical signs related to hypersplenism, remove spleens at risk for rupture or eliminate the focus of residual disease in dogs having successfully responded to chemotherapy in other sites.¹⁴ Based on our results, we hypothesize that surgery may also play an important role in the management of splenic MZL, possibly improving outcome. Whether adjuvant chemotherapy is necessary in an adjuvant (postsurgical) setting has not been evaluated before. Our findings suggest that systemic monotherapy can be useful in preventing relapse, possibly eradicating minimal residual disease. However, 3 dogs with splenic MZL were alive between 7 and 19 months after splenectomy only.³ This finding has important clinical

implication, as conservative (surgical) treatment could lead to prolonged survival, thereby outlining the importance of obtaining a definitive histological diagnosis before discussing prognosis with the owners. Indeed, the general diagnosis of “lymphoma” is largely inaccurate, as different types of lymphoma have different biological behavior and harbor different prognosis, not necessarily being poor, as demonstrated by this series of dogs.

The detection of clonality by means of molecular methods may further improve the possibility to achieve a definitive diagnosis. In our study, 3 out of 5 splenic samples showed IgH clonal rearrangement, while on 2 cases no PCR products were detected. The lack of visible immunoglobulin rearrangement, however, could be interpreted as a false negative result. Indeed, as already reported,¹⁵ there are several causes of PARR false negative results, such as exhibition of V- or J-region gene segments not being amplified by the primers used and inadequate tissue quality for PCR analysis. This could explain the negative results obtained in 2 samples, in which the lymphoid neoplasm was histopathologically confirmed. The nucleic acid extracts from formalin-fixed tissues are not always suitable for amplification, being attributable to scarce or degraded DNA, or presence of remnants of formalin or xylene, which contain inhibitors of extraction procedures or amplification reaction. Thus, as already reported,³ the accurate interpretation of clonality results requires histological tissue examination as well as immunophenotyping.

This study has several limitations, including low number of cases and retrospective nature, which precluded to have a homogeneous population in terms of treatment. Furthermore, since histopathological evaluation was an inclusion criteria, cases for which only cytology was available were excluded.

In people, MZL arising from different anatomic sites have different biologic behavior, with nodal lymphomas having a more aggressive clinical course than splenic ones, thereby requiring a more aggressive therapeutic strategy.¹⁶ Future works should be aimed at evaluating if the same holds true for dogs.

In conclusion, splenic MZL seems to be an indolent disease and may benefit from splenectomy, possibly followed by systemic chemotherapy. Future clinical trials should focus on the prognostic role of adjuvant chemotherapy. Best treatment options for this poorly described disease remain to be defined in dogs.

References

1. Valli VE. Marginal zone and MALT lymphoma. In: Valli VE, ed. *Veterinary Comparative Hematopathology*. Ames, IA: Blackwell Publishing; 2007:168–189.
2. Fournel-Fleury C, Magnol JP, Bricaire P, et al. Cytohistological and immunological classification of canine malignant lymphomas: Comparison with human non-Hodgkin's lymphomas. *J Comp Pathol* 1997;117:35–59.
3. Swerdlow SH, Campo E, Harris NL, et al. *WHO Classification of Tumours of Haematopoietic and Lymphoid Tissues*. Lyon, France: IARC Press; 2008.
4. Valli VE, Vernau W, de Lorimier LP, et al. Canine indolent nodular lymphoma. *Vet Pathol* 2006;43:241–256.
5. Valli VE, Jacobs RM, Parodi AL, et al. *WHO Histological Classification of Hematopoietic Tumors of Domestic Animals, Vol VIII, 2nd ed.* Washington, DC: Armed Forces Institute of Pathology; 2002.
6. Burnett RC, Vernau W, Modiano JF, et al. Diagnosis of canine lymphoid neoplasia using clonal rearrangements of antigen receptor genes. *Vet Pathol* 2003;40:32–41.
7. Berger F, Felman P, Thieblemont C, et al. Non-MALT marginal zone B-cell lymphomas: A description of clinical presentation and outcome in 124 patients. *Blood* 2000;15:1950–1956.
8. Troussard X, Valensi F, Duchayne E, et al. Splenic lymphoma with villous lymphocytes: Clinical presentation, biology and prognostic factors in a series of 100 patients. *Groupe francais d'hematologie cellulaire (GFHC). Br J Haematol* 1996;93:731–736.
9. Thieblemont C, Felman P, Callet-Bauchu E, et al. Splenic marginal-zone lymphoma: A distinct clinical and pathological entity. *Lancet Oncol* 2003;4:95–103.
10. Thieblemont C, Felman P, Berger F, et al. Treatment of splenic marginal zone B-cell lymphoma: An analysis of 81 patients. *Clin Lymphoma* 2002;3:41–47.
11. Mulligan SP, Matutes E, Dearden C, Catovsky D. Splenic lymphoma with villous lymphocytes. Natural history and response to therapy in 50 cases. *Br J Haematol* 1991;78:206–209.
12. Lefrère F, Hermine O, Belanger C, et al. Fludarabine: An effective treatment in patients with splenic lymphoma with villous lymphocytes. *Leukemia* 2000;14:573–575.
13. Wrigley RH, Konde LJ, Park RD, Lebel JL. Ultrasonographic features of splenic lymphosarcoma in dogs: 12 cases (1980–1986). *J Am Vet Med Assoc* 1988;193:1565–1568.
14. Vail DM, Young KM. Canine lymphoma and lymphoid leukemia. In: Withrow SJ, MacEwen EG, eds. *Small Animal Clinical Oncology, 4th ed.* Philadelphia, PA: WB Saunders Co; 2007:699–733.
15. Avery PR, Avery AC. Molecular methods to distinguish reactive and neoplastic lymphocyte expansions and their importance in transitional neoplastic states. *Vet Clin Pathol* 2004;33:196–207.
16. Zucca E, Bertoni F, Stathis A, Cavalli F. Marginal zone lymphomas. *Hematol Oncol Clin North Am* 2008;22:883–901.

Footnotes

^a RecoverAll Total Nucleic Acid Isolation Kit, Ambion, Austin, TX

^b NanoDrop Technologies Inc, Wilmington, DE
