

Research Article

In Vivo Challenge Trials with Dietary Antiparasitics Reveal New Insights into the Practical Use of Fenbendazole against *Sparicotyle chrysophrii* (Monogenea) Infection in *Sparus aurata* (Teleostei)

Paolo Merella ,¹ Francisco Esteban Montero ,² Luca Parma ,³ Lorenzo Morsiani,³ Roberto Cerri ,⁴ Andrea Di Biase ,⁴ Marta Polinas ,¹ Claudio Murgia ,¹ Elisabetta Antuofermo ,¹ and Giovanni Garippa ¹

¹Department of Veterinary Medicine, University of Sassari, Via Vienna 2, 07100, Sassari, Italy

²Cavanilles Institute for Biodiversity and Evolutionary Biology, Science Park, University of Valencia, P.O. Box 22 085, 46071, Valencia, Spain

³Department of Veterinary Medical Sciences, University of Bologna, Via Tolara Di Sopra 50, 40064, Ozzano Emilia, Italy

⁴Veronesi Holding S.p.A., Via Valpantena 18/G, 37142 Quinto di Valpantena, Verona, Italy

Correspondence should be addressed to Paolo Merella; paolomerella@uniss.it

Received 27 October 2023; Accepted 6 May 2024

Academic Editor: Hamed Ghafarifarsani

Copyright © 2024 Paolo Merella et al. This is an open access article distributed under the Creative Commons Attribution License, which permits unrestricted use, distribution, and reproduction in any medium, provided the original work is properly cited.

The microcotylid *Sparicotyle chrysophrii* is one of the most harmful parasites for the aquaculture of the gilthead seabream *Sparus aurata*, for which effective treatments are needed. The efficacy of dietary praziquantel (PZQ, 30–50 mg kg body weight⁻¹ day⁻¹), emamectin benzoate (EMB, 0.015–0.050 mg kg BW⁻¹ day⁻¹), and fenbendazole (FBZ, 40–75 mg kg BW⁻¹ day⁻¹) against *S. chrysophrii* on gilthead seabream was tested in four different *in vivo* challenge trials. Specimens of gilthead seabream naturally infected with *S. chrysophrii* were maintained in three separate recirculating aquaculture systems of 142 L (1 control vs. 2 treated). Fish were fed (ration 1.2% BW day⁻¹) 5 days a week for 4 weeks, alternating weeks with medicated and control feed. On days 0, 14, and 28, samples of 7–9 fish per group were collected and the gills were examined for *S. chrysophrii*. The gills of hosts treated with EMB and FBZ were evaluated by histopathology. The trials showed that in-feed PZQ has low palatability, causing rejection which did not allow its efficacy to be adequately investigated. While dietary EMB was associated with adverse effects, such as gill de-epithelialisation and necrosis, with no demonstrated efficacy against *S. chrysophrii*. On the other hand, all the fish treated with FBZ lost all parasites, showing 100% efficacy and also suggesting a preventive/repellent action against the monogenean. In conclusion, the present study provides indications for the use of dietary FBZ as a medical device for the treatment/prophylaxis of sparcotylosis in aquaculture.

1. Introduction

The monogenean microcotylid *Sparicotyle chrysophrii* (Van Beneden & Hesse, 1863) Mamaev, 1984 is a gill parasite that poses a significant threat to gilthead seabream *Sparus aurata* Linnaeus, 1758 (Osteichthyes, Sparidae) farming in Mediterranean cages [1, 2, 3, 4]. A common method to treat monogeneans is formalin bath [5]. However, this approach has several drawbacks, such as risks to the health of workers,

adverse environmental impact, and increased stress for the fish [6, 7, 8]. On the other hand, the dietary application of antiparasitic drugs has numerous advantages in addressing problems associated with formalin [4, 5, 9].

Among the compounds used for in-feed treatments of monogeneans, praziquantel (PZQ), a synthetic pyrazinoisoquinoline, is often described as one of the most promising compounds against platyhelminths in aquaculture [10]. Several studies have shown its efficacy against monogeneans by

TABLE 1: Compounds, drugs, and doses used to prepare the experimental medicated feeds (feeding ration 1.2% body weight day⁻¹).

Compound	Drug	Treatment	mg kg BW ⁻¹ d ⁻¹	mg comp kg feed ⁻¹
Praziquantel	Fluke-Solve ¹	PZQ-L	30	2.5000
		PZQ-H	50	4.1667
Emamectin benzoate	Lice-Solve ²	EMB-LL	0.015	0.00125
		EMB-L	0.030	0.00250
		EMB-H	0.050	0.00420
Fenbendazole	Panacur Forte ³	FBZ-L	40	3.3333
		FBZ-H	75	6.2500

¹Fluke-SolveTM 50 g (Vetark, Winchester, SO23 9SQ, United Kingdom; Candioli Pharma srl, Beinasco, TO, Italy), praziquantel 50%. ²Lice-SolveTM 10 g (Vetark, Winchester, United Kingdom; Candioli Pharma srl, Beinasco, TO, Italy), emamectin benzoate 1.4%. ³Panacur[®] Forte tablets 500 mg (MSD Animal Health srl, Segrate, MI, Italy; Intervet International BV, Boxmeer—Netherlands), fenbendazole 500 mg, excipients up to 780 mg (64.1%). Abbreviations: BW, body weight; LL, extra low; L, low; H, high.

oral administration on diverse fish groups, e.g., the puffer *Takifugu rubripes* (Temminck & Schlegel, 1850) infected with *Heterobothrium okamotoi* Ogawa, 1991 [11], the amberjacks *Seriola* spp. infected with *Benedenia seriola* (Yamaguti, 1934) Meserve, 1938, *Neobenedeniagirellae* (Hargis, 1955) Yamaguti, 1963 and *Zeuxapta seriola* (Meserve, 1938) Price, 1962 [9, 12, 13, 14], and the silver perch *Bidyanus bidyanus* (Mitchell, 1838) infected with *Lepidotrema bidyana* Murray, 1931 [7]. Dietary inclusion of PZQ against *S. chrysophrii* was tested by Sitjà-Bobadilla et al. [2] and Merella et al. [15] without significant results, due to the reduced consumption of PZQ-medicated feed, consequently reducing the impact for the administration of subtherapeutic doses. This issue was apparently due to the low PZQ palatability, as reported by several authors (i.e., Williams et al. [9]; Forwood et al. [7]; Partridge et al. (2014) [13]; and Norbury et al. [10]). Recently, Rigos et al. [16] have successfully administered dietary PZQ to the gilthead seabream, thanks to the incorporation of krill into the feed to induce a masking effect, achieving significant results for the control of *S. chrysophrii* on *S. aurata*.

The benzimidazoles fenbendazole (FBZ) and febantel are commonly used in aquaculture for monogeneans, cestodes, and nematodes [17, 18]. Forwood et al. [7] and Gupta et al. [8] used fenbendazole on *B. bidyanus* and *Labeo rohita* (Hamilton, 1822) infected with *L. bidyana* and *Dactylogyrus* sp., respectively; Ogawa [19] and Kimura et al. [20] successfully experimented in-feed febantel on *T. rubripes* infected with *H. okamotoi*. Recently, Merella et al. [15] suggested dietary FBZ as effective against *S. chrysophrii* on *S. aurata*.

Avermectins are mainly used in aquaculture to control copepod infections in farmed salmon by oral administration of emamectin benzoate (EMB) [21]. These compounds are often described as potentially effective against monogeneans (e.g., [22, 23]), but according to Buchmann and Bjerregaard [24], they act primarily on the GABA-system and are not expected to have efficacy on platyhelminths. Despite this, avermectins are sometimes prescribed off-label for the treatment of sparcotylosis (Merella P., pers. obs.). In this context, it is important to investigate the efficacy of these drugs against monogeneans, to reconsider their possible use or definitively demonstrate their ineffectiveness.

This study aims to evaluate the efficacy of different dietary applications of PZQ, FBZ, and EMB against *S. chrysophrii*,

through *in vivo* challenge trials on naturally infected hosts. Possible findings related to EMB and FBZ treatments were assessed by histopathological analysis of the gills. The changes in the population structure of the parasite were evaluated in relation to the different treatments.

2. Materials and Methods

2.1. Experimental Diets. Three compounds (PZQ, EMB, and FBZ) were chosen for the trials and were administered at two different doses (low, L; high, H), if necessary a further extra low (LL) dose was considered, based on the literature [2, 7, 8, 9, 10, 11, 12, 13, 14, 15, 19, 20, 21]. A commercial extruded feed for the gilthead sea bream (“Vita 2,” 50% protein, 20% lipid, pellet diameter 2.3–2.6 mm, Veronesi Holding S.p.A., Verona, Italy) was used as reference feed, and it was oil coated without medicaments for the control. The inclusion ratio of the three compounds in the control, necessary to obtain the different doses, was calculated for a feeding ration of 1.2% BW day⁻¹. The amount of commercial drugs to be added to the control feed for the different diets was calculated based on the percentage of compounds in each drug (Table 1 for details on the doses and drugs used).

2.2. Maintenance of Fish and Parasites in Captivity. For the trials, specimens of *S. aurata* already infected with *S. chrysophrii* were maintained in three recirculating aquaculture systems (RAS) of 142 L, with independent and separate water circulation, mechanical/biological filtration, control of temperature (20–22° C), and photoperiod (12:12 hr light/dark). Water quality was maintained at the optimal ranges for the host (salinity 36–37‰; oxygen 7–8 ppm; pH 7.8–8.2; free ammonia, nitrites, and nitrates well below the threshold values). Infected fish were collected at a fish farm in Sardinia and transported alive by a specialised company authorised for fish transportation (Panaque srl, Viterbo).

To maintain the infection of *S. chrysophrii* under experimental conditions and favouring the completion of its biological cycle, entangling and hatching of parasite eggs were improved by placing handcrafted egg collectors into each RAS. The egg collectors, similar to those described by Merella et al. [15], were realised with a thin square nylon mesh (1.4 mm side), supported on a 9 cm square frame, hung on one side, and ballasted on the opposite one (Supplementary 1).

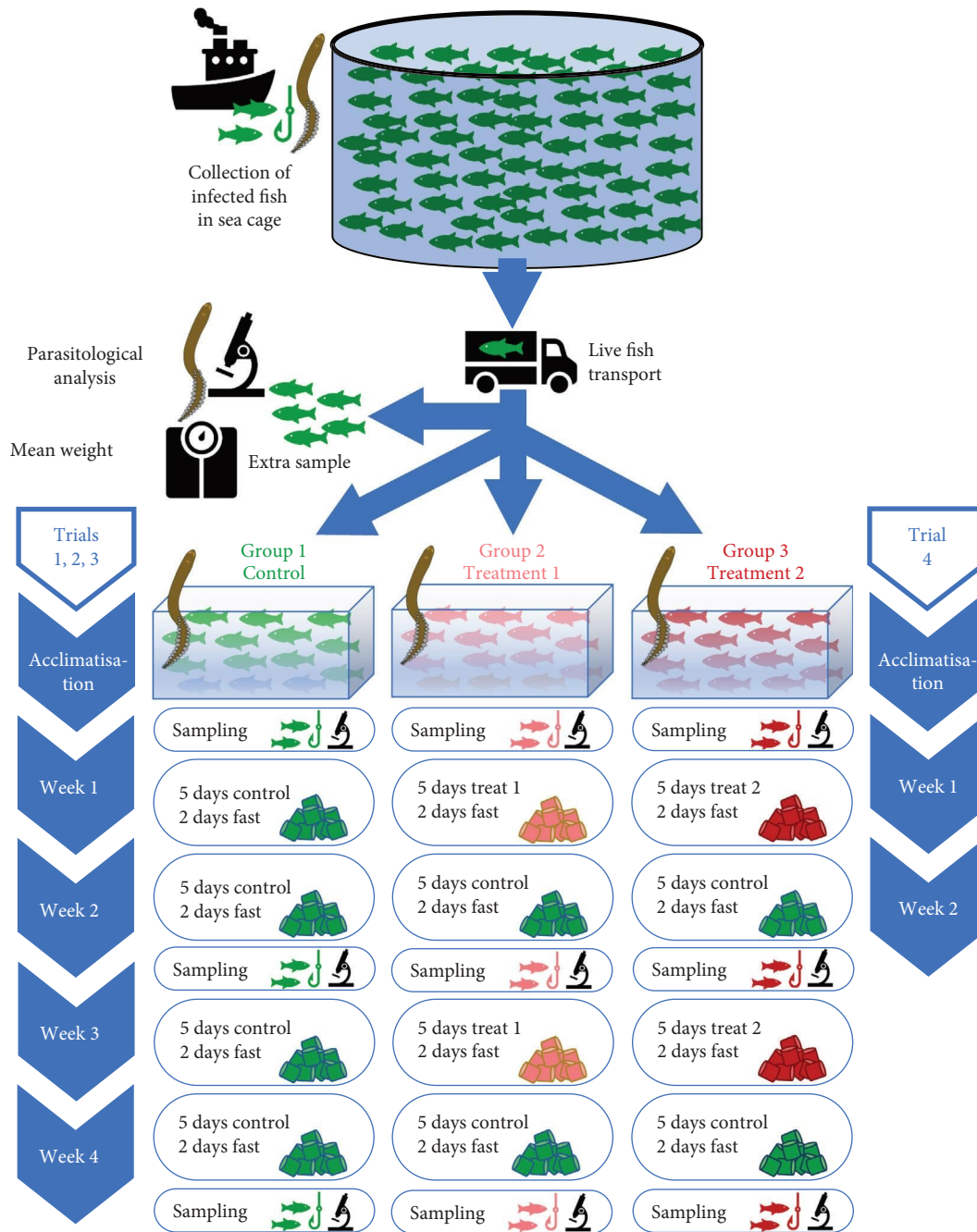


FIGURE 1: Graphical summary of the experimental design for the control (green) and medicated (light and dark red) feeds.

3. Experimental Design and Sampling

The experimental design was approved by the Italian Ministry of Health (Authorisation No. 700/2021-PR of 17/09/2021). For each trial, infected specimens of *S. aurata* were equally divided into the three RAS, forming three homogeneous groups (one control and two treated). The efficacy of the diets with different doses was tested in four different consecutive challenge trials. Based on the chronobiology of the parasite [25], trials lasted 28 days (apart from the last one which was of 14 days), starting 7–10 days after fish

acclimatisation (Figure 1). Trials 1–3 tested two different doses of PZQ, EMB, and FBZ, respectively, and trial 4 tested FBZ-L vs. EMB-LL. The details of the four trials are shown in Table 2. For each trial, an extra sample of 10 specimens was collected at the same farm, to evaluate the infection level of *S. chrysophrii* and the mean host weight at the beginning of the trials. Diets were administered 5 days a week, and the control group was fed throughout the period with control feed. The two treated groups started the first week with medicated feed, followed by 1 week with control, another of treatment to prevent reinfection with free-living larval

TABLE 2: List of the trials performed.

Trial	Date start	Group 1	Group 2	Group 3	N. Fish	W \pm s.d. (g)
1	20/05/2022	Control	PZQ-L	PZQ-H	21	58.8 \pm 12.1
2	07/10/2022	Control	EMB-L	EMB-H	27	40.9 \pm 16.6
3	25/11/2022	Control	FBZ-L	FBZ-H	27	49.0 \pm 8.3
4	06/02/2023	Control	FBZ-L	EMB-LL	18	62.6 \pm 10.4

N. Fish, number of specimens per group; W, mean weight of fish; s.d., standard deviation.

TABLE 3: Percentage of reduction of the mean abundance (MA) and prevalence (P%) of *Sparicotyle chrysophrii* on the gills of *Sparus aurata* supplied by different medicated diets.

Group	Inter-group		Intra-group	
	MA (%)	P (%)	MA (%)	P (%)
Trial 1				
PZQ-L	+4	0	0	0
PZQ-H	+5	0	+5	0
Control	—	—	-1	0
Trial 2				
EMB-L	+69	0	-6	0
EMB-H	+39	0	-74	0
Control	—	—	-255	0
Trial 3				
FBZ-L	+100	+100*	+100*	+100*
FBZ-H	+100	+100*	+100*	+100*
Control	—	—	+26	0
Trial 4				
FBZ-L	+100*	+100*	+100*	+100*
EMB-LL	+15	0	-131*	0
Control	—	—	-114	0

*Significant differences between infection levels.

stages, and a last week with control (Figure 1). Feed was provided by hand; in case uneaten feed was detected, pellets were removed 15 min after administration and quantified to assess the effective ration. On days 0, 14, and 28 after the start of trials, a sample of 7–9 fish per each group was sacrificed by percussive blow to the head, according to the Directive 2010/63/EU [26].

3.1. Parasitological Analysis and Statistics. After sampling, the gills of each host were removed and all holobranchs were examined under a stereomicroscope for *S. chrysophrii*. Prevalence and mean abundance of the parasite were calculated according to Bush et al. [27]. To evaluate differences in the *S. chrysophrii* population structure between the beginning and end of the trials, the developmental stage of the parasite was classified according to its chronobiology [25] into four stages: S_0 , 0–6 clamps; S_1 , 7–18 clamps; S_2 , > 18 clamps; and S_3 , with eggs.

The significance ($p \leq 0.05$) of the differences between the pairwise comparison of prevalence and mean abundance of *S. chrysophrii* was evaluated with the unconditional exact test and the bootstrap two-sample *t*-test, respectively [28]. The quantitative results were statistically analysed with the free online software Quantitative Parasitology web 1.0.15 [28].

The efficacy of treatments was assessed as a percentage reduction (%R) of the mean abundance and prevalence [29]. It was calculated inter-group (a treated group at the end of the trial vs. the control group at the same time) and intra-group (a group at the end of the trial vs. the same group at the start).

3.2. Histopathological Analysis. At the end of trials 2 and 3, three fish from each group were sampled for histopathological analysis; these hosts were not considered for parasite counts. Gills were fixed in 10% buffered formalin for 48 hr, dehydrated in increasing alcohol and xylene in an automatic tissue processor, and paraffin-embedded, and then cut at 3 μ m thickness (RM2245, Leica Biosystems). Slides were stained with haematoxylin and eosin in an automatic multi-stainer (ST5020, Leica Biosystems) and then evaluated under light microscopy (Nikon Eclipse 80i). Histological findings were classified to identify possible features related to treatment exposure. Morphological aspects of parasites in gills were evaluated according to Bruno et al. [30].

4. Results

4.1. Effectiveness of the Treatments and Percentage of Reduction. Table 3 shows the percentage of reduction inter- and intra-group of the mean abundances and prevalences for

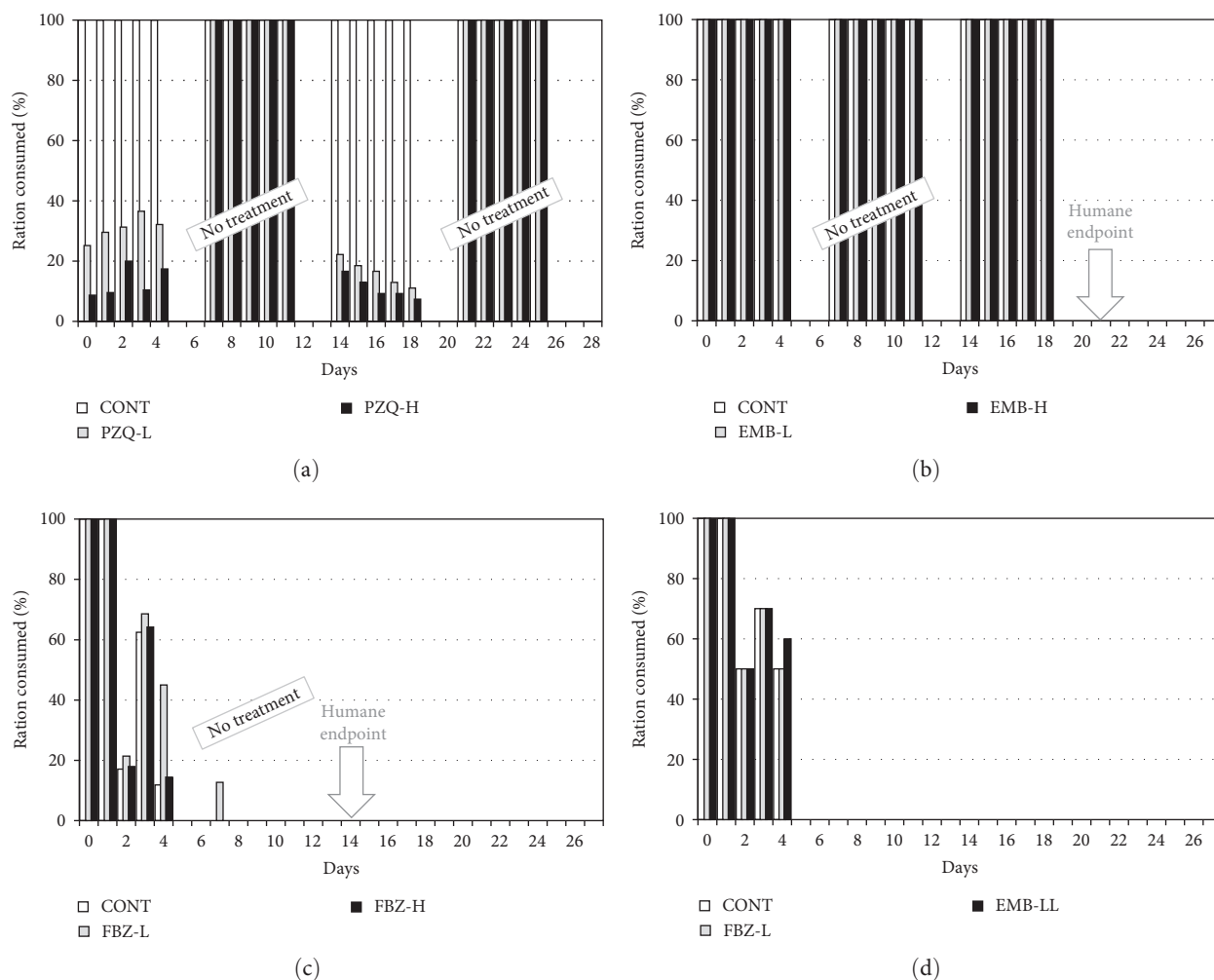


FIGURE 2: Percentage of ration ingested (control and medicated diets) in the four trials (a–d). “No treatment,” control feed administration period also to the treated group; “humane endpoint,” anticipated end of the trial.

each trial, as well as any statistical significance found in the differences between the levels of infection. The results of the four trials carried out are described below.

4.2. *Trial 1: Praziquantel (PZQ)*. This trial was largely influenced by the almost total rejection (64%–93%) of the medicated feed with PZQ at both doses (Figure 2(a)), while the control feed was 100% ingested during the entire experimental cycle, both in control and in the treated groups during the control feed administration periods (Figure 2(a)). No significant differences were found between the levels of infection of the parasite in the three groups during the whole trial. The prevalence was always 100% in all groups, and the mean abundance slightly fluctuated (Figure 3(a)) without significant differences in either inter- or intra-group (Table 3). The %R of the mean abundance was close to zero in both inter- and intra-groups, and the %R of the prevalence was equal to zero in all cases (Table 3).

4.3. *Trial 2: Emamectin Benzoate (EMB)*. The diet with EMB was well-accepted and always 100% consumed as the control one (Figure 2(b)). Unfortunately, 21 days after the start of the

trial, an outbreak of the protist *Cryptocaryon irritans* Brown, 1951 (Ciliophora) caused severe clinical manifestations in fish, leading to the anticipated conclusion of the trial (humane endpoint).

No significant differences were found between the levels of infection of the three groups. The prevalence was always 100% in all groups, and the mean abundance in control varied slightly compared with the treated ones (Figure 3(b)), without significant differences in either inter-group or intra-group (Table 3). The %R of the mean abundance was generally low, and the greater value (69%) was that of EMB-L (Table 3). It is worth noting the negative value of the %R intra-group of EMB-H (-74%). The %R of the prevalence was equal to zero in all cases (Table 3).

Histopathological findings of the gills of three fish from each group, sampled at the end of the trial, were characterised by mild to severe mononuclear inflammatory infiltrate admixed with structures, characterised by an ovoid cell (80–250 μm) with a single basophilic crescent-shape macronucleus, consistent with *C. irritans*, confirming the presence of the parasite (Figure 4(A), 4(B), and 4(C)). The severity of the inflammation was lower in control compared to the EMB-treated

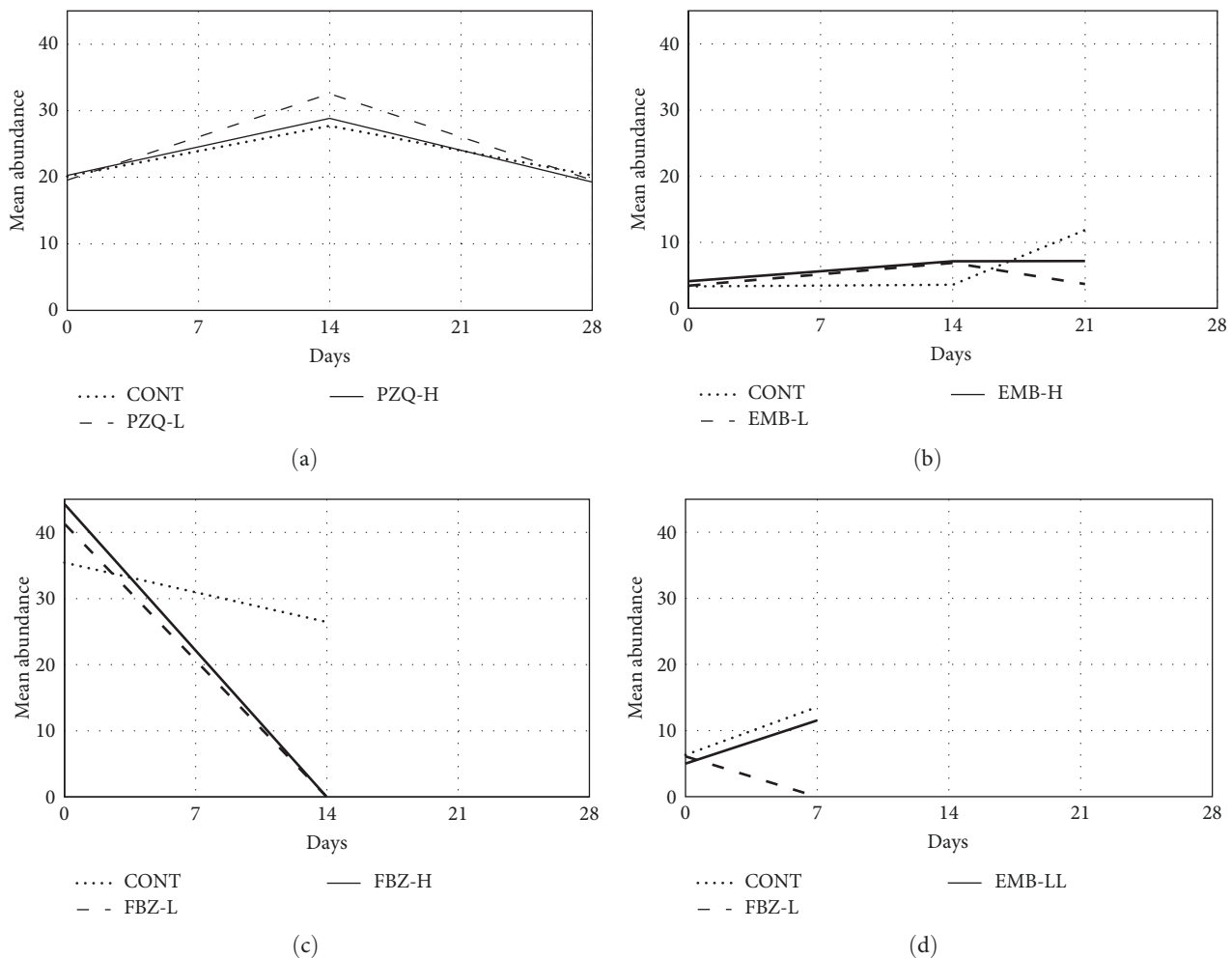


FIGURE 3: (a–d) Dynamics of the mean abundance of *Sparicotyle chrysophrii* in control and treated groups during the four trials.

groups, which also showed de-epithelialisation and necrosis of the primary and secondary lamellae (Figures 4(B) and 4(C)).

4.4. Trial 3: Fenbendazole (FBZ). The feed with FBZ was well-accepted and 100% consumed as the control one, but also this trial was affected by an outbreak of the protist *C. irritans*, which after a few days caused severe clinical manifestations and food refusal (medicated and control), as shown in Figure 2(c). Therefore, the trial was concluded beforehand after 14 days (humane endpoint).

Despite the early termination of the trial, it was possible to evaluate the efficacy of the medicated diets with FBZ. At the beginning, there was no significant difference between the levels of infection of *S. chrysophrii* in the three groups, with prevalence 100% and mean abundance ranging 35–44. Afterward, the levels of infection did not vary significantly in control ($P = 100\%$, MA = 26), while they dropped to zero in the two FBZ groups (Figure 3(c)), suggesting the efficacy of the treatments. Significant differences were found between the prevalences both in inter- and intra-groups, while the mean abundance varied significantly only in the intra-group, and in the inter-group, the differences were close to significance (FBZ-L, $p = 0.080$; FBZ-H, $p = 0.063$). The %R associated with

both FBZ treatments was 100%, for mean abundance and prevalence, both intra- and inter-group, supporting the efficacy of the FBZ diets (Table 3).

Histological analysis of three fish from each group, sampled at the end of the trial, confirmed the presence of *C. irritans* trophonts in the gills of fish of all groups, with higher infections in the treated groups compared to the control one (Figure 4(D), 4(E), and 4(F)). Further, the gills of specimens treated with FBZ showed hyperplasia and fusion of secondary lamellae, as well as moderate to severe mononuclear inflammatory infiltrate in FBZ-L and FBZ-H, respectively (Figures 4(E) and 4(F)).

4.5. Trial 4: Fenbendazole vs. Emamectin Benzoate (FBZ vs. EMB). In light of the results of trials 2 and 3, a fourth trial was set up to (1) evaluate the possible use of EMB against *S. chrysophrii* at an extra low dose (EMB-LL 0.015 mg kg BW^{-1} day $^{-1}$), to limit the possible damage on the host, and (2) verify the efficacy of FBZ-L treatment (40 mg kg BW^{-1} day $^{-1}$) against *S. chrysophrii*. Given the constant presence of *C. irritans* in the cage facility, the trial was shortened to avoid/limit the outbreak of the protist into the RAS (Figure 1), and it was designed according to the following

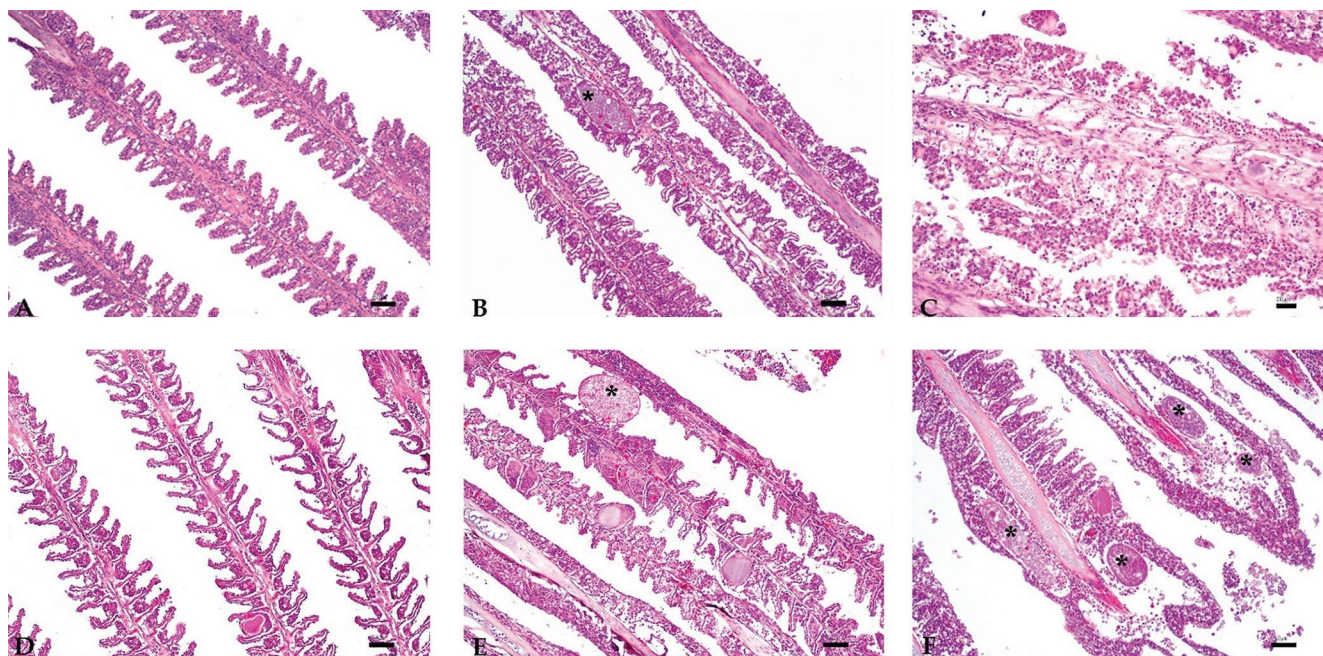


FIGURE 4: Histopathological findings in gills of the gilthead seabream *Sparus aurata* treated with emamectin benzoate (EMB) and fenbendazole (FBZ) at low (L) and high (H) doses; haematoxylin and eosin staining. (A–C) Trial 2. (A) Control: normal primary and secondary lamellae (scale bar = 50 μm , 100x). (B) EMB-L: mild secondary lamellae hyperplasia and presence of *Cryptocaryon irritans* trophonts (asterisk) (scale bar = 50 μm , 100x). (C) EMB-H: diffuse detachment of epithelial cells de-epithelialisation, multifocal necrosis of gill lamellae lamellar necrosis, and severe mononuclear inflammatory infiltrate (scale bar = 20 μm , 200x). (D–F) Trial 3. (D) Control: normal primary and secondary lamellae (scale bar = 50 μm , 100x). (E) FBZ-L: multifocal secondary lamellar fusion and presence of *C. irritans* trophonts (asterisk) (scale bar = 50 μm , 100x). (F) FBZ-H: severe mononuclear inflammatory infiltrate intermingled with around *C. irritans* trophonts (asterisk) (scale bar = 20 μm , 200x).

scheme: (i) stock 18 specimens into each RAS (control, FBZ-L, and EMB-LL); (ii) acclimatisation; (iii) sampling of nine specimens per group; (iv) 5 days treatment; (v) 2 days fasting; and (vi) sampling of nine specimens per group.

At the beginning of the trial, prevalence was 100% and mean abundance ranged 5–6, with no significant difference between groups (Figure 3(d)). Unfortunately, by the third day after starting treatments, fish in the three groups showed clinical signs of *C. irritans* infection, reducing food intake to 50%–70% (Figure 2(d)). At the end of the trial, despite the reduced administration of medicated feeds, the infection levels of the monogenean in the FBZ-L group dropped to zero, while those in control and EMB-LL increased (Figure 3(d)). Significant differences in inter- and intra-groups were found in FBZ-L, due to the disappearance of the parasite, and intra-group in EMB-LL, due to the increase of the mean abundance. The %R of mean abundance and prevalence was always 100% in FBZ-L, both inter- and intra-groups, showing the efficacy of the treatment (Table 3). Regarding EMB-LL, it is noteworthy the negative value of the %R of the mean abundance intra-group, and the %R of the prevalence was equal to zero (Table 3).

4.6. Population Structure of *S. chryso-phrii*. The effectiveness of the egg collectors for the enhancement of the cycle of *S. chryso-phrii* into the RAS was shown by the finding of clusters of parasite eggs entangled in the nylon nets (Supplementary 2), which likely favoured the presence of all stages of development

of the parasite on the gills of the hosts, from larvae with hamuli up to mature adults with eggs (Supplementary 3).

Regarding the differences in the *S. chryso-phrii* population structure between the beginning and end of the trials (Figure 5), an increase in the relative importance of the earliest stage (S_0) was recorded in control and EMB groups of trials 2–4 (Figure 5(b), 5(c), and 5(d)). This result indicates the reproductive success of the parasite in the RAS, with the recruitment of new individuals after egg hatching and larval development. On the other hand, the total absence of all parasite stages after the FBZ treatments, including the S_0 postlarval stage (Figures 5(c) and 5(d)), suggests that FBZ treatments may also have hindered parasite settlement and recruitment.

5. Discussion

The four trials carried out in the present study allowed to test the efficacy of medicated diets with PZQ, EMB, and FBZ against sparcotylosis, and despite the interference by *C. irritans* infection, the results showed the limitations of dietary PZQ and EMB and highlighted the potential of FBZ in aquaculture.

An important component of the *in vivo* investigation of monogenean infections is the successful cultivation and maintenance of parasites in RAS [31]. Apart from the presence of suitable hosts and favourable environmental conditions, the reproduction of monogeneans can be improved by

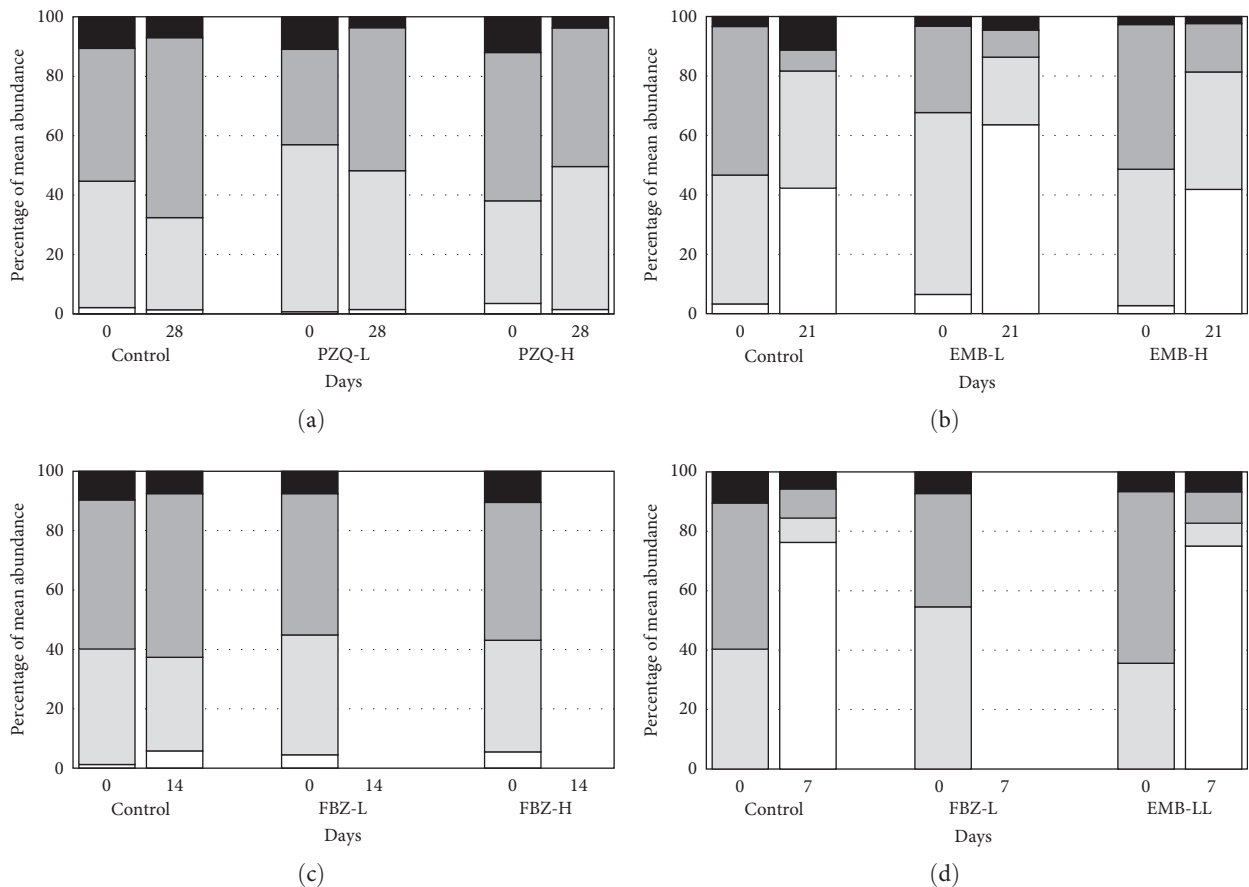


FIGURE 5: Changes in the population structure of *Sparicotyle chrysophrii* in the four trials (a–d), expressed as a percent repartition of four developmental stages (S₀; S₁; S₂; S₃).

placing egg collectors in the RAS, to allow eggs to entangle and hatch in captivity [31, 32, 33]. In this current study, the hand-crafted collectors initially designed by Merella et al. [15] and partially modified by Riera-Ferrer et al. [34] demonstrated effectiveness in promoting the parasite life cycle, highlighted by the high levels of infection observed both in the control groups and where the treatment proved ineffective. Such devices may represent a tool to obtain parasitic infections for *in vivo* studies on monogeneans and can also be used to monitor egg-laying [35], parasite infection in RAS [34], or even in a commercial aquaculture system.

The possible alteration of feed palatability due to the addition of chemical compounds is a factor to be considered when carrying out *in vivo* studies for testing medicated diets [29]. In the present study, only PZQ (trial 1) showed this issue, being largely rejected (64%–93%), whereas control and EMB/FBZ-medicated feeds were completely ingested and only rejected as a consequence of *C. irritans* infection. Rejection of feed with PZQ by *S. aurata* has already been reported by Sitjà-Bobadilla et al. [2] and Merella et al. [15]. However, recently, Rigos et al. [16] have overcome this issue by providing gilthead seabream with a PZQ diet masked by the incorporation of krill in the feed. Although PZQ is considered one of the most promising compounds for the treatment of monogeneans by oral administration [5], according to Norbury et al. [10], its palatability is an obstacle that needs

to be overcome before it can be embraced by aquaculture for its effective dietary administration.

The potential adverse effects of drugs are crucial factors to take into account when evaluating new treatments, and it is imperative to consistently monitor the welfare of fish during the trials to ensure their well-being [29]. In the present study, detachment and necrosis of the epithelium of the gill lamellae were observed in fish treated with EMB. Severe damages associated with avermectins have also been previously reported [21, 24, 36, 37, 38]. Although some authors suggested a potential efficacy of avermectins against monogeneans [22, 23], the present results did not show any significant reduction of the infection after the treatments with EMB. On the other hand, considering the severe and diffuse necrosis of the primary and secondary lamellae, it is conceivable that the putative reduction of infection associated with avermectins could be related to the damage of the gill tissue and the consequent destruction of the monogenean gill habitat. Considering the lack of any significant efficacy of EMB against *S. chrysophrii* at the different doses tested in the present study, and the possible associated gills damage, also observed in previous studies [37, 38, 39], the use of dietary EMB and other avermectins for the treatment of sparcotylosis should be discouraged. The branchitis observed in fish fed with FBZ may be related to an increased susceptibility to *C. irritans* infection, and the consequent

reaction of the host against the parasite [40, 41]. In contrast to EMB, trials conducted with FBZ (trials 3 and 4) showed notable efficacy against *S. chrysophrii*, mitigating potential adverse effects.

Significant efficacy of dietary FBZ against *S. chrysophrii* has already been reported by Merella et al. [15] and also in previous studies for other host and monogenean species [7, 8, 20]. Furthermore, the current results showed that also the low dose of FBZ (FBZ-L, 40 mg kg BW⁻¹ day⁻¹) had high efficacy, and it is possible to think that lower doses of FBZ may be also effective against *S. chrysophrii*. This has also been described by Kimura et al. [20] and Gupta et al. [8], who reported that febantel is effective already at a dose of 25 mg kg BW⁻¹ day⁻¹ for 3 days and FBZ at 20 mg kg BW⁻¹ day⁻¹ for three alternate days, respectively. A reduction in the dose and days of treatment will play an important role in fish farm management, saving costs for the preparation of medicated feed, reducing withdrawal periods, and limiting possible adverse effects on fish. A dose reduction will also be favourable for the environmental impact, limiting the leftovers of medicated feed, reducing the impact on surrounding organisms, and avoiding drug resistance [5, 7, 21, 22].

Another noteworthy consideration regarding FBZ dietary treatment is its potential preventive/repellent effect against *S. chrysophrii*. Indeed, no postlarval (*S*₀) stage of *S. chrysophrii* was detected in all FBZ-treated fish, in stark contrast to the abundance of this stage in both the other treated groups and the control group. According to Iosifidou et al. [42], orally administered FBZ mainly accumulates in the skin of the rainbow trout *Oncorhynchus mykiss* (Walbaum, 1792). Therefore, an external accumulation could have a preventive effect in the postlarval stages settlement. This aspect needs to be further investigated because it could allow the formulation of preventive protocols to avoid the arrival of the parasite on the external surface of fish.

In conclusion, the results confirm FBZ as an effective compound against platyhelminth infections [15, 17, 18] and also settle the ineffectiveness of avermectins against this group of parasites [24]. On the other hand, the putative efficacy of PZQ remains to be investigated due to its administration difficulties [10]. The main clinical application derived from the present study is to provide indications for the development of a medical device able to treat/prevent sparcotylosis, with possible application for other microcotylid infections [43, 44, 45]. To ensure the reliability of this treatment, it is imperative to conduct field trials in fish farms, assessing its benefits on a commercial scale. Furthermore, given that the use of FBZ in aquaculture is not currently registered in the European Union, studies evaluating FBZ residues and establishing a withdrawal period are essential prerequisites for the registration process, facilitating the recognition of dietary FBZ as a veterinary medicinal product.

Data Availability

The data that support the findings of this study are available on request from the corresponding author.

Conflicts of Interest

The authors declare that they have no conflicts of interest.

Acknowledgments

The authors would like to thank Pierluigi Perantoni, Veronesi Holding S.p.A. (Verona, Italy), for the availability and free supply of control feed; Fiona Macdonald, Fish Treatment Ltd. (Ringwood, United Kingdom), and Luca Cravero, Vetark—Candioli Pharma srl (Beinasco, Italy), for providing Fluke-Solve and Lice-Solve free of charge; Elisa Benini (University of Bologna) for improving the English language; Clemente Graziano, Fulvio Mongile, Santino Cherchi, and Marco Mura, Compagnie Ittiche Riunite srl (Golfo Aranci, Italy), for their effective collaboration; Flavio Gagliardi, Angela Pira, Matteo Spanu, and Alessandro Muggianu, Acquario di Cala Gonone—Panaque srl (Dorgali, Italy), for their efficiency and great expertise; and Luca Aru, skilfull aquarist (Sassari, Italy), for advice and assistance. This work was supported by Fondazione di Sardegna call 2017.

Supplementary Materials

Supplementary 1. The handcrafted eggs collector (bar = 3 cm).

Supplementary 2. Eggs of *Sparicotyle chrysophrii* entangled in nylon mesh of the egg collector (bar = 1 mm).

Supplementary 3. Photomicrographs of the stages of *Sparicotyle chrysophrii*. Arrows: (A) hamuli; (E) eggs. Bar = 200 μm.

References

- [1] P. Merella, G. Garippa, and F. Salati, "Parasites of cage cultured European seabass *Dicentrarchus labrax* and gilthead seabream *Sparus aurata* from Sardinia (western Mediterranean): first results," *XXIV Congress of the Italian Society of Parasitology, Parassitologia*, vol. 48, Article ID 290, 2006.
- [2] A. Sitjà-Bobadilla, M. Conde de Felipe, and P. Alvarez-Pellitero, "In vivo and in vitro treatments against *Sparicotyle chrysophrii* (Monogenea: Microcotylidae) parasitizing the gills of gilthead sea bream (*Sparus auratus* L.)," *Aquaculture*, vol. 334–337, pp. 39–44, 2012.
- [3] A. Sitjà-Bobadilla, M. J. Redondo, and P. Alvarez-Pellitero, "Occurrence of *Sparicotyle chrysophrii* (Monogenea: Polyopisthocotylea) in gilthead sea bream (*Sparus aurata* L.) from different mariculture systems in Spain," *Aquaculture Research*, vol. 41, no. 6, pp. 939–944, 2010.
- [4] G. Rigos, I. Mladineo, C. Nikoloudaki, A. Vrbatovic, and D. Kogiannou, "Application of compound mixture of caprylic acid, iron and mannan oligosaccharide against *Sparicotyle chrysophrii* (Monogenea: Polyopisthocotylea) in gilthead sea bream, *Sparus aurata*," *Folia Parasitol.*, vol. 63, Article ID 027, 2016.
- [5] C. Bader, D. E. Starling, D. E. Jones, and M. T. Brewer, "Use of praziquantel to control platyhelminth parasites of fish," *Journal of Veterinary Pharmacology and Therapeutics*, vol. 42, no. 2, pp. 139–153, 2019.

- [6] J. Stone, I. H. Sutherland, C. S. Sommerville, R. H. Richards, and K. J. Varma, "The efficacy of emamectin benzoate as an oral treatment of sea lice, *Lepeophtheirus salmonis* (Krøyer), infestations in Atlantic salmon, *Salmo salar* L.," *Journal of Fish Diseases*, vol. 22, no. 4, pp. 261–270, 1999.
- [7] J. M. Forwood, J. O. Harris, and M. R. Deveney, "Efficacy of bath and orally administered praziquantel and fenbendazole against *Lepidotrema bidyana* Murray, a monogenean parasite of silver perch, *Bidyanus bidyanus* (Mitchell)," *Journal of Fish Diseases*, vol. 36, no. 11, pp. 939–947, 2013.
- [8] G. Gupta, A. Chatterjee, M. Kumar, P. Sardar, T. Varghese, and P. P. Srivastava, "Efficacy of single and multiple doses of fenbendazole against gill parasites (*Dactylogyrus* sp.) of *Labeo rohita* (Hamilton, 1822) and its physio-metabolic effects on the fish," *Aquaculture Research*, vol. 51, no. 3, pp. 1190–1199, 2019.
- [9] R. E. Williams, I. Ernst, C. B. Chambers, and I. D. Whittington, "Efficacy of orally administered praziquantel against *Zeuxapta seriolae* and *Benedenia seriolae* (Monogenea) in yellowtail kingfish *Seriola lalandi*," *Diseases of Aquatic Organisms*, vol. 77, pp. 199–205, 2007.
- [10] L. J. Norbury, S. Shirakashi, C. Power, B. F. Nowak, and N. J. Bott, "Praziquantel use in aquaculture—current status and emerging issues," *International Journal for Parasitology: Drugs and Drug Resistance*, vol. 18, pp. 87–102, 2022.
- [11] N. Hirazawa, T. Ohtaka, and K. Hata, "Challenge trials on the anthelmintic effect of drugs and natural agents against the monogenean *Heterobothrium okamotoi* in the tiger puffer *Takifugu rubripes*," *Aquaculture*, vol. 188, no. 1–2, pp. 1–13, 2000.
- [12] N. Hirazawa, K. Akiyama, and N. Umeda, "Differences in sensitivity to the anthelmintic praziquantel by the skin parasitic monogeneans *Benedenia seriolae* and *Neobenedeniagirellae*," *Aquaculture*, vol. 404–405, pp. 59–64, 2013.
- [13] G. J. Partridge, R. J. Michael, and L. Thuillier, "Praziquantel form, dietary application method and dietary inclusion level affect palatability and efficacy against monogenean parasites in yellowtail kingfish," *Diseases of Aquatic Organisms*, vol. 109, no. 2, pp. 155–163, 2014.
- [14] J. M. Forwood, E. J. Bubner, M. Landos, M. R. Deveney, and T. D'Antignana, "Praziquantel delivery via moist pellets to treat monogenean parasites of yellowtail kingfish *Seriola lalandi*: efficacy and feed acceptance," *Diseases of Aquatic Organisms*, vol. 121, no. 3, pp. 201–209, 2016.
- [15] P. Merella, F. E. Montero, C. Burreddu, and G. Garippa, "In-feed trials of fenbendazole and other chemical/natural compounds against *Sparicotyle chrysofhrui* (Monogenea) infections in *Sparus aurata* (Osteichthyes)," *Aquaculture Research*, vol. 52, no. 11, pp. 5908–5911, 2021.
- [16] G. Rigos, A. Glaropoulos, K. Tzokas, E. Gourzioti, D. Kogiannou, and E. Golomazou, "A field evaluation of orally administered praziquantel against the gill fluke *Sparicotyle chrysofhrui* infecting gilthead seabream (*Sparus aurata*)," *Journal of Fish Diseases*, vol. 46, no. 12, pp. 1439–1443, 2023.
- [17] C. Baeder, H. Bähr, O. Christ et al., "Fenbendazole: a new, highly effective anthelmintic," *Experientia*, vol. 30, no. 7, pp. 753–754, 1974.
- [18] A. J. Ngomuo, S. E. Marriner, and J. A. Bogan, "The pharmacokinetics of fenbendazole and oxfendazole in cattle," *Veterinary Research Communications*, vol. 8, no. 1, pp. 187–193, 1984.
- [19] K. Ogawa, "Gill fluke disease-2," in *Infectious and Parasitic Diseases of Fish and Shellfish*, H. Wakabayashi and K. Muroga, Eds., pp. 369–375, Kouseisha-Kouseikaku Publ, Tokyo, 2004.
- [20] T. Kimura, M. Sameshima, Y. Nomura, J. Morita, H. Mizoguchi, and M. Ishihara, "Efficacy of orally administered febantel against monogenean *Heterobothrium okamotoi* infection of cultured tiger puffer *Takifugu rubripes*," *Fish Pathology*, vol. 41, no. 4, pp. 147–151, 2006.
- [21] I. M. Davies and G. K. Rodger, "A review of the use of ivermectin as a treatment for sea lice *Lepeophtheirus salmonis* (Kroyer) and *Caligus elongatus* (Nordmann) infestation in farmed Atlantic salmon (*Salmo salar* L.)," *Aquaculture Resource*, vol. 31, pp. 869–883, 2000.
- [22] F. Athanassopoulou, I. S. Pappas, and K. Bitchava, "An overview of the treatments for parasitic disease in Mediterranean aquaculture," in *The Use of Veterinary Drugs and Vaccines in Mediterranean Aquaculture*, C. Rogers and B. Basurco, Eds., pp. 65–83, Zaragoza, CIHEAM, 2009.
- [23] C. M. G. Alves, J. N. Nogueira, I. B. Barriga, J. R. Dos Santos, G. G. Santos, and M. Tavares-Dias, "Albendazole, levamisole and ivermectin are effective against monogeneans of *Colossoma macropomum* (Pisces: Serrasalimidae)," *Journal of Fish Diseases*, vol. 42, no. 3, pp. 405–412, 2019.
- [24] K. Buchmann and J. Bjerregaard, "Effect of ivermectin, pyrantel and morantel on the European eel and its monogenean parasites," *Bulletin of the European Association of Fish Pathologists*, vol. 10, pp. 146–148, 1990.
- [25] A. Repullés-Albelda, J. A. Raga, and F. E. Montero, "Post-larval development of the microcotylid monogenean *Sparicotyle chrysofhrui* (Van Beneden and Hesse, 1863): comparison with species of Microcotylidae and Heteraxinidae," *Parasitology International*, vol. 60, no. 4, pp. 512–520, 2011.
- [26] Official Journal of the European Union, "Directive 2010/63/EU of the European parliament and of the council of 22 September 2010 on the protection of animals used for scientific purposes," pp. 33–79, 2010.
- [27] A. O. Bush, K. D. Lafferty, J. M. Lotz, and A. W. Shostak, "Parasitology meets ecology on its own terms: Margolis et al. revisited," *The Journal of Parasitology*, vol. 83, no. 4, pp. 575–583, 1997.
- [28] J. Reiczigel, M. Marozzi, I. Fabian, and L. Rozsa, "Biostatistics for parasitologists—a primer to quantitative parasitology," *Trends in Parasitology*, vol. 35, no. 4, pp. 277–281, 2019.
- [29] C. Sommerville, R. Endris, T. A. Bell, K. Ogawa, K. Buchmann, and D. Sweeney, "World association for the advancement of veterinary parasitology (WAAVP) guideline for testing the efficacy of ectoparasiticides for fish," *Veterinary Parasitology*, vol. 219, pp. 84–99, 2016.
- [30] D. W. Bruno, B. Nowak, and D. G. Elliott, "Guide to the identification of fish protozoan and metazoan parasites in stained tissue sections," *Diseases of Aquatic Organisms*, vol. 70, pp. 1–36, 2006.
- [31] K. S. Hutson, A. K. Brazenor, D. B. Vaughan, and A. Trujillo-González, "Chapter three—monogenean parasite cultures: current techniques and recent advances," *Advances in Parasitology*, vol. 99, pp. 61–91, 2018.
- [32] G. C. Kearn, K. Ogawa, and Y. Maeno, "Egg production, the oncomiracidium and larval development of *Benedenia seriolae*, a skin parasite of the yellowtail, *Seriola quinqueradiata* in Japan," *Publications of the Seto Marine Biological Laboratory*, vol. 35, no. 6, pp. 351–362, 1992.
- [33] N. Hirazawa, R. Takano, H. Hagiwara, M. Noguchi, and M. Narita, "The influence of different water temperatures on *Neobenedeniagirellae* (Monogenea) infection, parasite growth, egg production and emerging second generation on amberjack

- Seriola dumerili* (Carangidae) and the histopathological effect of this parasite on fish skin,” *Aquaculture*, vol. 299, no. 1–4, pp. 2–7, 2010.
- [34] E. Riera-Ferrer, R. Del Pozo, C. Piazzon, A. Sitjà-Bobadilla, I. Estensoro, and O. Palenzuela, “*Sparicotyle chrysophrii* experimental infection of gilthead seabream (*Sparus aurata*): Establishment of an *in vivo* model reproducing the pathological outcomes of sparicotylosis,” *Aquaculture*, vol. 573, Article ID 739588, 2023.
- [35] K. Ogawa, N. Yamabata, and T. Yoshinaga, “Egg-laying of the monogenean *Heterobothrium okamotoi* on experimentally infected tiger puffer *Takifugu rubripes*,” *Fish Pathology*, vol. 40, no. 3, pp. 111–118, 2005.
- [36] J. P. G. Toovey, A. R. Lyndon, and J. H. Duffus, “Ivermectin inhibits respiration in isolated rainbow trout (*Oncorhynchus mykiss* Walbaum) gill tissue,” *Bulletin of the European Association of Fish Pathologists*, vol. 19, pp. 149–152, 1999.
- [37] I. Mladineo, J. Marsic-Lucic, and M. Buzancic, “Toxicity and gross pathology of ivermectin bath treatment in sea bream *Sparus aurata*, L,” *Ecotoxicology and Environmental Safety*, vol. 69, no. 10, pp. 438–442, 1991.
- [38] I. Varó, G. Rigos, J. C. Navarro et al., “Effect of ivermectin on the liver of gilthead sea bream *Sparus aurata*: a proteomic approach,” *Chemosphere*, vol. 80, no. 5, pp. 570–577, 2010.
- [39] M. Thiripurasundari, K. Sathya, A. Uma, M. Srinivasan, and P. Rajasekar, “A comparative study on the toxicity of ivermectin in zebra fish and catla fish models,” *Indo American Journal of Pharmaceutical Research*, vol. 4, no. 9, pp. 3683–3688, 2014.
- [40] L. Cervera, C. González-Fernández, M. Arizcun, A. Cuesta, and E. Chaves-Pozo, “Severe natural outbreak of *Cryptocaryon irritans* in gilthead seabream produces leukocyte mobilization and innate immunity at the gill tissue,” *International Journal of Molecular Sciences*, vol. 23, no. 2, Article ID 937, 2022.
- [41] Z. Zhong, X. Wu, M. Bai, X. Huang, Q. Zheng, and C. Ai, “Treatments of orange-spotted grouper (*Epinephelus coioides*) against *Cryptocaryon irritans* with OH, ClO₂ or HCHO: survival, physiological and histological response,” *Journal of Fish Diseases*, vol. 46, no. 3, pp. 215–227, 2023.
- [42] E. G. Iosifidou, N. Haagsma, M. W. T. Tanck, J. H. Boon, and M. Olling, “Depletion study of fenbendazole in rainbow trout (*Oncorhynchus mykiss*) after oral and bath treatment,” *Aquaculture*, vol. 154, no. 3–4, pp. 191–199, 1997.
- [43] F. E. Montero, S. Crespo, F. Padrós, F. De la Gándara, A. García, and J. A. Raga, “Effects of the gill parasite *Zeuxapta seriola* (Monogenea: Heteraxinidae) on the amberjack *Seriola dumerili* Risso (Teleostei: Carangidae),” *Aquaculture*, vol. 232, no. 1–4, pp. 153–163, 2004.
- [44] P. Merella, S. Cherchi, F. Salati, and G. Garippa, “Parasitological survey of sharpnose seabream *Diplodus puntazzo* (Cetti) reared in sea cages in Sardinia (western Mediterranean),” *Bulletin of the European Association of Fish Pathologists*, vol. 25, pp. 140–147, 2005.
- [45] P. Merella, S. Cherchi, G. Garippa, M. L. Fioravanti, A. Gustinelli, and F. Salati, “Outbreak of *Sciaenacotyle panceri* (Monogenea) on cage-reared meagre *Argyrosomus regius* (Osteichthyes) from the western Mediterranean Sea,” *Diseases of Aquatic Organisms*, vol. 86, pp. 169–173, 2009.