

Extraocular cutaneous sebaceous carcinoma in a patient with Muir-Torre syndrome: special emphasis on histologic and dermoscopic features

Francesco Savoia,¹ Matelda Medri,¹ Davide Melandri,²⁻⁴ Lucia Domeniconi,⁵ Emilia Crisanti,⁵ Andrea Sechi,⁶ Ignazio Stanganelli^{1,7}

¹Skin Cancer Unit, IRCCS Istituto Romagnolo per lo Studio dei Tumori (IRST) “Dino Amadori”, Meldola (FC); ²Dermatology Unit, Bufalini Hospital, AUSL della Romagna, Cesena (FC); ³Dermatology Unit, IRCCS Azienda Ospedaliero-Universitaria di Bologna; ⁴Department of Medical and Surgical Sciences, Alma Mater Studiorum University of Bologna; ⁵Pathologic Anatomy, AUSL della Romagna, Ravenna; ⁶Dermatology Unit, San Bortolo Hospital, Vicenza; ⁷Dermatology Unit, Department of Clinical and Experimental Medicine, University of Parma, Italy

Correspondence: Francesco Savoia, Skin Cancer Unit, IRCCS Istituto Romagnolo per lo Studio dei Tumori (IRST) “Dino Amadori”, Meldola (FC), Italy.
Tel.: 0039-0543-739100.
Fax: 0039-0543-739123.
E-mail: francesco.savoia@irst.emr.it

Key words: cutaneous sebaceous carcinoma, Muir-Torre syndrome, hereditary nonpolyposis colorectal cancer syndrome, dermoscopy.

Contributions: FS, conception and design, acquisition of data, analysis and interpretation of data, drafting of the manuscript; MM, LD, EC acquisition of data; DM, IS, conception and design, revision of the manuscript; AS, conception and design, drafting of the manuscript. All authors gave final approval of the version to be published.

Conflict of interest: the authors declare no potential conflict of interest.

Ethics approval and consent to participate: not applicable.

Patient consent for publication: the patient gave his written consent to use his personal data for the publication of this case report and any accompanying images.

Funding: none.

Availability of data and materials: data associated with this article are available and can be accessed on request from the corresponding author.

Received: 22 August 2023.
Accepted: 23 August 2023.
Early view: 13 September 2023.

This work is licensed under a Creative Commons Attribution-NonCommercial 4.0 International License (CC BY-NC 4.0).

©Copyright: the Author(s), 2023
Licensee PAGEPress, Italy
Dermatology Reports 2024; 16:9832
doi:10.4081/dr.2023.9832

Publisher's note: all claims expressed in this article are solely those of the authors and do not necessarily represent those of their affiliated organizations, or those of the publisher, the editors and the reviewers. Any product that may be evaluated in this article or claim that may be made by its manufacturer is not guaranteed or endorsed by the publisher.

Abstract

Cutaneous sebaceous carcinoma (CSC) can be classified into periocular and extraocular and can occur as part of Muir-Torre syndrome. It is usually a pink-red or yellow solitary nodule, mainly located in the head and neck region. According to the literature, dermoscopy is characterized in most cases by a yellow color, polymorphic vessels, and ulceration. We performed a review of the literature, and we found 14 papers describing the dermoscopic features of 33 sebaceous carcinomas, to which we added a case that we have recently observed. Compared to the data of the literature and in particular to the latest published reviews, we found that milky-red areas are frequently observed in CSC (47% of the cases) and can be added to the main dermoscopic features for the diagnosis. In our case, histology showed some features that were consistent with a CSC with a secretory pattern, and other features that were instead consistent with a non-secretory pattern. This was probably due to the fact that the lesion we observed was a moderately differentiated and not well-differentiated CSC. The presence of a CSC should always alert the clinician to the possible association with Muir-Torre syndrome, and immunohistochemistry for mismatch repair gene defects can help in the diagnostic pathway.

Introduction

Cutaneous sebaceous carcinoma (CSC) is a rare adnexal skin cancer that usually affects the head and neck area, with a peculiar predilection for the eyelids.¹ However, cases of CSC located outside the head and neck area have been previously described. Here, we report a CSC of the upper arm in the context of Muir-Torre syndrome.

Case Report

A 52-year-old man referred to us for a rapidly growing pink nodule of the volar surface of his left arm (Figure 1a). The lesion was 1.2 cm in its maximum diameter, was firm to palpation, asymptomatic, and showed a central white adherent crust. Dermoscopy showed a pink background with milky-red areas, irregular polymorphic vessels, including branching out of focus vessels, white structures, and a white crust at the center of the nodule (Figure 1b). Surgical excision with 4 mm margins was per-

formed, and histology was consistent with a moderately differentiated sebaceous carcinoma involving the reticular dermis (Figure 2). The tumor had a double component, with sebaceous areas involving slightly less than 50% of the tumor and characterized by cells with foamy cytoplasm and diffuse areas of atypical spindle cells.

The presence of an organoid and lobulated architecture, areas of comedonecrosis, and focal areas of holocrine secretion within

the sebaceous differentiated component were consistent with a secretory variant of sebaceous carcinoma, according to the paper of Misago *et al.*² On the contrary, the presence of marked atypia within the spindle cell component and the presence of a high

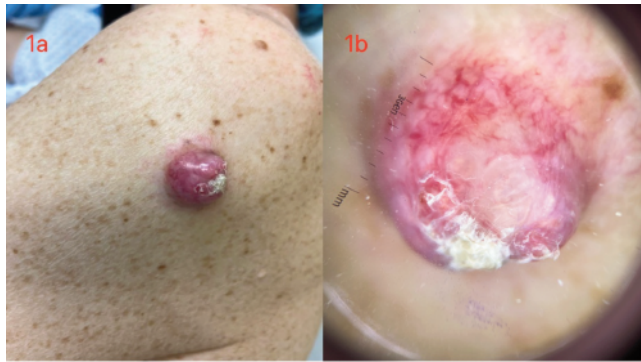

Figure 1. a) A pink nodule with telangiectasias and a central white crust on the left arm of the patient; b) dermoscopy showing a pink background with milky-red areas, irregular polymorphic vessels, including branching out of focus vessels, white structures and the presence of the white crust at the center of the nodule (Dermlite DL3).

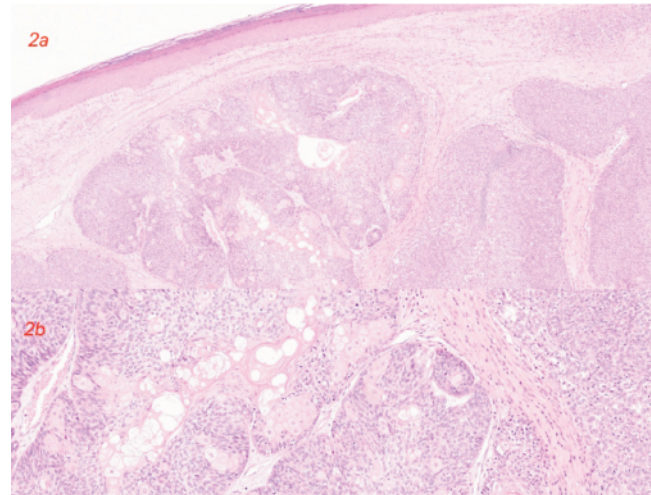


Figure 2. a) At low magnification, histology shows a scattered sebaceous differentiation [hematoxylin and eosin stain (H&E), magnification 2 \times]; b) at higher magnification the sebaceous differentiation is more evident (H&E, magnification 10 \times).

Table 1. Specific dermoscopic features reported up to now in the English Literature, in order of publication's year.

Reference	Dermoscopic features
Coates <i>et al.</i> , 2011	- a variably yellow and milky red tumour with polymorphic vessels and an area of ulceration - a predominately diffuse yellow tumour with polymorphic vessels and an area of ulceration
Lallas <i>et al.</i> , 2014	- polymorphous vascular pattern comprising linear irregular and tortuous vessels, yellowish structures and ulceration
Iikawa <i>et al.</i> , 2015	- polymorphous vessels with homogenous yellow background; the polymorphous vessels were composed of linear irregular vessels, glomerular vessels and hairpin-like vessels
Manríquez <i>et al.</i> , 2015	- ulcerated areas and telangiectasias over white-yellow background - multiple telangiectasias over yellow globules
Satomura <i>et al.</i> , 2017	- brilliant yellow background, polymorphous vessels - ulceration, linear irregular vessels (similar to crown vessels) and hairpin vessels, yellowish area - dotted and hairpin vessels, yellow lesion - linear irregular and dotted vessels, yellow background - linear irregular and hairpin vessels, yellowish background
Zaballos <i>et al.</i> , 2018	- polymorphous atypical vessels, homogeneous yellowish background and ulceration.
Nair <i>et al.</i> , 2018	- heterogeneous yellowish background with peripheral blood vessels and areas of ulceration
Horimoto <i>et al.</i> , 2018	- multiple, roundish, irregularly arranged yellowish structures with indistinct borders in homogenous whitish-pink background areas, polymorphous vessels consisting of linear irregular vessels and arborizing vessels and an ulceration with a crust - whitish-pink areas, yellowish structures and small ulcerations with crusts, polymorphous vessels consisting of linear irregular vessels, hairpin-like vessels and arborizing vessels - yellowish disseminated structures accompanied with a moderate dose of yellow necrotic tissues, polymorphous vessels comprising linear irregular vessels, comma-like vessels and dotted vessels
Mitsui <i>et al.</i> , 2019	- multiple yellowish structures with indistinct borders
Cheng <i>et al.</i> , 2020	- linear-irregular vessels, arborizing vessels, hairpin vessels, dotted vessels, corkscrew vessels, coiled vessels, milky red areas (vessels can be monomorphic or polymorphic, vascular arrangement can be radial, centered, clustered or unspecific) - ulceration, crust, scale, purplish globules, white structureless areas, white structureless areas, milia-like cyst, perifollicular white halo, whitish-pink area, yellowish structure, yellowish structureless area, yellowish lobules/globules
Cheng and Chuang, 2020	- blue ovoid nests and bluish structureless areas
Pradhan <i>et al.</i> , 2020	- yellowish inhomogeneous areas, polymorphous vessels, whitish superficial scaling, erythematous lesion.
Kawamura <i>et al.</i> , 2021	- multiple yellowish dots with whitish structureless areas.
Arslan <i>et al.</i> , 2021	- polymorphous vessels, white-yellow structures, ulceration
Savoia <i>et al.</i>	- a pink background with milky-red areas, polymorphic vessels with branching out of focus vessels, white structures and a white crust at the center of the nodule

mitotic rate, up to 40 mitosis \times 10 high-power fields at a 40 \times magnification, were consistent with a non-secretory variant.² After the histologic diagnosis was made, specific immunohistochemistry testing was performed. The expression of mismatch repair proteins MSH2 and MSH6 was altered, with complete absence within the tumor. Immunohistochemistry staining for CK20 to detect Merkel cells within the tumor was negative, while rare Merkel cells were evident on the overlying epidermis.

A more accurate anamnesis pointed out that the patient had a personal history positive for colon cancer and positive genetic testing for hereditary nonpolyposis colorectal cancer (HNPCC) syndrome, allowing us to make the diagnosis of Muir-Torre syndrome. A dermatologic follow-up with clinical examination and locoregional lymph node echography every 6 months was scheduled, in alternation with oncologic visits that the patient was doing every 6 months, to control the patient every 3 months. After 12 months, the patient is free from local recurrences or distant metastases and has not developed new CSC or other skin cancers.

Discussion

CSC can be classified into periocular and extraocular and can occur as part of Muir-Torre syndrome, a variant of HNPCC syndrome, also called Lynch syndrome.^{1,3}

Muir-Torre syndrome is due to germline mutations in the mismatch repair genes *MLH1*, *MSH2*, or *MSH6*, or due to biallelic *MYH* germline mutations, and it is characterized by the association of multiple sebaceous tumors or keratoacanthomas and one or more visceral cancers.⁴ Our patient fulfilled the criteria for Muir-Torre syndrome since she had a personal history of colon cancer and CSC, presented multiple sebaceous hyperplasias on the face, few sebaceous adenomas on the face and trunk, and carried a germline mutation of the mismatch repair genes *MSH2* and *MSH6*.

It is important to outline that in young patients, in particular those aged under 50 years, and with an extraocular CSC, recent guidelines advise considering tumor immunohistochemistry testing for mismatch repair protein before genetic testing for HNPCC syndrome.⁵

According to the literature, CSC is usually a pink-red or yellow solitary nodule, mainly located in the head and neck region.¹ Dermoscopy is characterized by multiple dermoscopic features that can be variably associated with a single lesion, even though yellow color, polymorphous vessels, and ulceration are considered the most frequently reported ones in CSC.^{1,3,6-10}

We performed a review of the literature through PubMed and Google Scholar, and we found 14 papers describing the dermoscopic features of 33 sebaceous carcinomas, to which we added the case that we have recently observed (Table 1).^{1,6-18}

These dermoscopic characteristics included the presence of: i) yellow color in 30/34 cases (88.2%); ii) polymorphous vessels in 26/34 cases (76.4%); iii) milky-red areas in 16/34 cases (47%); iv) ulceration in 16/34 cases (47%); v) crusts in 10/34 cases (29.4%); vi) shiny white structures in 8/34 cases (23.5%); vii) monomorphous vessels in 5/34 cases (14.7%); viii) purple globules in 5/34 cases (14.7%); ix) milia-like cysts in 4/34 cases (11.7%); x) scales in 3/34 cases (8.8%); xi) erythematous areas in 2/34 cases (5.8%); xii) blue structures in 1/34 cases (2.9%).

Compared to the data of the literature and in particular to the latest published reviews, we found that milky-red areas are frequently observed in CSC (47% of the cases) and can be added to the main dermoscopic features for the diagnosis.^{1,3}

In our case, histology showed some features that were consis-

tent with a secretory pattern CSC and other features that were instead consistent with a non-secretory pattern CSC. This is probably due to the fact that we have observed a moderately differentiated CSC and not a well-differentiated one, as in the case series reported by Misago *et al.*² In our case, the staining for CK20 was negative within the tumor, confirming the data of the literature that extraocular CSC do not contain Merkel cells.¹⁹

Conclusions

In conclusion, the presence of a CSC should always alert the clinician to the possible association with HNPCC syndrome, and immunohistochemistry testing for mismatch repair genes can help in the diagnostic pathway. The case we had the opportunity to observe and the review of the literature allowed us to add milky-red areas to the most important dermoscopic features for the diagnosis of CSC since it can be found in about half of the cases.

References

- Zaballos P, Gómez-Martín I, Martín JM, Bañuls J. Dermoscopy of adnexal tumors. *Dermatol Clin* 2018;36:397-412.
- Misago N, Toda S, Narisawa Y. Two histopathologic patterns of well-differentiated extraocular sebaceous carcinoma. *J Cutan Pathol* 2011;38:767-74.
- Lai M, Muscianese M, Piana S, et al. Dermoscopy of cutaneous adnexal tumours: a systematic review of the literature. *J Eur Acad Dermatol Venereol* 2022;36:1524-40.
- Guillén-Ponce C, Castillejo A, Barberá VM, et al. Biallelic MYH germline mutations as cause of Muir-Torre syndrome. *Fam Cancer* 2010;9:151-4.
- Owen JL, Kibbi N, Worley B, et al. Sebaceous carcinoma: evidence-based clinical practice guidelines. *Lancet Oncol* 2019;20:e699-714.
- Cheng CY, Su HJ, Kuo TT. Dermoscopic features and differential diagnosis of sebaceous carcinoma. *J Dermatol* 2020;47:755-62.
- Horimoto K, Kato J, Sumikawa Y, et al. Dermoscopic features distinctive for extraocular sebaceous carcinoma. *J Dermatol* 2018;45:487-90.
- Lallas A, Moscarella E, Argenziano G, et al. Dermoscopy of uncommon skin tumours. *Australas J Dermatol* 2014;55:53-62.
- Coates D, Bowling J, Haskett M. Dermoscopic features of extraocular sebaceous carcinoma. *Australas J Dermatol* 2011;52:212-3.
- Cheng CY, Chuang YH. Pigmented sebaceous carcinoma: dermoscopic features of a new case. *Eur J Dermatol* 2020;30:58-60.
- Iikawa M, Namiki T, Arima Y, et al. Extraocular sebaceous carcinoma in association with a clonal seborrheic keratosis: dermoscopic features. *J Dermatol* 2015;42:1105-6.
- Manriquez J, Cataldo-Cerda K, Álvarez-Véliz S, Vera-Kellet C. Dermoscopy of sebaceous carcinoma: an unusual image. *G Ital Dermatol Venereol* 2015;150:626-7.
- Satomura H, Ogata D, Arai E, Tsuchida T. Dermoscopic features of ocular and extraocular sebaceous carcinomas. *J Dermatol* 2017;44:1313-6.
- Nair PA, Patel T, Gandhi S. The usefulness of dermoscopy in extraocular sebaceous carcinoma. *Indian J Dermatol*

- 2018;63:440-2.
15. Mitsui Y, Ogawa K, Fukumoto T, et al. Superficial sebaceous carcinoma: the correlations between the clinical, dermoscopic and histopathological findings of a rare variant of sebaceous carcinoma. *J Dermatol* 2019;46:e280-1.
 16. Pradhan S, Xiao H, Yang HL, Ran YP. Dermoscopic clues for sebaceous carcinoma arising in nevus sebaceous. *Chin Med J* 2020;133:2121-2.
 17. Kawamura T, Kitamura S, Maeda T, et al. Dermoscopic features of sebaceous carcinoma of the nipple. *J Dermatol* 2021;48:e327-8.
 18. Arslan Z, Çetinarslan T, Bali ZU, et al. A painless, solitary, yellow-pink colored, vascularized, firm nodule on the forehead. *Indian J Dermatol Venereol Leprol* 2021;87:878-80.
 19. Fernandez-Flores A, Cassarino DS. Merkel cells in extraocular sebaceous carcinoma. *J Cutan Pathol* 2019;46:171-4.