

# Primary cutaneous CD4<sup>+</sup> small/medium T-cell lymphoproliferative disorder nodule successfully treated with laser CO<sub>2</sub> ablation: a case report and literature review

Corrado Zengarini,<sup>1,2</sup> Alba Guglielmo,<sup>1,3</sup> Martina Mussi,<sup>1,2</sup> Andrea Filippini,<sup>1,2</sup> Sabina Vaccari,<sup>1,4</sup> Bianca Maria Piraccini,<sup>1,2</sup> Alessandro Pileri<sup>1,2</sup>

<sup>1</sup>Department of Medical Sciences and Surgery, University of Bologna; <sup>2</sup>Dermatology Unit, IRCCS Azienda Ospedaliero-Universitaria di Bologna; <sup>3</sup>Institute of Dermatology, “Santa Maria della Misericordia” University Hospital, Udine; <sup>4</sup>Oncologic Dermatology Unit, IRCCS Azienda Ospedaliero-Universitaria di Bologna, Italy

## Abstract

This case report describes an 83-year-old patient with a history of non-melanoma skin cancer who presented with a violaceous, painless nodule on the neck. Dermoscopic examination and subsequent biopsy revealed a Small/Medium CD4<sup>+</sup> T-cell lymphoproliferative disorder (SMPLPD) of the skin. Although excision was initially recommended, the patient opted for treatment with CO<sub>2</sub> laser ablation. The procedure had some minor complications but resulted in successful healing. SMPLPDs are a rare skin condition with limited treatment data, and this case suggests that CO<sub>2</sub> laser ablation with minimal margins could be a viable alternative for selected patients, reducing bleeding and promoting second-intention healing for small nodules. However, more extensive follow-

up data for SMPLPD cases are needed to understand long-term outcomes better.

## Introduction

We present a case of an 83-year-old patient in yearly follow-up for a history of cutaneous basal cell carcinoma. During the last visit, besides some actinic keratoses of multiple grades, he presented a violaceous, firm nodule on the neck (Figure 1A).

He reported that the lesion was painless and arose in the last three months without any other symptoms. Clinical examination showed no other cutaneous lesions.

Besides his non-melanoma skin cancers, the rest of the clinical history was remarkable for hypertension, hypercholesterolemia and atrial fibrillation.

A dermoscopic examination of the lesion showed a well-defined nodule with irregular and serpiginous vessels and shiny whitish structures over a salmon-pink homogenous background (Figure 1B). As described in the literature, such dermoscopic features together with the clinical appearance led to the suspicion of a lymphoproliferative disorder.<sup>1</sup>

A central punch biopsy was performed and subsequent histopathological and immunohistochemical evaluation showed small-to medium-sized CD4<sup>+</sup> lymphocytes with dermal involvement in a dense nodular pattern, with no epidermotropism and positive BCL-6, PD-1, CXCL-13 expression, but negative CD10 marker. Molecular studies showed a clonal rearrangement of T-cell receptor genes in more than 60% of cases, leading to the diagnosis of primitive T-lymphoproliferative disorder of the skin, with Small/medium CD4<sup>+</sup> cells, (SMPLPD) according to the WHO classification of 2017.

During the work-up, haematological tests with white blood count and lymphocyte profile evaluation, total body CT-PET and abdominal and lymph node ultrasound scans were performed to exclude systemic involvement. All laboratory and instrumental investigations resulted negative.

The patient was then offered primary excision of the tumour, which he refused, asking for a less invasive treatment with ablative CO<sub>2</sub> laser already programmed for his actinic keratoses treatment and scheduled in the same session.

After an internal consultation with other specialists and after explaining to the patient that this type of treatment, although reasonable, was not the first indication but that other options exist, he still preferred to be treated with the CO<sub>2</sub> laser.

Therefore, in conjunction with the session scheduled for the actinic keratoses of the scalp, after intralesional local anaesthesia with 1cc of lidocaine 20mg/ml the nodule was treated with a CO<sub>2</sub> laser device. Setting specifics were ultra-pulse mode, pulsed

Correspondence: Alba Guglielmo, Department of Medical Sciences and Surgery, University of Bologna, via Massarenti, 1, 40138 Bologna, Italy.  
Tel.: +39.0512144849 - Fax: +39.0512144867.  
E-mail: albaguglielmo@gmail.com

Key words: oncology; skin; cancer; lymphoma; CO<sub>2</sub>-laser.

Conflict of interest: the authors declare no potential conflict of interest.

Ethical approval and consent to participate: not applicable.

Availability of data and material: data are available on request from the authors.

Informed consent: the patients in this manuscript have given written informed consent to the publication of their case details.

Received: 1 November 2023.

Accepted: 10 December 2023

This work is licensed under a Creative Commons Attribution-NonCommercial 4.0 International License (CC BY-NC 4.0).

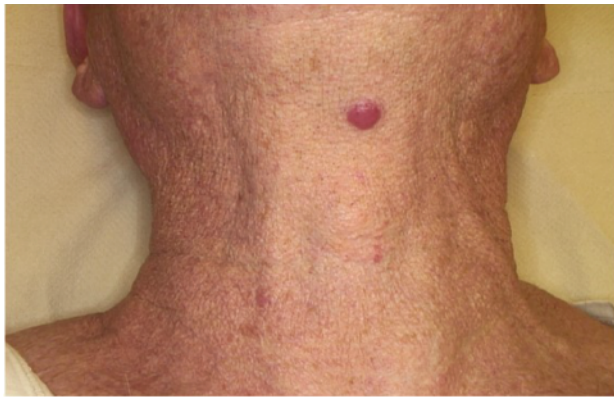©Copyright: the Author(s), 2024

Licensee PAGEPress, Italy

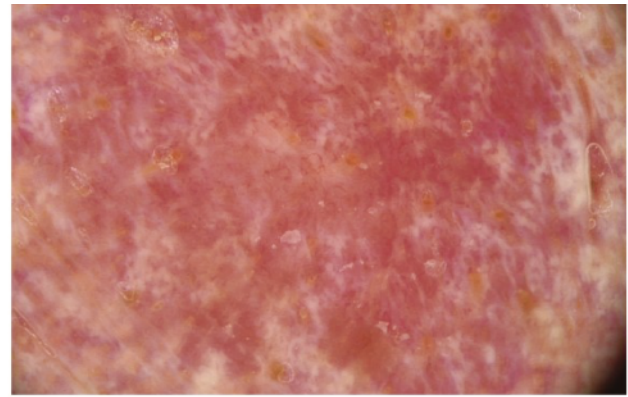
Dermatology Reports 2024; 16:9884

doi:10.4081/dr.2024.9884

*Publisher's note: all claims expressed in this article are solely those of the authors and do not necessarily represent those of their affiliated organizations, or those of the publisher, the editors and the reviewers. Any product that may be evaluated in this article or claim that may be made by its manufacturer is not guaranteed or endorsed by the publisher.*



A



B

**Figure 1.** A) Clinical image taken from the front of the nodule of primary cutaneous CD4+ small/medium-sized pleomorphic T-Cell Lymphoproliferative disorder. The appearance stood out noticeably to the eye, and it was not excessively tense and had a well-defined consistency; B) Dermoscopic view. The prevailing image is the absence of pigmentation associated with white-milky formations serpiginous vessels arranged indefinitely on an orange-yellow background. Some plugs can also be highlighted (10x magnification).

Figure 1. A) Clinical image taken from the front of the nodule of primary cutaneous CD4+ small/medium-sized pleomorphic T-Cell Lymphoproliferative disorder. The appearance stood out noticeably to the eye, and it was not excessively tense and had a well-defined consistency; B) Dermoscopic view. The prevailing image is the absence of pigmentation associated with white-milky formations serpiginous vessels arranged indefinitely on an orange-yellow background. Some plugs can also be highlighted (10x magnification)., 20 Hz, 0.8 j/ms fluency with the endpoint of reaching the deep dermis and ablating 0.2-0.3 cm per each observable margin. However, the procedure caused a more profound wound than expected, for which we preferred to close by primary intention with 3 stitches 3-0 polypropylene to speed up breach closure.

The patient was treated for the following two weeks, and upon removal of the stitches, the wound was found to be fine and healing. After 1 year of a follow-up, the patient showed no clinical recurrences.

## Discussion

SMLPDs are rare primitive affections of the skin with limited data regarding the long-term morbidity and recurrence rate, due to the recent nosological definition of the disease and its rare diagnosis<sup>2-6</sup> compared to the broader, continuous and more robust evidence of other primitive skin lymphoma.<sup>7,8</sup> Since most data come from a limited number of published cases and retrospective studies<sup>9,10</sup>, there is a lack of evidence regarding the dermoscopic appearance and the preferred treatments for this disease.<sup>11</sup> It has been considered a skin-limited primitive formation once any possible concomitants loco-regional or systemic lymph node and organ affections are discarded.<sup>12</sup> Since then, it has been widely addressed with excision surgery with conservative margins.<sup>13</sup> However, selective radiation therapy<sup>14</sup> and local steroids<sup>15</sup> have also been used to address cells' proliferative potential and lymphoid origin, sensible to radiotherapies and steroid suppression, even if locally. On the contrary, the use of an ablative treatment with CO<sub>2</sub> has never been reported before, and we propose it as a treatment option since it allows the removal of the entire lesion

with minor margins. Indeed, using the same ratio of a tumour extirpation with close margins, it is supposed to ensure radicality even without histopathological margin controls. It could also be considered an acceptable alternative to steroid and radiation therapies due to the indolent course of disease. However, for our limited experience, it is still advisable to perform a local excision of a single nodule, even if already biopsied, to ensure a second histopathological evaluation and better control of the depth and wound healing process instead of ablating the mass until reaching peripheral tissues with only eye-guided tissue vaporisation.

## Conclusions

Laser CO<sub>2</sub> ablative treatment with minor margins of SMPLPD single nodule could be considered an alternative if local excision is not viable for selected patients. It would reduce minor bleeding during the procedure and for the medication. It would also allow second-intention healing for small nodular lesions. However, more extended data regarding the follow-up of these patients and, in general, of SMPLPDs in the long term are needed.

## References

1. Ungureanu L, Vasilovici A, Şenilă SC, et al. Dermoscopy in the diagnosis of cutaneous lymphoma (Review). *Exp Ther Med* 2022;23:377.
2. Grogg KL, Jung S, Erickson LA, et al. Primary cutaneous CD4-positive small/medium-sized pleomorphic T-cell lymphoma: a clonal T-cell lymphoproliferative disorder with indolent behavior. *Mod Pathol* 2008;21:708–15.
3. Bakr F, Wain EM, Barlow R, Robson A. Primary Cutaneous CD4+ Small/Medium T-Cell Lymphoproliferative Disorder or Primary Cutaneous Marginal Zone B-Cell Lymphoma? Two Distinct Entities With Overlapping Histopathological Features. *Am J Dermatopathol* 2021;43:e204–12.
4. Plumtre IR, Said JT, Sun T, et al. Clinical features and treat-

- ment outcomes for primary cutaneous CD4+ small/medium T-cell lymphoproliferative disorder: a retrospective cohort study from the Dana-Farber Cancer Institute and updated literature review. *Leuk Lymphoma* 2022;63:2832–46.
5. Bakr F, Wain EM, Wong S, et al. Prominent Blasts in Primary Cutaneous CD4+ Small/Medium T-Cell Lymphoproliferative Disorder. A Reconsideration of Diagnostic Criteria. *Am J Dermatopathol* 2021;43:e190–6.
  6. Swerdlow SH, Campo E, Pileri SA, et al. The 2016 revision of the World Health Organization classification of lymphoid neoplasms. *Blood* 2016;127:2375–90.
  7. Alberti Violetti S, Alaibac M, Ardigò M, et al. An expert consensus report on mycosis fungoides in Italy: epidemiological impact and diagnostic-therapeutic pathway. *Ital J Dermatol Venerol* 2021;156:413–21.
  8. Pileri A, Morsia E, Zengarini C, et al. Epidemiology of cutaneous T-cell lymphomas: state of the art and a focus on the Italian Marche region. *Eur J Dermatol* 2023;33:360–7.
  9. Ayala D, Ramón MD, Cabezas M, Jordá E. Primary Cutaneous CD4+ Small/Medium-Sized Pleomorphic T-Cell Lymphoma With Expression of Follicular T-Helper Cell Markers and Spontaneous Remission. *Actas Dermosifiliogr* 2016;107:357–9.
  10. Yi LG, Gru AA. Primary Cutaneous CD4-Positive Small/Medium T-Cell Lymphoproliferative Disorder Mimicking Jessner Lymphocytic Infiltrate and Tumid Lupus-A Report of Two Cases. *Am J Dermatopathol* 2021;43:e293–7.
  11. Salah E. Primary cutaneous CD4+ small/medium pleomorphic T-cell lymphoproliferative disorder: Where do we stand? A systematic review. *JDDG: J Dtsch Dermatol Ges* 2019;17:123–36.
  12. Gru AA, Wick MR, Eid M. Primary cutaneous CD4+ small/medium T-cell lymphoproliferative disorder-clinical and histopathologic features, differential diagnosis, and treatment. *Semin Cutan Med Surg* 2018;37:39–48.
  13. Kim J, Jeong M, Jun D, et al. Primary cutaneous CD4+ small/medium T-cell lymphoma: a case report. *Arch Craniofac Surg*. 2021;22:199–203.
  14. Kim EJ, Aria AB, Wilmas K, et al. Primary cutaneous CD4+ small- to medium-sized pleomorphic T-cell lymphoproliferative disorder in a pediatric patient successfully treated with low-dose radiation. *Pediatr Dermatol*. 2019;36:e23–6.
  15. Valentim F de O, Oliveira CC, Miot HA. Case for diagnosis. Primary cutaneous CD4+ small/medium T-cell lymphoproliferative disorder. *An Bras Dermatol* 2019;94:99–101.